THE AMERICAN HEART JOURNAL

©Am. Ht. Assn.

A JOURNAL FOR THE STUDY OF THE CIRCULATION

PUBLISHED MONTHLY

UNDER THE EDITORIAL DIRECTION OF

THE AMERICAN HEART ASSOCIATION

ADVISORY EDITORIAL BOARD

EDGAR V. ALLEN
E. P. CARTER
HENRY A. CHRISTIAN
ALFRED E. COHN
ELLIOTT C. CUTLER
WALTER W. HAMBURGER
JAMES B. HERRICK
WILLIAM J. KERR
SIR THOMAS LEWIS
E. LIBMAN
H. M. MARVIN
JONATHAN MEAKINS
JOHN H. MUSSER
JOHN ALLEN OHLE
STEWART R. ROBERTS
G. CANBY ROBINSON
FRED M. SMITH
PAUL D. WHITE
CARL J. WIGGERS
FRANK N. WILSON
CHARLES C. WOLFERTH

Lewis A. Conner.....Editor

Associate Editors

Hugh McCulloch Evelyn Holt

Irving S. Wright

VOLUME 13

JANUARY—JUNE, 1937

ST. LOUIS

THE C. V. MOSBY COMPANY

1937

COPYRIGHT, 1937, BY THE C. V. MOSBY COMPANY

(All rights reserved)

Printed in U. S. A.

(R.R.)
L32m73:N25
G7
5758

Press of
The C. V. Mosby Company
St. Louis

It should be clearly stated in the beginning that it is not the purpose of this paper to attempt to establish any etiological relationship between the hyperreactivity of the vasomotor system to the stimuli previously mentioned and the hypertensive state. However, aside from any etiological significance that might exist, it appears to us that this phenomenon is most certainly of sufficient importance to warrant investigation of the mechanism which produces it. The work reported in this paper was undertaken in the hope that it might throw some further light on this mechanism.

STATEMENT OF PROBLEM

The present investigation is concerned, generally speaking, with the problem of the abnormal vasopressor response to certain stimuli (cold, pain, etc.) which occurs among subjects who have essential hypertension and among certain individuals who have a normal blood pressure. It represents an attempt to determine whether or not this abnormal vasomotor response might be explained in part by the presence of an arteriolar hypersensitivity to pressor stimuli. Specifically, it is concerned with determination of the reaction of the digital arterioles to a common stimulus, epinephrine. The reaction is measured by determination of the cutaneous temperature. The types of subjects employed are divided into groups which will be explained later.

The investigations of Raab[2, 7] on this problem led him to conclude that the abnormal response of the blood pressure of hypertensive subjects to various stimuli is caused by a hyperirritability of the vasomotor centers produced by the accumulation of lactic acid within these centers. He based this conclusion on his experimental work which showed, first, that a hyperirritability of the vasomotor centers of cats to inhaled carbon dioxide resulted from a shortage of oxygen, or perfusion of the brain stem with lactic acid and, second, that a similar hyperirritability occurred among human subjects who had essential hypertension.

Apparently, very little attention has been directed toward the possibility that the peripheral vasomotor mechanism might play a part in this abnormal reaction. Lian, Stoicesco, and Vidrasco[8] by means of the plethysmograph investigated the effect of intravenous administration of a solution of epinephrine on the blood flow of the forearm of normal and hypertensive subjects and concluded, generally speaking, that there is a marked hyperexcitability of the vasomotor system of the hypertensive individual. One cubic centimeter of a 1:100,000 solution of epinephrine when administered intravenously to hypertensive subjects produces a greater rise in the blood pressure and plethysmographic evidence of a much greater peripheral vasoconstriction than it does when administered to normal individuals. This would seem to indicate that the peripheral arterioles of hypertensive

of 30° C. was established as the minimal level at which the observations were made. After the temperature of the digits had reached a fairly stable level, the infusion was started. Physiological saline solution was administered for a short period; then, without the patient's knowing it, administration of a 1:250,000 solution of epinephrine was begun. This solution usually was administered for twenty to thirty minutes. The rate of the injection was sufficiently rapid (usually 3 to 9 c.c. per minute; 0.012 to 0.036 mg. of epinephrine per minute) to produce a minimal elevation of 20 mm. of mercury in the systolic blood pressure. The administration of epinephrine then was stopped and at times the physiological saline solution was allowed to run into the vein for a short period, that is, long enough as a rule to allow the temperature of the digits to regain the preinjection level. At other times, administration of the physiological saline solution and administration of the solution of epinephrine were stopped simultaneously. Such a procedure was followed for the purpose of eliminating as much as possible the psychic factors that might have influenced the cutaneous temperature had the patients known the exact moment at which the administration of epinephrine was to be started. During the entire observation the blood pressure, pulse rate, and the cutaneous temperature of the volar surfaces of the distal phalanges of several of the digits of the upper extremities were taken at intervals of three to five minutes. The observations of the cutaneous temperature were made by using a thermopile equipped with copper-constantan junctions.

INDIVIDUALS OBSERVED

Fifteen individuals were observed. These were divided into three groups: Group 1 consisted of five individuals who had normal blood pressures and reacted normally to the cold pressor test. As far as could be ascertained by physical and ophthalmoscopic examination, the individuals in this group possessed normal arteries. Group 2 consisted of three subjects who had normal blood pressures but reacted abnormally to the cold pressor test; that is, there was an increase of more than 20 mm. of mercury in the values for the systolic and diastolic pressures. Group 3 consisted of seven individuals who had clinical evidence of hypertension and reacted abnormally to the cold pressor test.

RESULTS

The vasoconstrictor effect of epinephrine was measured as the extent of the decrease in cutaneous temperature (expressed in degrees centigrade) from the preinjection level. The results have been charted in three ways: first, as the maximal decrease in digital temperature in each individual case; second, as the minimal decrease in digital temperature in each individual case; and third, as the average decrease in digital temperature in each individual case. This last value was obtained by adding the values representing the decrease in temperature of all the digits measured in an individual case and dividing this result by the number of digits measured. The results obtained are shown in Fig. 1.

Group 1.—It will be seen that in this group there was a marked variation in the decrease in cutaneous temperature; the maximal response varied from a decrease of 7.6° to 0.8° C. It also will be seen that there

thetic impulses. In view of the fact that the action of epinephrine on the digital arterioles is similar to its action on the arterioles of the greater part of the body, it might be reasoned that in general the sensitivity of the arterioles of hypertensive individuals to pressor stimuli is no greater than is that of the arterioles of normal individuals. The limitations of our observations, however, do not justify the formation of this conclusion.

However, we do feel that these observations definitely establish the fact that there is no difference in the sensitivity of the digital arterioles of normal and hypertensive subjects to the intravenous administration of epinephrine, as measured by studies of the cutaneous temperature. It would seem that this fact rather supports the idea that in hypertension the abnormality which results in an overactivity of the vasomotor system in response to certain stimuli, such as carbon dioxide and cold, is not the result of any hypersensitivity of the arterioles to pressor stimuli, but is probably situated centrally in the vasomotor centers.

SUMMARY

The sensitivity of the digital arterioles of normal and hypertensive subjects to intravenous administration of epinephrine was investigated.

We found that there is no essential difference in the sensitivity of the arterioles of these two groups of individuals to the administration of epinephrine.

The possible relationship that the results of these observations might have to the abnormal vasomotor mechanism present in cases of hypertension has been considered.

REFERENCES

1. Pal, J.: Gefässkrisen, Leipzig, 1905, S. Hirzel.
2. Raab, W.: Die Beziehungen zwischen CO_2-Spannung und Blutdruck bei Normalen und Hypertonikern, Ztschr. f. d. ges. exper. Med. 68: 337, 1929.
3. Hardgrove, M., Roth, Grace, and Brown, G. E.: Unpublished data.
4. Baráth, Eugene: Arterial Hypertension and Physical Work, Arch. Int. Med. 42: 297, 1928.
5. O'Hare, J. P.: Vascular Reactions in Vascular Hypertension, Am. J. M. Sc. 159: 369, 1920.
6. Hines, E. A., Jr., and Brown, G. E.: A Standard Test for Measuring the Variability of Blood Pressure: Its Significance as an Index of the Prehypertensive State, Ann. Int. Med. 7: 209, 1933.
   Idem: A Standard Stimulus for Measuring Vasomotor Reactions: Its Application in the Study of Hypertension, Proc. Staff Meet. Mayo Clin. 7: 332, 1932.
7. Raab, W.: Central Vasomotor Irritability: Contribution to the Problem of Essential Hypertension, Arch. Int. Med. 47: 727, 1931.
8. Lian, C., Stoicesco, S., and Vidrasco, C.: De l'état du système nerveux végétatif dans l'hypotension et l'hypertension artérielles permanentes, Presse méd. 2: 1309, 1929.
9. Steele, J. M., and Kirk, E.: Significance of Vessels of Skin in Essential Hypertension, J. Clin. Investigation 13: 895, 1934.
10. Elliott, T. R.: The Action of Adrenalin, J. Physiol. 32: 401, 1905.
11. Cannon, W. B.: Sympathin E and Sympathin I, Tr. A. Am. Physicians 48: 236, 1933.
12. Freeman, N. E., Smithwick, R. H., and White, J. C.: Adrenal Secretion in Man; Reactions of Blood Vessels of Human Extremity, Sensitized by Sympathectomy to Adrenalin and to Adrenal Secretion Resulting From Insulin Hypoglycemia, Am. J. Physiol. 107: 529, 1934.

These figures include the total number of uninflamed hearts in each series, and the results with each injection material were recorded for comparison. The best efforts failed to produce an absolutely even suspension of lamp black. Small clumps of the individual particles were frequently observed when microscopic search was made for them, and it is believed that lamp black gives a lower percentage of injected vessels than does the India ink (Weber's) or soluble blue. These last two were satisfactory suspensions for the injection of capillaries.

The necessity of a clear definition of what is meant by a heart valve in this investigation is obvious. The character of the aortic and pulmonic cusps is such that no significant difference of opinion as to what constitutes "valve" can exist. The frequent extension of a myocardial wedge into the atrioventricular leaflets has led to differences of opinion as to what part of the leaflets is truly valve. A broad definition of the heart valves, and the one that we regard as correct, is that they are fibrous or fibromuscular membranes attached to the inner surface of the heart wall which, when closed, normally form an intact septum preventing the regurgitation of blood. By such a definition, the myocardial muscle wedge or even a part of the fibrous ring attachment would frequently be a part of the valve. In no instance was a valve recorded as vascularized unless vessels extended beyond a line drawn perpendicular to its surface and through the most distal point of its basal attachment.

Another definition and one which is based on the histological structure of the valve was proposed by Gross and Kugel.[2] They did not believe that the frequent extensions of the myocardium or the fibrous connective tissue from the valve ring into the center of the proximal portion of the valve should be regarded as part of the valve proper. The extent of the myocardial wedge is variable, especially in the septal leaflet of the mitral and tricuspid valves and in both situations frequently retracts with age. With the retreat of the wedge a fibrous or fibromuscular tongue often persists. It is our belief that functionally and anatomically this proximal portion of the leaflet is still valve, regardless of whether it contains myocardium or not.

Despite this academic difference as to the exact definition of a heart valve, it must be accepted that so far as the normal vascularization of the valves in relation to endocarditis is concerned, it is the distal fibroelastic portion of the valve that constitutes the significant zone.

It was not the purpose of this investigation to study the vascularization only of normal valves, but also to compare valve vascularization in inflamed and normal hearts. It is difficult to define an absolutely normal valve because of inherent developmental differences, age changes, and varying degrees of sclerosis. The macroscopic criteria

The third group of structural variations which, so far as we know, is not related to inflammation, is represented by focal degenerative changes frequently associated with calcification. These changes are commonly termed "endocardial" or "subendocardial sclerosis" and have been described in detail by Ribbert,[4] Beitzke,[5] Dewitzky,[6] and Mönckeberg.[7]

Without attempting to review the various noninflammatory degenerative changes ordinarily ascribed to sclerosis, attention must be directed to the difficulties occasionally encountered in distinguishing such changes from those due to healed endocarditis. The work of Böhmig and Krückeberg[8] illustrates the futility of attempting to establish an arbitrary distinction between healed inflammation and sclerosis of heart valves in the case of some of the borderline lesions. These investigators described nine anatomical layers in each of the atrioventricular valves and were of the opinion that in the case of localized nonexudative valve thickening, the determination of the particular layer involved is of great importance in distinguishing between inflammatory and sclerotic lesions. Such conclusions are not susceptible of proof or disproof. Obviously the possibility of an inflammation having been present in any given valve cannot be excluded. Theoretically, an inflammation can be so mild and be followed by such complete healing that either no scar is formed or, if it were formed, the scar cannot be recognized as the end-result of an inflammatory process. It does not seem likely that, even if a given indeterminate lesion could be oriented according to the nine zones of Böhmig and Krückeberg, its true identity would be any more accurately determined.

The inscriptions on the monuments to inflammation fade, and it will always remain a matter of opinion as to when they cease to be decipherable. Since this investigation had for its objective the determination of the incidence of vessels in normal valves, in contradistinction to valves that have been the seat of inflammation, the criteria for distinguishing the two must be defined. These criteria are defined with no illusions as to their infallibility and with the knowledge that certain hearts included in the normal group may have sustained a valvulitis at some remote time and that other hearts may have been excluded because of an erroneous suspicion of past inflammation. Having previously excluded all hearts in which there was shortening or adhesions between leaflets or cusps, recognizable vegetations whether they were active or healed, or shortening, thickening, or adhesions between chordae tendineae, the only microscopic ground for excluding a heart grossly accepted as noninflammatory is the finding of an active or organizing inflammatory lesion which had not been recognized on the gross examination. Fibroblastic proliferation, reduplica-

tion of elastic fibers, or the presence of thick-walled blood vessels with or without exudation, was considered acceptable microscopic evidence of inflammation.

The 333 hearts injected were divided into two groups, the first including 78 hearts which were judged to be or to have been the seat of inflammation, and the second comprised of 255 hearts regarded as being free from any stigmas of active or healed inflammation.

The percentile incidence of valve vascularization in the two groups is shown in Table II. In the inflammatory group, sixty-nine hearts, or 88 per cent of the entire group, had one or more valves vascularized. The mitral valve contained vessels most frequently, the incidence being 82 per cent, and, of the two mitral leaflets, the anterior was vascularized more commonly than the posterior in a ratio of 5 to 4. No significant differences were noted in the selective vascularization of the tricuspid leaflets or of the aortic or pulmonic cusps. The mitral was the valve most commonly affected by inflammatory changes in this series and was followed by the aortic, tricuspid, and pulmonic in diminishing frequency. Despite the fact that the pulmonic valve was least frequently the seat of valvulitis, 37 per cent of all pulmonic valves in the inflammatory group of hearts were vascularized. This represents a higher incidence of vascularization than is seen in the aortic (27 per cent), although the aortic valve was the seat of inflammation eight times as frequently as the pulmonic.

TABLE II

	PERCENTILE INCIDENCE OF VALVE VASCULARIZATION				
	MITRAL	TRICUSPID	AORTIC	PULMONIC	TOTAL
Seventy-eight hearts showing active or healed inflammation	82%	51%	27%	37%	88%
Two hundred and fifty-five hearts showing no active or healed inflammation	50%	31%	5%	14%	66%

In the noninflammatory group of 255 hearts there were 168, or 66 per cent, in which one or more valves were vascularized. The same order of frequency of valves affected was seen here as in the inflammatory group, the mitral having the highest incidence (50 per cent) followed by the tricuspid, pulmonic, and aortic in diminishing frequency. The same order of the frequency with which the various valves were vascularized was observed in the previous study by Wearn, Bromer and Zschiesche.[1]

A comparison of the inflammatory and noninflammatory groups, according to the number of valves vascularized in each heart, is shown in Table III. In the inflammatory group the vascularization of more than one valve was more common than the vascularization of a single valve in a ratio of 2 to 1. Vascularization of all four valves was seen in 17 per cent of the entire group.

In the noninflammatory group, vascularization of a single valve was more common than vascularization of more than one valve, in a ratio of 4 to 3, and in less than 1 per cent of the noninflammatory hearts were all four valves vascularized.

TABLE III

	PERCENTILE INCIDENCE OF MULTIPLE VALVE VASCULARIZATION				
	1 VALVE	2 VALVES	3 VALVES	4 VALVES	TOTAL
Seventy-eight hearts showing active or healed inflammation	28%	29%	14%	17%	88%
Two hundred and fifty-five hearts showing no active or healed inflammation	38%	22%	5%	1%	66%

The foregoing data are at variance with the observations of Gross and Kugel,[2] and it was thought that differences in the anatomical conception of what constitutes a valve might account in part for the higher incidence of vascularization of noninflammatory heart valves reported here. As stated in the early part of this paper, we chose to regard the entirety of the freely moving membranes between chambers or between the chambers and the large arteries as valve leaflets or cusps. Prolongations of myocardium or extensions of the fibrous valve rings are frequently present in the atrioventricular valves. Gross and Kugel[2] did not regard such extensions as part of the valves, and, when valve vascularization was confined to intravalvular prolongations of cardiac muscle or fibrous connective tissue extensions from the annulus, they did not regard the valve as being vascularized. So far as the relation of blood vessels to valvulitis is concerned, it must be admitted that it is the vessels beyond the basal third which are significant, since the most commonly occurring inflammatory lesions are in the distal rather than the proximal portions of valves. Since the difference in the anatomical concept of a valve applied chiefly to the atrioventricular leaflets, 104 atrioventricular leaflets from noninflammatory hearts in which vessels were limited to the proximal third were cut in such a manner that blocks for histological examination included the sites of vascularization. The results are shown in Table IV.

TABLE IV

LOCATION OF VESSELS IN ONE HUNDRED AND FOUR UNINFLAMED ATRIOVENTRICULAR LEAFLETS IN WHICH VASCULARIZATION WAS LIMITED TO THE BASAL THIRD OF THE LEAFLETS

	PERCENTILE INCIDENCE
Vessels in myocardial muscle wedge in leaflets	62
Vessels in extension of fibrous valve ring into leaflet	25
Vessels in atrial lamella of leaflet	10
Vessels in ventricular lamella of leaflet	3

Table IV reveals that only 13 per cent of the atrioventricular valves reported by us as being vascularized in their proximal portions would be accepted by Gross and Kugel[2] as being truly vascularized valves.

Since all valves in injected hearts were drawn to scale on square millimeter paper with the location and length of vessels indicated, it is possible to determine the extent to which each valve was vascularized. All vascularized valves were classified in two groups, according to whether the vessels were confined to or extended beyond the proximal or basal third of the leaflet or cusp. These data are recorded in Table V.

TABLE V

	UNINFLAMED HEARTS		INFLAMED HEARTS	
	VESSELS LIMITED TO PROX. THIRD (PERCENTILE INCIDENCE)	VESSELS EXTENDING BEYOND PROX. THIRD (PERCENTILE INCIDENCE)	VESSELS LIMITED TO PROX. THIRD (PERCENTILE INCIDENCE)	VESSELS EXTENDING BEYOND PROX. THIRD (PERCENTILE INCIDENCE)
Aortic	2	3	7	20
Pulmonic	10	4	23	14
Mitral	26	24	22	66
Tricuspid	21	10	23	28

With the elimination of all valves vascularized only in their proximal portions, there still remain 32 per cent of all noninflammatory and 69 per cent of all inflammatory hearts with one or more valves vascularized beyond the proximal third of leaflets or cusps.

There is considerable difference in the mean age of the two groups of individuals from whom inflamed and uninflamed hearts were obtained. The mean age of the inflammatory group was fifty years and of the noninflammatory group, thirty-four years. It was desirable to reclassify the noninflammatory group according to age in order to determine if any age relationship to extent of vascularization exists. Table VI shows the observed relation of age to occurrence and extent of valve vascularization in uninflamed hearts.

TABLE VI

THE INCIDENCE AND EXTENT OF VESSELS IN UNINFLAMED VALVES IN RELATION TO AGE

AGE IN YEARS	NO. OF CASES	PER CENT OF HEARTS IN WHICH VESSELS EXTENDED BEYOND PROXIMAL THIRD OF VALVE	TOTAL PERCENTAGE OF HEARTS IN WHICH ONE OR MORE VALVES WERE VASCULARIZED
0-20	77	19.5	54.5
21-40	61	26.0	59.0
41-60	86	37.0	76.5
61-80	31	61.0	77.0

The two significant changes in valve vascularization in relation to age are seen. The first is the absolute increase of valve vascularization, from an incidence of 54.5 per cent in the first two decades to an in-

cidence of 77 per cent in the two decades between sixty-one and eighty years. The second is the relative increase in the extent to which valves are vascularized, beginning with a 19.5 per cent incidence in the youngest age group and increasing to 61 per cent in the oldest group, in which one or more valves were vascularized beyond the proximal third. This observation of the increasing incidence of valve vascularization with age is in accord with the earlier data of Wearn, Bromer, and Zschiesche. A rearrangement of their data is shown in Table VII.

TABLE VII

THE INCIDENCE OF VESSELS IN THE VALVES OF EIGHTY-THREE UNINFLAMED HEARTS IN RELATION TO AGE*

AGE PERIOD	NO. OF CASES	TOTAL PER CENT OF HEARTS IN WHICH ONE OR MORE VALVES WERE VASCULARIZED
0-20	13	60
12-40	19	74
41-60	36	90
61-80	15	100

*Wearn, Bromer, and Zschiesche.[1]

Their data also show an increasing incidence of vessels in valves with age and in the older age groups show a higher incidence of vascularization than that observed in the present study. The difference may be the result of chance variation in hearts examined or may be due to better injections obtained with India ink than were obtained with lamp black or soluble blue. (See Table I for comparison of various injection fluids.)

SUMMARY AND DISCUSSION

The coronary arteries of 333 hearts were injected with a suspension of lamp black or soluble blue, and the occurrence and distribution of vessels in the valves were studied. The hearts were divided into two groups according to whether there was evidence of inflammatory heart disease or not. Careful macroscopic and exhaustive microscopic examination was carried out for the purpose of establishing the noninflammatory group, which, so far as could be determined, included no instance of healed or active myocardial or endocardial inflammation.

In the noninflammatory group there were 255 hearts from individuals ranging from infancy to old age, the mean age being thirty-four years. Sixty-six per cent of these showed vascularization of one or more valves. Microscopic examination of the vascularized valves showed that, in a large proportion of the valves vascularized only in their proximal portion, the vessels were confined to prolongations, either of myocardial muscle fibers or of the fibrous valve ring beyond

the base and into the valve. In 32 per cent of the entire group one or more valves were vascularized beyond the proximal third of the leaflets or cusps.

Both the occurrence and the length of vessels in valves of noninflammatory hearts increased with age. There appears to be an acquisition of new vessels in valves with advancing age and also an age increase in the extent to which individual valves are vascularized. The increased incidence of valves vascularized was not as striking as was the increased number and length of vessels in the valves vascularized.

The increased incidence and extent of vessels with age would suggest that the valves were the seat of occult active or unrecognized healed inflammation. Unrecognized inflammation, however, does not suffice to explain the existence of all vessels in valves in view of the fact that in 19 per cent of the normal hearts of children under ten years of age, one or more valves were vascularized beyond their proximal third. Furthermore, there were forty-nine infants under one year of age in the noninflammatory group and in twelve of them one or more of the heart valves were vascularized beyond the proximal third. It seems probable then that normal valves are commonly vascularized beyond their proximal third and that, if the acquisition of new vessels and the lengthening of old vessels in valves with advancing age are due to inflammation, the inflammation must leave no recognizable trace of its occurrence.

A similar study was made of the incidence and character of valve vascularization in seventy-eight hearts recognized as being or as having been the seat of inflammation. Eighty-eight per cent of the entire group showed vascularization of one or more valves, and in 69 per cent of the entire group one or more valves were vascularized beyond their proximal third. These figures indicate a considerable increase in the occurrence and extent of valve vascularization in this group as compared with the noninflammatory group. The actual difference was not as great as the apparent difference because the mean age of the inflammatory group was fifty years, whereas that of the noninflammatory group was thirty-four years. A comparison of the incidence of vascularization in the inflammatory group with that in a comparable noninflammatory age group showed a total incidence of 88 per cent in the former as compared with 76.5 per cent in the latter and an incidence of vascularization beyond the proximal third of 69 per cent in the former as compared with 37 per cent in the latter.

The frequency with which the various individual valves were vascularized followed the same sequence in the inflammatory and in the noninflammatory groups, the mitral having the highest incidence in each group, followed by the tricuspid, pulmonic, and aortic in diminishing frequency. The sequence of the incidence with which

the various valves were vascularized in the inflammatory group did not correspond to the frequency with which the various valves were affected by inflammation. The mitral valve was most commonly the seat of valvulitis, followed by the aortic, tricuspid, and pulmonic valves in diminishing frequency.

The incidence of the vascularization of multiple valves in each heart was higher in the inflammatory than in the noninflammatory group. This is especially apparent in the case of vascularization of all four valves in a single heart. Seventeen per cent of the entire inflammatory group showed vessels in all four valves in contrast to an incidence of less than 1 per cent of similarly extensive vascularization in the noninflammatory group.

CONCLUSIONS

1. *Vascularization of Normal Valves.*—The frequent presence of blood vessels in the valves of infants and children in whom the absence of degenerative or proliferative age changes makes possible the recognition of normal anatomical structure definitely establishes the existence of vessels in normal heart valves.

2. *Inflammatory Vascularization of Valves.*—The increased incidence and extent of vascularization of valves which are the seat of inflammation indicate that valves not originally vascularized may acquire vessels incident to inflammation.

3. *Age Changes in the Occurrence and Character of Vascularization of Noninflammatory Valves.*—There is an apparent age increase in the incidence and extent of valve vascularization which may represent a normal anatomical age change or may be the result of occult active or healed valvulitis.

REFERENCES

1. Wearn, J. T., Bromer, A. W., and Zschiesche, L. J.: The Incidence of Blood Vessels in Human Heart Valves, Am. Heart J. 11: 22, 1936.
2. Gross, L., and Kugel, M. A.: Topographic Anatomy and Histology of the Valves in the Human Heart, Am. J. Path. 7: 445, 1931.
3. Karsner, H. T.: Textbook of Pathology, ed. 4, Philadelphia, 1935, J. B. Lippincott Company, p. 444.
4. Ribbert, H.: Die Erkrankungen der Endokards, Handbuch der speziellen pathologischen Anatomie und Histologie, Henke, F., and Lubarsch, O., Berlin, 2: 184, 1924, Julius Springer.
5. Beitzke, H.: Ueber die sogenannte "Weissen Flecken" am grossen Mitralsegel, Virchows Arch. f. path. Anat. 163: 343, 1901.
6. Dewitzky, W.: Ueber den Bau und die Entstehung verschiedener Formen der chronischen Veränderungen in den Herzklappen, Virchows Arch. f. path. Anat. 199: 273, 1910.
7. Mönckeberg, J. G.: Der normale histologische Bau und die Sklerose der Aortenklappen, Virchows Arch. f. path. Anat. 176: 472, 1904.
8. Böhmig, R., and Krückeberg, B.: Untersuchungen über die diagnostischen Schwerigkeiten bei chronischen Veränderungen der Mitralklappe (Mit Beitrag zur normalen Histologie), Beitr. z. path. Anat. u. z. allg. Path. 94: 163, 1934.

CONCERNING A NEW CONCEPT OF THE GENESIS OF THE ELECTROCARDIOGRAM*

L. N. Katz, M.D.
In Collaboration With A. Bohning, M.D., I. Gutman, M.D., K. Jochim, M.D., H. Korey, M.D., F. Ocko, M.D., and M. Robinow, M.D.
Chicago, Ill.

THE problem of the genesis of the electrocardiogram has intrigued investigators ever since the time of Waller and Einthoven. The problem, which is to define and account for the electrical field created by the heart, can be divided into three phases: (1) the time sequence and spatial orientation within the heart of the electromotive forces set up; (2) the distribution of the electrical currents generated by the heart within the body as a whole; and (3) the influence on the distribution of the electrical currents which results from the variable electrical conductivity of the tissues in contact with the heart, i.e., those tissues which make the bridge between the generator and the conducting medium. While considerable attention has been paid to the first two aspects of the problem, little thought has been given to the last. During the past few years, we have been concerned in this laboratory more particularly with this last aspect, and our studies have led us to a new concept of the genesis of the electrocardiogram. In the present communication an attempt is made to present this concept and to summarize briefly the evidence which has led us to this view. The material will be presented under the three aspects outlined above with the aid of schematic diagrams. No attempt will be made to review the extensive literature or to become involved in controversies with views already expressed since presentations of these controversial views are available in the literature, viz., Lewis,[1] Craib,[2] Katz,[3] Wilson and his coworkers,[4] Groedel,[5] Eyster and his collaborators,[6] and Gilson and Bishop.[7]

THE TIME SEQUENCE AND SPATIAL ORIENTATION WITHIN THE HEART OF THE ELECTROMOTIVE FORCES SET UP

The active heart in situ can be considered as equivalent to a composite electric battery placed in a relatively large volume of a conducting medium, a battery which varies the orientation of its poles and its potentials during the cardiac cycle. There is now a large body

*From the Heart Station and the Cardiovascular Laboratory, Department of Physiology, Michael Reese Hospital.

Presented before the American Society for Clinical Investigation at Atlantic City, May 19, 1936.

of evidence to show that resting muscle cells, including the heart, are in a state of electrical polarization at their surfaces. There is still some controversy concerning the manner in which this polarized state is brought about, but it has been shown to depend on the activity of the living cell, which requires energy for its creation and maintenance. Any attempt to destroy this state of electrical polarization tends to bring about its restitution unless the cell is killed. It has also been established that stimulation and the process of activity cause a temporary loss of the polarized state of the cell (depolarization). Sometimes, as in an injured region of the heart, there is a balance between the processes of depolarization and restitution, resulting in a sustained state of partial or almost complete depolarization. Advantage has been taken of this last fact to define the electrical activity of the various fractions of the heart during the cardiac cycle. For example we (Jochim, Katz and Mayne[8]; Katz, Jochim, and Abramson[9]) have determined the synchrony of the onset of depolarization and of the reestablishment of the polarized state in various fractions of the mammalian heart. This was made possible by connecting in turn various spots of the heart through an Einthoven recording string galvanometer with a spot rendered inactive by injury (Jochim, Katz, and Mayme[8]). Evidence was presented, which has recently been confirmed by H. Wiggers,[10] that the curves so recorded can be used to measure the time course of events beneath the uninjured spots. It was found by reference to a simultaneously recorded lead (Lead II) that both the time of onset of depolarization and the time of the reestablishment of the polarized state were not synchronous in all the spots. Further, the time span between these two events showed a variation of as much as 0.03 sec. in the different spots, and the time curves from the various spots were out of phase.

In Fig. 1 an attempt is made to show these facts schematically. In this figure three uninjured spots of the dog's heart are depicted, connected in turn through a recording Einthoven string galvanometer with an injured spot. In the frame are shown the time curves which might have been obtained in this way during a heart cycle. The two vertical lines running between the curves represent, respectively, the peak of the major phase of the QRS complex and the peak of the T-wave in a simultaneously recorded Lead II. The curves show that both depolarization and repolarization are out of phase in the three spots. Depolarization starts after the peak of QRS_2 in the top curve, is simultaneous with the peak of QRS_2 in the middle curve, and starts before the peak of QRS_2 in the bottom curve. The order of reestablishment of the repolarized state is the exact reverse; viz., it occurs before the peak of T_2 in the top curve, is simultaneous with this point in the middle curve, and occurs after the peak of T_2 in the bottom

curve. The duration of time between depolarization and repolarization is, therefore, unequal, the time span being shortest in the top and longest in the bottom curve.

It is this asynchrony of similar events in different fractions of the heart that gives rise to the electromotive forces which cause electrical currents to flow within the heart and from the heart throughout the body. This, therefore, is the cause of the electrical field which we tap when electrocardiograms are recorded. A survey of the evidence in the literature available in 1928, with which more recent work has fitted, led the author[3] at that time to enunciate the process of genesis in the following terms:

"If we consider the heart a syncytium—and in the present state of our knowledge this view is just as reasonable as the alternative view that the heart is composed of individual discrete cells—then it follows

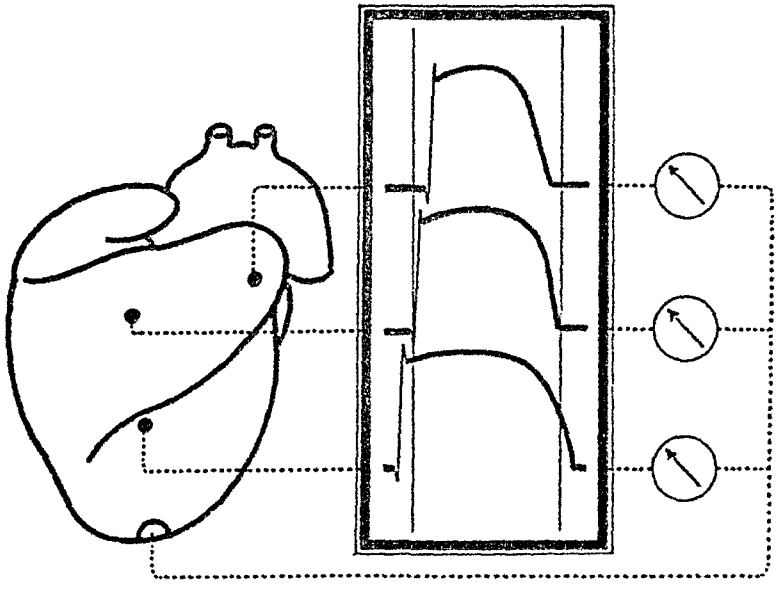

Fig. 1.—This is a diagram showing in the frame the curves which could be obtained from the three spots (solid circles) on the heart if they were connected in turn through galvanometers to an injured area (open circle). The two vertical lines running through the curves represent the peak of QRS of Lead II simultaneously recorded. The asynchrony of the three curves is clearly shown as well as the difference in their time spans. Discussed in text.

that as soon as a region becomes active it will tap the inside of the rest of the heart's syncytium. The active region will therefore act as the negative pole, and the rest of the heart, which is inactive, will of necessity act as the positive pole, the source and sink of the electrical potential being ultimately referable to the two sides of the intact membrane or surface. . . . Certain regions gain an advantage because the intensity of current flow varies not only with the difference in potential, but also with the amount of electrical resistance between regions having such differences of potential. Obviously, the greatest intensity of current flow will be between adjacent active and inactive regions, as the resistance is least here. For this reason adjacent active and inactive regions will appear to act as the two poles of the source

of the bioelectric current, although in reality it is the two sides of the intact surface layer or membrane in the inactive regions which is the source."

The exact geographical pattern of the asynchrony of depolarization and repolarization is at present undetermined. The classical picture presented by Lewis and Rothschild[11] has been questioned recently by Robb,[12] H. Wiggers,[10] and Abramson and Jochim.[13]

Aside from this source of electrical current, which may be briefly stated as the asynchronous depolarization and repolarization in the various regions of the heart, two other possibilities for the generation of electrical currents must be considered. The first is the electromo-

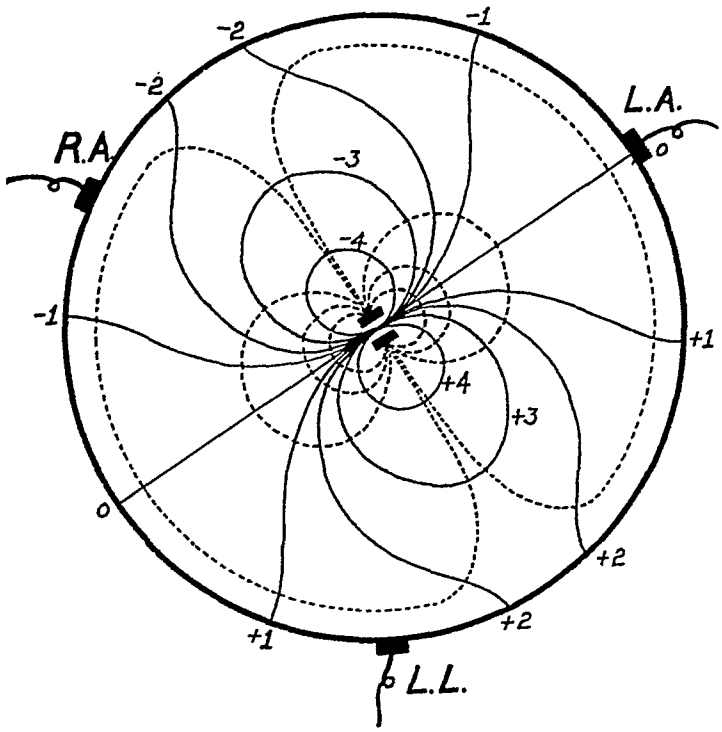

Fig. 2.—This is a diagram representing the electrical field set up in a circular homogeneous medium by a simple bipole placed in the center, indicated by the solid rectangles in the center. The solid lines indicate the lines of equipotential, the broken lines, the flow lines. The figures on the solid lines give the values of the potential lines in arbitrary units. *RA*, *LA*, and *LL* represent three electrodes placed at the angles of a triangle and are equivalent to the right arm, left arm and left leg electrodes. The triangle in this figure is equilateral. Discussed in text.

tive forces set up by the difference in the rate of migration of the positively and negatively charged ions when depolarization occurs (cf. Katz[3]). The second is frictional electricity. In recent work (Katz, Sigman, Gutman, and Ocko[14]) evidence was elicited that frictional electricity can set up electromotive forces when mercury in contact with the lungs is rhythmically agitated; such forces were demonstrated to occur in living unoperated dogs following the intravenous injection of mercury (Buchbinder and Katz[15]). The exact rôle played by these latter two factors is still unknown, but in all likelihood they are of minor significance.

DISTRIBUTION OF ELECTRICAL CURRENTS GENERATED BY THE HEART WITHIN THE BODY AS A WHOLE

The distribution of the currents from the heart within the body depends on the electrical properties of the various tissues composing the body. This phase of the problem can best be developed by means of simple models. In this laboratory we (Jochim and Katz[16]) have used such models. If a large circular dish containing concentrated salt solution is used and two electrodes are immersed in the center of the dish and connected to a 60 cycle 110 volt alternating current, then an electrical field is set up. This can be defined by using exploring

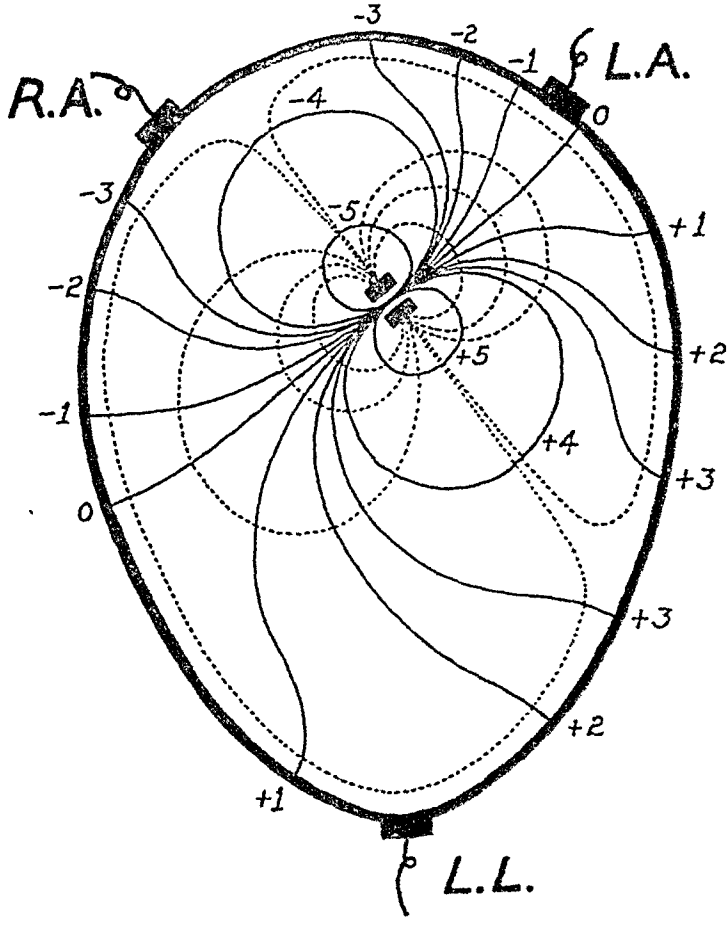

Fig. 3.—This is a diagram representing the electrical field set up in an ovoid homogeneous medium by a simple bipole placed eccentrically. Conventions as in previous figure. Note that the triangle at whose angles the electrodes *RA*, *LA*, and *LL* are placed is not equilateral. Discussed in text.

electrodes and a suitable method of measurement. (The method we used was suggested to us by Dr. A. Kolin of this department.) In this way the lines of equal potential in the field can be mapped out, and the lines of the current flow can be constructed as orthogonal trajectories. These lines will depict the distribution of the electrical flow and give information regarding the intensity of the flow of current and the gradient of the potential drop in the various parts of the field. The concentration of the lines of equipotential will give the potential drop, and the concentration of the lines of flow will give the intensity of the current flow.

The result of such an exploration is represented diagrammatically in Fig. 2; the lines of equipotential are shown as solid lines and the lines of current flow as interrupted ones. It will be seen that the current flow and the potential drop are greatest near the battery and least at the periphery of the field. If, in such a field, recording electrodes are placed at the periphery as indicated by *RA, LA* and *LL,* they form an equilateral triangle, and the Einthoven concept would apply accurately. In the body, however, these conditions are not fulfilled for several reasons: (1) the conducting medium of the body is not homogeneous nor is it spherical or circular; (2) the battery (the heart) is not centrally placed; and (3) the battery poles are of complex form. Let us consider the effect of each of these factors separately.

The electrical field of the body has the shape of the body; the limits are determined by the poor conducting environment surrounding it, viz., the outer layers of the integument and the air. The appendages, the head and the limbs, it has been established, have so little of the heart's current flowing in them and so small a gradient of potential drop (Wilson[17]) that they can be ignored without serious error. The shape of the electrical field can, therefore, be considered to be that of the torso. The heart, furthermore, is not in the center of this field but is sternad and considerably cephalad from the center. Obviously, both the shape of the conducting medium and the location of the battery in it will alter the electrical field.

In Fig. 3 is shown diagrammatically the electrical field that is obtained in an ovoid, homogeneous medium having the battery displaced upward from the center. The three electrodes, *RA, LA,* and *LL,* no longer form an equilateral triangle. This fact has been ignored or dismissed as of no significance, we believe unjustly, by many workers in the field. In fact, diagrams in many texts, of which Fig. 4 is an example, show at once how the positions of the three electrodes have been displaced to make the triangle appear equilateral. To accomplish this the body is foreshortened, the heart is put too far caudad, the leg electrode contact is displaced upward and to the right, and the arm electrode contacts are displaced laterally. It is not surprising that the Einthoven equilateral triangle concept has been questioned recently as to its practical utility (Zeisler,[18] Zeisler and Katz,[19] Eyster and his coworkers,[6] Koch-Momm,[20] and Storti[21]). Experience has convinced the author that the significance of axis deviation is not arrived at from the Einthoven equilateral triangle concept but rather on an empirical basis. Marked left axis deviation has been found, for example, in brown atrophy (Katz, Saphir and Strauss[22]), in displacement of the heart to the right with rotation (Robinow[23]) and, in accord with previous workers, we have found that the direction of the electrical deviation in the dog and in man does not always parallel the direction of the anatomical axis shift (Katz and Ackerman[24] and Katz and Robinow[25]).

The body is not a homogeneous conducting medium. Eyster and his collaborators[6] have shown clearly that the blood-filled compact muscle masses are sufficiently better electrical conductors than the other tissues of the body so that the electrical field of the body approaches that of a plane of homogeneous material, the greater dimensions of which are parallel to the plane formed by the standard limb electrodes. It can be shown that the introduction into a homogeneous conducting medium of conductors better and worse than the general medium will alter the electrical field set up by a battery in the medium. The amount of alteration will depend on several factors:

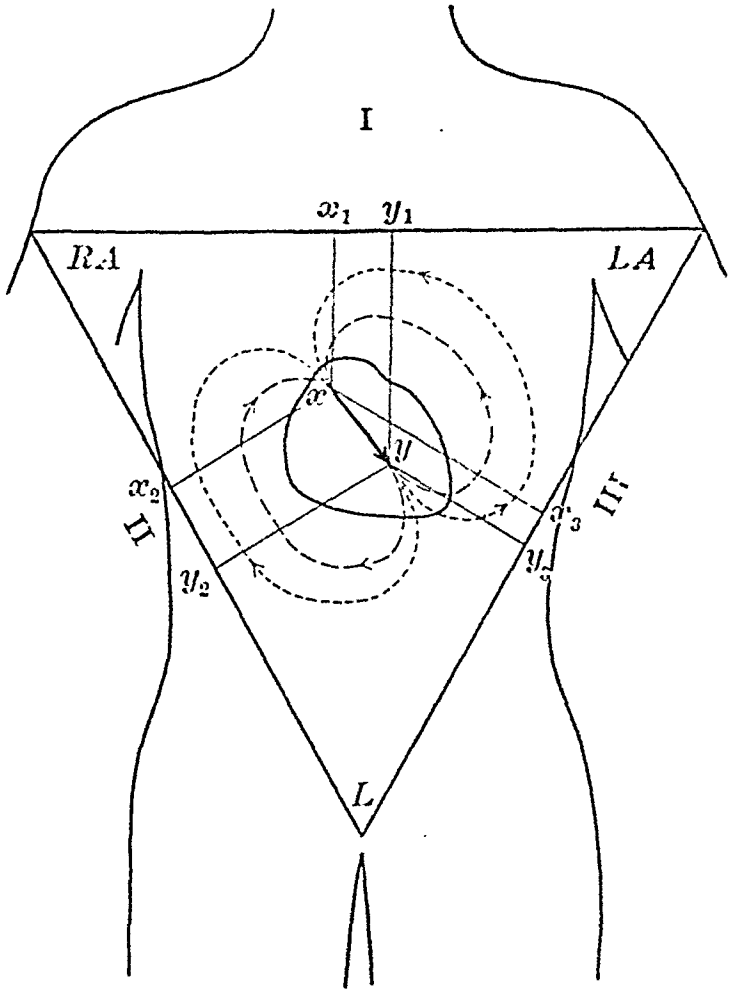

Fig. 4.—This is a reproduction of Fig. 96 from Wiggers' *Circulation in Health and Disease* (Lea & Febiger, ed. 2), which is modified from Fig. 1 of Parlee's *Clinical Aspects of the Electrocardiogram* (Hoeber). Discussed in text.

(1) the total volume of the nonhomogeneous conductors introduced, (2) the size of the individual masses of the introduced conductor, (3) the disparity between the specific electrical conductivity of the introduced mass and that of the surrounding medium, and (4) the distance of the introduced masses from the source generating the currents. The effect on the electrical field will be greater as the total volume introduced is increased, as the size of the individual masses is increased, as the disparity between the specific electrical conductivity of the introduced mass and the rest of the conducting medium is in-

creased, and as the introduced mass is brought toward the current source. If an introduced conductor is not spherical in shape, the effect will also vary, depending on how it is placed. When the introduced mass is a better conductor than the environment, it will push apart the lines of equipotential so that they are concentrated on its borders, and it will concentrate the lines of current flow within it. On the other hand, when the introduced mass is a poorer electrical conductor, the reverse will be true; it will concentrate the lines of equipotential within it; and it will spread the lines of current flow so that they are concentrated on its borders.

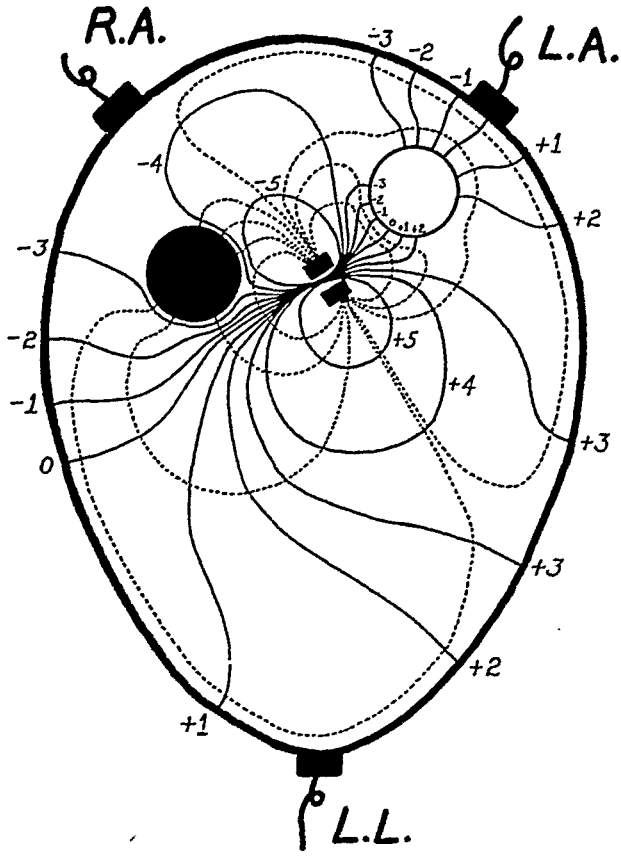

Fig. 5.—This is a diagram representing the electrical field set up in an ovoid nonhomogeneous medium by a bipole placed eccentrically. Conventions as in Fig. 2. Open circle represents a poorer conductor, and the solid circle a better conductor than the rest of the medium. Discussed in text.

In Fig. 5 is shown diagrammatically an example of the alterations in the electrical field which were caused by introducing a poor electrical conductor, like glass (open circle), and a good electrical conductor, like tin (solid circle), in the ovoid homogeneous medium shown in Fig. 3. The presence of such dissimilar conductors, even in a circular field such as shown in Fig. 2, might in itself be sufficient to prevent the accurate application of the Einthoven equilateral triangle concept.

Finally, the source of electricity in the heart is not a simple bipole but a battery with poles of complicated design, a design that changes rapidly

during the heart cycle, especially when the QRS complex is inscribed. The changes in design are a combination of the following: (1) the location and angle of the bipole within the heart, (2) the distance between the two poles, (3) the area of each pole, (4) the angle at which the two poles are placed in relation to each other, and (5) the three-dimensional shape of each pole. In actuality, the shape of each pole is complicated, and it does not lie in one plane. It is because of these factors that Eyster and his coworkers[6] found that when the

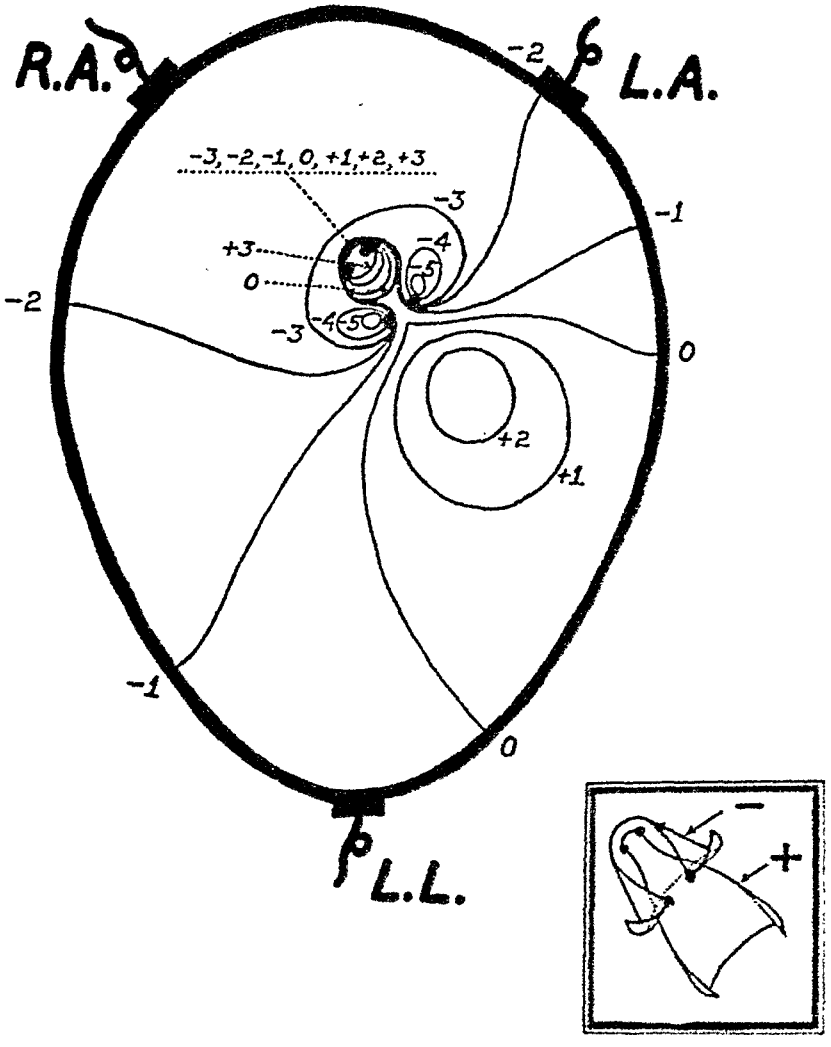

Fig. 6.—This is a diagram representing the electrical field set up in an ovoid homogeneous medium by a bipole of complex design placed eccentrically. The shape of the bipole as viewed from above is shown in the frame below. Also indicated are the points where it cuts the plane of the field mapped out. Conventions as in Fig. 2. The flow lines have been omitted as they are so complicated that they would confuse the illustration. Discussed in text.

heart is placed in a uniform conducting field, the resultant electrical field is better fitted by two independent small bipoles than by one. Actually, however, the battery consists of two poles, a positive and a negative one, of very complex design, and it does not lend itself readily to reduction to simple theoretical bipoles.

In Fig. 6 is shown diagrammatically an example of the alterations in the electrical field which were caused by substituting a bipole of

complicated design for the simple one used in Fig. 3. The marked alteration in the field is readily seen by comparing the two figures.

All of these facts have been known to the majority of workers who have delved deeply into the subject of the electrical field, but there has been a tendency to minimize the significance of the variables we have outlined above with the result that the Einthoven equilateral triangle concept has been accepted by most electrocardiographers as axiomatic or, at least, as a good approximation to an accurate presentation of the conditions. It is the experience of the author that except in the hands of a few who recognize, as did Einthoven himself, the limits of his concept, the concept has confused rather than clarified our understanding of the electrical field. A return to the more general view as outlined in this section should serve to clarify the problem.

THE INFLUENCE ON THE DISTRIBUTION OF THE ELECTRICAL CURRENTS WHICH RESULTS FROM THE VARIABLE ELECTRICAL CONDUCTIVITY OF THE TISSUES IMMEDIATELY IN CONTACT WITH THE HEART

A further factor complicating the general problem outlined in the preceding sections defining the genesis of the heart's electrical currents and the properties of the conducting medium of the body is the important part played by the electrical conductivity of the tissues which serve as the bridges between the heart and the body. Recent work in this laboratory has shown that these bridges in contact with the heart are not uniform in their ability to conduct away the currents which the heart generates. Not all regions of the heart are in contact with good electrical conductors, and some regions are in contact with poor electrical conductors. It is obvious that those that are in contact with good conductors have a decided advantage over other regions of the heart in their influence on the electrical field. The evidence for this viewpoint is summarized below.

We have found that the electrocardiographic contour of experimentally induced premature contractions from fixed points of the heart can be readily altered by shifting the position of the heart (Katz and Ackerman[24]) or by introducing a metal shunt between a region of the heart and some part of the body (Abramson and Katz[26]). We have found also that the electrocardiographic contour of a fixed type of intraventricular block can be altered by a shift in the position of the heart both in the experimental animal (Ackerman and Katz[27]) and in man (Kissin, Ackerman and Katz[28]). It can also be altered in the animal by introducing a metal shunt between a region of the heart and some part of the body (Abramson and Katz[26]). An assay of the electrocardiographic contour of various types of intraventricular block in man has shown further that the contour does not always coincide with the functional evidence of block in the right and left

ventricle (Katz, Landt, and Bohning[29]). The electrocardiographic evidence of myocardial infarct location obtained in man from the standard three leads does not always fit with the location established post mortem (Saphir, Priest, Hamburger, and Katz[30]). Injury with alcohol within a large region of the dog's heart does not give a constant type of electrocardiographic deformity (Korey and Katz[31]). All these facts suggested that the location of defects in the conduction system, of ectopic pacemakers, and of injured regions within the ventricles is only one of the factors which determine their electrocardiographic contour. Another factor which appears to be important is the position and shape of the heart.

Another line of evidence which we have recently uncovered points to the same deduction. We found that surrounding the ventricles by insulating material (a glass oncometer) greatly decreased the magnitude of the ventricular complex in the standard three electrocardiographic leads. Analysis showed that such insulation tends to confine the currents generated to the heart. The introduction of insulators (rubber sheeting) between the heart and various parts of the surrounding structures had an unequal effect, depending on where the insulator was placed (Katz and Korey[32]). The results are summarized in Table I taken from this report. This disparity in action was taken as evidence indicating disparity in the electrical conductivity of the various structures adjacent to the heart. The lungs and the large systemic and pulmonary vessels coming off from the heart were found, in this way, to be poor conductors, while the muscular structures of the chest wall, especially the diaphragm and posterior paravertebral muscle mass, were found to be good conductors.

Experiments of a converse nature were done with good conductors. Thus, when the heart was surrounded by a metallic conductor, a decrease in the electrocardiogram in the standard three leads was obtained (Katz, Sigman, Gutman and Ocko[14]). This result is attributed to the fact that the good conductor shunts back the currents generated and so tends to prevent the currents from passing to the rest of the body. The effect of insulators and excellent conductors in electrical fields is well known to physicists. Alterations in the contour of the standard three-lead electrocardiograms were also obtained by a similar shunting action when warm isotonic saline was placed in the dog's chest.[14]

Furthermore, evidence was secured that the introduction of good electrical conductors adjacent to the heart altered the electrical records obtained when leading directly from the heart or when the leads were a combination of one electrode on the heart and another at a distance from it.[14] The action of these introduced conductors was shown to depend on (a) their offering a by-pass for the currents generated by the heart, thereby decreasing the amount passing

through the galvanometer circuit, (b) their altering the path taken by currents to distant points, and (c) their altering the relative contribution of the various regions of the heart to the recorded electrical curves. These experiments with introduced good electrical conductors show how the electrocardiogram can be modified by altering the contacts with the body and support the general concept that the natural contacts play an important rôle.

TABLE I
(TAKEN FROM KATZ & KOREY[32])

THE EFFECT OF INSULATING THE HEART ON THE SUM OF THE MAJOR DEFLECTIONS OF QRS IN THE THREE STANDARD LEADS

DOG NUMBER	(A) MASSIVE INSULATION OF HEART EXCEPT FOR SYSTEMIC AND PULMONARY VESSELS	(B) INSULATION OF HEART FROM ANTERIOR CHEST WALL	(C) INSULATION OF HEART FROM POSTERIOR CHEST WALL	(D) INSULATION OF HEART FROM DIAPHRAGM	(E) INSULATION OF HEART FROM RIGHT LATERAL CHEST WALL	(F) INSULATION OF HEART FROM LEFT LATERAL CHEST WALL	(G) INSULATION OF LUNGS FROM HEART AND ENTIRE CHEST WALL EXCEPT FOR PULMONARY VESSELS BETWEEN FORMER TWO	(H) INSULATION OF HEART FROM SYSTEMIC VESSELS
Dog on back								
1	++++		++++					±
2	++++	±	+++	++				
3	++++		+++	++			±	±
4			++++				±	±
5	++++	±	+++	±			±	
6	++++		++++	±			+	±
7	+++	±	++	±			±	
8	++++		+++				±	
Dog on abdomen								
9	++++	+++	±					
10	+++	++	±	±				
Dog on left side								
11	+++	±	±	++		++		
12	++++	±	±	+		++		
Dog on right side								
13	++++	±	+++	++	±			
14	+++	±	+++	+++	±			

± is equivalent to decrease of from 0 to 15 per cent.
+ is equivalent to decrease of from 15 to 25 per cent.
++ is equivalent to decrease of from 25 to 50 per cent.
+++ is equivalent to decrease of from 50 to 75 per cent.
++++ is equivalent to decrease of from 75 to 100 per cent.
NOTE: The sums of these percentages, because of the roughness of the approximation, of course do not give 100 per cent.

Evidence of a similar sort was obtained in another way. Katz, Gutman, and Ocko[33] demonstrated that certain regions of the heart may gain a decided advantage over the rest merely because they are in contact with a good electrical conductor, provided they are nearer to one of the recording electrodes. This was shown by connecting various regions of the heart with various parts of the body by means of a good electrical nonpolarizable shunt. The region of the heart so

shunted sets up its own electrical field, which summates with that set up by the heart through its natural contacts. The alterations obtained were of two sorts (or intermediate or mixed forms): (a) diphasic additions when the region in the heart under the shunt electrode was not injured and (b) monophasic additions when the region under the shunt electrode was injured. The direction and magnitude of the electrical addition were found to depend on the resistance of the shunt circuit and the distance between the point of the shunt on the body and the recording electrodes. The two types of additions are diagrammatically represented in Fig. 7, where the two directions they may take are shown by curves *A* and *B* and the variation in magnitude by the arbitrary scales at the left.

Following up the view that there is an electrical field, we have explored, recently, the lines of equipotential inscribed on the surface

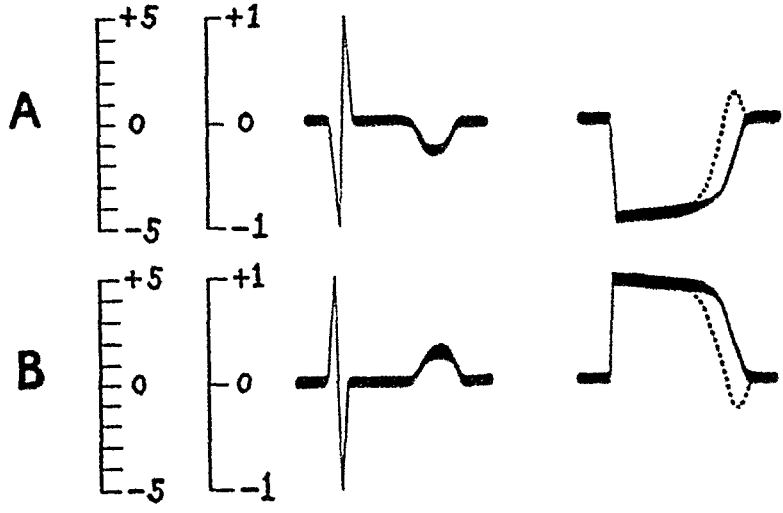

Fig. 7.—This is a diagram (previously published[33]) showing two types of additions which can be obtained when a region of the heart is shunted to the body by a good electrical conductor. On the left are the diphasic, and on the right are the monophasic types of additions. *A* and *B* represent the two directions these additions may take. The arbitrary scales on the left represent the various magnitudes the additions may take. Discussed in text.

of the body (Robinow, Katz, and Bohning[34]). We have so far, because of its relative simplicity, confined ourselves to the part of the heart cycle during which the T-wave is inscribed. The potential of the peak of the T-wave at various points on the body was noted, the potential being determined as a relative value compared to that of the leg. While the potential at the leg is not zero and the peak of the T-wave is not homologous in the various spots, the errors introduced in these ways are of no real significance for the use we made of the data. We found that the lines of equipotential were more concentrated over the precordium than elsewhere and were irregular in shape. We have paid particular attention to the line having a potential equal to that in the leg; that is, the places on the body on which no T-wave appeared when they were connected through a galvanometer

to the leg. This line we have called the line of "leg potential." This line was found to vary in its position under different clinical conditions. In Fig. 8, for example, is shown the complicated course taken by the line of "leg potential" during the peak of the T-wave in a fifty-year-old subject with congenital heart disease. It is difficult to see how the simple concept of the Einthoven triangle could explain the results obtained, whereas it fits into the electrical field concept deduced from our work.

The importance of good electrical contact in giving particular regions of the heart an advantage was shown by a different type of experiment (Katz, Gutman, and Ocko[33]). Figure 9 illustrates the results. In this dog the heart had been separated from the posterior paravertebral muscle mass so as to permit the application of a boot

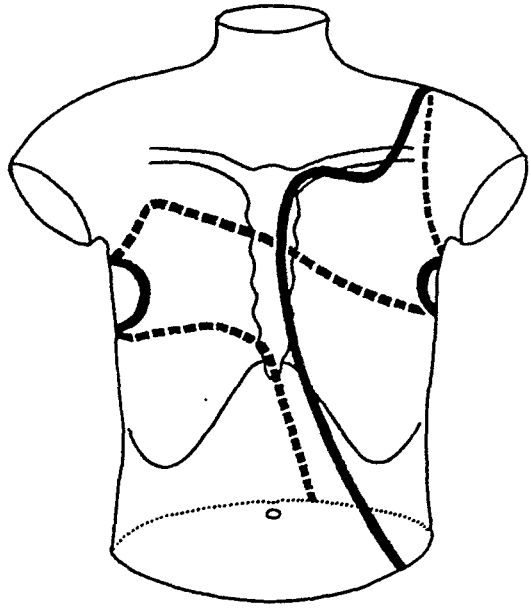

Fig. 8.—This is a diagram showing the complicated course taken by the line of "leg potential" during the inscription of the peak of the T-wave in a fifty-year-old subject with congenital heart disease. The line of "leg potential" represents the points on the surface of the torso in which no T-wave would be registered when the precordial electrode located there is connected with a second electrode on the left leg. This line separates regions which with this lead combination give positive and negative T-waves. (Modified from figure already published.[24]) Discussed in text.

electrode on the posterior surface. This boot had produced injury beneath it. It had been removed, however, when segment *A* was taken. Segment *A* shows the usual type of electrocardiogram obtained with the heart in this position. When, however, the heart was placed back in contact with the posterior paravertebral muscle mass (segment *B*), a marked monophasic addition was obtained in Leads II and III. This monophasic addition disappeared when the heart was returned to its preexisting position (segment *C*). It is obvious that the injury had persisted after the boot was removed but did not affect the electrocardiogram because it was not advantageously situated. By placing this

injured area in contact with a good electrical conductor, the posterior paravertebral muscle mass, it gained sufficient advantage to dominate the curve. The change in contact of the heart in its two positions is illustrated diagrammatically in Fig. 10. This experiment shows that regions of the heart at a disadvantage in contributing to the electrical field can gain a definite advantage by being brought in contact with a good conductor. It demonstrates graphically what is accomplished when precordial leads are employed. Here, however, instead of mov-



Fig. 9.—Series of electrocardiograms showing the importance of good electrical contact of an injured area of the heart in bringing out the characteristic contour. The injured area in this open-chested anesthetized dog was located posteriorly on the ventricles. Segments *A* and *C* show the standard three leads when the apex of the heart was moved up and the heart separated from the posterior paravertebral muscles. Segment *B* shows the standard three leads when the heart was brought in contact with this muscle mass. (Previously published.[33]) Discussed in text.



Fig. 10.—This is a diagram of a sagittal section of the open-chested dog showing the two positions of the heart from which the records in Fig. 9 were obtained; dotted heart outline when segments *A* and *C* were recorded, solid heart outline when segment *B* was recorded. The injured area is shaded. The good electrical conductors are shown on the heart as shaded areas. Discussed in text.

ing the heart, the recording electrode is brought closer to the "silent" areas. It is a case of "Mohammed going to the mountain" instead of the "mountain going to Mohammed."

In view of the evidence presented above, it is apparent that changes in the electrocardiogram can result from variations in the relative position of the electrical conductors in contact with the heart. This

may be caused either by alterations in the position or shape of the conductors or by changes in the position or shape of the heart itself. As a result, regions of the heart which normally exert a great influence on the electrocardiogram may become "silent," while other regions previously "silent" may now exert a prominent effect.

Such changes in the contacts between heart and body occur during the heart cycle. It follows that the regions of the heart which play the dominant rôle in giving rise to the T-wave may be different from those giving rise to the QRS complex.

Such changes in the contacts between heart and body occur also during respiration and thus account for the variations in the electrocardiographic contour seen during the respiratory cycle. Displacements of the heart alter the contacts between heart and body, as do hypertrophy and dilatation of the various heart chambers. The electrical evidence of axis deviation and preponderant hypertrophy may thus turn out to be the result of these changes in contact rather than



Fig. 11.—This is a diagram of a cross-section of the human body at about the level of the middle of the ventricles to represent the location of the various types of electrical conductors in contact with the heart which serve to bridge the gap between heart and body. The good electrical conductors are shaded, and the poorer ones are left blank. The blood-filled cardiac cavities are stippled. The vertical line shows the plane in which Fig. 12 was drawn. Discussed in text.

of some hypothetical resultant vector dependent on the spread of the impulse within the heart. The occurrence clinically of tremendous axis deviation in the absence of intraventricular conduction disturbances would lead to the inference that the axis deviation in intraventricular block might be due, in part at least, to a similar cause. It is, therefore, unjustifiable to ascribe the entire disturbance to alteration in the spread of the impulse, and ignore the influence which position and shape changes in the heart have in modifying the contacts between the heart and the body. A similar argument holds also in localizing regions of infarction. In other words, account must be taken not only of the intrinsic changes within the heart, but also of the contacts between the heart and the body. Our results, given above, point clearly to this conclusion.

Edema in the tissues surrounding the heart, and solid tumor masses,

by altering the electrical nature of the contacts between heart and body can modify the electrocardiogram. Infarcts of the lung, when adjacent to the pericardium, should also have a similar effect. Evidence of this sort, however, is still incomplete, and further work along these lines is indicated.

To recapitulate, our results indicate that the electrocardiogram is not a summation of events occurring in all parts of the heart but is primarily a summation of events occurring in those regions which are in contact with the better electrical conductors. Other regions play a relatively lesser rôle.

From the evidence elucidated, we have attempted in Figs. 11 and 12 to indicate the relations of the better and poorer conductors in

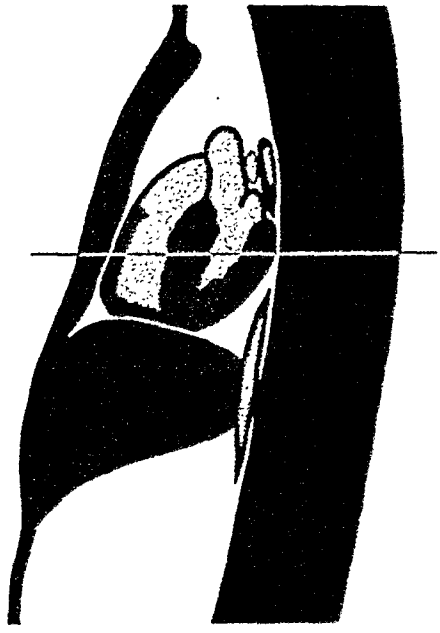

Fig. 12.—This is a diagram of a sagittal section of the human body to represent the location of the various types of electrical conductors in contact with the heart which serve to bridge the gap between the heart and body. Conventions as in Fig. 11. The horizontal line shows the plane in which Fig. 11 was drawn. Discussed in text.

contact with the heart of man. Figure 11 is a diagram of a cross section of the human body at about the level of the middle of the ventricles, and Fig. 12 is a diagram of a sagittal section of the human body. The heart muscle, the liver, and the chest walls are shown as solid black areas to indicate that they are good electrical conductors. The blood-filled cavities of the heart are stippled, and the lungs and alveolar mediastinal spaces are left blank to indicate that they are poor electrical conductors. According to the experiments with models outlined above, the electric currents will flow primarily through the solid areas. The flow lines will be most concentrated anteriorly where the good conductors are thinner than elsewhere in the chest; this will also be true of the lines of equipotential.* The potential

*The reason for this is that when dealing with equally good conductors in parallel separated by a poorer conductor, the thinner one will have the more concentrated current flow.

gradient in this region will also be steepest. In the lungs the current flow will be the least and the potential gradient the most gradual. The conditions as to current flow and potential gradient will be intermediate posteriorly and caudad.

According to the concept presented, the regions of the heart which will have the greatest effect on the distant electrical field and hence on the electrocardiogram will be those in contact with the diaphragm (the caudad regions of right auricle, right ventricle and left ventricle) and those in contact with the posterior paravertebral muscle mass (the base of left ventricle and the posterior aspect of left auricle). The anterior surfaces of the right auricle, right ventricle and left ventricle in contact with the anterior chest wall over the precordium will have a less important influence, while the rest of the heart shielded from the body by the lungs will have an unimportant influence, especially in the upper lateral parts of the heart where the lung is so thick that, practically, it completely shields these parts of the heart from the chest walls. The difference obtained in the experiments of Katz and Korey[32] between the electrical conductivity of the lungs and that of the muscles is so marked—being of the order of 1 to 10 in the open-chested animal—that the differences outlined above cannot be dismissed as of little actual significance. This great difference in conductivity, we believe, is primarily responsible for the "silent" regions of the heart.

SUMMARY

The electrocardiogram as shown by the evidence presented above, is a record of events in favored rather than in all regions of the heart. It registers the play of electromotive forces set up from moment to moment in these favored spots rather than the balance of the electromotive forces set up in the entire heart. It gives the order of invasion and retreat in these favored regions and depicts disturbances in these processes, primarily as they affect these favored regions. Similarly, it reveals injury currents affecting these particular regions but misses injury currents in other regions not so favorably situated. The precordial leads are from this viewpoint a method of bringing out into the open lesions in regions of the heart which are not favorably situated for notice by the ordinary distant leads.

REFERENCES

1. Lewis, T.: Mechanism and Graphic Registration of the Heart Beat, ed. 3, London, 1925, Shaw & Sons.
2. Craib, W. H.: The Electrocardiogram, Medical Research Council, Special Report Series No. 147, 1930.
3. Katz, L. N.: Physiol. Rev. 8: 447, 1928; J. A. M. A. 97: 1364, 1931.

4. Wilson, F. N., Macleod, A. G., and Barker, P. S.: Distribution of the Currents of Action and of Injury Displayed by Heart Muscle and Other Excitable Tissues, Ann Arbor, 1933, University of Michigan Press.
5. Groedel, F. M.: Extremitäten-, Thorax- und Partial-Elektrokardiogramm des Menschen, Dresden and Leipzig, 1934, T. Steinkopff.
6. Eyster, J. A. E., Maresh, F., and Krasno, M. R.: Am. J. Physiol. 106: 574, 1933.
7. Gilson, A. S., and Bishop, G. H.: Am. J. Physiol. 109: 40, 1934.
8. Jochim, K., Katz, L. N., and Mayne, W.: Am. J. Physiol. 111: 177, 1935.
9. Katz, L. N., Jochim, K., and Abramson, D. I.: Unpublished.
10. Wiggers, H. C.: Proc. Soc. Exper. Biol. & Med. 34: 337, 1936.
11. Lewis, T., and Rothschild, M. A.: Phil. Trans. Royal Soc., B 206: 181, 1915.
12. Robb, J. S.: Am. J. Physiol. 116: 129, 130, 1936.
13. Abramson, D. I., and Jochim, K.: Unpublished.
14. Katz, L. N., Sigman, E., Gutman, I., and Ocko, F.: Am. J. Physiol. 116: 343, 1936.
15. Buchbinder, W. C., and Katz, L. N.: Am. J. M. Sc. 187: 785, 1934.
16. Jochim, K., and Katz, L. N.: Unpublished.
17. Wilson, F. N.: Am. Heart J. 5: 599, 1930.
18. Zeisler, E. B.: Proc. Soc. Exper. Biol. & Med. 28: 12, 1930.
19. Zeisler, E. B., and Katz, L. N.: Am. Heart J. 8: 676, 1933.
20. Koch-Momm, E.: Ztschr. f. Biol. 93: 241, 1933.
21. Storti, E.: Ztschr. f. Kreislauff. 27: 836, 1935.
22. Katz, L. N., Saphir, O., and Strauss, H.: Am. Heart J. 10: 542, 1935.
23. Robinow, M.: Am. Heart J. 13: 104, 1937.
24. Katz, L. N., and Ackerman, W.: J. Clin. Investigation 11: 1221, 1932.
25. Katz, L. N., and Robinow, M.: Am. J. M. Sc. 192: 556, 1936.
26. Abramson, D. I., and Katz, L. N.: Unpublished.
27. Ackerman, W., and Katz, L. N.: Am. Heart J. 8: 490, 1933.
28. Kissin, M., Ackerman, W., and Katz, L. N.: Am. J. M. Sc. 186: 721, 1933.
29. Katz, L. N., Landt, H., and Bohning, A.: Am. Heart J. 10: 681, 1935.
30. Saphir, O., Priest, W., Hamburger, W. W., and Katz, L. N.: Am. Heart J. 10: 567, 1935.
31. Korey, H., and Katz, L. N.: Am. J. M. Sc. 188: 387, 1934.
32. Katz, L. N., and Korey, H.: Am. J. Physiol. 111: 83, 1935.
33. Katz, L. N., Gutman, I., and Ocko, F.: Am. J. Physiol. 116: 302, 1936.
34. Robinow, M., Katz, L. N., and Bohning, A.: Am. Heart J. 12: 88, 1936.

HEART DISEASE IN CHILDREN*

A. Rheumatic Group

I. Certain Aspects of the Age at Onset and of Recurrences in 488 Cases of Juvenile Rheumatism Ushered in by Major Clinical Manifestations

Irving R. Roth, M.D., Claire Lingg, M.A., and
Alice Whittemore, A.B.
New York, N. Y.

THIS report is based on a study of 488 rheumatic children. It deals with the clinical aspects of the *age at onset* and of *recurrences* in juvenile rheumatism. The children were selected exclusively on the basis *of major rheumatic affections*† *as the first manifestations of the disease.* This method of selection makes easy the identification of the disease and utilizes well-defined initial episodes as reliable points of reference in timing recurrent affections. The cases constitute a subgroup of 750 cases of rheumatic fever observed in the Children's Cardiac Clinic of Mount Sinai Hospital, of which the population followed in the course of fifteen years was 1,107. Since all these cases are intended to serve as material for future studies related more or less to the subject of this paper, the original group is classified and presented in Table I. It is divided into three parts: A, rheumatic group; B, congenital cardiacs; and C, cardiac suspects.

The rheumatic group consisting of 750 patients has been further subdivided (Table I). The members of subdivisions 1, 2, and 3 have in common a history of at least one acute major *rheumatic* episode.‡ Patients with a history of fleeting muscle or joint pains only, though heart disease was present, were not included.

---

*From the Children's Cardiac Clinic of the Mount Sinai Hospital and the Heart Committee of the New York Tuberculosis and Health Association.

This paper is Number X in the series "Statistical Studies Bearing on Problems in the Classification of Heart Diseases."

†The term "rheumatic affection" is employed instead of "rheumatic infection" not because of doubt as to the infectious nature of acute rheumatism but to indicate reference to clinical forms of the disease.

‡By major episodes are meant well-defined clinical forms of juvenile rheumatism such as acute polyarthritis, carditis, or chorea.

Cases of clinical *polyarthritis* are those which exhibit migrating joint pains requiring rest in bed. Ambulatory cases, with mild muscle and joint pains or "growing" pains, were not included in this group.

The diagnosis *carditis* was made preferably during stay in a hospital. It was made only when it was recognized as an acute clinical manifestation but was not assumed to be present at the time of discovery of chronic valvular disease, since the cardiac lesion may have developed insidiously.

To accept the diagnosis of *chorea* on history is not difficult since a description of this disease is generally unmistakable. Diagnosis without sufficient description is unreliable. Such cases were excluded.

Subdivision 4 we designate as *presumably rheumatic* because, though a definite major rheumatic episode was not traced, the presence of mitral stenosis is taken as evidence of rheumatic affection.

The designation *probably rheumatic* in subdivision 5, implies doubt. It is employed to indicate that a well-defined clinical form of juvenile rheumatism has not been traced. All cases in this subdivision exhibit well-defined cardiac valvular defects such as mitral insufficiency, aortic insufficiency, or both. We find it desirable to designate these cases as probably rheumatic in order to separate cases in which there is a clear rheumatic background from those in which it is merely inferred.

The data were gathered in several ways. 1. Patients who were in continuous attendance at the Children's Cardiac Clinic, or who had been transferred to our Adult Cardiac Clinic, afforded the most de-

TABLE I

CLASSIFICATION OF RECORDS

GROUPS	NUMBER	PER CENT	M. & J. PAINS* PRECEDING MAJOR MANIFESTATION	VALVULAR LESION PRECEDING MAJOR MANIFESTATION	NO RECORD OF AGE AT INITIAL MANIFESTATION	MAJOR MANIFESTATION, THE FIRST SIGN OF RHEUMATIC INFECTION, AND AGE AT ITS OCCURRENCE KNOWN
1. A—Rheumatic (C V D)	523	47.2	50	21	21	431
2. Class E and F	56	5.1	5	0	0	51
3. Class F	6	0.5	0	0	0	6
Total (1, 2, and 3)	585	52.8	55	21	21	488
4. Presumbly rheumatic	63	5.7				
Total (1, 2, 3, and 4)	648	58.5				
5. Probably rheumatic	102	9.2				
Total (1, 2, 3, 4, and 5)	750	67.7				
6. B—Congenital H. D.	79	7.1				
7. C—Cardiac suspects (Class E)	278	25.1				
Grand Total	1107	99.9				

Legend for rheumatic subgroups, 1, 2, 3, 4, 5.

1, History of one or more attacks of a major rheumatic manifestation; well-defined cardiac valvular defects.

2, History of one or more attacks of a major rheumatic manifestation; physical signs abnormal, but not descriptive of organic heart disease.

3, History of one or more attacks of a major rheumatic manifestation; no physical signs to suggest a valvular defect.

4, No definite history of a major rheumatic manifestation; well-defined valvular defects, *including mitral stenosis.*

5, No definite history of a major rheumatic manifestation; well-defined valvular defects, *not including mitral stenosis.*

*In 20 of these valvular lesion, also, preceded major manifestation.
M. & J., muscle and joint.

pendable records. 2. A social worker* attempted to bring back to the clinic, at least once, those who were no longer in actual attendance in order to obtain interval histories and examinations. 3. Of patients treated during the interval in other hospitals or convalescent homes, information was gathered from interviews with the family or family physician, a perusal of the hospital records, autopsy reports, or death certificates. In this group we included cases only when the original records contained dependable information.

Distribution According to Sex.—There were 240 (49.2 per cent) males and 248 (50.8 per cent) females. This distribution is similar to that in the entire rheumatic group as well as in that of the basic group of

TABLE II

AGE AT BEGINNING OF OBSERVATION

AGE	NO.	PER CENT	CUMULATIVE PER CENT
2	1	0.2	0.2
3	8	1.6	1.8
4	10	2.0	3.8
5	17	3.5	7.3
6	24	4.9	12.2
7	41	8.4	20.6
8	46	9.4	30.0
9	52	10.7	40.7
10	55	11.3	52.0
11	53	10.9	62.9
12	65	13.3	76.2
13	47	9.7	85.9
14	42	8.6	94.5
15	19	3.9	98.4
16	6	1.2	99.6
17	2	0.4	100.0
Total	488	100.0	
Mean 10.1 years			

1,107 cases. In the whole rheumatic group there were 344 (45.9 per cent) males and 406 (54.1 per cent) females. In the basic group there were 532 (48.1 per cent) males and 575 (51.9 per cent) females.

Age at Beginning of Observation.—In studying juvenile rheumatic heart disease the group selected should be representative of childhood. Initial observations should be begun before puberty. Observations first undertaken at a later age preclude the probability of obtaining dependable histories. Statements made later are often vague with reference even to major manifestations. Earlier histories are likely to contain records of milder flares, since the initial affection may date back only two or three years.

*A full-time social worker was assigned for about two years to locate patients who could not be reached by the usual means of communication. Contact was often made through such indirect channels as interviews with former neighbors and relatives; through records of other hospitals and clinics; or through other social service agencies. We are indebted to Mrs. Henry F. Glazer and to the Social Service Auxiliary of Mount Sinai Hospital for the social worker who was assigned to assist in this study. Statisticians and clerical aid were provided by the Research Committee of the New York Heart Association.

The age at first observation was in most cases within the period of childhood (Table II). The mean age was ten years. Twenty-five per cent were first examined before 7.5 years of age, and an additional 50 per cent between 7½ and twelve years of age. Over 94 per cent were under observation on attaining fourteen years of age.

Interval Between Initial Rheumatic Manifestation and Beginning of Period of Observation.—The patients came under observation at varying intervals after their initial major rheumatic affection (Fig. 1). Most of them, however, were first observed either during the same year as, or a few years after, the initial episode. In a few isolated

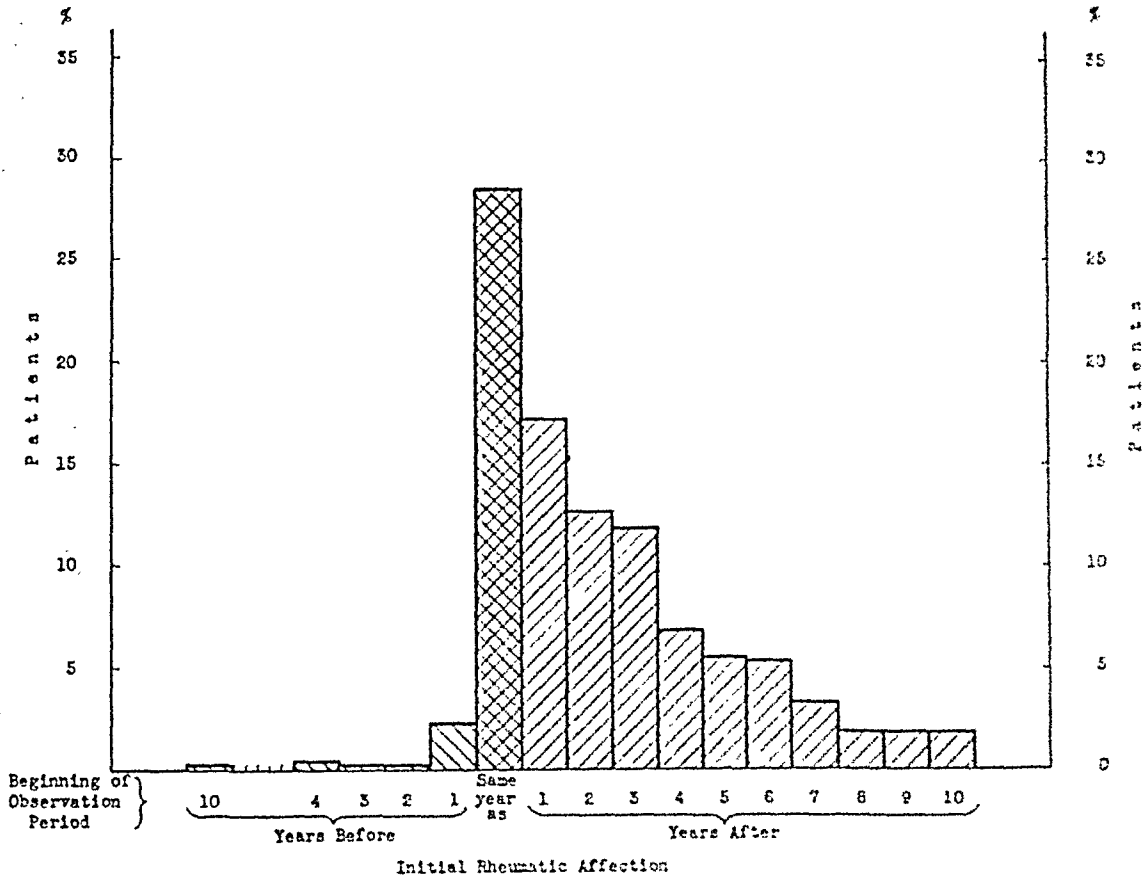

Fig. 1.—Interval between initial rheumatic manifestation and beginning of period of observation.

cases observation began from one to ten years before the first major rheumatic affection, but this number was negligibly small (11, or 3.3 per cent). A far greater number (28.5 per cent) was observed during the year of initial affection than in any other year. Next in frequency were those who came under observation one, two, and three years later. The mean interval between the year of initial affection and the year of first observation was two and three-tenths years.

Duration of Observation Since Initial Rheumatic Manifestation.—The interval between the initial affection and the end of the period of observation in this selected group averaged eight years (Fig. 2). Since these children came under active clinic care about two years

after their first affection (see preceding section), the period during which the course of the disease has been actually observed is less than six years. However, since the disease was ushered in by a major rheumatic affection in all these children, the majority had been attended either in hospitals or by private physicians. The records give satisfactory information, therefore, of the length of the period between initial episode and first observation. Eight years, consequently, may be considered as the mean duration of observation.

Initial Major Rheumatic Affections, Grouped According to Type.—Polyarthritis was the most common type of initial affection (Fig. 3). It was present in 66 per cent (322) of cases. It was the only apparent affection in 45 per cent (220). Associated with carditis, it was present in 16 per cent (79); and with chorea, in 4 per cent (18).

Carditis was present in 32 per cent (158) of cases. It appeared alone in 14 per cent (68). The remaining cases were associated mainly with

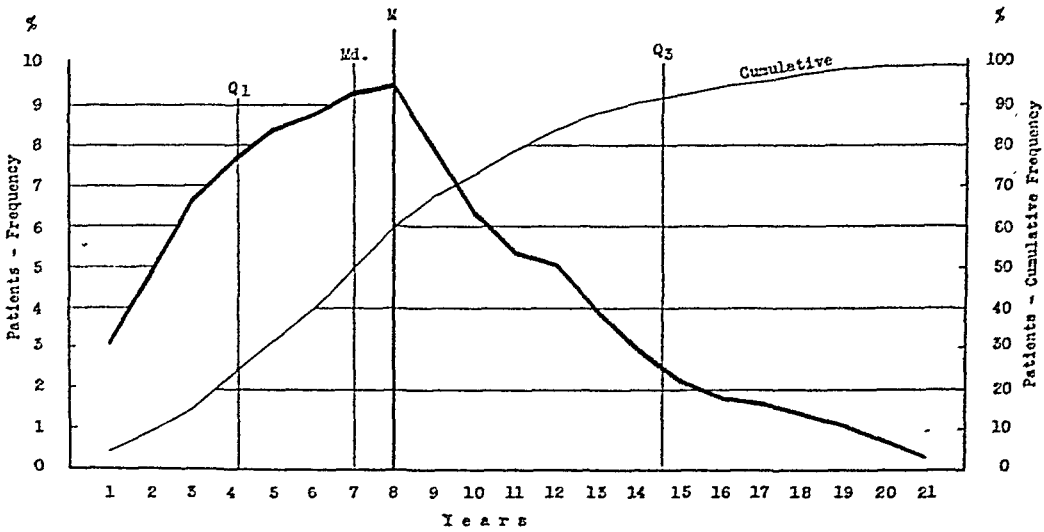

Fig. 2.—Duration of observation since initial rheumatic affection.

polyarthritis, that is to say, in 16 per cent (79), as already stated. Carditis was associated with chorea in only 1 per cent (6).

Chorea was present in 25 per cent (121). It occurred alone in 19 per cent (92). Its association with polyarthritis and carditis has already been mentioned.

A combination of the three major rheumatic affections as an initial manifestation was rare. It occurred in only 1 per cent (5).

Types of Initial Affections by Sex.—When the sexes are considered separately, polyarthritis was the most common initial manifestation of the disease in girls as well as boys. However, one and one-half times as many girls as boys exhibited chorea as the first evidence of rheumatic affection (Fig. 4). A concurrence of chorea and carditis was observed somewhat more often among girls than boys. The number of these cases, however, is far too small to permit of any generalization.

AGE AT ONSET OF MAJOR RHEUMATIC AFFECTIONS

The age at onset of juvenile rheumatism has been studied over many years, especially in England and the United States. We have found

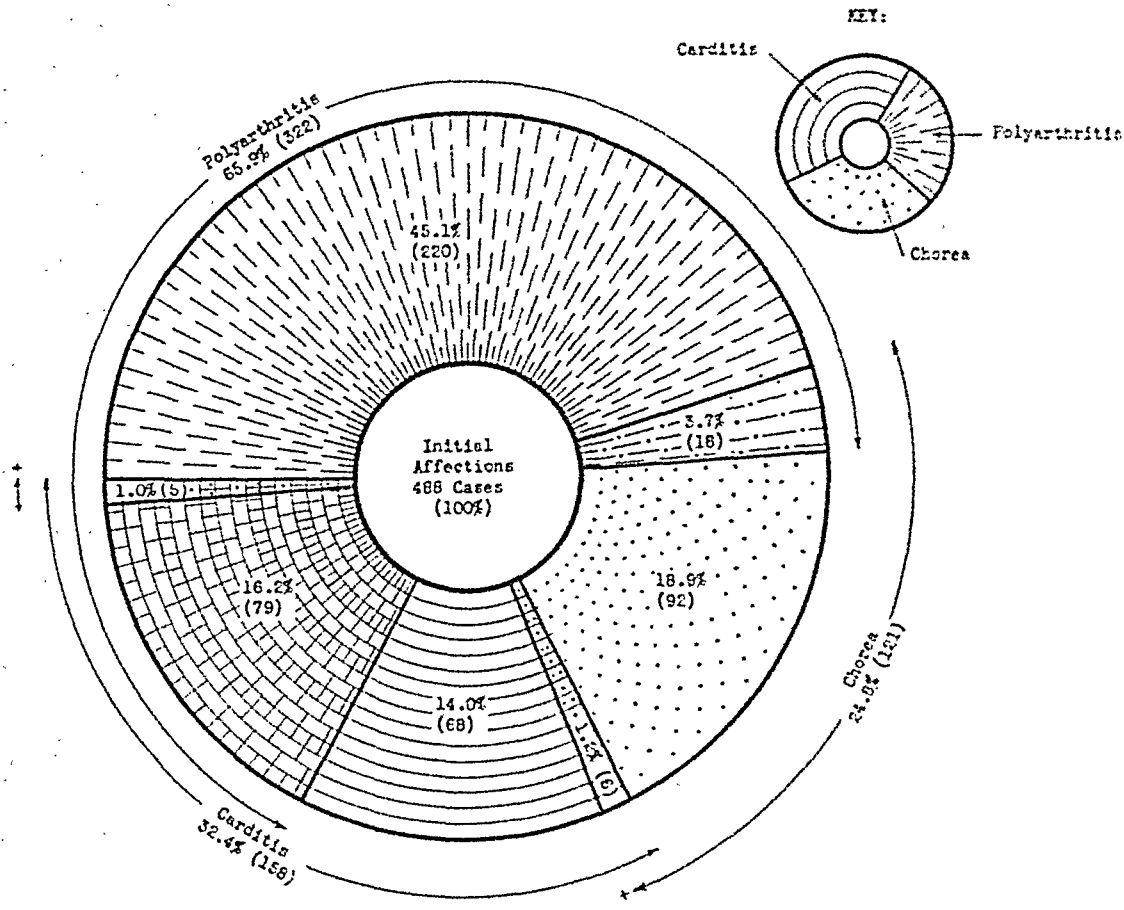

Fig. 3.—The number of cases in each initial major rheumatic affection according to type.

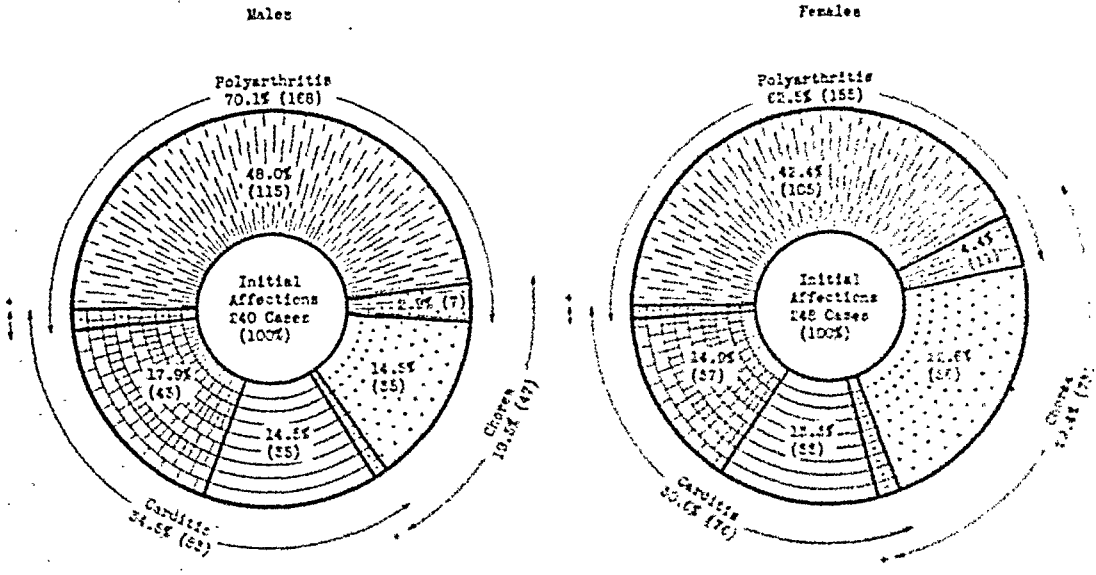

Fig. 4.—The number of cases in each type of initial affection by sex.

no reports in the literature dealing with groups of patients in whom the initial manifestations of the disease consisted exclusively of major rheumatic episodes, which would make them comparable, however, to the data presented in this paper.

In the literature the age at onset is generally regarded in a broad sense as representing an age period. Most writers refer to the span five to fifteen years as the period of greatest incidence of first manifestations of rheumatism.[1, 2, 3, 4, 5] Some narrow the age group down to the years seven to twelve,[6] while still others limit it to the age period ten to twelve years.[7]

The *mean* age at onset, as given in the literature, ranges from about seven years[8, 9, 10] to as high as nine years.[3]

The *mode* or year of greatest incidence varies similarly in different reports. The most common estimate is the seventh or the eighth year.[2, 8, 10, 11, 12] Some have found it as low as the sixth or the seventh year.[13] In contrast to these, one report, based on 1,000 cases compiled over some thirty years, concludes that the highest incidence of "rheumatic heart disease" is "around the tenth year." This author[14] states, in addition, that the incidence of acute rheumatism is relatively infrequent before five years of age, although it is his impression that the disease is more frequent than is generally recognized. He adds a review of 100 cases of acute juvenile rheumatism which he observed. Among these he found that 13 per cent had their first attack between the ages of three and five years.

The discrepancy in the literature is due to several factors. Not only the size of the groups but also the age limits of the groups vary widely with different reports. Some groups consist of only 50 cases;[4] others are as large as 1,000 cases.[14] The age groups in some reports are limited to children below ten years of age,[10, 11] while in others the study includes not only children and young adults but also the aged.[5, 14] Perhaps even more important than these is the utter lack of uniformity in criteria in the literature as to what constitutes acute rheumatism. Equally difficult is the task of tracing the initial episode when the disease takes an ill-defined form. Some authors compile their rheumatic series on the basis of "rheumatic pains,"[11] which include "growing pains" as well as "pain and swelling of the larger joints," and "rheumatic carditis" which turns out to be valvular lesions without any "other manifestation of rheumatism." Others[14] deal with the incidence of "rheumatic heart disease" only. Still other authors,[5] by including cardiac involvement as evidence of active rheumatism, base their diagnosis on such findings, at times, as tachycardia, cardiac enlargement, extrasystoles, or murmurs. With the assumption that in isolated cases such findings are of diagnostic importance in that they help to round out a clinical picture of acute carditis, it must still be admitted that there is no uniform agreement among different investigators as to the actual significance of these findings.

Finally, there still remains the problem of a careful compilation of statistical data and the interpretation of graphic records. In an attempt to arrive at a figure representing the average age in childhood

at which rheumatic affection begins, two points must be kept in mind: first, the size of the sample, and second, its constitution. Obviously, in a relatively small sample, particularly such as is usual in the experience of a single observer, even after many years of experience, the *mean* (arithmetic average) is affected by a few extreme cases at either end of the scale. Before placing too great dependence on the mean, the whole curve must, therefore, be taken into consideration, and the *mode* (the age at which the greatest incidence occurs) should be considered as possibly more typically descriptive of the series. Furthermore, the samples must be homogeneous to such a degree as will make the comparisons valid. The age limits included in any

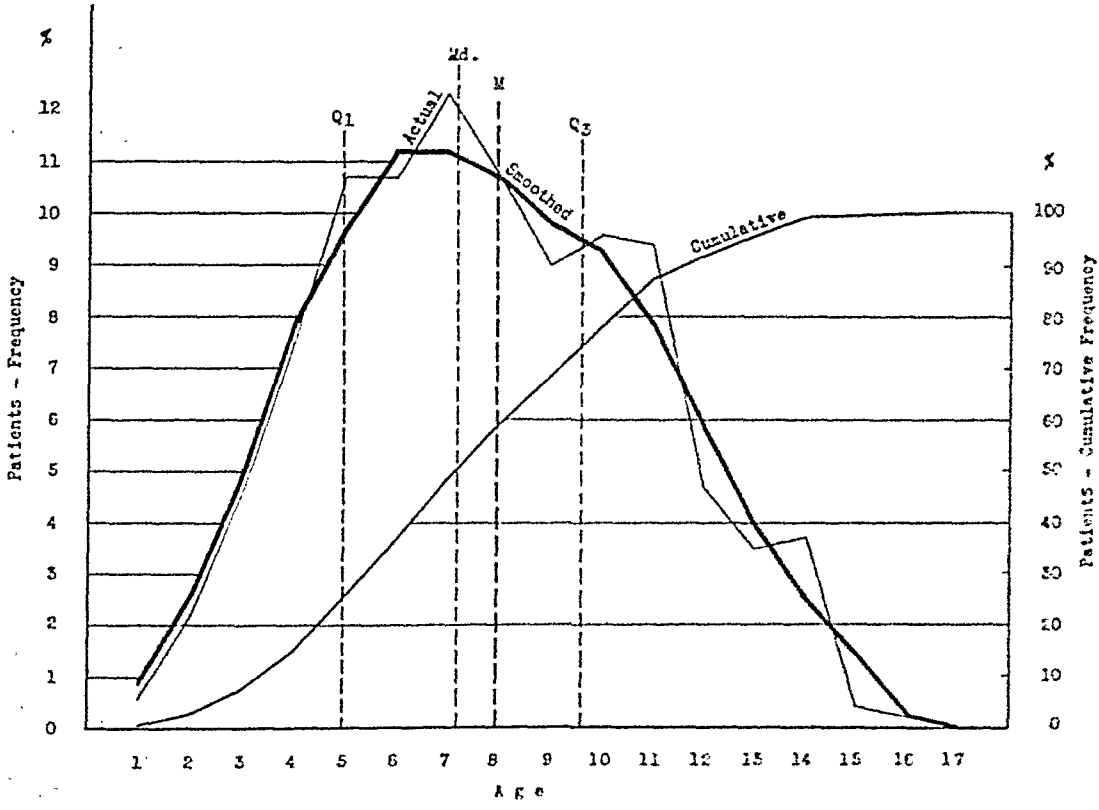

Fig. 5.—Age at onset of the major rheumatic affections.

given series of cases naturally affect the mode as well as the mean. A sample that is drawn from a clinic in which the upper age limit for admission is twelve years will, for instance, present a different curve from one in which the upper age limit is sixteen years. An average, to be useful, must be typical of actual conditions. These are factors that must be kept in mind when comparing the observations reported by different authors.

Age at Onset in the Group Selected for This Study.—The mean age at first manifestation of juvenile rheumatism in our group of 488 children in whom the disease was ushered in by a major manifestation was eight years, and the mode, or highest incidence, was at seven years (Fig. 5). The smoothed curve shows the height of incidence as early as the sixth year. This height is practically maintained up

to the age of eight years, after which the curve slopes gradually. It is interesting to note that 26 per cent of this group experienced a first rheumatic affection within the first five years; 36 per cent within the first six years; and that as many as 78 per cent already presented a first affection by the end of the tenth year. In over 90 per cent the age at onset was less than twelve years. In other words, in one-fourth of the children the initial major rheumatic affections appeared within the preschool age, and in most of the remaining three-fourths it occurred before the thirteenth year.

It is possible that our group is distinctive only in that it represents cases in which the disease had a stormy onset, while the groups studied by other writers represent those cases also in which the disease had

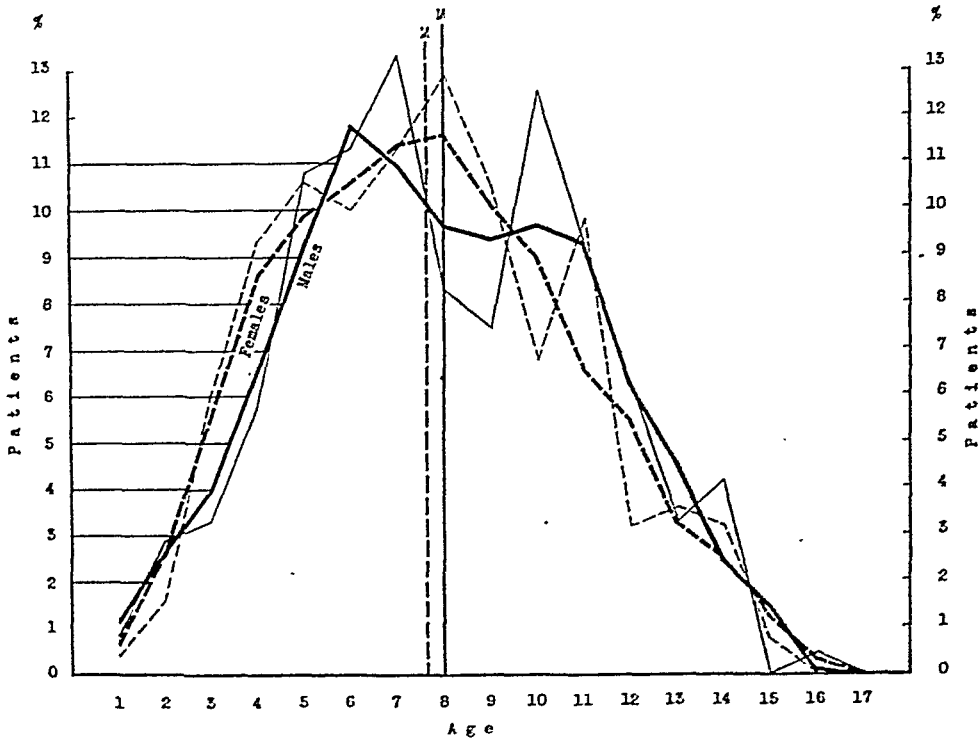

Fig. 6.—Age at onset of the major rheumatic affections by sex.

an insidious onset. The agreement in the age incidence of first affections between our group and some of those reported suggests that, generally speaking, the so-called rheumatic pain may very well be the first manifestation of rheumatism in childhood.

A further analysis brings out several interesting features of the disease, not quite apparent in a general survey of the subject. We find, for instance, that the mean age at onset is very close for the two sexes (Fig. 6). It is slightly earlier for girls than boys. But the mode or highest incidence of initial rheumatic affections is at a definitely earlier age in the case of boys. First affections among boys occurred in greater numbers at about six years than at any other age, while in girls, the highest incidence was reached during the eighth year.

Age at Onset for Patients Grouped According to the Type of the Initial Rheumatic Affection.—Far more revealing is the analysis of the age at onset for the different clinical *types* of first affections—polyarthritis, carditis, carditis with polyarthritis, and chorea (Fig. 7). We find that the mode or the highest incidence of a first manifestation of these major affections varies definitely with the type of the affection. For polyarthritis as a first affection the mode is reached at about the age of five years; for carditis, at six years; while for chorea it is delayed to the ages of seven and eight years. Furthermore, while polyarthritis and carditis occur in at least 20 per cent of cases in the

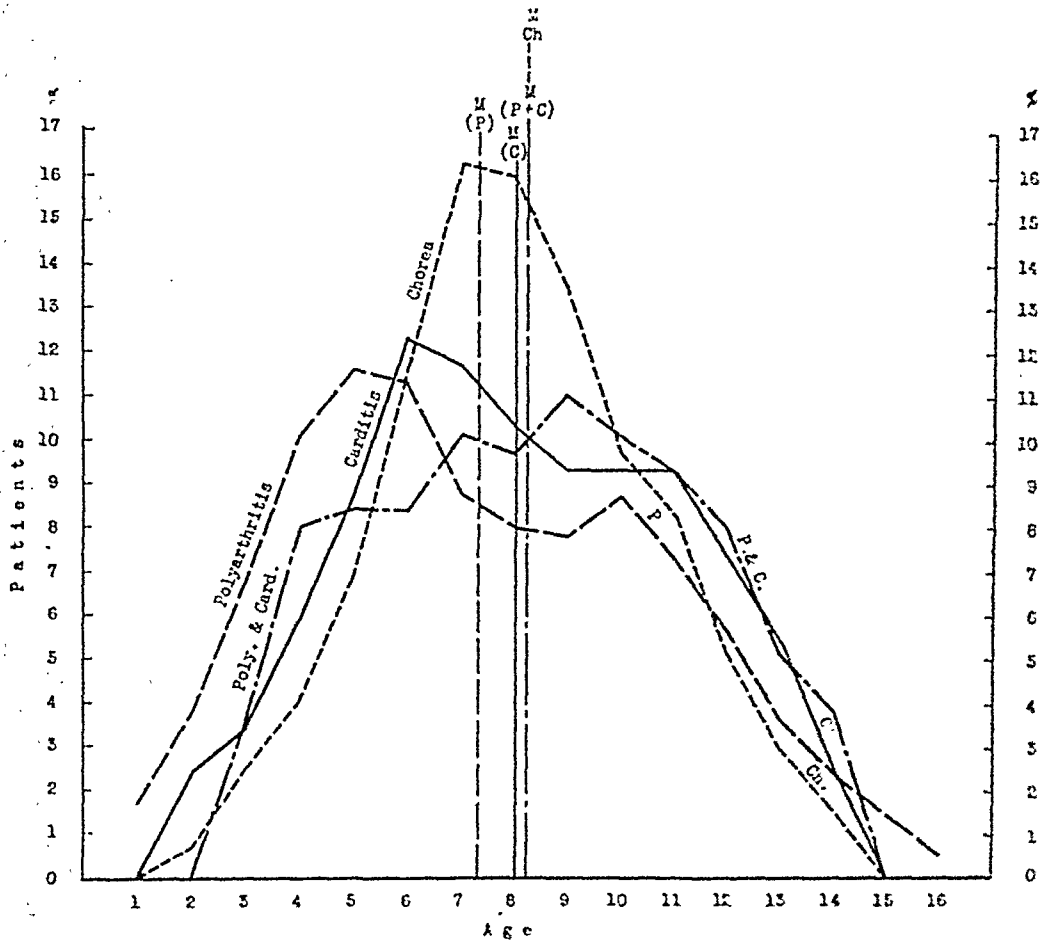

Fig. 7.—Age at onset in each clinical type of the major rheumatic affections.

preschool ages, the curves depicting the incidence for these affections tend to continue more or less high up to ten and twelve years. Chorea, on the other hand, occurs in only 13 per cent in the preschool ages, but its curve reaches a conspicuous peak at seven and eight years. The delay of the mode in the curve for chorea as a first manifestation explains why the highest incidence for all first affections is later for girls than for boys (Fig. 6). Chorea was found to be a more common first affection among girls than among boys, proportionately as 73 to 47 (Fig. 4).

The curve of concomitant affections of polyarthritis and carditis follows that of either polyarthritis or carditis, although the incidence

by year of this dual affection is highest between seven and eleven years. Both polyarthritis and carditis, as individual affections, seem to have a slight secondary rise in incidence as first affections at ages nine and ten years.

In our group then, initial rheumatic manifestations, consisting exclusively of acute attacks of polyarthritis, carditis, or chorea, or any combination of these, occurred at a rather early age. Our records show, furthermore, that the age period at which the onset of the disease reaches its greatest incidence varies appreciably with the different clinical types of initial affections. The age incidence for polyarthritis and carditis as first manifestations reaches a peak before or at the age of school entrants. We note, furthermore, that these affections play a significant rôle not only during the preschool age but also during the ages up to puberty. Chorea, on the other hand, while present in fair numbers during the same periods, takes a decided lead at ages seven to ten years, and its incidence at this time proportionately overshadows the other affections as a first manifestation of juvenile rheumatism.

Of course, believing as we do that major affections are not the only manifestations of active juvenile rheumatism and that many of the major episodes are preceded by and at times considerably antedated by less conspicuous clinical signs (exclusive even of muscle and joint pains), our observation of this special group leads to the assumption that acute rheumatism in children has its onset at a far earlier age than is generally implied in literature on the subject. Even though the disease is found at all ages, statistical curves, compiled for no matter how many age groups, still show that the incidence of first manifestations is highest during childhood. Clearly, it requires an intimate study of children's groups to indicate how early the disease really begins. If in coming years our familiarity with the "minor" symptoms and signs of juvenile rheumatism becomes greater, and if dependable diagnostic tests come to our aid, the disease may be found to have its onset among the earliest diseases of childhood.

RECURRENT MAJOR RHEUMATIC AFFECTIONS

Because of the protean manifestations of juvenile rheumatism, particularly because of its frequently protracted clinical course, the question is asked, what is a recurrence? This question is embarrassing in view of the fact that no adequate criteria exist to decide when the disease begins or when it actually terminates. Obviously, clinical criteria, in order to be serviceable, must define a recurrence as a clearly distinguishable event far enough removed from a preceding episode to preclude the likelihood of its being merely a continuation. Even this criterion is unsatisfactory in a disease which has a tendency to follow a polycyclic course. Any criterion is, in fact, arbitrary.

When an acute rheumatic affection was located, especially at the beginning or at the end of a year, the records of the year preceding or following it were examined, to be certain the episode was an isolated major affection. In order that the second attack might qualify as a recurrence, several months of apparent well-being must have elapsed during which a child was ambulatory, attending school or on a vacation. An uninterrupted episode even of two years' duration was regarded as a single attack.

Average Duration of Observation After the Initial Affection in Patients With and Without Recurrences.—In estimating the meaning of recurrences, the average duration of observation since the beginning must be known, particularly in relation to types of initial affection. Those without recurrences may not have survived or have been observed long enough to experience a recurrence. For comparison the mean duration of observation in both groups has, therefore, been tabulated, and for each subgroup according to the type of the initial affection (Table III).

TABLE III

AVERAGE DURATION OF OBSERVATION AFTER THE INITIAL AFFECTION IN PATIENTS WITH AND WITHOUT RECURRENCES

INITIAL MANIFESTATION	GROUP WITH RECURRENCES	GROUP WITHOUT RECURRENCES
	YEARS	YEARS
Polyarthritis	9.0	7.3
Chorea	8.7	7.0
Carditis	7.3	5.4
Polyarthritis and carditis	7.5	8.3
Total group	8.5	7.1

For the entire group the average length of observation since the onset has been 8.5 years in patients with recurrences and 7.1 years in those without recurrences. The shortest period occurred in the subgroup *carditis*, particularly in those without recurrences. But even in these, the period has already exceeded five years. That this period affords ample time for a recurrence to take place will be shown in a subsequent paragraph.

TABLE IV

THE INCIDENCE OF A MAJOR RECURRENCE DURING THE PERIOD OF OBSERVATION IN THE ENTIRE GROUP AND IN SUBGROUPS, ACCORDING TO TYPE OF THE INITIAL AFFECTIONS

INITIAL MANIFESTATION	TOTAL PATIENTS	PER CENT	NUMBER WITH RECURRENCES	PER CENT
Polyarthritis	220	100.0	149	67.7
Chorea	92	100.0	68	74.0
Carditis	68	100.0	40	58.8
Polyarthritis and carditis	79	100.0	49	62.0
Polyarthritis and chorea	18	100.0	15	83.4
Chorea and carditis	6	100.0	5	83.3
Polyarthritis, carditis, and chorea	5	100.0	5	100.0
Total group	488	100.0	331	67.8

Major Recurrences and Their Frequency in the Period of Observation.—More than two-thirds of the patients, 68 per cent (331), experienced at least one recurrence during an average of eight years (Table IV). The number varied according to the type of the initial affection. A recurrence was most common in *chorea* (74 per cent). So far, only about one-quarter of these children escaped. Next in order of frequency was the subgroup *polyarthritis* or *polyarthritis with carditis* (67.7 per cent and 62 per cent, respectively). In the subgroup *carditis* recurrences appeared in 58.8 per cent. In the combined affections the number was too small to warrant further study.

The number of recurrences (Table V) in individual cases differed widely. In the majority there was only one or two, but in an appreciable number there were three, four, or five. In a few cases there were six or more.*

TABLE V

NUMBER OF RECURRENCES IN INDIVIDUAL CASES

NUMBER OF RECURRENCES	NUMBER OF PATIENTS	PER CENT OF PATIENTS	CUMULATIVE PER CENT
1	128	38.7	38.7
2	89	26.9	65.6
3	58	17.5	83.1
4	22	6.6	89.7
5	20	6.0	95.7
6	8	2.4	98.1
7	2	0.6	98.7
8	1	0.3	99.0
9	0	-	99.0
10	2	0.6	99.6
11	1	0.3	99.9
Total	331	99.9	99.9

Interval Between the Initial Affection and a First Major Recurrence.—As has been stated, a first recurrent major affection was observed in 331 cases in the course of an average period of observation of eight years:

44 per cent (145) within one year of the initial affection;
20 per cent (67) in the course of the second year; and
9 per cent (31) during the third year.

Recurrences appeared, therefore, within three years after the initial manifestation of the disease in 73 per cent (243) (Fig. 8).

*Two cases presented ten and one case eleven major recurrences in the course of twelve and thirteen years. These cases being unusual, a brief description of the clinical course presented by one patient is given: J. G., a female, suffered at the age of four years an attack of polyarthritis for one week in winter; at the age of six years chorea appeared for two months in the autumn, and polyarthritis for one and a half weeks in winter; at the age of seven years chorea returned for two months in the autumn; at the age of eight years there was another attack of chorea for two months in the autumn; at the age of nine years, again, an attack of chorea for two months in the autumn and of polyarthritis for two weeks in winter; at the ages of ten and eleven years, another attack of chorea for two months in the autumn during each year; at the age of twelve years, chorea again for two months in the autumn and polyarthritis in winter; at the age of thirteen years, polyarthritis in the spring; at the age of fourteen years, carditis with adhesive pericarditis for seven months, from January to August; and at the age of sixteen years, severe rheumatic carditis for one month in the autumn resulting in death.

In a similar manner the time interval between the initial affection and the first recurrence in the several subgroups was analyzed. Of 220 patients with *polyarthritis*, 149 experienced at least one major recurrence:

38 per cent (57) within one year of the initial affection;
18 per cent (27) during the second year; and
7 per cent (11) during the third year.

In this subgroup, then, recurrences had appeared in 63 per cent (95), by the end of three years following the initial affection (Fig. 8).

In the subgroup *carditis*, of 68 patients, 40 experienced at least one major recurrence:

57.5 per cent (23) within one year of the initial affection;
15.0 per cent (6) during the second year; and
12.5 per cent (5) in the course of the third year.

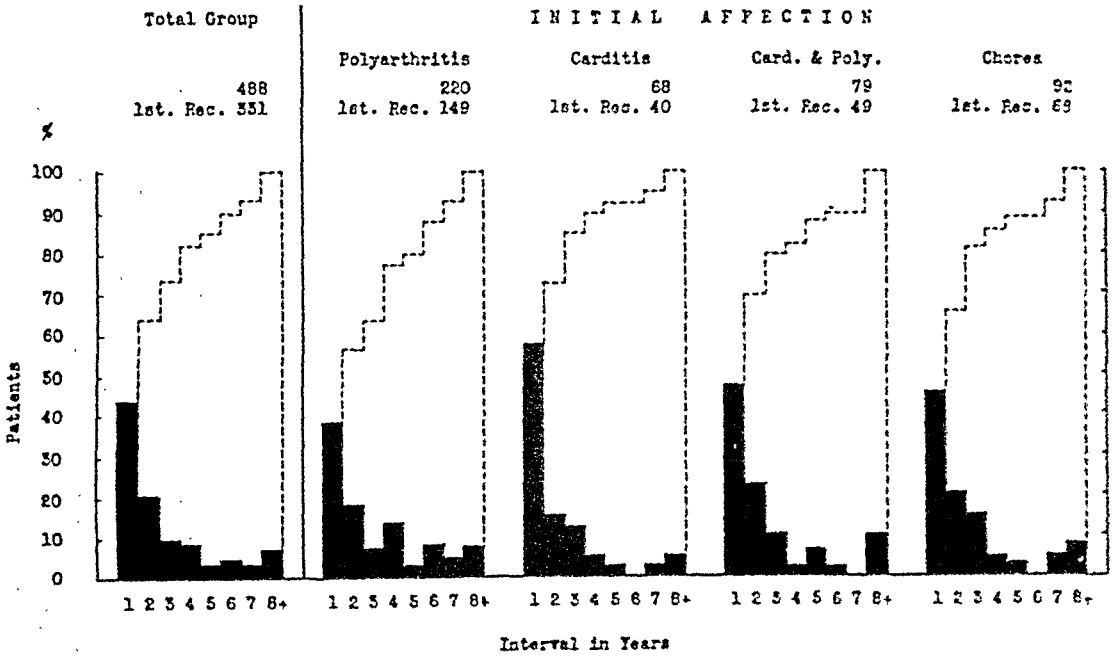

Fig. 8.—Interval between initial affection and first major recurrence.

In this subgroup recurrences made their appearance in 85 per cent (34) by the end of three years (Fig. 8). To make this point is important because in a previous paragraph the mean duration of observation in patients with this form of affection but without recurrences was given as 5.4 years (Table III), shorter than for any other group. But the relative brevity of the period of observation does not account for the smaller number of recurrences (Table IV), for 90 per cent occurred before the expiration of five years.

In the subgroup (79 cases) in which *carditis and polyarthritis* were combined there were 49 recurrences:

47 per cent (23) within one year after the initial affection;
23 per cent (11) during the second year; and
10 per cent (5) during the third year.

Here 80 per cent (39) occurred within three years (Fig. 8).

In the subgroup *chorea* (92 cases), the number of recurrent affections was 68:

46 per cent (31) within a year following the initial attack;
21 per cent (14) during the second year; and
15 per cent (10) during the third year.

In this subgroup recurrences appeared in 82 per cent (55) within three years (Fig. 8).

Interval Between the Initial Affection and a Second Major Recurrence.—The time of second recurrences has also been analyzed (Fig. 9). These took place in 198 (40 per cent):

35 per cent (69) appeared within two years after the initial attack;
16 per cent (32) in the course of the third year; and
11 per cent (21) during the fourth year.

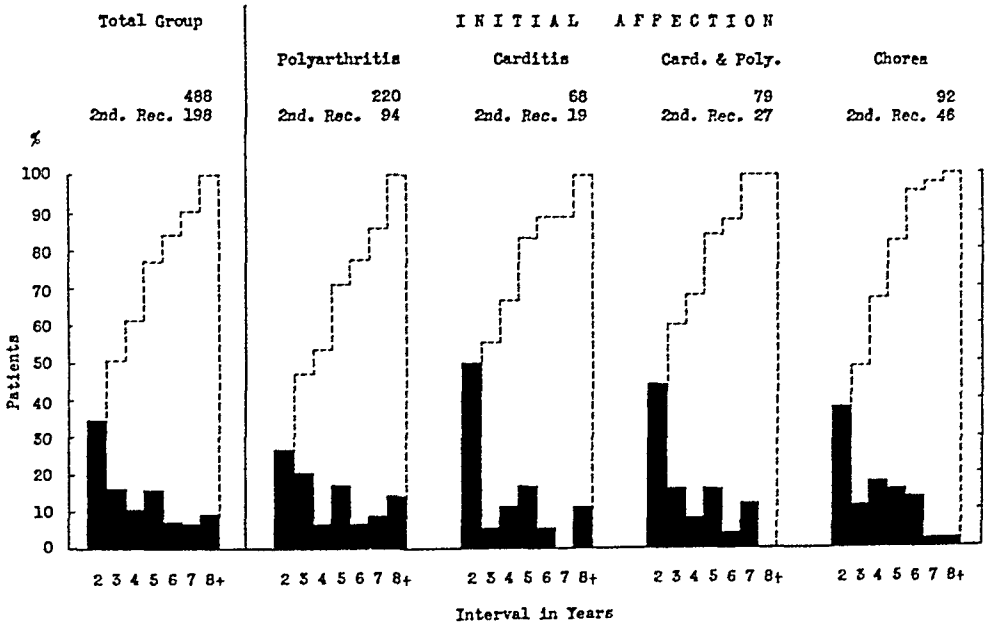

Fig. 9.—Interval between initial affection and second major recurrence.

Sixty-two per cent (122), or almost two-thirds, appeared by the end of four years. When a major recurrent affection appeared within one year after the initial attack, it was not regarded as a second recurrence.

Second recurrences in each of the subgroups need not be described in detail. The numbers are too small. The facts are presented, however, in Fig. 9. It is apparent that second recurrences are not crowded into the years immediately following the initial affection as are the first recurrences. What is significant is that they appear in appreciable numbers as late as four, five, or even six years after the onset of the disease.

The Factor of Personal Susceptibility.—From the data on first and second recurrent affections, particularly with reference to the order

of their appearance in successive years following the initial affection, it becomes apparent that attacks of juvenile rheumatism have a great tendency to recur. It is obvious, furthermore, that by far the greatest number appear within a few years after the onset of the disease. One-third to one-half of the first recurrences made their appearance within one year; and approximately three-quarters not later than three years after the initial affection. Second recurrences naturally appeared later. Nevertheless, among these, too, approximately two-thirds appeared within four years.

Two interpretations are possible. In the first place, so-called recurrences may be in reality not distinct and separate episodes, but merely exacerbations of silent or smoldering processes. But, applied to the data now reported, this conception assumes that juvenile rheumatism runs a continuous course for two or more years in at least one-third of the cases and for three or more years in one-quarter of all cases. While the disease undoubtedly runs a long-drawn-out course in an appreciable number of cases (such cases have been reported[15]), unsupported experience does not lead to the conclusion that cases of several years' duraton are as common as the records suggest, counting recurrent major episodes merely as recrudescences. One-quarter of the first recurrences failed, indeed, to appear for three years. First recurrences sometimes appear so many years after the initial attack that a true recurrence* of the disease must be assumed. Recurrence did not, in fact, appear in 5 to 10 per cent of cases, for as long as eight years or more (Fig. 8).

According to the second interpretation, later attacks may be not recrudescences but distinct, new infections. Their appearance in the first few years after the initial manifestation is taken to indicate that there is increased susceptibility to new invasion. Seasonal recurrences, as well as their tendency to follow in the wake of intercurrent diseases, especially of the upper respiratory type, lend plausibility to this assumption. This view is strengthened, furthermore, by the well-known fact that patients migrating to subtropical climates are generally free from this disease, although on returning to their former homes, even after several years, they are subject, not uncommonly, to new attacks.[16, 17]

Obviously in the present state of knowledge the nature of recurrent attacks of juvenile rheumatism is not understood.

The Relation of Types of Recurring Attacks to the Type of the Initial Affection.—With the hope of shedding more light on the nature of recurrent manifestations of juvenile rheumatism, the recurrences themselves have been grouped according to clinical types.

*A true recurrence may be likened to what is analogously termed a "superinfection" in tuberculosis.

Polyarthritis.—In 220 cases of initial *polyarthritis,* recurrences appeared in 149 cases and second recurrences in 94 cases (Figs. 8 and 9).

Among the 94 *second recurrences* (Fig. 10*A*) polyarthritis was present, alone or combined, in 74 per cent (110 cases). It was the only affection in 55 per cent (82). It was associated with acute carditis in 24 cases, and with chorea in only 3 cases. Acute carditis was the next most common. It was present alone in 17 per cent (25) and combined with polyarthritis in 16 per cent (24). Chorea was present alone in only 9 per cent (13). In 5 additional cases it was combined with the other affections.

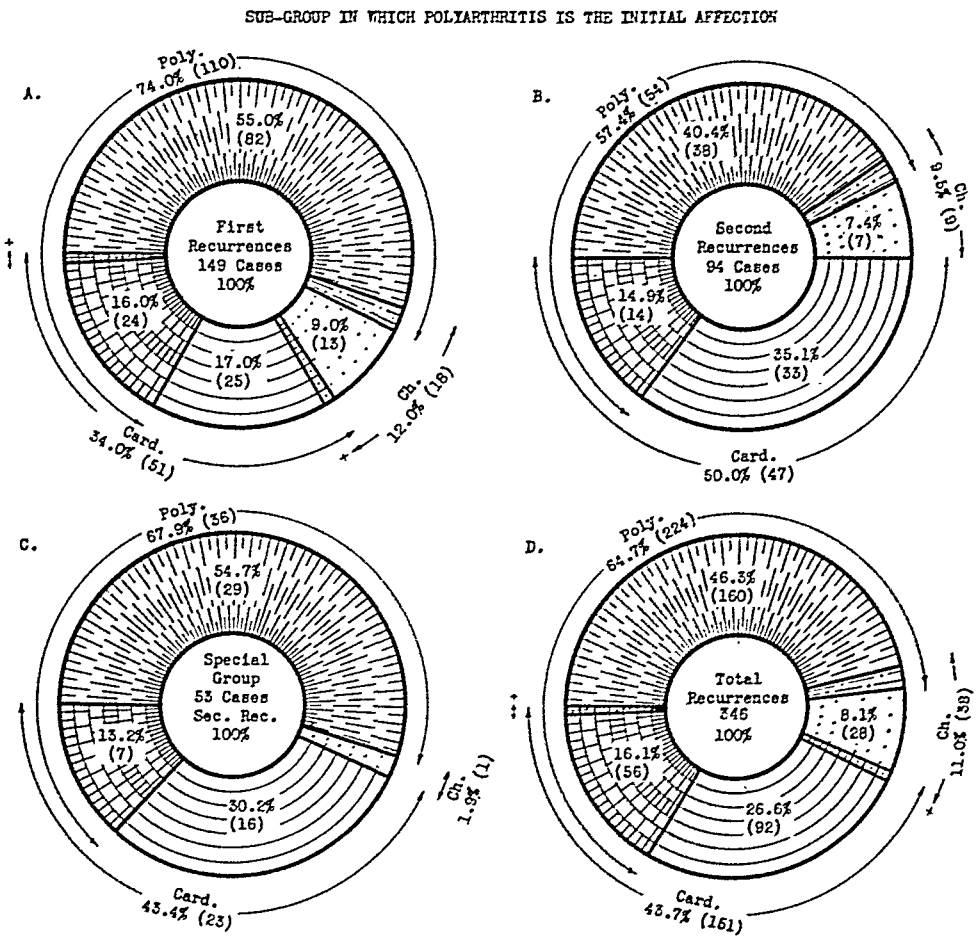

Fig. 10.—Clinical types of recurrent major affections related to *polyarthritis* as initial affection.

Of 220 patients with primary *polyarthritis,* 149 experienced at least one recurrence of a major manifestation, *A,* and 94 exhibited a second recurrence, *B.* Fifty-three patients (of the 82 shown in *A*) are constituted a "special" group because they exhibited a major episode three times, the initial attack and the first recurrence being *polyarthritis, C. D* presents the types of a total of 346 recurrent manifestations experienced by 149 of the 220 patients in whom one or more recurrences appeared during the period of observation.

Among the 94 *second recurrences* (Fig. 10*B*) polyarthritis was present in 57 per cent (54). It appeared alone in 40 per cent (38), and combined with carditis in 15 per cent (14). Acute carditis was al-

most as common a second recurrence as polyarthritis, appearing alone in 35 per cent (33), and associated with polyarthritis in 15 per cent (14). Chorea appeared among the second recurrences of this group in only 9 cases, or in less than 10 per cent.

Second recurrences were next examined in a *special group* of 82 cases, characterized by the fact that both the *initial attack* and the *first recurrence* were polyarthritis. In this group a second recurrence appeared in 53 cases (Fig. 10C). While the group is small, it is im-

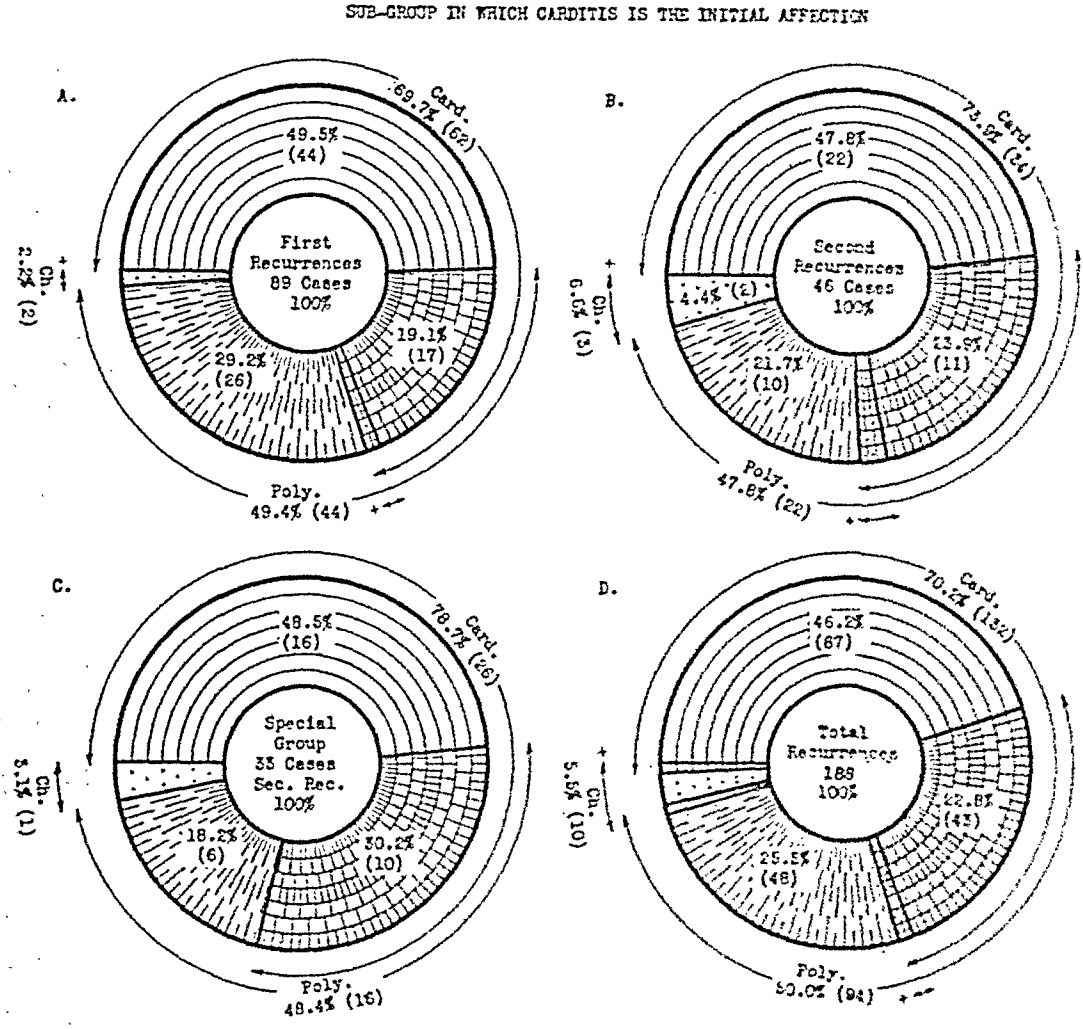

Fig. 11.—Clinical types of recurrent major affections related to *carditis* as initial affection.

Of 147 patients with primary *carditis* (with or without polyarthritis), 89 experienced at least one recurrence of a major manifestation, *A*, and 46 exhibited a second recurrence, *B*. Thirty-three patients (of the 44 shown in *A*) are constituted in a "special" group because they exhibited a major episode three times, the initial attack and the first recurrence being *carditis*, *C*. *D* presents the types of a total of 188 recurrent manifestations experienced by 89 of the 147 patients in whom one or more recurrences appeared during the period of observation.

portant that 55 per cent (29) again presented polyarthritis. Carditis appeared in 30 per cent (16) and polyarthritis with carditis in 13 per cent (7). Chorea appeared only once. Accordingly, the second recurrences constituting, in fact, the third major episode consisted almost

entirely (98 per cent) of polyarthritis, carditis, or both. Although there was a high incidence of carditis throughout, polyarthritis stood out as the predominant affection.

Carditis.—Because in the group of initial polyarthritis, carditis alone or in combination was a common recurrence, the group of initial *carditis* alone or combined with polyarthritis was also investigated. There were 147 such cases (68 cases of carditis alone and 79 cases of carditis with polyarthritis), in which 89 first and 46 second recurrences were traced (Fig. 11*A* and *B*).

Of 89 *first recurrences* (Fig. 11*A*) carditis appeared alone in 50 per cent (44); polyarthritis alone in approximately 30 per cent (26); and a combination of carditis with polyarthritis in 20 per cent (17). Chorea was present in 2 cases only, in one case alone and in one case with carditis.

Among the 46 *second recurrences* (Fig. 11*B*) carditis appeared alone in 48 per cent (22); polyarthritis alone in 22 per cent (10); carditis with polyarthritis in 24 per cent (11); and chorea in 3 cases only. In 2 cases it appeared alone, and in a third case it was associated with carditis and polyarthritis. In this group, too, when carditis, either alone or in association with polyarthritis, was the initial affection, both carditis and polyarthritis reappeared as the dominant affections among first and second recurrences to the extent of 98 per cent and 93 per cent, respectively.

Chorea.—In a similar manner the subgroup in which *chorea* was the initial manifestation has been investigated. Of 92 cases, 68 exhibited at least one recurrence and 46, two recurrences (Fig. 12).

Of the *first recurrent affections* chorea appeared alone in 70.5 per cent (48); with carditis, in 6 per cent (4); and with polyarthritis, in 3 per cent (2). Acute carditis appeared alone in 7 per cent (5) and polyarthritis alone in 12 per cent (8). Altogether chorea made its reappearance in 79 per cent (54) (Fig. 12*A*).

The *second recurrences* were equally impressive. Here again the initial affection chorea reappeared. It holds true in 78 per cent (36). These were all, except one, clinically uncomplicated cases of chorea. In the remaining 10 cases polyarthritis was present in 6, and acute carditis in 4 cases (Fig. 12*B*).

As before, a *special group* of 48 cases was studied in which chorea appeared as the *initial* as well as the *first recurrent* affection. A third major episode occurred in 36 (Fig. 12*C*), of which 81 per cent (29) were chorea alone, 8 per cent (3) each polyarthritis and carditis, and 1 case chorea with carditis.

These observations are recapitulated in tabular form for the sake of giving a general summary (Table VI).

The Factor of Susceptibility.—This analysis of the first and second recurrences reveals, it seems, convincingly, that major recurrences, the

first and second at any rate, are predominantly of the same clinical type as characterized the first manifestation of the disease. The disease usually remained true to type. When *polyarthritis* or *carditis* or both appeared as the initial manifestation of the disease, these affections reappeared to the extent of 91 per cent in first recurrences and 92.6 per cent in second recurrences (Fig. 10*A* and *B*). If, furthermore, the

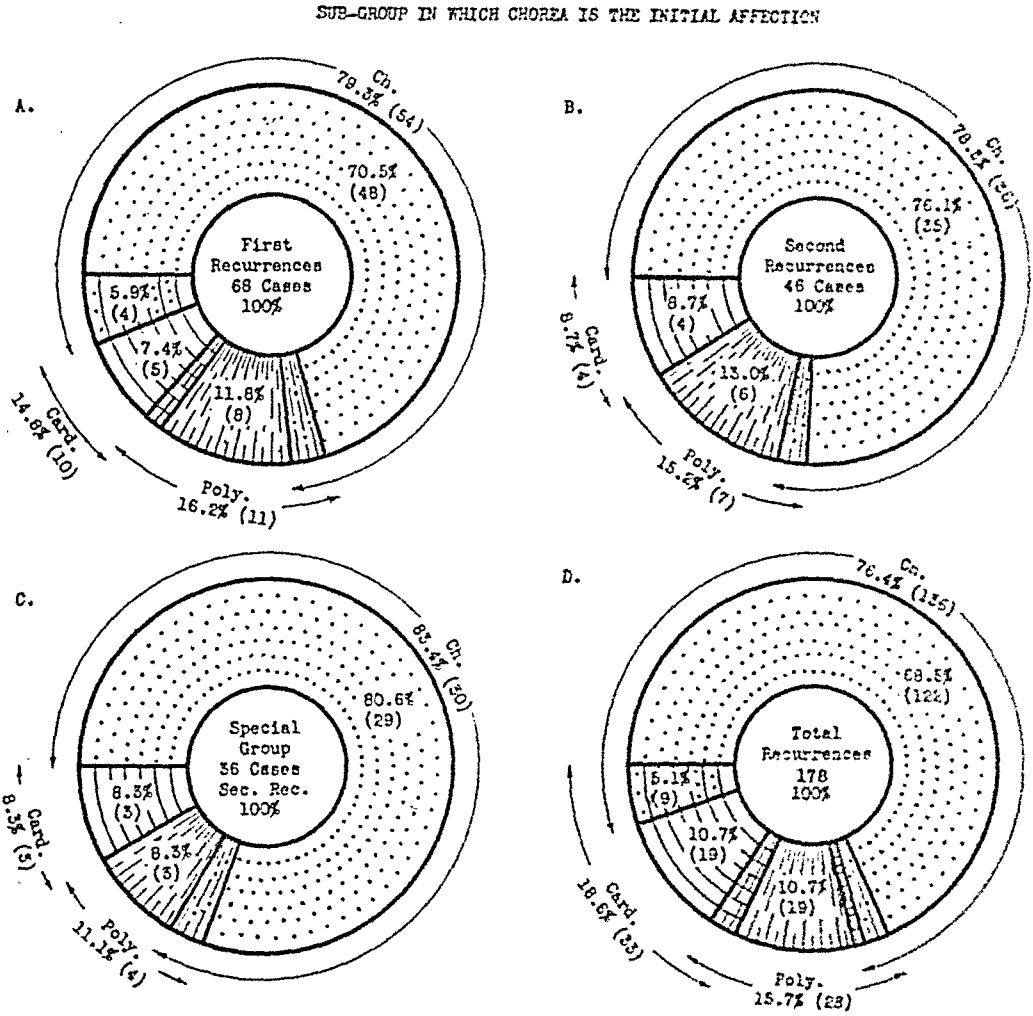

Fig. 12.—Clinical types of recurrent major affections related to *chorea* as initial affection.

Of 92 patients with primary *chorea*, 68 experienced at least one recurrence of a major manifestation, *A*, and 46 exhibited a second recurrence, *B*. Thirty-six patients (of the 48 shown in *A*) are constituted a "special" group because they exhibited a major episode three times, the first attack and the first recurrence being *chorea*, *C*. *D* presents the types of a total of 178 recurrent manifestations experienced by 68 of the 92 patients in whom one or more recurrences appeared during the period of observation.

initial affection and the first recurrence were polyarthritis, this type dominated the next recurrence or the third major episode almost exclusively.

The events are the same when *chorea* is the initial manifestation. The first and second recurrences are then predominantly chorea.

This striking tendency of recurrent affections to remain true to the initial pattern suggests that in juvenile rheumatism it is the state of the tissue which decides the form of the initial invasion and that it is

the state in which the tissue is left after the original attack which determines the subsequent clinical form of the disease. This statement, purposely put in this vague form, is as far as current evidence permits a deduction.

Clinical Types of All Major Recurrences.—Whether the appearances which were observed in the first and second recurrences are clinical types rather than acute exacerbations in the course of protracted forms of disease is open to doubt. If they are merely exacerbations,

TABLE VI

RECURRENCES OF MAJOR MANIFESTATIONS, SO FAR AS THEY REMAIN TRUE TO THE TYPE OF THE INITIAL MANIFESTATIONS

(RECAPITULATION OF FIGS. 10, 11, AND 12)

RECURRENCES		INITIAL MANIFESTATION: POLYARTHRITIS (220 CASES) NO.	%	CARDITIS (147 CASES) NO.	%	CHOREA (92 CASES) NO.	%
First recurrence	Total patients	149	100.0	89	100.0	68	100.0
	Same type as initial manifestation	110	74.0	62	69.7	54	79.3
	Pure	82	55.0	44	49.5	48	70.5
	Complicated	28	19.0	18	20.2	6	8.8
Second recurrence	Total patients	94	100.0	46	100.0	46	100.0
	Same type as initial manifestation	54	57.4	34	73.9	36	78.3
	Pure	38	40.0	22	47.8	35	76.1
	Complicated	16	17.4	12	26.1	1	2.2
Second recurrence in special group*	Total patients	53	100.0	33	100.0	36	100.0
	Same type as initial manifestation	36	67.9	26	78.7	30	83.4
	Pure	29	54.7	16	48.5	29	80.6
	Complicated	7	13.2	10	30.2	1	2.8
All recurrences	Total incidence	346	100.0	188	100.0	178	100.0
	Same type as initial manifestation	224	64.7	132	70.2	136	76.4
	Pure	160	46.3	87	46.2	122	68.5
	Complicated	64	18.4	45	24.0	14	7.9

*This is a group in which the first recurrent affections (second major episodes) are pure clinical types, the same as the initial affections.

they would naturally resemble the phenomena at the time of the initial affection. Doubt is removed in part, however, since approximately 25 per cent of all first and 50 per cent of all second recurrences appeared not less than three years after the onset of the disease.

But the analysis was carried further. It included not only first and second, but all major recurrences throughout the period of observation. Recurrent major affections continued to be predominantly of the same clinical type as the initial manifestations.

In the subgroup *polyarthritis* (220 cases), 149 children experienced a total of 346 major recurrences (Fig. 10*D*). Polyarthritis, or carditis, or both were present 308 times (91.9 per cent). In 10 instances one or both of these affections were complicated by chorea. Uncom-

plicated chorea appeared only 28 times (8.1 per cent). This distribution resembles that in the first (91.0 per cent) and second (92.6 per cent) recurrences in the same subgroup.

In the subgroup *carditis,* with or without polyarthritis (147 cases), 89 children experienced 188 major recurrences (Fig. 11*D*). Among these, carditis, polyarthritis, or both were present 182 times (96.8 per cent). Four were complicated by chorea. Chorea alone was present only 6 times (3.2 per cent).

In the subgroup *chorea* (92 cases), 68 children experienced 178 major recurrences (Fig. 12*D*). Chorea reappeared 136 times (76.3 per cent). Fourteen were complicated by polyarthritis or carditis. Polyarthritis, carditis or both, uncomplicated by chorea, appeared 42 times (23.7 per cent).

In this form of analysis, also, the clinical type of the initial affection reappeared as the dominant type in approximately the same proportion as in first and second recurrences. This occurrence may be taken in connection with the remarks already made on the state of the tissue as an important factor in juvenile rheumatism.

The remarkable tendency of the original clinical form of the disease to reappear, year after year, occurs especially in cases in which the disease was ushered in by polyarthritis or carditis. Among the recurrences of this group, chorea was present in less than 10 per cent. When *polyarthritis* and *carditis* were the dominant clinical types, they reappeared in such large numbers and were so commonly associated as to suggest that they belonged essentially to one and the same clinical pattern.

In the subgroup *chorea,* on the other hand, though this manifestation was predominant in recurrent affections in its group (76 per cent), polyarthritis and carditis occurred as not uncommon complications. They were present alone, together, or in association with chorea, in over 30 per cent.

The relative rarity of chorea among recurrences in primary polyarthritis or carditis, in which valvular heart disease is known to be common, and the frequent appearance of polyarthritis and carditis as recurrences in primary chorea, in which valvular heart disease is reported as relatively rare, suggest that valvular disease in cases of primary chorea is due not to chorea, but to accompanying or intercurrent episodes of polyarthritis and carditis. Since it is believed that the latter appear, often not as easily recognized episodes such as have been termed "major manifestations" in this report, but in inconspicuous subacute form, their actual incidence in cases of primary chorea may be even greater than these statistics indicate. That this is the case may be inferred from the fact that these patients were referred to the cardiac clinic not because of chorea, but because heart disease was either present or suspected. Furthermore, in the cases of

primary chorea, in which polyarthritis or carditis appeared as major manifestations, mitral stenosis was three and one-half times as common as when these manifestations did not appear.

In the literature the incidence of cardiac involvement in chorea varies to such extreme degrees as to render any attempt at calculating its incidence a hopeless task. It is reported to be as low as 3 per cent,[18] and as high as 25 per cent[19] and even 60 per cent.[20] The marked divergence in opinion is due largely, it seems, to lack of uniform criteria as to what constitutes heart disease in the first place and, second, to difficulty in deciding when a case is really one of primary or pure chorea. If a rough estimate were attempted, nevertheless, the incidence of heart disease in cases of chorea would range between 30 and 40 per cent. This is approximately the percentage of major recurrent attacks of polyarthritis and carditis in our subgroup *chorea.* Valvular heart disease encountered in cases of chorea is probably due, in short, not to chorea but to accompanying or intercurrent episodes, often subacute, of polyarthritis and carditis.

SUMMARY AND CONCLUSIONS

This study is based on 488 cases, in each of which the onset of juvenile rheumatism was traced to a major episode, either polyarthritis, carditis, or chorea, or a combination of these, and the clinical course of which had been observed at the Children's Cardiac Clinic of Mount Sinai Hospital in New York within a period of fifteen years. There was only a slight difference in distribution according to sex.

The average interval between the *initial affection* and the time of *first observation* was 2.3 years; the average age at first observation was ten years; and the average duration between the initial affection and the end of the period of observation was eight years.

Polyarthritis was the initial affection in 322 cases; *carditis,* in 158 cases; chorea, in 121 cases. Combinations of these types, especially polyarthritis and carditis, were common. Polyarthritis was the most common initial affection for the entire group; chorea was one and one-half times as common among girls as among boys.

The mean *age at onset* was eight years and the mode was seven years. A more detailed analysis showed, however, that in fully one-quarter of the patients initial affections occurred in the preschool age. The mode varied with the clinical type characterizing the initial affection. In polyarthritis it appeared at about the age of five years; in carditis, at about six years; and in chorea, between seven and eight years of age. While the number of cases of polyarthritis and of carditis were at a relatively high level throughout the preschool as well as the entire school age, chorea appeared conspicuously crowded between the ages of seven and ten years (60 per cent).

During eight years, the average duration of the period of observation, at least *one recurrence* took place in 68 per cent; in the subgroup *chorea* 74 per cent had recurrences. In the majority of cases there were only one or two recurrences, but in an appreciable number as many as three, four, or five, and in a few cases six or more, were observed.

In the entire group, 73 per cent of first recurrences appeared not later than three years after the initial manifestation of the disease. In the subgroups they appeared within three years, as follows: in polyarthritis, 64 per cent; in carditis, 85 per cent; in carditis with polyarthritis, 80 per cent; in chorea, 81 per cent. At least two recurrences took place in approximately 40 per cent of cases. Nearly two-thirds of all second recurrences appeared not later than four years after the initial affection.

Juvenile rheumatism has, therefore, a great tendency to recurrences. For three or four years after its onset personal vulnerability is greatest. This has an important therapeutic implication. It suggests that a rheumatic child should be under close observation, in many cases preferably in an institution, for the first several years.

The question whether recurrences, especially the first and second, remained true to type was carefully studied. The analysis suggests that the type of the major recurrences is usually the same as that of the initial affection. Subsequent attacks of juvenile rheumatism appear, therefore, to depend on the original state or on the state subsequent to infection of the tissues. It is impossible now to come to a precise conclusion. An analysis of all the events which were observed confirms this deduction.

The tendency to remain true to type year after year is especially the case in polyarthritis and carditis. These manifestations are, furthermore, so frequently associated as to suggest that they express a similar method of response. Chorea reappears, nevertheless, with sufficient frequency to suggest that it is a distinct type, though polyarthritis or carditis is found not uncommonly among its recurrences.

It seems probable that the valvular heart disease which ultimately develops in cases in which the initial affection is chorea is due not to chorea but rather to polyarthritic and carditic manifestations associated with it or its recurrences. Further study of this problem is important.

REFERENCES

1. Coombs, Cary F.: Lectures on the Causes and Preventions of Rheumatism, Lancet 1: 579, 634, 739, 802, 1927.
2. McSweeney, C. J.: Acute Rheumatism in Childhood, Lancet 1: 959, 1928.
3. Dally, J. F. Halls: Report of the St. Marylebone Children's Rheumatism Supervisory Centre, London, 1926-1929.
4. Hill, T. W.: The Prevention of Child Rheumatism, M. Officer 41: 123, 1929.

5. Mackie, Thomas T.: The Prognosis and Treatment of Rheumatic Infection, AM. HEART J. 3: 31, 1927.
6. Hill, N. Gray: The Etiology of Juvenile Rheumatism, Brit. J. Child. Dis. 27: 161, 1930.
7. McCulloch, Hugh, and Irvine-Jones, Edith I. M.: The Rôle of Infection in Rheumatic Children, Am. J. Dis. Child. 37: 252, 1929.
8. Wilson, M. G., Lingg, C., and Croxford, G.: Statistical Studies Bearing on Problems in the Classification of Heart Disease: IV. Tonsillectomy in Its Relation to the Prevention of Rheumatic Heart Disease, AM. HEART J. 4: 197, 1928.
9. Benjamin, F. J.: Rheumatism in Childhood, Metropolitan Asylums Board Annual Report, London, 1926-1927.
10. Sutton, L. P.: Carditis in Children, Health Examiner 5: 5, 1935.
11. Campbell, Maurice, and Warner, E. C.: A Study of Rheumatic Disease in Children, Lancet 1: 61, 1930.
12. Miller, Reginald: Report on the Environmental and Other Predisposing Causes of Rheumatic Infection, Brit. M. J. 2: 23, 1926.
13. McLean, C. C.: Early Rheumatic Infections of Childhood, Arch. Pediat. 46: 657, 1929.
14. Poynton, F. John: Lettsomian Lectures on Rheumatic Heart Disease in Childhood, Tr. M. Soc., London 51: 313, 1928.
15. Swift, Homer F.: Rheumatic Fever, Am. J. M. Sc. 170: 631, 1925.
16. Coburn, Alvin F.: The Factor of Infection in the Rheumatic State, Baltimore, 1931, The Williams and Wilkins Company.
17. Seegal, D., and Seegal, B. C.: Studies in the Epidemiology of Rheumatic Fever, J. A. M. A. 89: 2, 1927.
18. Jones, T. Duckett: Clinical Significance of Chorea as a Manifestation of Rheumatic Fever, J. A. M. A. 105: 571, 1935.
19. St. Lawrence, William: Potential Heart Disease, J. A. M. A. 78: 947, 1922.
20. Mackie, Thomas T.: An Analytical Study of 396 Cases of Rheumatic Fever and 89 Cases of Chorea, Am. J. M. Sc. 172: 199, 1926.

ATRIOVENTRICULAR RHYTHM WITH AND WITHOUT RETROGRADE BLOCK

ADOLF SCHOTT,* M.D. (HEIDELBERG), M.R.C.S. (ENGLAND)
LONDON, ENGLAND

THE following case presents several unusual features which are of a clinical as well as of a physiological interest so that a short communication seems warranted.

REPORT OF CASE

Mrs. H., aged fifty-eight years, consulted me on Oct. 22, 1935, for palpitation of the heart. She had had a slow pulse for over twenty years; as long as her pulse rate was about 40-42 she felt well, but when the rate exceeded 48 she noticed palpitations which were associated with discomfort in her chest and head. She had diphtheria as a child and typhoid fever at the age of seventeen. In 1925 she consulted a well-known professor of medicine in Switzerland for pain in the right hypochondrium and for palpitation of the heart and slow pulse. It was found at the time that she suffered from chronic cholecystitis with hypercholesterinemia; an electrocardiogram taken at the time revealed that the bradycardia was due to a simple sinus bradycardia with a rate of 55 to 61 beats per minute (Fig. 1). For the past ten years after having taken repeated cures at Karlsbad and Vichy, and living permanently on a suitable diet, she had no trouble from her gallbladder. Another electrocardiogram taken in 1932 showed again sinus bradycardia, the rate now being 40 to 46; apart from a less marked S in Lead I and a different shape of P in Leads II and III, the tracing did not show any material difference in comparison with the record taken in 1925.

On examination I found the heart considerably dilated to the left, there was a sharp systolic murmur over the apex and the second aortic sound was accentuated and ringing. Heart and pulse rate was 44 per minute; the heart action was irregular, and on auscultation the arrhythmia gave the impression of being caused by numerous extrasystoles. Blood pressure was 140/80. The liver and the gallbladder were not palpable, and there was no tenderness in the right hypochondrium. The x-ray examination confirmed that the heart was dilated to the left and showed, moreover, a large left ventricle and a prominent aorta of increased density (Fig. 2). The retrocardiac space was free, the left auricle not enlarged. The urine was normal.

ELECTROCARDIOGRAMS

The first electrocardiogram taken the same day showed that the arrhythmia was not caused by extrasystoles but that this was a case of the comparatively uncommon "dissociation with interference" (Fig. 3). Taking Lead II first we see that there is a regular sequence of P-waves following one another at an interval of 1.56 to 1.59 sec. (corresponding to a rate of 38 per minute) and a regular sequence

*Clinical assistant, Guy's Hospital, London.

of ventricular complexes following one another at intervals of 1.50 to 1.56 sec. (rate: 38 to 40 per minute). There is a constant change of the position of the P-waves in relation to the ventricular complexes

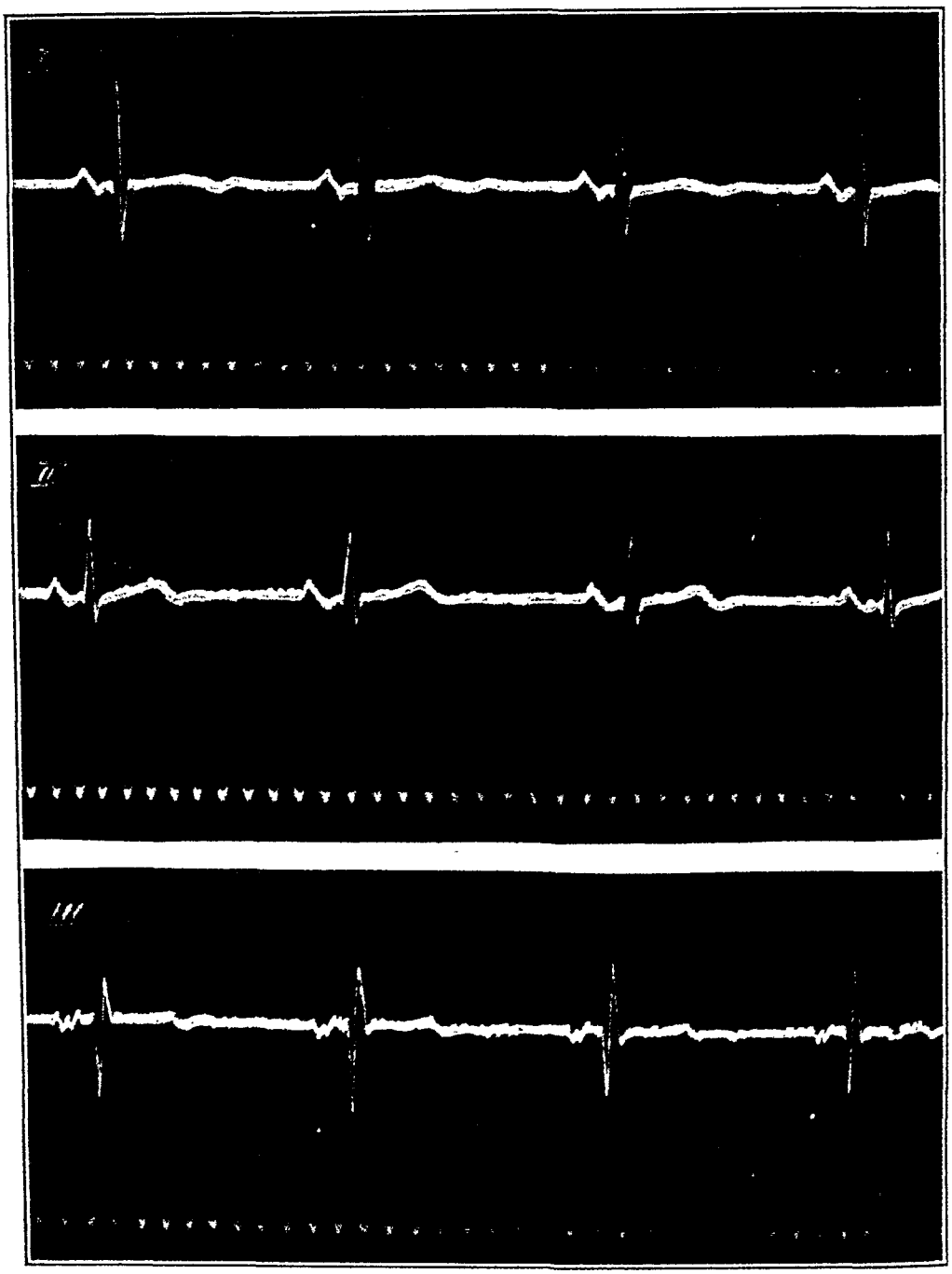

Fig. 1.—Electrocardiogram taken in 1925, showing sinus bradycardia. Leads I, II, and III. Time in tenths of a second.

indicating that these two rhythms are independent of one another. We are thus dealing with a case of dissociation of the action of the heart the auricles being stimulated by a center situated in—or in the

vicinity of—the sino-auricular node, and the ventricles following another pacemaker which must be situated above the site of division of the main bundle of His because of the normal shape of the ventricular complexes. It will also be noticed that the rate of the atrioventricular rhythm stimulating the ventricles is faster than the auricular rate. It is this difference in the rates of the two rhythms which causes a constant change of position of the P-wave in relation to the ventricular complexes. Leads I and III show the same phenomenon but demonstrate, moreover, that whenever an auricular impulse falls sufficiently late after a ventricular contraction so that it reaches the ventricles after their refractory period, it leads to a contraction of

Fig. 2.—Teleradiogram, taken Oct. 22, 1935.

the ventricles. Thus we see in Lead I that the first auricular contraction which occurs 0.22 sec. after the end of the preceding ventricular one is conducted to the ventricles and is followed by a ventricular complex after a P-R interval of 0.32 sec. The shape of the ventricular complex differs from those of the atrioventricular beats. This difference must be ascribed to aberrant conduction due to the fact that the conducting system had not completely recovered since the preceding beat, and therefore the conduction within the ventricles follows different paths. The phenomenon of aberrant conduction is well known in connection with early auricular extrasystoles (Lewis). The last ventricular beat in Lead I is another instance of the conduction of an

auricular impulse to the ventricles; here the auricular contraction occurred 0.24 sec. after the preceding ventricular complex and is conducted to the ventricles with a P-R interval of 0.32 sec. Lead III shows two conducted beats, the second and the fifth; in either case the auricular contraction follows the preceding ventricular one after 0.22 sec. and is conducted to the ventricles in 0.34 and 0.32 sec. respectively.

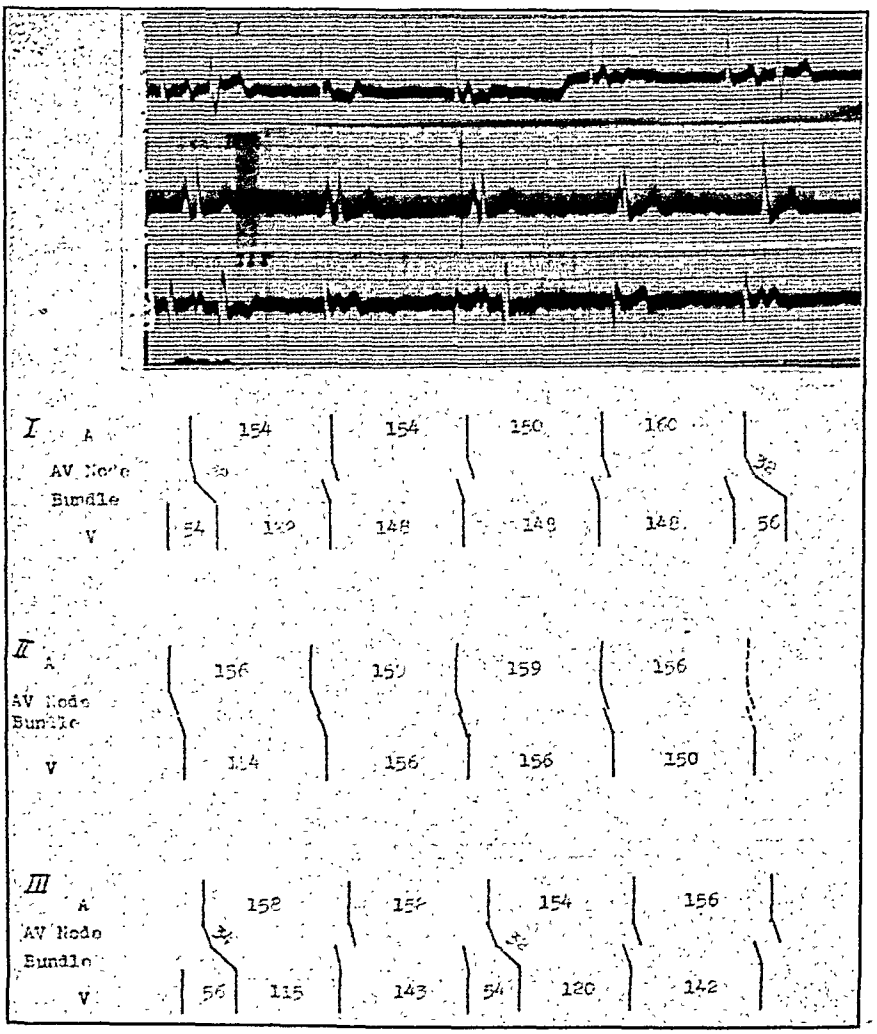

Fig. 3.—Electrocardiogram taken Oct. 22, 1935. Leads I, II, and III, showing dissociation with interference. For explanation see text and key below the tracing. Time in this and all the subsequent figures in twenty-fifths of a second.

This tracing shows therefore that the regular beats as found on auscultation are atrioventricular beats and that the "premature beats" which disturb the regular rhythm are due to the occasional conducted auricular beats.

One should expect the interval between a conducted impulse and the following atrioventricular impulse to be equal to the interval between two atrioventricular impulses, because the conducted impulse

when passing the atrioventricular center temporarily interferes with the impulse formation in the atrioventricular node, and therefore the impulse starts to form again in the atrioventricular center when the conducted impulse has left the center. In the present case, however, the time interval between the conducted beat and the following atrio-

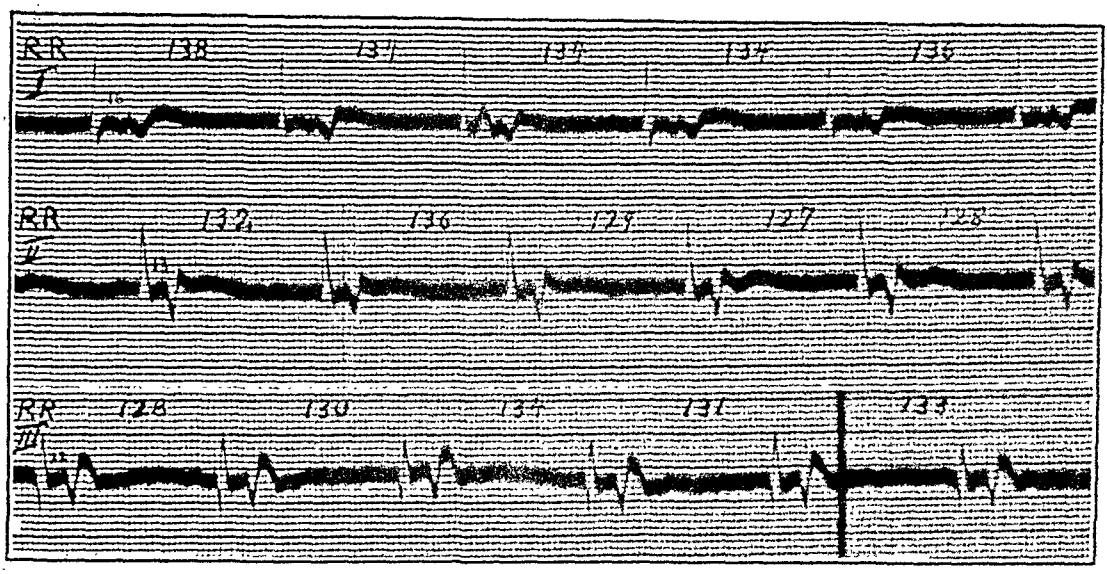

Fig. 4.—Electrocardiogram taken Oct. 24, 1935. Leads I, II, and III, showing atrioventricular rhythm.

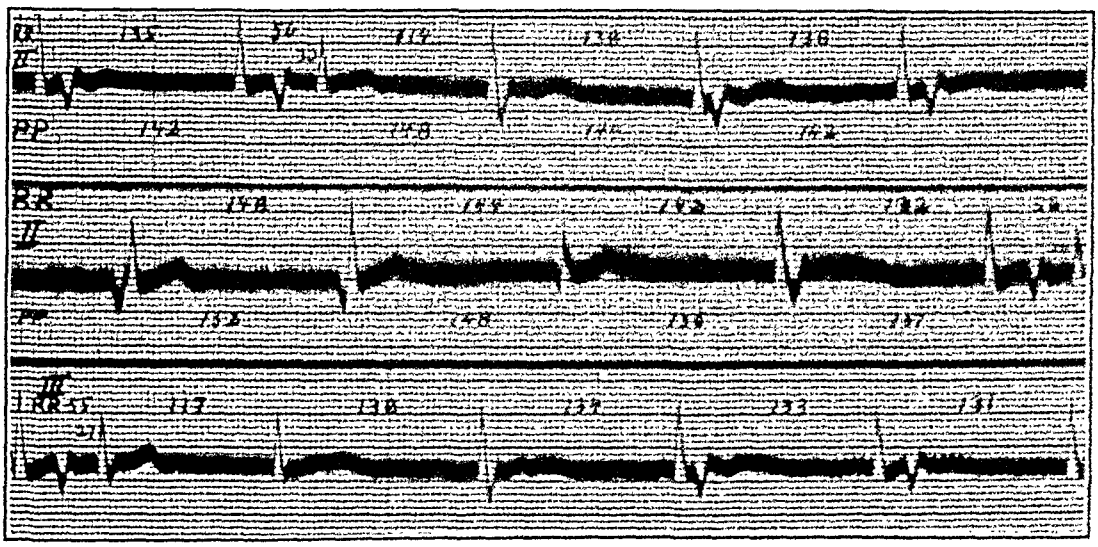

Fig. 5.—Electrocardiogram taken a few minutes after Fig. 4. Lead II only. Showing dissociation with interference and intra-auricular disturbances of conduction.

ventricular impulse is shorter than the time between two successive atrioventricular beats. Thus, in Lead I, the interval between the second—conducted—and the following—atrioventricular—beat is only 1.22 sec. as compared with the interval of 1.48 sec. separating the following atrioventricular beats. This phenomenon is of considerable theoretical importance and will be discussed later.

A coexistence of two independent rhythms, a sino-auricular and an atrioventricular one, can of course occur only when there is no retrograde conduction of the atrioventricular impulses to the auricles.

The patient came to see me again two days later and the first electrocardiogram taken on that occasion (Fig. 4) shows a different condition although no treatment had yet been inaugurated. In this tracing we see only an atrioventricular rhythm, the ventricular complexes following one another at a time interval of 1.27 to 1.36 sec. (rate: 44 to 47 beats per minute). Negative P-waves follow the ventricular complexes at an R-P interval of 0.16 to 0.18 sec. in Lead I, 0.11 to 0.13 sec. in Lead II and at a Q-P interval of 0.22 to 0.23 sec. in Lead III. We are dealing therefore with an atrioventricular rhythm originating in the lower parts of the A-V node, and the fundamental difference between this and the first electrocardiogram (Fig. 3) is that here every atrioventricular impulse is conducted backward to the auricles.

Atrioventricular rhythm is often a transitory phenomenon. The next tracing taken only a few minutes after the preceding one shows that the condition had changed again and that dissociation with interference had replaced the atrioventricular rhythm (Fig. 5). In this immediate succession. The similarity between this tracing and the tracing Lead II only was used, and the three strips were taken in first electrocardiogram (Fig. 3) is very striking, particularly with regard to the time relations. We see again the dissociation of the two rhythms: P-waves following one another at time intervals of 1.40 to 1.52 sec. and independently herefrom ventricular complexes following one another at intervals of 1.31 to about 1.48 sec., and again auricular impulses are conducted to the ventricles when they occur sufficiently late after the preceding ventricular contraction so as to reach the ventricles after their refractory period. Two features of this tracing call for special mention. The first is that the top tracing taken by itself could be interpreted as indicating an atrioventricular rhythm with gradually lengthening R-P intervals; if this interval exceeds a certain limit, the auricular contraction, itself inaugurated by the atrioventricular node, gives rise to a second ventricular contraction, the excitation wave which had traveled from the A-V node upward to the auricles, returning and stimulating the ventricles which are by then past their refractory period. This phenomenon has been described as "reciprocated beats" on several occasions (White, 1915, Gallavardin and Gravier; Drury). However, this explanation is untenable if one takes into consideration the middle tracing taken immediately after the top one. Here we see that in the two first beats negative P-waves precede the ventricular complexes, which fact makes it extremely improbable that we are dealing with an atrioventricular rhythm

57518

originating in the lower parts of the A-V node. Moreover, the time relations as shown in this tracing and in Fig. 3, which is undoubtedly indicative of a dissociation with interference, give every reason to assume that we are dealing here as well with the coexistence of an auricular and an atrioventricular rhythm and that the two rhythms are occasionally linked up by conducted auricular beats. If this con-

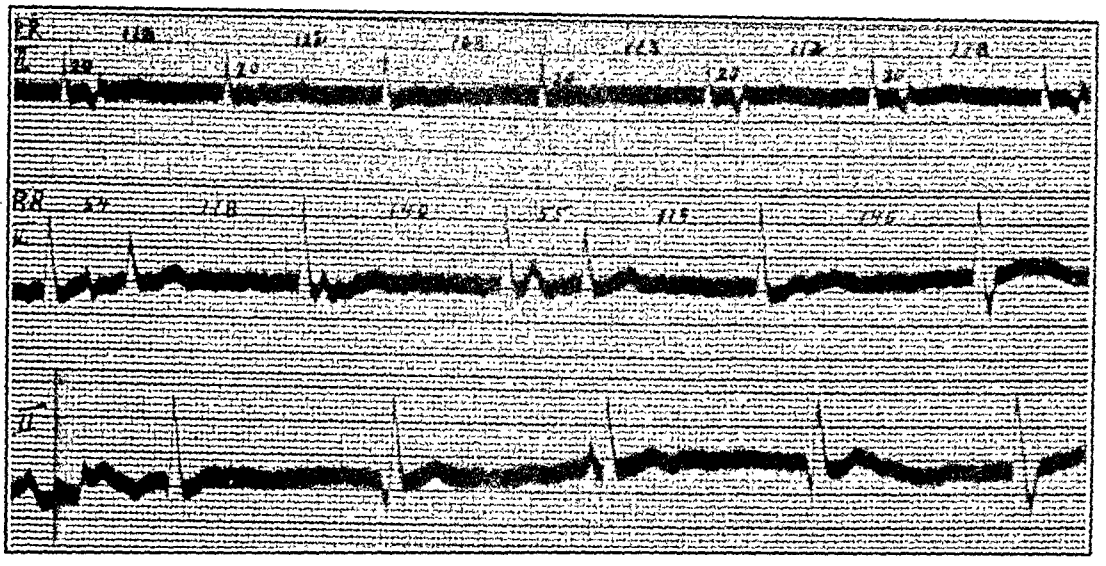

Fig. 6.—Electrocardiogram taken immediately after mild exercise test. Lead II only, top curve showing atrioventricular rhythm, middle curve showing dissociation with two conducted beats, bottom curve showing dissociation; intra-auricular disturbances of conduction in all three strips.

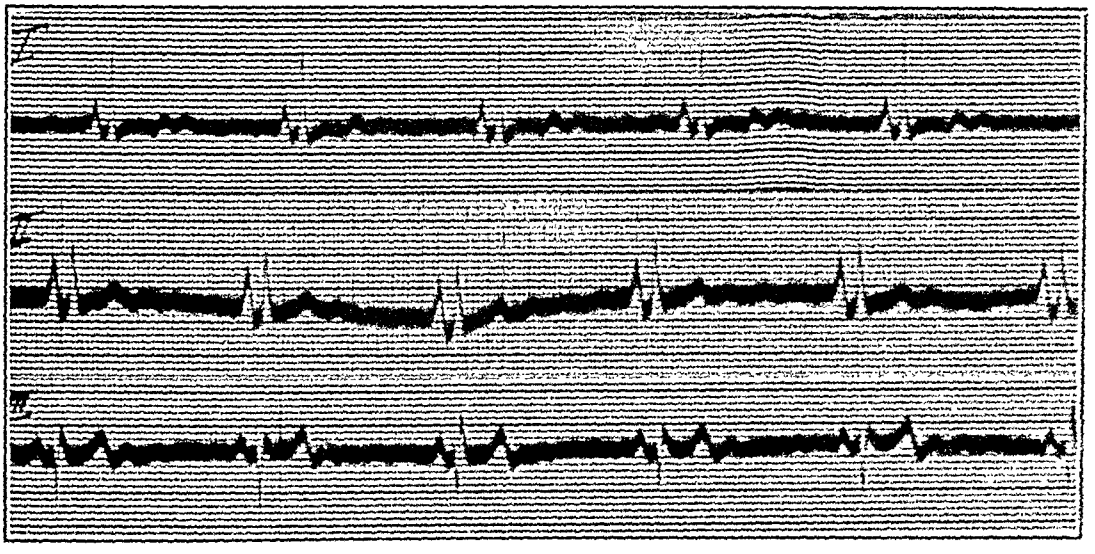

Fig. 7.—Electrocardiogram taken Oct. 30, 1935, after administration of small doses of digitalis. Leads I, II, and III. Showing sinus bradycardia.

ception is correct we have to account for the fact that here—in contradistinction to Lead II in Fig. 3—the P-waves are negative. The most reasonable explanation is that this is due to intra-auricular disturbances of conduction, and this conception receives support if one considers the result on the electrocardiogram of an exercise test, as shown in Fig. 6. All three strips represent Lead II, taken in immediate

succession. The top curve shows atrioventricular rhythm; the time intervals are shortened to 1.08 to 1.18 sec. as a result of exercise; the R-P interval is constant (0.20 sec.), but the P-waves differ in shape one from another: the site of impulse formation remaining the same, this can be due only to intra-auricular disturbances of conduction. The middle and bottom curves show that with the gradual slowing of the heart rate after the termination of the exercise test the two independent rhythms are reëstablished, but the bottom tracing shows by the varying shape of the P-waves that even then the intra-auricular disturbances of conduction persisted.

The patient was given small doses of digitalis and when I saw her again six days later sinus rhythm was restored, the electrocardiogram showing a sinus bradycardia with an average ventricular rate of 39 and a P-R interval of 0.20 sec. (Fig. 7).

DISCUSSION

One of the fundamental laws of the action of the heart is that the heart follows that pacemaker which forms impulses at the highest rate. Thus, as normally the sino-auricular node possesses the highest automaticity, the rhythm of the normal heart is the sinus rhythm. If, however, impulses originate at a higher rate in the atrioventricular node than in the sino-auricular node—this may occur as the result of either an abnormally great irritability of the atrioventricular node or of a depression of the normal impulse formation in the sino-auricular node—then the heart will follow the rhythm set up by the atrioventricular node. If there is no retrograde block, the excitation wave will spread to the auricles as well as to the ventricles, and the result is atrioventricular rhythm (Fig. 4). If, however, the spread of the excitation wave to the auricles is blocked ("reversed block"), then the auricles will be stimulated by the sino-auricular node (which, as the result of the block, is not reached by the impulses originating in the atrioventricular node) and the ventricles only will be stimulated by the atrioventricular impulses. In this condition there is therefore a dissociation of the cardiac mechanism present, characterized by the coexistence of a ventricular rhythm of a higher rate, originating in the atrioventricular node, and a sino-auricular rhythm of a lower rate, originating in the sino-auricular node. Most of the sino-auricular impulses will fail to yield a response from the ventricles because they reach the ventricles within their refractory period. However, as the rate of the impulse formation in the sino-auricular node in such a case is lower than that in the atrioventricular node, there will be a continuous shifting of the two rhythms, and those sino-auricular impulses which reach the ventricles outside their refractory period will

yield a ventricular contraction and at the same time, while traveling through the junctional tissues, will interfere with the formation of impulses in the atrioventricular node. The result is that with these conducted sino-auricular beats, and with these only, the two rhythms are linked with one another. The next atrioventricular beat following such a conducted sino-auricular beat usually occurs after a time interval corresponding to the rate of impulse formation in the atrioventricular node because the conducted impulse had temporarily disturbed the atrioventricular impulse center. This interval, however, may be shortened for reasons discussed below in connection with the present case.

Such a condition characterized by the coexistence of a faster atrioventricular and a slower sino-auricular rhythm with occasional interference of the slower with the faster rhythm has been originally described by Wilson and by White; it has become more universally recognized as an arrhythmia sui generis by the extensive studies of Mobitz, who called this condition "Interferenzdissoziation." In English one might call it dissociation with interference, in analogy to Wenckebach's terminology, *Dissoziation mit Interferenz.*

On ordinary clinical examination this condition is bound to be mistaken for a case of normal sinus rhythm with occasional extrasystoles. Auscultation reveals a regular somewhat slow rhythm with occasional premature beats. It will be clear from the foregoing analysis, however, that the regular rhythm is in reality the atrioventricular rhythm and that the premature beats are not ectopic beats, but the conducted sino-auricular beats.

The present case presents several individual features of interest. As to the underlying mechanism, we know in this case that for the last eleven years at least there was a sinus bradycardia, as verified by electrocardiograms, so that we have every reason to assume that there has been for years an interference with the normal impulse formation in the sino-auricular node. The cause of the temporarily increased activity of the atrioventricular node remains unknown, however. Second, from a clinical point of view, it is important to note that small doses of digitalis lead to a symptomatic cure. The only complaints of the patient were "palpitations," and these were caused by the arrhythmia produced by the "interfering" conducted auricular impulses. The effect of digitalis in this case was to depress the impulse formation in the atrioventricular node so that its automaticity became again less than that of the sino-auricular node, with the result that sinus bradycardia of a rate of about 38 was restored. With the abolition of the arrhythmia the palpitations disappeared, and the patient lost the discomfort. This effect of *small* doses of digitalis is the more

remarkable, as in many of the previously described cases exhibiting this type of arrhythmia the condition had been *caused* by *large* doses of digitalis.

It is worth noting that a mild exercise test (10 times sitting up) caused the rate to increase to 42, sinus rhythm persisting.

From a physiological point of view the fact mentioned above, that the interval following a conducted auricular impulse was shorter than the interval between two atrioventricular beats, calls for special explanation. This phenomenon was first described by Scherf, and the explanation given for his case seems not only to be the adequate one for this case, but also to receive additional support by it. If the conducted impulse traveling through the junctional tissues temporarily interferes with the impulse formation in the atrioventricular node, the impulse formation in the atrioventricular node begins again at a moment when the conducted impulse has left the A-V node. This moment practically coincides in most cases with the moment in which the activation of the ventricles starts, as indicated in the electrocardiogram by the onset of the ventricular complex, because the conduction of the impulse through the bundle of His and the lower parts of the junctional tissues is fast. Therefore the interval between the conducted beat and the following atrioventricular beat is approximately equal to the interval between two atrioventricular beats. For those cases, however, in which the interval after the conducted beat is materially shortened, Scherf assumes a disturbance of, and delay in, conduction of the excitation wave of the conducted beat through the bundle of His. The result of this delay is that an abnormally long interval elapses between the moment when the excitation wave of the conducted beat leaves the atrioventricular node and when it activates the ventricles. The formation of the next atrioventricular impulse however starts when the excitation wave of the conducted beat has left the atrioventricular impulse center. By the time this atrioventricular impulse travels through the bundle, the junctional tissues have had sufficient time to recover, and this next excitation wave reaches the ventricles in the normal time, thus leading to the shortening of the interval following the conducted beat. Scherf gives good reasons for this assumption, and the present case exhibits features which may be quoted as additional support: viz., electrocardiographic evidence of disturbances of conduction of various kinds: the conducted beats show a lengthening of the P-R interval to as much as 0.32 sec. as against 0.20 sec. during sinus bradycardia; the ventricular complexes of the conducted beats have a different shape from the atrioventricular ones due to aberrant conduction; and last, there are the differences in the shape of the P-waves indicative of intra-auricular disturbances of conduction.

SUMMARY

A case of dissociation with interference of the heart is described and the underlying mechanism of the arrhythmia is discussed.

The special features of the case are:

For the last eleven years at least sinus bradycardia was present, as shown by the history and verified by electrocardiograms.

There was electrocardiographic evidence of disturbances of conduction both in the bundle of His and in the auricles.

Atrioventricular rhythm occurred at times, the impulses originating in the lower parts of the atrioventricular node, stimulating the auricles as well as the ventricles.

Small doses of digitalis effected a symptomatic cure.

REFERENCES

Drury: Heart 11: 405, 1924.
Gallavardin and Gravier: Arch. des mal. du coeur 14: 71, 1921.
Lewis: Heart 1: 262, 1909-10; 2: 23, 1910-11; 3: 279, 1911-12.
Mobitz: Deutsches Arch. f. klin. Med. 141: 257, 1923; Ztschr. f. d. ges. exper. Med. 34: 490, 1923.
Scherf: Wien. Arch. inn. Med. 12: 327, 1926.
White: Arch. Int. Med. 16: 517, 1915; 18: 244, 1916; 28: 213, 1921.
Wilson: Arch. Int. Med. 16: 989, 1915.

THE ELECTROCARDIOGRAM DURING AND AFTER EMERGENCE FROM DIABETIC COMA*

SAMUEL BELLET, M.D., AND W. WALLACE DYER, M.D.
PHILADELPHIA, PA.

ALTHOUGH both clinical and necropsy observations suggest that the heart is severely deranged in diabetic coma, electrocardiographic evidence of such derangement has not been frequently or consistently found. Previous studies of the electrocardiographic changes that develop during severe diabetic acidosis have led to somewhat inconsistent and contradictory conclusions. Certain observations suggested to us that rather marked and, on the whole, consistent alterations of the T-waves and lengthening of the Q-T interval were present during certain stages of diabetic coma, not as one might expect at the height of the coma, but rather after the acidosis had been partially or even completely controlled. These observations led us to study the matter carefully in a series of seventeen cases of diabetic coma and six cases of "precoma," the result of which is the subject of this report.

LITERATURE

Hepburn and Graham[7] in 1928 made electrocardiographic studies in 123 cases of diabetes mellitus and concluded that none of the patients with severe acidosis showed an abnormal electrocardiogram. Taterka[15] in 1929, studying cases of diabetic coma, observed extrasystoles and a diminution in the amplitude of all deflections; the changes affected particularly the T-waves, which were either depressed or entirely negative. This author felt that the condition of the heart before the onset of coma was an important factor in the production of these changes and that these changes were more marked the longer the duration of the coma and the greater its severity. Unfortunately the published paper includes no electrocardiographic records. Smith and Hickling[13] studied electrocardiographically a group of 20 patients, all of whom had severe diabetes with varying degrees of ketosis but without actual or impending coma. Tracings were taken before treatment was begun and at intervals of from two to seven days thereafter. Of these 20 individuals, 2 showed inverted T-waves in Lead I; and 2, inverted T-waves in Lead II; in all 4 instances these waves became upright after treatment. Alterations of the T-waves of Lead III, more or less marked, occurred in 11 of the 20 patients. Faulkner and Hamil-

*From the Division of Cardiology and the Division of Metabolism of the Philadelphia General Hospital and the Robinette Foundation for the Study of Cardiovascular Diseases of the University of Pennsylvania.

ton[4] were of the opinion that there were no published data to indicate that the degree of acidosis reached in disease is sufficient to cause profound electrocardiographic disturbances. These authors made electrocardiographic studies of 15 cases of diabetic coma, the procedure being to take an electrocardiogram immediately on admission in coma and a control record from one to eight days later. They found the electrocardiogram to be within normal limits in 9 cases, while in 4 the only abnormal features (diaphasic T_1 or T_2 or both) might be explained by overshooting, due to high skin resistance. Only two patients showed minor T-wave changes which could not be explained in this manner. They concluded that "electrocardiographic changes are not the rule in diabetic coma and when present they consist of minor abnormalities which are not likely to be confused with or to mask the picture of coronary occlusion." As far as we are aware, Klingenberg[8] is the only author who has felt that there were consistent electrocardiographic changes during and following severe diabetic acidosis. He observed normal electrocardiograms in only one of ten patients in diabetic coma.

METHODS

The 17 patients of our series were studied electrocardiographically as soon as feasible after their admission to the hospital. In thirteen cases the first electrocardiogram was taken within one to six hours after admission in coma; in 2, within six to twelve hours: in 3, between twelve and twenty-four hours; and in one case, thirty-eight hours after admission. The first electrocardiogram in two-thirds of the cases was therefore taken within a comparatively short time after admission while the patient was still in a state of acidosis, but, in almost all instances, not before the patient had received varying amounts of insulin, glucose, and fluids. Tracings were made every day at 10:00 A.M. and 4:00 P.M. as long as electrocardiographic changes were present (usually for from four to six days) to determine whether certain changes might be present in the postacidotic period as well as during coma. During the remainder of the stay in the hospital, usually for more than a month, tracings were taken once a day.

MATERIAL

Seventeen patients in diabetic coma and 6 in precoma were studied in the manner discussed above; 2 of the 17 were studied during two periods of coma. The series was not at all selected, the cases included representing successive admissions to the hospital. All of these showed the well-known clinical picture: subnormal temperature, rapid pulse, Kussmaul respiration, moderate or marked hyperglycemia, with ketosis and a plasma carbon dioxide combining power of the blood of 20 volumes per cent or less. In 9 of the 17 cases the coma during and following which we made our studies constituted the first recognized

TABLE I

CHEMICAL DATA

NO.	NAME	DATE OF ADMISSION	AGE	COLOR	SEX	HR. IN ACIDOSIS BEFORE ADMISSION (ESTIMATED)	HR. IN ACIDOSIS AFTER TREATMENT STARTED	ADMISSION BLOOD SUGAR (MG./100 C.C.)	ADMISSION (CO_2 VOL. %)	ADMISSION UREA N (MG. 100 C.C.)	ADMISSION PLASMA CHLORIDES (MG. 100 C.C.)	TOTAL UNITS INSULIN ADM. DURING ACIDOSIS	TOTAL FLUID AS N. S. S. (C.C.)	TOTAL SODIUM BICARB. (GM.)	TOTAL GLUCOSE (GM.)	COMPLICATIONS
1	M. B.	8/26/35	35	W	F	5	10	864	20	17	524	316	3000	0	65	Enteritis
2	W. B.	6/ 5/35	43	B	F	24	14	300	16	16	608	145	6500	36	275	Carbuncle
3	E. B.	5/24/35	24	W	M	24	19	816	14	48	492	205	7100	5	104	None
4	J. B.	1/ 6/35	20	W	M	48	3	904	15	30	474*	120	3000	8	30	None
5	F. C.	1/20/35	39	B	F	8	12	1024	15	63	—	430	4450	29	50	None
6	B. C.	6/18/35	42	B	F	96	6	992	19	38	508	130	4500	30	30	None
7	C. C.	1/30/35	16	B	F	30	10	680	13	19	524	280	3170	32	110	None
7a	C. C.	9/ 6/35	16	B	F	96	20	352	14	11	615	430	3650	14	210	None
8	N. D.	12/23/34	21	B	F	48	10	1850	13	95	430*	660	5000	30	90	Pneumonia
9	C. D.	3/29/35	42	W	F	48	7	612	12	35	—	180	4900	32	120	None
10	E. F.	12/10/34	57	W	M	12	9	756	13	12	434*	270	2600	13	230	None
11	J. G.	7/27/35	20	B	M	24	8	808	12	30	526	250	3000	43	90	None
11a	J. G.	5/ 6/35	20	B	M	24	8	800	14	35	468	90	2500	32	60	None
12	L. J.	9/ 6/35	48	B	F	24	64	848	11	21	568	490	4500	—	215	None
13	J. P.	3/20/35	22	B	M	60	8	1056	14	43	—	220	5000	43	90	None
14	G. R.	3/20/35	31	W	F	24	15	548	17	14	534	230	5400	32	180	None
15	B. R.	2/ 1/35	61	B	F	8	11	736	18	30	564	335	4800	30	160	Sepsis
16	M. W.	9/ 9/35	46	W	F	48	54	912	11	34	—	490	4250	—	125	None
17	F. Y.	2/ 5/35	38	B	F	8	7	708	12	15	554	240	3800	30	120	None

*Whole blood chloride.

evidence of diabetes. In the remaining patients, all of whom were known to be diabetic, coma in each instance resulted from failure to follow the advised dietary and insulin program. In addition to the 17 cases, we also studied in a similar manner 7 cases of precoma. Although the data obtained in the precoma cases are not included in our tables, a brief summary of the findings in this group is included in the results of this study.

Complications.—Complications were unusually infrequent in our series of cases. One patient (Case 2) developed post-coma lobar pneumonia, from which she made an uneventful recovery, and another (Case 6) died fifty-four days after admission from dermatitis gangrenosa and a severe urinary tract infection.

Age, Sex, and Race.—Twelve of our 17 patients were females and 5 were males. Ten were white, and 7 were colored. The ages ranged from seventeen to sixty-one years, the average of the entire group being thirty-five years. According to age groups, they can be arranged as follows:

10-20 yr.	21-30 yr.	31-40 yr.	41-50 yr.	51-60 yr.	61-70 yr.
3	3	4	5	1	1

Cardiovascular Status.—The estimate of the cardiac and circulatory systems was arrived at by examining the patients after their acidosis had been alleviated. The clinical and graphic studies made at the time of discharge led us to conclude that the heart, blood pressure and arterial systems were within normal limits in 14 of the 17 cases. In one of the remaining 3 cases, clinical examination revealed no evidence of disease, but inverted T-waves were present in Leads II and III of the electrocardiogram. In a second case the heart was not abnormal, but the patient showed a rather pronounced generalized arteriosclerosis. In the third instance there was a slight cardiac enlargement; a soft, systolic murmur was audible at the apex; and the blood pressure was 154/96 at the time of discharge from the hospital. No drugs belonging to the digitalis group were administered during the period of our observation except strophanthin, gr. $\frac{1}{100}$, given intravenously in two divided doses in Case 6.

Treatment.—All our patients received routine chemical studies consisting of the frequent determination of the blood sugar, the carbon dioxide combining power of the plasma, the urea nitrogen concentration of the blood, and the plasma chloride values. The routine treatment of diabetic coma was applied to all cases of our series. Insulin, in total amounts from 90 to 661 units, the average being 311, was administered during the period of acidosis. Fluids in the form of normal saline solution were always given either subcutaneously or intravenously in average total amounts of 4,186 c.c. during the period of acidosis. Glucose was given freely, orally, subcutaneously, or intravenously in average total amounts of 126 gm. Sodium bicarbonate

was administered through a retained gastric tube in quantities varying from 5 to 43 gm. during the period of acidosis in all except Cases 1, 12, 14, 15, and 17. Acacia was given intravenously in Case 8. When the carbon dioxide combining power had risen to 45 volumes per cent, the patient was considered to have recovered from acidosis.

ELECTROCARDIOGRAPHIC CHANGES

Electrocardiographic changes, more or less marked, were observed in all the seventeen cases of our series; in the second admission for coma of Case 7 the alterations were insignificant. Although there were slight alterations in the P-waves, the P-R intervals, and the QRS complexes, these were of minor importance. The striking changes that we wish to emphasize were observed in the T-wave and the Q-T interval. The T-wave changes were remarkable for their consistency, so much so that in typical cases they might be regarded as almost characteristic. The abnormalities were transient, usually reaching their maximum development not during coma but after coma. The changes disappeared in all but one instance. In Case 3 inverted T-waves in Leads II and III, although undergoing changes in form, tended to persist. Unfortunately we have no control electrocardiogram before the onset of coma in this case. The time interval from admission in diabetic coma to complete return to normal varied from three to ten days, the average being five days. In seven cases of this series electrocardiographic changes were again observed after the electrocardiogram had initially returned to normal, the changes being quite marked in three of these. The electrocardiograms of the patients in this group ultimately returned to normal except in Case 6, in which the electrocardiogram, having returned to normal after the acidosis had been controlled, later presented marked T-wave changes so that the electrocardiogram at discharge could not be considered normal. In the cases just referred to, in which the electrocardiograms after initial return to normal varied on successive days, the tracings taken in the afternoon showed marked improvement over those taken in the morning. We are not able, definitely, to explain this finding. In nine cases sudden electrocardiographic changes were observed to appear in a comparatively short period of time. In two cases (Cases 14 and 15) marked changes were observed in the space of two hours.

Some difficulty in taking an electrocardiogram was occasionally experienced by reason of the high skin resistance presented by the patients in coma. However, by the use of salt, pumice, and tragacanth paste and by brisk and repeated rubbing, we were able to obtain tracings which on the whole were quite satisfactory.

The high rate in the initial electrocardiogram (120 to 150 per minute) at times rendered the accurate determination of the Q-T intervals difficult.

The alterations which were noted will now be presented in detail.

T-Waves.—The T-wave changes in diabetic coma and upon emergence from this state were remarkable, not only for the presence of marked deviations from the normal, but for the completeness with which these altered waves returned to normal. In many instances the T-waves upon admission in diabetic coma showed little change from the normal

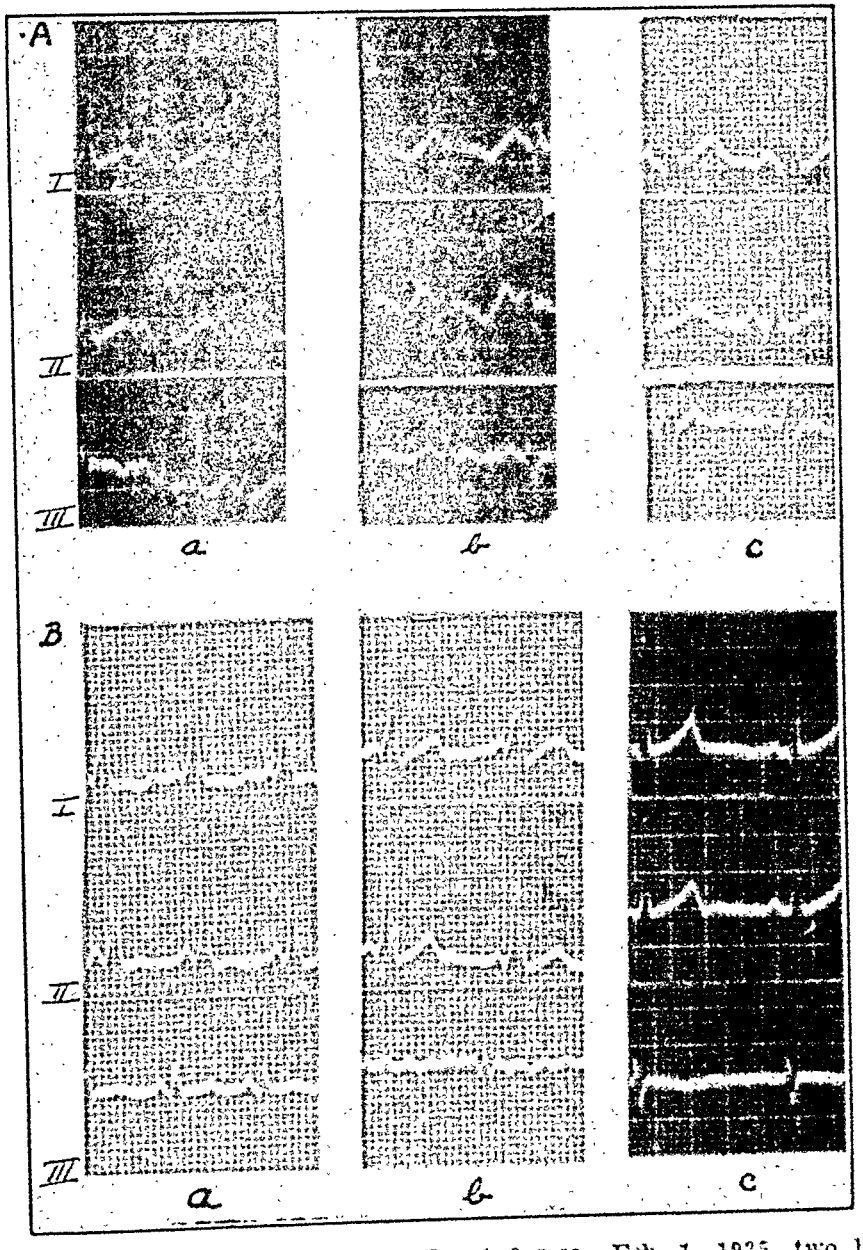

Fig. 1.—*A* (Case 15): *a*, tracing made at 9 P.M., Feb. 1, 1935, two hours and twenty minutes after admission in coma, shows slight tachycardia and upright T_3 and T_2 of somewhat diminished amplitude; *b*, tracing made Feb. 2, 1935, at 9:45 A.M., thirteen hours after *a*, when the patient was out of acidosis and clinically better, shows inverted T_1 and T_2 and a long Q-T interval; *c*, tracing made Feb. 5, 1935, four days after admission in coma. This tracing is now practically normal.

B (Case 11a): *a*, tracing made May 6, 1935, at 12 M., ten hours after admission in coma—patient had been out of acidosis for two hours. Note inverted T_3, low amplitude T_2, short P-R interval and prolonged, slurred QRS complexes. *b*, Tracing made May 7, 1935, at 2:50 P.M. Note that T_3 and T_2 are now upright but that the P-R intervals are still short and the QRS complexes prolonged. *c*, Tracing made May 31, 1935, at 10 A.M., normal.

(Fig. 1); subsequent electrocardiograms taken twenty-four hours after admission showed marked T-wave alterations, the T-wave becoming

either inverted or the S-T interval being markedly depressed, and usually being associated with prolongation of the Q-T interval. A gradual return of the T-wave to normal occurred in most cases. A rather sudden return was observed in others. The following types of changes were noted: elevation of the S-T interval (2 cases); inverted, changing to depressed T-waves (3 cases); low amplitude (2 cases); in another case they were unchanged. The most frequent change observed was depression of the S-T interval accompanied by an alteration in the T-wave (Fig. 2*Aa*, and Fig. 3*b*). This T-wave change might be regarded as almost typical. This depression is not unlike that observed as the result of the action of digitalis, with the notable difference that in these cases the S-T interval is prolonged, whereas in the T-wave produced by digitalis it is shortened.[3] In the few cases

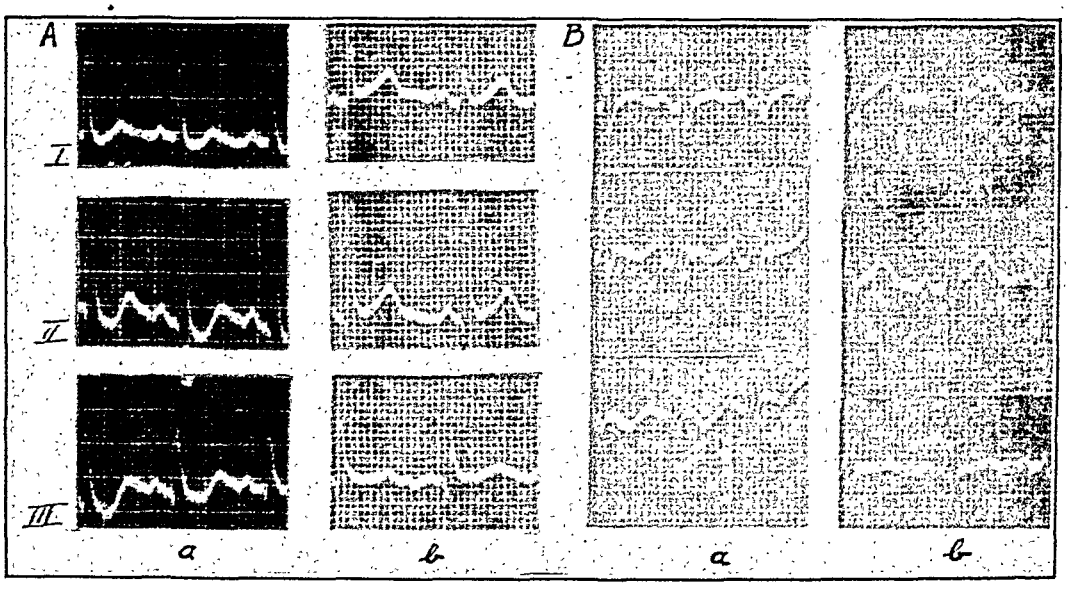

Fig. 2.—*A* (Case 5): *a*, tracing made Jan. 21, 1935, at 11:55 A.M. (twenty-five hours after admission in coma); patient had been out of acidosis for nineteen hours. S-$T_{I,II,III}$ are depressed. The Q-T interval is prolonged. *b*, Tracing made Jan. 22, 1935, at 11:10 A.M., twenty-four hours later. Note that this electrocardiogram is now practically normal.

B (Case 7): *a*, tracing made Jan. 31, 1935, at 5 P.M., (twenty-three hours after admission in coma); patient had been out of acidosis for thirteen hours. Note low amplitude of T_1 and inverted T_2 and T_3. *b*, Tracing made Feb. 1, 1935, at 3:15 P.M., is now practically normal.

in which the Q-T interval was not prolonged, the S-T depression was practically indistinguishable from stage 2 or 3 of a digitalis S-T depression.[10] These changes were most marked in Leads II and III although all three leads were not infrequently involved. The changes in Lead III, however, were frequent and characteristic. When a reversion to normal occurred, Lead I was the first to show this change and Lead II followed.

Q-T Intervals.—The Q-T interval has been used as a measure of electrical ventricular systole.[2] White and Mudd[16] found the Q-T intervals to be prolonged in bundle-branch block, in the presence of low blood

serum calcium, in ventricular paroxysmal tachycardia and in auricular paroxysmal tachycardia. Von Haynal[5] and Schaffer, Bucka and Friedlander[12] observed lengthening of this interval following the administration of insulin. Lengthening of the Q-T interval was a

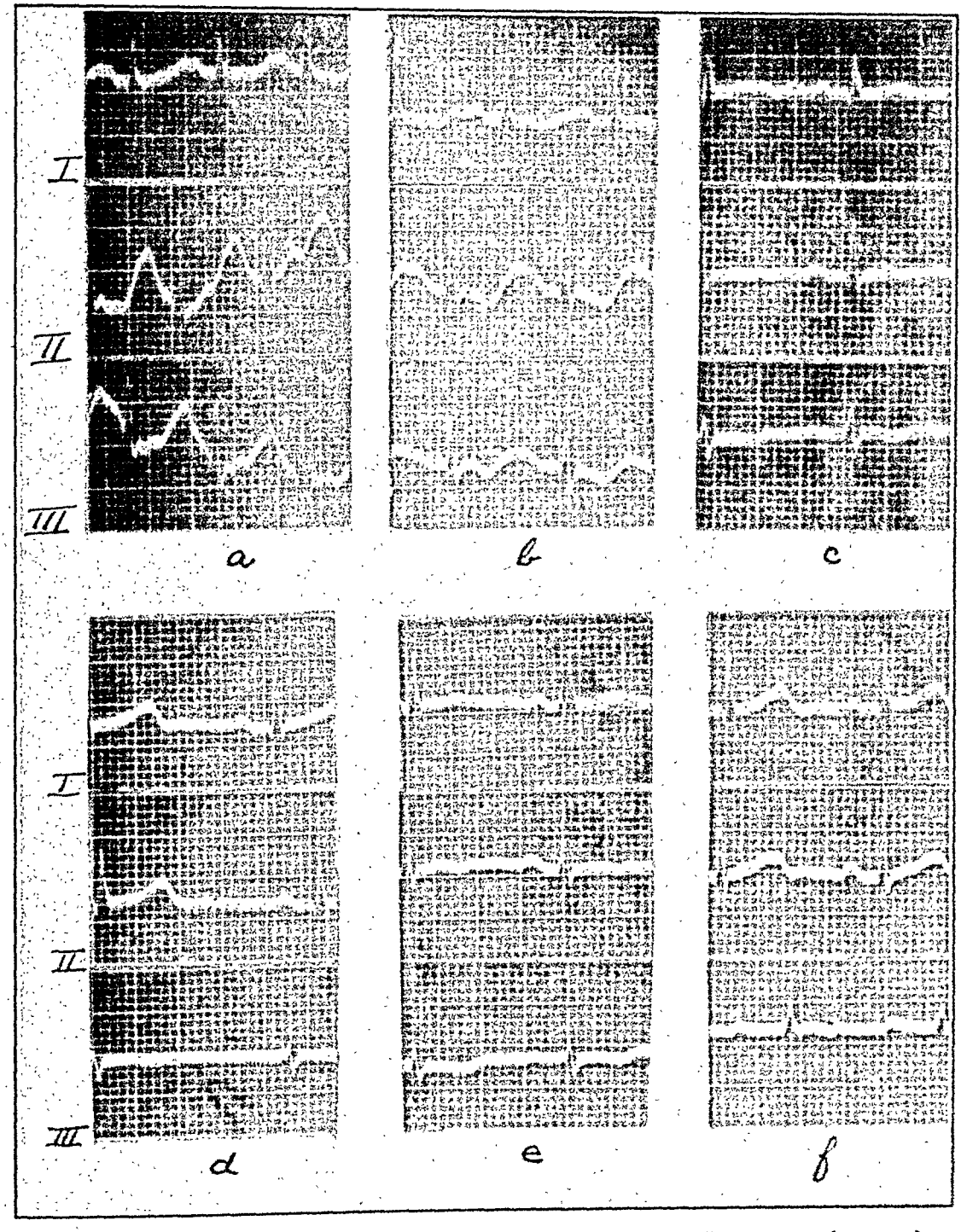

Fig. 3.—(Case 14): *a*, tracing made March 20, 1935, at 3:55 P.M., two hours after admission, patient in coma. Note S-T interval depression in Lead I, rather bizarre T_2 and T_3 and a long Q-T interval. *b*, Tracing made March 21, 1935, at 5:25 P.M., patient had been out of acidosis for 10.5 hours. T_1, T_2 and T_3 are inverted; the Q-T interval is prolonged. Subsequent tracings showed gradual improvement with return to normal. *c*, Tracing made March 27, 1935, at 9:45 A.M. The T-waves in Leads I and II are now upright but of low amplitude; T_3 is flattened. *d*, Tracing made March 27, 1935, at 4:10 P.M. shows T_1 and T_3 upright and of normal amplitude. Normal tracing. *e*, Tracing made March 28, 1935, 10:38 A.M., 18.5 hours after *d*, again shows a tracing similar to *c*. *f*, Tracing made March 28, 1935, 4:05 P.M., 5.5 hours after *e*, is again normal.

prominent finding in the cases of diabetic coma that we studied. According to the formula of Bazett,*[1] $S = K \sqrt{C}$ as a measure of the normal Q-T interval, our results indicated that it was prolonged from 20 to 50 per cent above its normal value in thirteen of our seventeen cases. In Case 3, this finding constituted the only definite electrocardiographic change observed. Its presence is often difficult to determine clearly in the initial electrocardiogram because of the high ventricular rate. The change was observed not only during actual coma, but it usually persisted for from three to five days after the acidosis had been effectively controlled. The return to normal was usually gradual, but at other times it was quite abrupt, a prolonged interval returning to normal (Case 15) in a space of six hours. The prolongation of the Q-T interval was present for one or two days in thirteen of our seventeen cases.

P-Waves and P-R Intervals.—The P-waves were normal in all but three cases. Of these one showed an extremely tall P-wave on the day after admission; another showed a bifid P-wave on the third day after admission; a third showed on the day of admission auricular flutter which gave way to a normal rhythm in twelve hours.

The P-R intervals were normal except in 2 cases; in one (Case 7a) the P-R interval was prolonged to 0.22 sec. on the third day after admission; in the other (Case 11 and 11a) there was a short P-R interval (0.06 sec.) with a prolonged QRS complex, which abnormality lasted six and seven days on the first and second admissions, respectively (Fig. 1, *B*).

QRS Complexes.—The QRS complexes were normal in all but 3 cases. In one (Case 3), as the patient emerged from coma, an initial low amplitude of R_1 changed to a higher amplitude in tracings taken from four to six days after emergence from coma. Slight slurring of the QRS complexes was observed on the second day in Case 13. The presence of short P-R intervals with prolonged QRS complexes for six and seven days, respectively, in the same patient on two different admissions in coma (Case 11) has been discussed under P-R interval changes.

Arrhythmias.—A normal sinus rhythm was present in all cases except for the presence of a transient auricular flutter in one patient (Case 10). In another patient, ventricular extrasystoles were observed on the third day after emergence from the coma (Case 13), and auricular extrasystoles were observed on the first day in a third case (Case 17).

Relation of Maximum Electrocardiographic Changes to Acidotic State.—Although the electrocardiographic studies in thirteen cases were made from two to six hours after admission in coma, the most marked electrocardiographic changes were observed, not in the first electrocardiogram while the patient was still in coma, but at a slightly later

*In this formula S = length of systole; K = a constant; C = cycle length.

TABLE II

ELECTROCARDIOGRAPHIC FINDINGS

CASE NUMBER	RATE PER MINUTE IN INITIAL EKG.	INTERVAL BETWEEN ADM. & INITIAL EKG. (IN HR.)	DURATION OF ACIDOSIS AFTER ADMISSION (IN HR.)	INTERVAL BETWEEN ADM. & MOST ABNORMAL EKG. (IN HR.)	INTERVAL BETWEEN ADM. & RETURN TO NORMAL EKG. (IN DAYS)	IMPORTANT ELECTROCARDIOGRAPHIC CHANGES
1	120	6	10	29	8	Elevated S-T intervals in Leads II and III; Q-T interval, not prolonged.
2	107	38	4	38	7	Depressed S-$T_{1,2}$; Q-T interval, normal.
3	100	4	19	22	6	Q-T interval, prolonged 3 days; bifid $T_{1,2}$; inverted T_2 became upright on 13th day and again inverted on 14th day after admission.
4	125	23	3	23	3	Inverted T_1; depressed S-$T_{2,3}$; the ekg. became practically normal within 24 hours; Q-T interval, prolonged 2 days.
5	115	25	12	25	3	Depressed S-T in all leads; within 24 hr. ekg. became practically normal; Q-T interval, prolonged 1 day.
6	140	2	6	35	6	After initial depression of S-T intervals, $T_{1,2}$ became deeply inverted; Q-T interval, prolonged for 1 day.
7	142	2	10	24	2	Ekg., normal during acidosis; T_1 low and $T_{2,3}$ inverted, 24 hr. later (alteration present only 24 hr.); Q-T interval, prolonged 2 days.
7a	120	7	20			No ekg. changes during second admission.
8	140	21	10	21	10	Depressed S-$T_{2,3}$; Q-T interval, prolonged 3 days.
9	140	2	7	23	7	Depressed S-T, all leads; after initial return to normal, T-waves were higher in P.M. than in A.M. on several successive days (see text); Q-T interval, prolonged 2 days.
10	140	3.5	9	8.5	3	Transient auricular flutter; depressed S-$T_{2,3}$; Q-T, prolonged 3 days.
11	140	4	8	24	6	Ekg., entirely normal during acidosis; 24 hr. later, P-R became short and QRS widened; these changes continued 6 days; Q-T, not affected.
11a	120	10	8	12	7	Short P-R with widened QRS, present in first ekg. and continued for 7 days; $T_{1,2}$ upright in 1st ekg. and inverted 2 hr. later, without changes in QRS; Q-T interval, not prolonged.
12	120	1.5	64	2	4	Elevated S-$T_{1,2}$; bifid $T_{1,2}$; Q-T, prolonged 4 days.
13	125	3	8	3.18	3	Depressed S-T intervals in all leads; ventricular extrasystoles on 3rd day; Q-T interval, prolonged 2 days; after initial return to normal, frequent transient T-wave varieties.

TABLE II—CONT'D

CASE NUMBER	RATE PER MINUTE IN INITIAL EKG.	INTERVAL BETWEEN ADM. & INITIAL EKG. (IN HR.)	DURATION OF ACIDOSIS AFTER ADMISSION (IN HR.)	INTERVAL BETWEEN ADM. & MOST ABNORMAL EKG. (IN HR.)	INTERVAL BETWEEN ADM. & RETURN TO NORMAL EKG. (IN DAYS)	IMPORTANT ELECTROCARDIOGRAPHIC CHANGES
14	150	2	15	16	7	Inverted T-wave and depressed S-T intervals in all leads; Q-T interval, prolonged 4 days; after initial return to normal T-waves were frequently taller in P.M. than in A.M. (see text).
15	125	2	11	13	4	Inverted T-waves and depressed S-T intervals in all leads; Q-T interval, prolonged 2 days; transient alterations of T-waves after initial return to normal.
16	120	1.5	54	20		Depressed $S\text{-}T_{1,2}$; this transiently reappeared after initial return to normal; Q-T intervals, not lengthened.
17	110	1	7	17	7	Depressed $S\text{-}T_{1,2}$; after initial return to normal, this reappeared transiently; Q-T prolonged for 4 days.

period when the patient was usually out of acidosis and appeared clinically improved. The most abnormal electrocardiogram in these thirteen cases was observed about twenty-four hours after admission. Of the remaining cases of the series, in Case 11a, the most abnormal electrocardiogram was observed twelve hours after admission, the first electrocardiogram having been taken two hours previously. Of the remaining four cases the most abnormal electrocardiogram was taken twenty-one to thirty-eight hours after admission. Thereafter the electrocardiogram tended to return gradually to normal. After a return to normal had taken place, other changes which will be discussed subsequently were observed.

The electrocardiograms of seven cases of precoma were studied in a manner similar to the cases of coma. In one of these cases the administration of digitalis complicated the electrocardiographic picture so that the results in six cases will be briefly recorded. The electrocardiographic changes were in every way similar, although slightly less marked than those observed in the case of patients in diabetic coma. Marked changes were observed in one case, moderate changes in four, and slight changes in one case. The Q-T interval was prolonged in every case; in one patient (Case 6P) the prolongation lasted eleven days, which was a longer period than in any other case of the entire series. The S-T interval was depressed in 5 cases and the

T-wave inverted in one case. In one case (4P) the T-waves were inverted in Leads I, II, and III and after a month had not yet returned to normal.

The explanation for the presence of the most marked electrocardiographic changes approximately twenty-four hours after admission is not entirely clear. It has been stated by Master and his associates[9] that in pneumonia the most abnormal electrocardiographic changes were obtained during the period of convalescence. It is quite possible that the maximum amount of myocardial derangement occurs many hours after inception of the acidosis. A parallel might be drawn with coronary occlusion in which the cardiac damage and the electrocardiographic findings may be most marked from twenty-four to forty-eight hours after the occlusion. The suddenness and completeness of return to normal in these cases, sometimes in the space of a comparatively few hours, is an incident the like of which we are not acquainted with in other cardiac states.

That the severity of the electrocardiographic changes is independent of the condition of the heart before the coma is indicated by the fact that the electrocardiographic changes were as frequent and as severe in the younger patients, in whom the hearts were apparently normal, as in the older diabetics with myocardial disease.

DISCUSSION

The marked electrocardiographic changes that we have described can be only the result of myocardial derangement. The striking feature of the alterations is their usual brief and transient nature. This would suggest that the myocardium is not permanently changed: that the effects are upon function rather than upon structure, as a rule. However, the changes are not always transient and reversible. This is indicated by Case 4P, in which the electrocardiogram continued to be abnormal for at least one month after the acidotic state had been completely controlled and also by the fact that the myocardium of individuals dying during diabetic coma is often markedly degenerated at necropsy.

This behavior suggests that the altered metabolic processes incident to diabetic coma, although usually affecting the function of the myocardium and therefore being reversible,* may, if they are long continued or very severe or if the muscle is for some reason particularly susceptible, alter the structure of the myocardium permanently and severely.

However, when an attempt is made to determine the factor or factors present during diabetic coma that are specifically responsible for the alteration of the myocardium, one is faced with a very complex

*The terms "reversible changes" and "irreversible changes" and their relation to functional and organic changes have recently been discussed by Bentley and Cowdry.[7]

problem, for many chemical and metabolic processes both intracellular and extracellular are profoundly altered during this state. Among the factors which may affect the myocardium are (1) acidosis per se, (2) the disturbances in electrolytes, especially sodium chloride, (3) alteration in the circulating blood volume, (4) dehydration, (5) the presence of azotemia, and finally (6) the effects of the various therapeutic procedures. Of these, insulin is perhaps most important, although the administration of normal saline, glucose, and sodium bicarbonate should also be considered. We have no personal observations nor have we found in the literature any evidence to commit definitely one of these factors as responsible for the alterations in the electrocardiogram. Any discussion on the possible rôle of these factors would therefore be largely hypothetical. We do, however, wish to consider briefly the possible rôle of insulin, for the reason that we have some data which indicate that it itself is not causative of the changes observed.

Insulin was administered in most cases in large doses during coma, often 50 to 100 units having been given before the first electrocardiogram was taken. That insulin can produce electrocardiographic changes coincident with the production of hypoglycemia is well established.[5, 11, 12, 14] Studies by Schaffer, Bucka, and Friedlander[12] von Haynal, Vidovsky, and Györgi,[6] and Soskin, Katz, Strouse, and Rubinfeld[14] have been reported in which the administration of insulin immediately covered by sufficient glucose to prevent hypoglycemia in a patient with cardiovascular disease also resulted in electrocardiographic changes. These alterations have been ascribed by these workers to the direct effect of insulin upon the myocardium. In spite of the conclusions of these authors, there are several reasons that lead us to feel that the changes observed by us, which were more marked and of a different character, cannot be attributed to the action of insulin per se. In the first place, in some of our patients, as in the series of Taterka,[15] profound alterations were observed in the electrocardiogram taken soon after admission in coma before the insulin administered could have produced any profound effects. In the second place, in many cases larger doses of insulin given after the return of the electrocardiogram to normal failed to produce consistently the changes noted during the acidotic state. The third reason we believe that insulin was not the cause of the alterations lies in the fact that we encountered the identical changes in a patient whose acidosis was nondiabetic in origin and who received no insulin whatever.

This patient, a colored woman aged thirty-two years, was admitted in ketosis on four separate times within the space of one year. Although she had a severe acidosis on each admission with the carbon dioxide combining power of the plasma below 20 volumes per cent, the blood sugar always ranged between 80 and 120 mg. per cent. While the cause of her acidosis has at this date not been finally deter-

mined, it is definitely not of diabetic origin. Insulin was administered during the first admission but not in the other three. The electrocardiogram of this patient (when insulin was not given), nevertheless, showed findings similar to those above described, with the exception

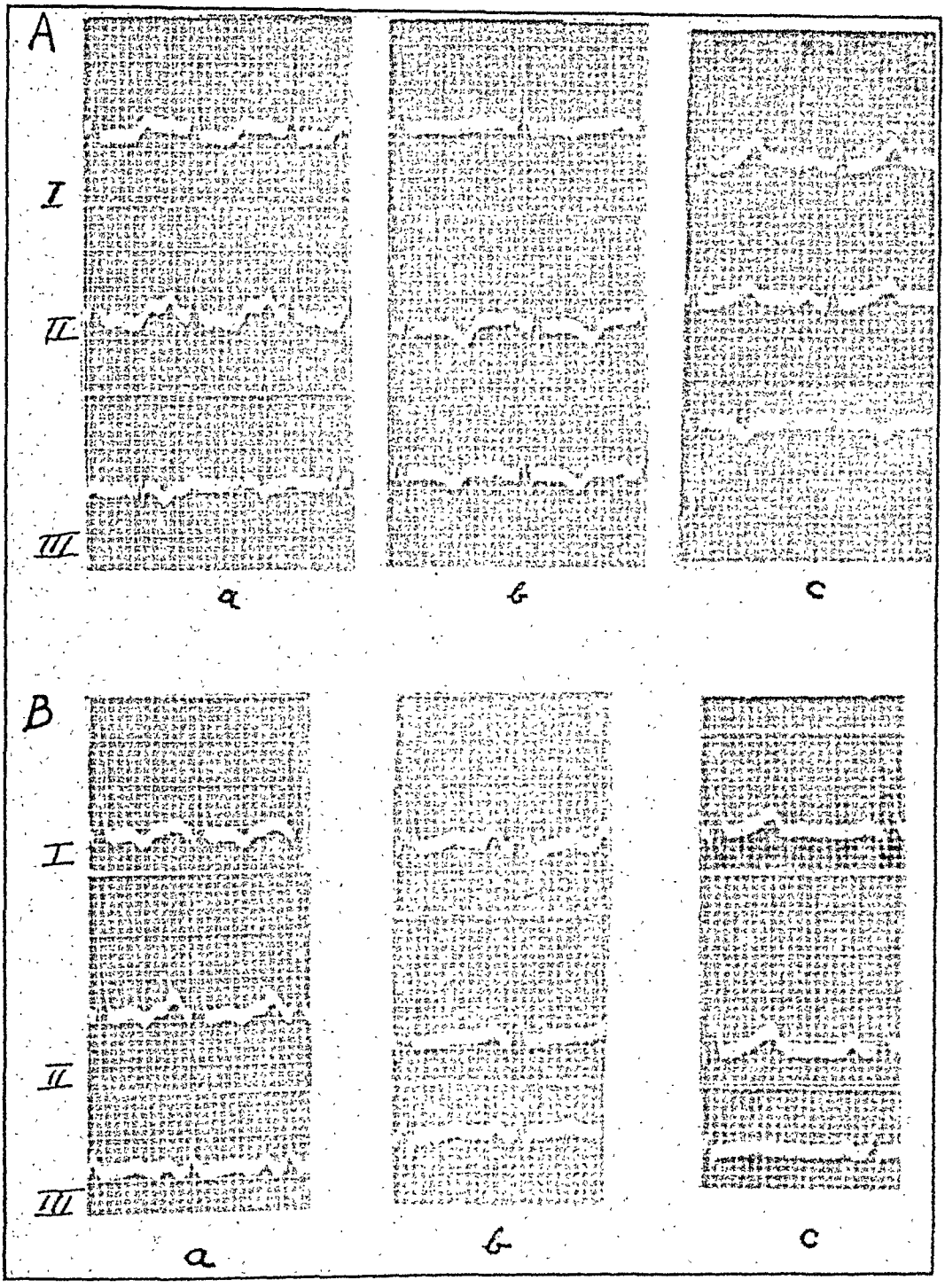

Fig. 4.—A (Case 6): *a*, Tracing made June 19, 1935, at 2:15 P.M., two hours after admission in coma. Note depressed and slightly inverted T_1 and inverted T_3. *b*, Tracing made June 20, 1935, at 4:25 P.M., twenty-two hours after patient was out of acidosis. Note slightly inverted T_1 and inverted T_2 and T_3 and absence of S-T depression. *c*, Tracing made June 24, 1935, at 11:30 A.M., practically normal with exception of left axis deviation.

B, case of acidosis, etiology undetermined (no insulin administered): *a*, Tracing made Jan 23, 1935, at 4:10 P.M., twenty hours after admission in acidosis. The CO_2 combining power of the blood on admission was 13 volumes per cent; at the time this tracing was taken it had returned to normal, being 63 volumes per cent. *b*, Tracing made Jan. 24, 1935, at 9:15 A.M., shows flattened T_1 and depressed S-T_1. *c*, Tracing made Jan. 28, 1935, at 5:30 P.M., is comparatively normal.

that the Q-T interval was not prolonged (Fig. 4*B*). We regard this one case as important since it shows that profound electrocardiographic changes can occur in and after emergence from ketogenic acidosis without insulin administration.

SUMMARY AND CONCLUSIONS

1. Except for a repeated study in one case, electrocardiographic changes were observed in every one of our 17 cases of coma and in 6 cases of precoma studied by serial electrocardiograms during and upon emergence from diabetic coma.

2. The electrocardiographic changes of the coma cases were graded as severe in 8 cases, moderate in 6 cases, and slight in 3 cases; the electrocardiographic changes in 6 precoma cases were similar although less severe than were the changes of those patients who entered the hospital in coma. Only one showed severe electrocardiographic changes; 4, moderate changes; and one, slight changes.

3. The chief alterations observed were lengthening of the Q-T interval, depression of the S-T interval, and inverted T-waves. Alterations in the QRS complexes were infrequent.

4. In all except 3 cases of the entire series of diabetic acidosis, the electrocardiogram eventually returned to normal.

5. The most abnormal electrocardiographic changes were observed not during coma but about twenty-four hours later when the patient was clinically improved and out of the acidotic state.

6. Serial electrocardiographic studies may be an important method of gauging the severity of cardiac disturbance during and upon emergence from diabetic coma.

7. The significance of these findings is discussed.

REFERENCES

1. Bazett, H. C.: An Analysis of the Time Relations of Electrocardiograms, Heart 7: 353, 1920.
2. Bentley, M., and Cowdry, E. V.: The Problem of Mental Disorders, New York, 1934, McGraw-Hill Book Company.
3. Berliner, K.: Observations on Duration of Electrical Systole of Heart With Special Reference to Effect of Digitalis, Am. Heart J. 7: 189, 1931.
4. Faulkner, J. M., and Hamilton, B. E.: The Electrocardiogram in Diabetic Coma, Am. Heart J. 8: 69, 1933.
5. Von Haynal, E.: Electrocardiographische Untersuchungen über Insulinwirkung auf das Herz, Klin. Wchnschr. 4: 403, 1925.
6. Von Haynal, E.: Vidovsky, L., and Györgi, G.: Electrocardiographische Untersuchungen über Insulinwirkung auf das Herz, Klin. Wchnschr. 7: 1543, 1928.
7. Hepburn, J., and Graham, D.: An Electrocardiographic Study on 123 Cases of Diabetes Mellitus, Am. J. M. Sc. 176: 782, 1928.
8. Klingenberg, A.: Heart and Diabetes, Norsk mag. f. Laegevidensk. 95: 940, 1934.
9. Master, A. M., Romanoff, A., and Jaffe, H.: Electrocardiographic Changes in Pneumonia, Am. Heart J. 6: 696, 1931.
10. McMillan, T. M., and Bellet, S.: The Effect of Digitalis on the Electrocardiogram, Cyclopedia of Practical Medicine, Vol. IV, p. 465, 1932, F. A. Davis Co., Philadelphia.

11. Middleton, W. S., and Oatway, W. H.: Insulin Shock and the Myocardium, Am. J. M. Sc. 181: 39, 1931.
12. Schaffer, H., Bucka, E., and Friedlander, K.: Ueber die Einwirkung des Insulin und der Hypoglykämie auf das menschliche Herz, Ztschr. f. d. ges. exper. Med. 57: 35, 1927.
13. Smith, K. S., and Hickling, R. A.: Electrocardiographic Changes During Treatment of Severe Diabetes, Lancet 1: 501, 1932.
14. Soskin, S., Katz, L. N., Strouse, S., and Rubinfeld, S. H.: Treatment of Elderly Diabetic Patients With Cardiovascular Disease, Arch. Int. Med. 51: 122, 1933.
15. Taterka, H.: Electrocardiographische Beobachtungen bei Coma diabeticum, Klin. Wchnschr. 8: 110, 1929.
16. White, P. D., and Mudd, S. G.: Effect of Various Factors on Duration of Electrical Systole of Heart as Indicated by Length of QT Interval of Electrocardiograms, J. Clin. Investigation 7: 387, 1929.
17. Wittgenstein, H., and Mendel, B.: Die Veränderung der T-Zacke des Electrocardiogram während der Insulinwirkung, Klin. Wchnschr. 3: 1119, 1924.

CARDIAC SYNCOPE

Concerning the Clinical Differentiation of Its Types

Joseph F. Borg,* M.D., and C. E. Johnson, M.D.
St. Paul, Minn.

CONSIDERABLE interest has been aroused in recent years concerning cardiac syncope, its nature, and the prevention of attacks. It has become fairly well recognized that these seizures are due to the occurrence of episodes of transient ventricular standstill or fibrillation, and certain opinions concerning the recognition and treatment of these attacks have been put forward. On account of the obviously limited opportunity for the study of these transient seizures, it seems wise to discuss this subject in the light of observations made on a case herein reported.

In ventricular standstill, the more common of these conditions, it has been fairly well established that epinephrine and ephedrine are effective in preventing the seizures, a marked stimulus to rhythmic ventricular rhythm resulting, as shown by Nathanson. Less clear is the ideal therapy for the prevention of recurring attacks of ventricular fibrillation. Dock,[1] Morawitz and Hochrein,[2] and Nathanson[3] affirm that quinidine diminishes the tendency to ventricular fibrillation by decreasing the irritability of the ventricles. On the other hand, Schwartz and Jezer[4] report two patients with complete auriculoventricular dissociation who were subject to recurrent attacks of ventricular fibrillation and who during periods of freedom from attacks regularly responded to intravenous quinidine with the development of ventricular fibrillation or prefibrillatory arrhythmia.

While controversy may exist over the treatment of these conditions, their clinical differentiation, if possible, is nevertheless important in this consideration. Since both of these conditions are usually found in connection with complete auriculoventricular dissociation, the basic heart rates are generally slow. In ventricular standstill, while observation prior to an attack may occasionally reveal the presence of dropped beats or premature contractions, the usual course of events is the sudden cessation of ventricular activity without warning, as described by numerous observers.

In transient ventricular fibrillation, little was known regarding the mechanism and possibilities of recognition clinically until the studies of Schwartz and his coworkers[5] were brought out. These showed that there is usually a change in the course of events for an appreci-

*From the Department of Medicine, University of Minnesota.

able time, usually several hours, before the onset of an attack. This starts with a gradual acceleration of both ventricular and auricular rates, the pulse rising to about 50 to 60 beats per minute. Then the intrusion of increasing numbers of ectopic beats of varying ventricular foci, left and right, occurs, producing a marked arrhythmia. This may be interrupted by a few isolated fibrillatory movements, and then the attack begins.

These observations would make it appear possible clinically to differentiate these conditions, since no irregularity simulating the pre-

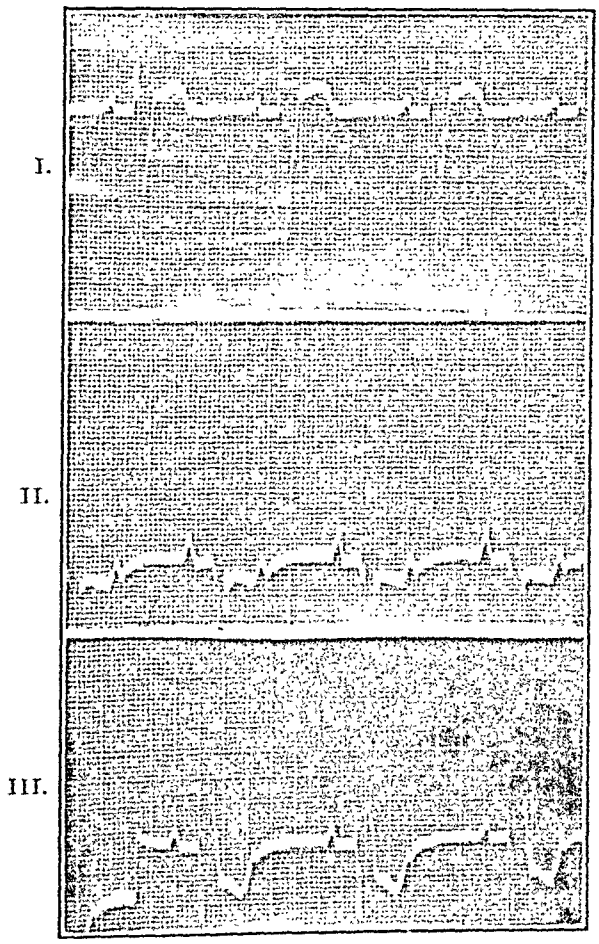

Fig. 1.—Record taken Feb. 27, 1933, showing right axis deviation. S-T is elevated in Lead I, depressed in Leads II and III, and 2:1 heart-block is seen.

fibrillatory type has been found described in the literature, although Schwartz, in a personal communication, recently states that he has seen several records of patients with auricular standstill, which showed introductory arrhythmias similar to those preceding ventricular fibrillation.

The study of a patient subject to recurring attacks of ventricular standstill which were preceded by an arrhythmia similar to that described as a prefibrillatory mechanism will therefore cast doubt upon this method of clinical differentiation, and seems worthy of report.

CASE REPORT

J. S., aged twenty-six years, was admitted to Bethesda Hospital, St. Paul, on July 9, 1935. He was a student and a trumpet player by occupation, and had always been well until January, 1933. At that time he developed acute coryza but worked daily. His sister was suffering from chickenpox, and he was said also to have had this disease although no rash appeared. Two days after this diagnosis was made, he fainted while reading a newspaper. He was observed by his brother to be very pale, rigid and breathing heavily. He was unconscious one-half hour. The next day he consulted his physician who had an electrocardiogram taken, a diagnosis of left bundle-branch block and two-to-one heart-block being made. The heart rate was 70 per minute. He did not complain otherwise, but following this the

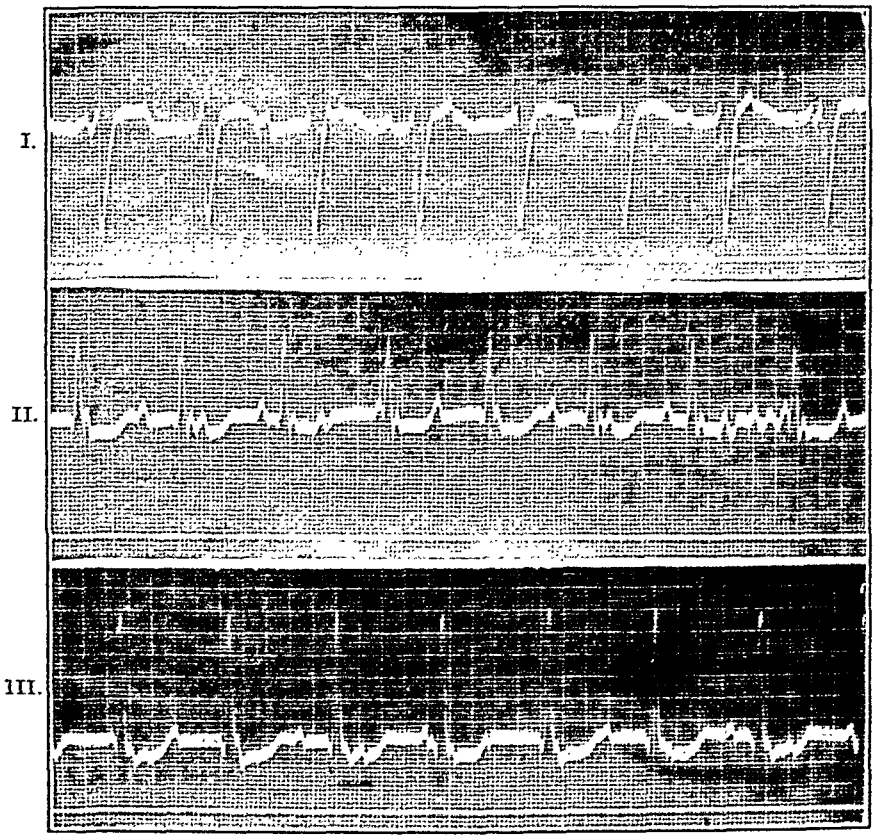

Fig. 2.—Record taken July 11, 1935, between attacks of syncope, patient being comfortable. This shows essentially similar wave contours, but a complete auriculo-ventricular dissociation with bundle-branch block has appeared.

attacks recurred about once a week. In February he consulted another physician who told him he had congenital heart disease. A week later he consulted a third physician who prescribed ephedrine sulphate, grains ⅜, three times a day. He then felt fairly well until June, 1933, when he began to have a recurrence of frequent attacks especially at night. These occurred as often as every 2 or 3 minutes lasting ½ to 2 minutes each. He was sent to Abbott Hospital, Minneapolis, where the attacks were prevented by the use of epinephrine. He was again returned home where the attacks occurred at irregular intervals, and fear of them caused him to remain in bed for two years. Intervals of as long as two months occurred between attacks. On July 4, 1935, he had a series of severe attacks which were not relieved by adrenalin as well as previously. On July 9 he had a very severe attack, a condition resembling status epilepticus, and was admitted to the hospital.

Physical examination revealed a well-nourished and well-developed young man, who showed no significant findings except for the heart. This was moderately enlarged to the left. The rate varied from 48 to 60 per minute and the rhythm appeared normal. There was heard a soft systolic murmur at the apex, not transmitted, and the second pulmonic sound was accentuated. The blood pressure was 140 mm. systolic, 100 mm. diastolic.



Fig. 3.—Continuous strip record of Lead II showing the onset, duration, and cessation of an attack of ventricular standstill and syncope lasting 43 seconds. Preceding the onset there is a complete heart-block with several beats from a ventricular focus, followed by a period of auricular contractions which gradually disappear. Effective ventricular contractions are initiated by two bizarre complexes of right ventricular origin, followed by a left ventricular tachycardia with a probable shifting of the focus of stimulus.

Repeated attacks of syncope occurred for twenty-four hours after admission, each lasting as long as several minutes. These were so severe that intracardiac injections of adrenalin, cardiac needling, or severe precordial blows were necessary to start



Fig. 4.—Records of Lead II showing the bizarre type of rhythm preceding various attacks. *A*, Continuous strip record; *B*, *C*, *D*, *E*, *F*, other examples showing the irregular ventricular rhythms which preceded different attacks.

cardiac activity. They occurred at intervals of a few minutes to one-half hour. Thereafter the attacks ceased, apparently being controlled by frequent 5 minim doses of adrenalin subcutaneously. He improved considerably although he was disoriented for about three days. On July 13 the attacks recurred with great frequency for about twenty-four hours, then diminished, and he felt fairly well until July 16 when they reappeared as often as every one-half minute, persisting for eight hours when he died in an attack, intracardiac adrenalin being of no avail. Autopsy was refused.

Immediately prior to the attacks of syncope there could be made out a variety of different heart rhythms. These were usually irregular, observation at times suggesting extrasystolic arrhythmias, at other times auricular fibrillation. The rate was usually accelerated from 80 to 120. These rhythms suggested very much the types described by Schwartz and his coworkers as prefibrillatory rhythms, and had it not been for the previous benefit obtained by the use of epinephrine, one would have been hesitant to use it. Electrocardiograms taken before, during, and after attacks show the bizarre and variable arrhythmias which occurred. These are shown and described in Figs. 1 to 5. Except for Figs. 1 and 2, as shown, all records are from Lead II.

Fig. 5.—Two records showing the mechanism of cessation of the attacks. After a few bizarre contractions a fairly regular ventricular tachycardia begins. This would gradually become slower and a type of rhythm illustrated by Fig. 2 would appear.

DISCUSSION

It is hoped that the report of this case may add to the accumulating information regarding the mechanism of cardiac syncopal seizures and their proper interpretation and treatment. A paucity of reports has made difficult their proper evaluation.

Epinephrine is becoming widely used in the treatment of Adams-Stokes seizures, regardless of the fact that there is usually no knowledge of the mechanism of the attacks. Schwartz and Jezer have demonstrated the tendency of this drug to produce prefibrillatory states and attacks of transient ventricular fibrillation in patients who have been known to be subject to the latter spontaneously. Nathanson's experimental work supports these observations. It is therefore important to watch carefully the effect of this drug on patients with such seizures in whom the mechanism has not been definitely established.

In conclusion it may be pointed out that it is apparently unsafe to judge from a study of rhythm immediately preceding an attack the mechanism which may be responsible for its production. As far as is known, no clinical observation can accurately determine this and electrocardiographic study during an attack may be necessary for absolute certainty.

SUMMARY

Attention is called to a prevailing opinion that a study of the mechanism of the attacks of transient cardiac syncope will differentiate them as caused by ventricular standstill or ventricular fibrillation.

A case of recurrent ventricular standstill in a young man with complete heart-block, in whom the mechanism of the attacks resembled that of transient ventricular fibrillation, is reported.

It is suggested that such differentiation is probably not possible clinically without electrocardiographic records.

REFERENCES

1. Dock, Wm.: Transient Ventricular Fibrillation, Am. Heart J. 4: 709, 1928-29.
2. Morawitz, P., and Hochrein, M.: Zur Verhütung des akuten Herztodes, München. med. Wchnschr. 76: 1075, 1929.
3. Nathanson, M. H.: Modification of Vagus Inhibition of the Heart by Quinidin, Proc. Soc. Exper. Biol. & Med. 31: 1234, 1933-34.
4. Schwartz, S. P., and Jezer, A.: The Action of Quinine and Quinidine on Patients With Transient Ventricular Fibrillation, Am. Heart J. 9: 792, 1934.
5. Schwartz, S. P.: Transient Ventricular Fibrillation, Arch. Int. Med. 49: 282, 1932.

Schwartz, S. P., and Hauswirth, L.: Studies on Transient Ventricular Fibrillation, Am. J. M. Sc. 187: 478, 1934.

Schwartz, S. P., and Jezer, A.: Transient Ventricular Fibrillation, Arch. Int. Med. 50: 450, 1932.

ARTERIOVENOUS ANEURYSM*

Report of a Case With Pronounced Electrocardiographic Changes

James T. Quattlebaum, M.D.
Columbia, S. C.

ELECTROCARDIOGRAPHY has attracted little interest concerning its relationship to the cardiac disability of arteriovenous aneurysm. An extensive review of the literature shows that several investigators have included clinical and experimental electrocardiograms in their studies (Lewis and Drury,[1] Gage and Hermann,[2, 3] Reid,[4] and others). The abnormalities, however, were so slight that little was to be said about them. Compression of the aneurysm with slowing of the pulse (Branham's bradycardiac phenomenon) has invariably appeared in the electrocardiogram as a simple prolongation of the diastolic pause. As noted by LaPlace[5] in a recent report, it is surprising how few electrocardiographic changes take place even when the heart is severely affected. Nevertheless, marked changes do take place though they are seen only in the last stages of the cardiac decompensation. Tracings showing these marked abnormalities have rarely been published or described—though an enormous amount has been written about arteriovenous aneurysms.

These defects, which may be acquired or congenital, are probably much more common than is generally supposed. Rienhoff[6] in 1923 found more than 500 reported cases (24 congenital) and since that time there are many more on record. Matas[7] has records of 41 (10 cerebral type) and Pemberton[8] states that 25 patients were operated on at the Mayo Clinic between 1915 and 1926 (16 acquired and 9 congenital). More than 75 cases of communication between the aorta and vena cava have been reported (Sheman,[9] Hartman and Levy[10]). Three arteriovenous aneurysms were of mycotic origin,[11] and several have been produced purposely[12] in the hope that the pressure in aorta would be reduced and aortic aneurysms relieved of strain.

Until twelve or fifteen years ago, the truly detrimental effects of these fistulas were unknown and prior to that time cases were reported primarily in regard to their surgical care. The heart disability, if observed, was thought to be coincidental.[13] From the reports of hundreds of these cases, it is obvious that many had no heart disability. Most of those seen by Makin[14] were of such recent origin that the cardiac disturbance had not developed. Then, too, all the cerebral and

*From the Veterans' Administration Hospital, Columbia, S. C.

Published with the permission of the Medical Director of the Veterans' Administration, who assumes no responsibility for the opinions expressed or the conclusions drawn by the writer.

most of the congenital cases have had no cardiac complications, which is probably true of any small one in the periphery. Some writers have stated that none of the congenital fistulas show cardiac changes, but Lewis[15] cites several instances[16] including one case seen by himself, disproving this idea. According to Thomason,[17] Callander's[18] analysis of 447 cases disclosed only 16 having cardiac hypertrophy. Matas,[7] however, found cardiac signs or symptoms in 70 per cent of his 31 cases, after the 10 cerebral cases had been excluded. Thus we see that cases with cardiac changes are far from common and of those with cardiac hypertrophy, in only a few were electrocardiograms made. Few of these tracings have been published.

CASE REPORT

White male, aged forty-five years, a stone and cement worker, was admitted to hospital Oct. 26, 1935, complaining of severe shortness of breath and swelling of the entire body. He had been fairly well until about one year previously when, following an accidental fall on his back, he began to have shortness of breath, though he was not hurt by the fall. He continued to do some work until one month prior to admission. After reconsideration he remembered that he had slight dyspnea and palpitation as far back as 1917 and had been rejected from the army on account of his heart. In 1912, he had been accidentally shot in the right groin and left hip and though he had soon noticed a vibration or buzzing feeling in the right leg, this extremity did not swell or cause any particular trouble until some years later (1927), when a large sore formed on the inner lower side and would frequently return following the slightest injury (near the internal malleolus). The swelling of this leg began and became more and more pronounced. During the past year, he had three attacks of pain in the epigastrium and lower sternal region, not radiating. They were associated with exertion. After these spells he noticed some tenderness in the region of the liver. Slight jaundice was noted about one month prior to admission.

Past History.—He always did hard work and was seldom sick except during the past few years when he had been frequently hospitalized on account of slight injuries to the affected leg which did not heal readily. He had bronchopneumonia in 1932 with uneventful recovery and influenza in 1922. He denied rheumatic fever, scarlet fever, diphtheria, or syphilis. He was married and had five living children. His father and mother were living and well, aged sixty-eight and sixty-five years respectively.

Physical Examination.—Pulse was 120; respiration, 20; temperature, 98.6° F; he was a well-developed white male with obvious dyspnea, cyanosis, anasarca, and slight jaundice. The edema involved the face, and the abdomen was so tense that it could not be palpated satisfactorily. The lower legs were enormously edematous and practically of equal size. No dilated veins were visible or palpable in the right leg or abdomen, but there was a large discolored area just above the internal malleolus on the right, apparently the site of an old varicose ulcer. Just below Poupart's ligament on the right, an intense thrill could be palpated over an area about 5 in. by 6 in. This area showed no enlargement and the pistol bullet scar was so small it was scarcely visible. Auscultation over this area revealed a very loud continuous machinery or humming murmur with systolic accentuation. This sound seemed best transmitted upward and also toward the lower, outer portion

of the leg. With firm pressure over this area, these signs ceased; the pulse rate decreased from 120 to 60 (Branham's[19] bradycardiac phenomenon). The blood pressure increased from 130/80 to 160/80. At no time was a murmur discernible over the heart. There was typical evidence of auricular fibrillation, and this was

Fig. 1. Fig. 2.

Fig. 1.—Before operative cure of the aneurysm. Midsternum to the right heart border, 6.8; midsternum to the left heart border, 13.3; chest, 31.

Fig. 2.—Seventy-six days after operation. Midsternum to the right heart border, 4.7; midsternum to the left heart border, 10.3; chest, 31.7.

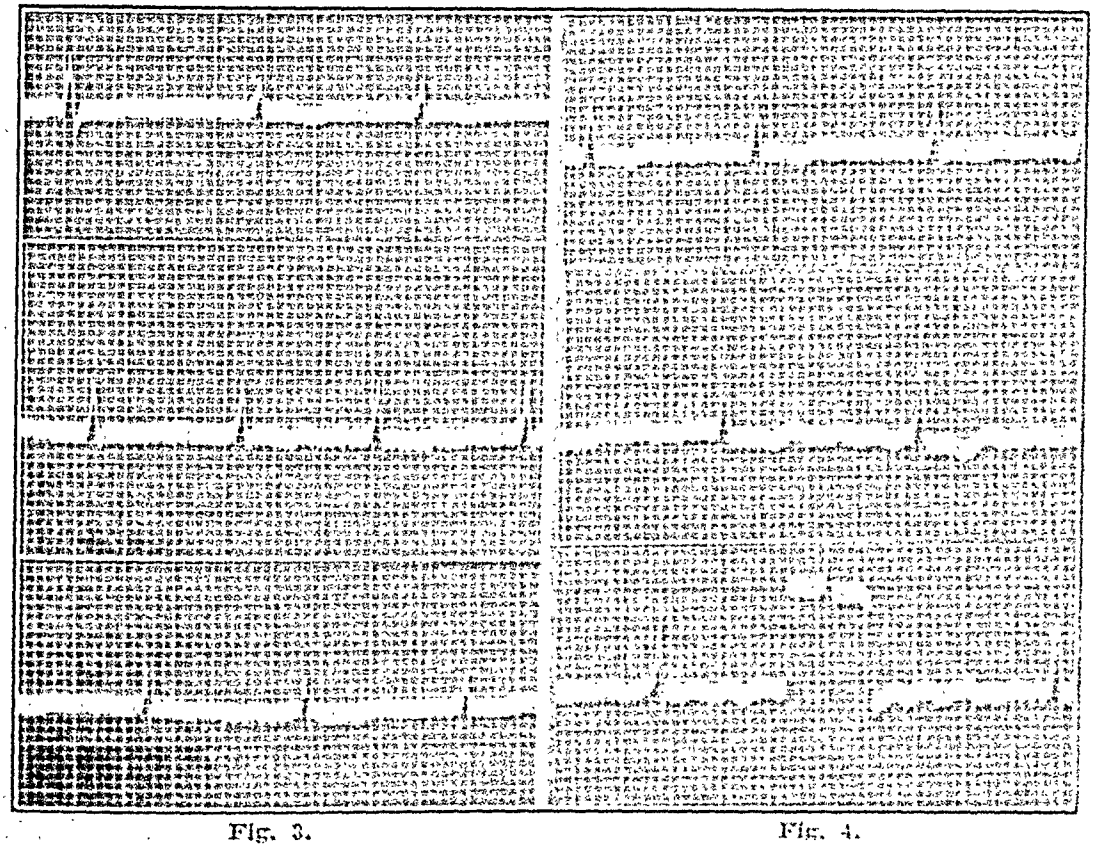

Fig. 3. Fig. 4.

Fig. 3.—Before operation, diminished voltage, T-waves almost isodectric in all leads. Ventricular rate, 166. Auricular fibrillation. Digitalization incomplete.

Fig. 4.—Nine days after operation, increased voltage, decreased rate.

not affected by compression of the fistula except as to rate. Blood pressure of the affected leg could not be ascertained. Blood pressure of the other leg was 200/70; right arm, 150/80; left arm 160/80. Cardiac dullness was markedly increased ex-

tending, in the sixth interspace, about 14 cm. to the left of the midsternal line. The apex impulse was not visible and was quite feeble. The heart sounds were soft, indistinct, particularly at the base, and there was complete arrhythmia. Peripheral arteries were not thickened appreciably. The liver was believed to be quite large but could not be palpated satisfactorily. No pronounced pulsation of the liver was detected.

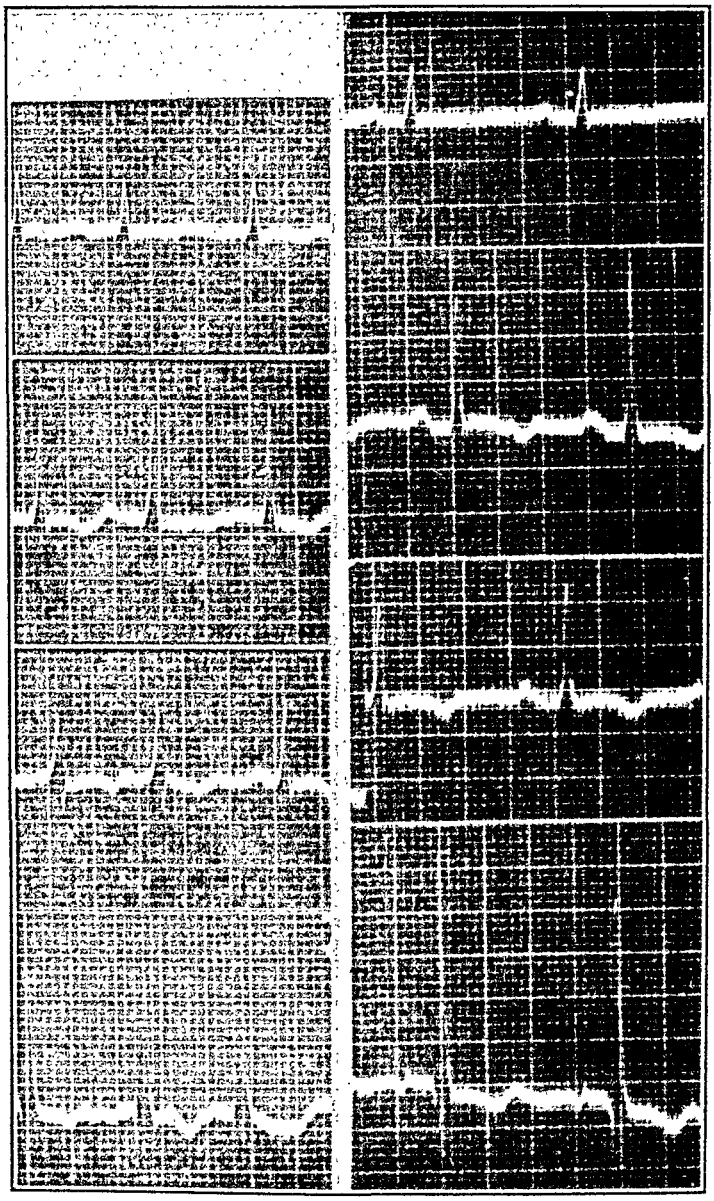

Fig. 5. Fig. 6.

Fig. 5.—Forty-six days after operation. Ventricular rate increased during quinidine therapy.

Fig. 6.—Forty-seven days after operation. Normal rhythm restored. Quinidine discontinued. T_2 and T_3 more deeply inverted. T_4 diphasic.

Laboratory Findings.—Wassermann reaction was negative; urine specific gravity, 1.017; very faint trace albumin, a few white blood cells and a few granular casts. Other urinalyses were negative. Leucocyte count was 12,600; polymorphonuclear leucocytes, 71; lymphocytes, 23; monocytes, 4; eosinophiles, 1; basophiles, 1; hemoglobin, 90 per cent (Tallqvist); nonprotein nitrogen, 66.6; creatinin, 1.8.

X-ray Findings.—(6 ft.) Heart greatly enlarged. Measurements: chest 31 cm.; midsternum to right heart border, 6.8 cm.; midsternum to left heart border, 13.3 cm. A great deal of hypostatic congestion evident (Fig. 1).

X-ray films taken after operation showed marked decrease in the size of the heart. Though an x-ray film made nineteen days after operation showed a very pronounced reduction in the heart shadow, a subsequent film, seventy-six days after operation, showed still further decrease (Fig. 2).

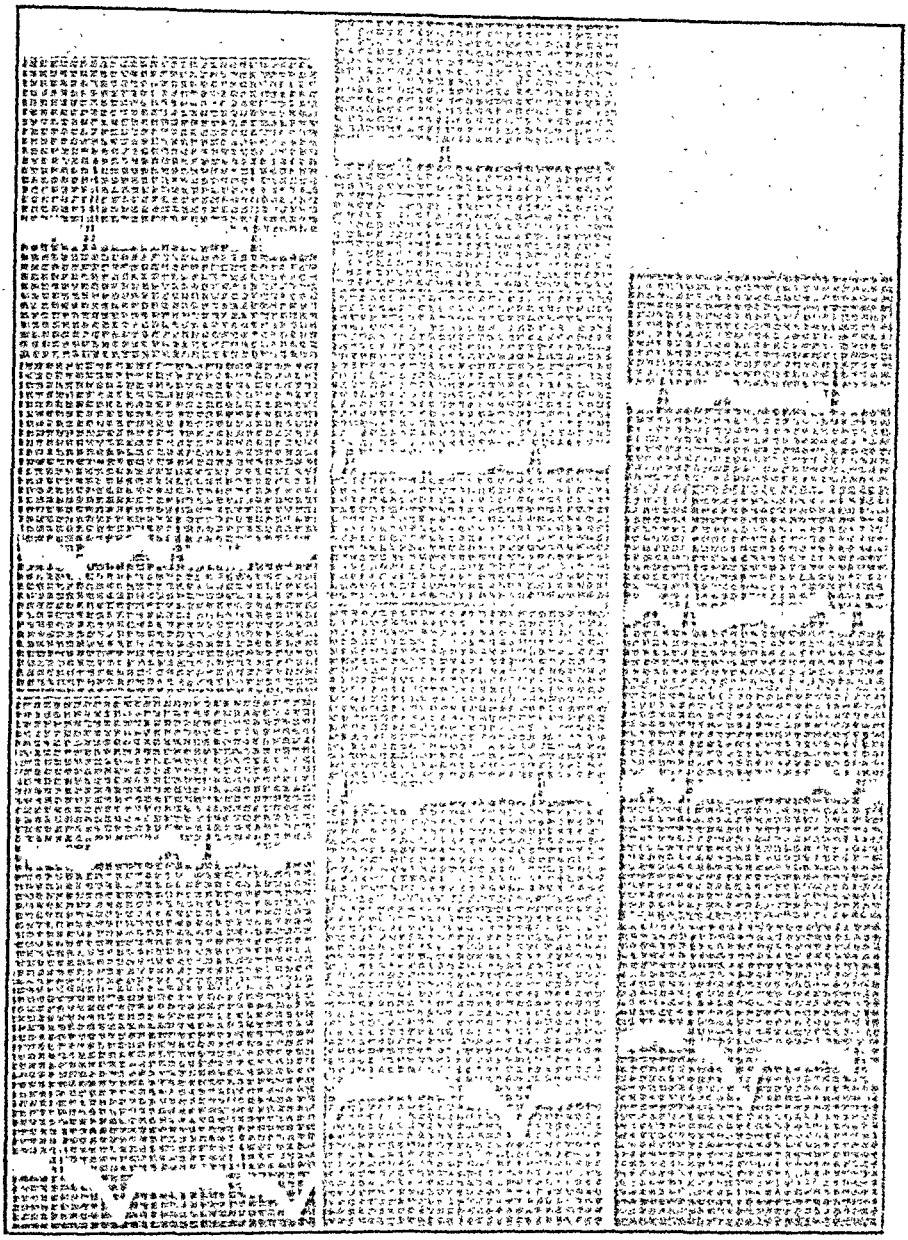

Fig. 7. Fig. 8. Fig. 9.

Fig. 7.—Eighty-eight days after operation. Eighty-four days after digitalis was discontinued and 41 days after quinidine was discontinued.

Fig. 8.—Ninety-five days after cure of aneurysm. T_1 upright. Depth of T_3 diminished.

Fig. 9.—One hundred twenty-three days after cure of aneurysm. T_1 has become upright. T_3 almost isoelectric. Q_1 has not improved.

Electrocardiograms showed pronounced abnormalities which had not completely returned to normal 123 days after operation (118 days after digitalis had been discontinued).

The series of changes which took place is interesting. The first electrocardiogram, Fig. 3 (prior to operation), showed diminished voltage, and there was an occasional ventricular ectopic beat. The T-waves were slightly inverted in all leads, almost isoelectric. At the time of this first tracing, 25 c.c. of tincture of digitalis had been given by mouth. However, since the average S-T segment did not show a typical digitalis effect, and with a rate of 100, it was believed that a full digitalis effect had not been obtained.

Following the operation, the voltage promptly increased, T_2 and T_3 became more deeply inverted, and T_1 gradually became upright (Figs. 4 to 9). More than three months after the operation T_2 became upright and T_3 showed evidence of beginning this change. Lead IV, when first observed, showed a very small Q and a somewhat flattened T which soon became diphasic and then normal. QRS_4 at the time of the last tracing showed no evidence of returning to normal. It had developed some notching, and Q_4 was even smaller than on previous occasions.

Course and Treatment.—Morphine was administered immediately and digitalization begun. When some slight improvement was noted, salyrgan was given intravenously on three occasions with definite benefit, and, though the patient continued very ill and uncomfortable, he appeared to be practically edema free, and both ankles were almost of normal and equal size.

He seemed to be in optimum condition on Nov. 22, 1935, and surgical correction of the fistula was carried[20] out. He reacted well, and during the night following the operation there was noticeable diuresis (1400 c.c.). Each day there was rapid clinical improvement. The fibrillation continued and was allowed to do so until Jan. 7, 1936, forty-six days after the operation. It had been allowed to continue in order to determine whether or not it would cease spontaneously. Digitalis had been discontinued four days after operation since there was such excellent improvement and the pulse was so slow. On Jan. 7, 1936, quinidine, gr. iii, was given at bedtime and the next morning gr. vi every two hours. Normal rhythm, restored after the fourth dose, continued until discharge from the hospital. All subjective symptoms of congestive failure had disappeared in little more than two weeks following the operation, and the patient rapidly gained strength and weight, though he did have rather frequent respiratory infection. The nonprotein nitrogen was only 33.3 and the creatinin, 1.8, Nov. 2, 1935, and 40.5 and 1.6, respectively, on Dec. 19, 1935. On Feb. 7, 1936, the blood pressure was 140/80; March 9, 169/98; and at time of discharge, March 25, 1936, the blood pressure was 150/90 and pulse, 80. His heart decreased to normal size; the electrocardiograms returned almost to normal; the signs of decompensation were absent.

At time of discharge there were occasional musical râles over both lungs and evidence of mild asthmatic bronchitis. The affected leg developed very slight edema after standing, but this edema subsided during the night. Aside from these mild disabilities he was a normal healthy person.

COMMENT

Though electrocardiograms showing pronounced abnormalities are rare, a comparison of the few available shows some more or less uniform and striking Q and T changes which suggest that the myocardial derangement is similar to that found in coronary disease or occlusion (not, however, meeting all specifications of Wilson and his coworkers[21] for recent occlusion). In the case reported by Fothergham and Alvarez,[22] there was a deep Q_3 and inverted T_3 of the coveplane type which disappeared twenty-one days after the operation. In Reid's[4] experimental work Dog No. 9 lived thirty months after the

fistula was opened and was finally found dead. An electrocardiogram made eighteen months after opening the fistula showed no abnormality, but twelve months later, and less than a month before the dog died, an electrocardiogram showed a deep Q_1 and a deeper Q_2, T_1 inversion of the cove-plane type, and definitely depressed R-T segments in Leads II and III. This tracing today would suggest coronary occlusion of the Q_1 T_1 type. Details of the autopsy were not given except for the fact that there was hypertrophy.

In the case presented here the most noteworthy features are the diminished voltage, T-wave inversion, small Q_4 with slight widening and notching of QRS, auricular fibrillation (see illustrations).

Two outstanding ideas have arisen since 1920, explaining the mechanism responsible for the onset of cardiac dilatation and hypertrophy in these cases. Extensive clinical and experimental observations have been made by the chief exponents of each. Holman[23] contends that the cardiac dilatation and hypertrophy are the result of increased work, consequent upon increased venous pressure and increased volume flow through the heart. Lewis and Drury[1] do not agree that there is increased venous pressure except that resulting from congestive failure. They maintain that the cardiac disorder is the result of diminished coronary flow with deficient myocardial nutrition. It is suggested that the ideas of Lewis and Drury are given support by electrocardiograms of long-standing, far-advanced cases. Matas[7] has had one patient die of angina pectoris and coronary occlusion shortly after the operation on the fistula. He points out that this should be a likely situation for the development of coronary occlusion if the ideas of Lewis and Drury are correct.

A brief discussion of certain clinical features of the present case follows: A similar absence of the blood pressure in the affected limb was noted in the case of Dean and Dean[24] and a decreased pressure has been noted by others.[1, 25] An enormous urinary output immediately after the operation was observed by Reid.[26] The diastolic pressure in the present case was unusually high throughout, though cases have occurred in which there was associated hypertensive disease of severe degree.[27] The absence of any marked blood pressure (diastolic) response during Branham's phenomenon can be explained only by the observation of Matas[7] that decompensation may be so severe that there is no response, though it is possible that, with an originally high diastolic pressure, no marked response may be expected. Tachycardia, which is often present and which has been explained as resulting from engorgement of the splanchnics,[28] is in many cases absent. Auricular fibrillation is said by some[29] to occur frequently, and Matas says that arrhythmia is often present. However, descriptions of auricular fibrillation in these cases are difficult to find. In Thomason's[17] case, auricular fibrillation developed suddenly twenty-

three days after the fistula had been cured, and Matas had three patients who developed paroxysmal tachycardia (a similar condition[30]) shortly after their operations, showing the soundness of Holman's[31] advice that a prolonged convalescence is indicated.

SUMMARY

Cardiac decompensation has been reported in a rather small percentage of all cases of arteriovenous aneurysm. Even when there is severe decompensation, the electrocardiogram often shows few changes. Published electrocardiograms showing marked abnormalities are very rare.

A case is presented showing pronounced abnormalities in the electrocardiogram. Tracings were made prior to surgical cure of the aneurysm and after the operation, over a period of 123 days. They showed a remarkably slow return to normal, though clinical improvement was rapid. Auricular fibrillation in this case did not cease spontaneously after operation but ceased with quinidine therapy, and showed no inclination to return.

Other cases on record having decidedly abnormal electrocardiograms are compared with the present case. Certain clinical features of this case are compared with other cases from the literature.

REFERENCES

1. Lewis, T., and Drury, A. N.: Observations Relating to Arteriovenous Aneurysm, Heart 10: 301, 1923.
2. Gage, I. M., and Hermann, G.: Proc. Soc. Exper. Biol. & Med. 25: 765, 1928.
3. Gage, I. M., and Hermann, G.: Further Observations on Experimentally Produced Arteriovenous Aneurysm, Proc. Soc. Exper. Biol. & Med. 26: 760, 1928.
4. Reid, Mont R.: The Effect of Arteriovenous Fistula Upon the Heart and Blood Vessels, Johns Hopkins Hosp. Bull. 31: 43, 1920.
5. LaPlace, L. B.: Observations on the Effect of an Arteriovenous Fistula on the Human Circulation, Am. J. M. Sc. 189: 497, 1935.
6. Rienhoff, W. F., Jr.: Congenital Arteriovenous Fistula, J. A. M. A. 83: 743, 1924.
7. Matas, Rudolph: On the Systemic or Cardio-Vascular Effects of Arteriovenous Fistulae, Internat. Clin. 2: series 35, 58, 1924.
8. Pemberton, J. de J.: Arteriovenous Aneurysm, Arch. Surg. 16: 469, 1928.
9. Shennan, T.: Spontaneous Arteriovenous Aneurysm in the Thorax, Edinburgh M. J. 32: 325 and 410, 1925.
10. Hartman, H., and Levy, M. D.: Rupture of Arteriovenous Aneurysm Into the Superior Vena Cava, South. M. J. 19: 595, 1926.
11. Floyd, Rolfe: A Large Mycotic Embolic Aneurism of Femoral Vessels, Surg. Gynec. & Obst. 33: 560, 1921.
12. Uttal, J.: Surgical Arteriovenous Aneurysm in the Treatment of Thoracic Aneurysm, Am. Heart J. 6: 426, 1931.
13. Osler, William: Lancet 1: 949, 1915.
14. Makin, Sir G. H.: On Gunshot Injuries to Blood Vessels, 1919.
15. Lewis, D.: Bradycardiac Reactions and Cardiac Changes in Arteriovenous Aneurisms: Their History, Libman Anniv. 2: 733, 1933.
16. Nicoladoni, Carl: Phlebarteriectasie der rechten oberen Extremitat, 1875.
17. Thomason, T. H.: Arteriovenous Fistula, Ann. Surg. 82: 293, 1925.
18. Callander, C. L.: Study of Arteriovenous Fistula With an Analysis of 447 Cases, Ann. Surg. 71: 428, 1920.

19. Branham, Harris M.: Aneurysmal Varix of the Femoral Artery and Vein Following a G. S. W., Internat. J. Surg. 111: 250, 1890.
20. Coffee and Benet: To be published.
21. Barnes, Arlie R.: Q and T Types Electrocardiograms: Their Comparative and Complementary Value in Indicating Occurrence of Acute Myocardial Infarction, Am. Heart J. 9: 722, 1934.
22. Fotheringham, T., and Alvarez, C.: Aneurysma arterio venosa y asystolia, Bol. Soc. cir. de Buenos Aires 19: 32, 1935.
23. Holman, E.: Experimental Studies in Arteriovenous Fistula, Arch. Surg. 9: 822, 1924.
24. Dean, J., and Dean, J. C.: Arteriovenous Aneurysm: Its Effect on the Heart. A Brief Review of the Literature and Report of a Case, Wisconsin M. J. 33: 587, 1934.
25. Yater, W. M., and White, C. S.: Roentgenographic Demonstration of Arteriovenous Aneurysm by Means of Thorotrast, Am. J. M. Sc. 186: 493, 1933.
26. Reid, Mont R.: Report of Vascular Lesions Which Illustrate Some of the Fundamental Principles That Have Been Taught and Emphasized by Professor Rudolph Matas, Am. J. Surg. 14: 17, 1931.
27. Hoover, C. S., and Beams, A. J.: Diagnosis and Pathologic Physiology of Arteriovenous Aneurysm, Arch. Int. Med. 33: 1, 1924.
28. Kisthinios, N.: Mechanism of Cardiac Disturbances in Aneurysms: Experimental Study, Presse méd. 43: 1329, 1935.
29. Reid, Mont R.: The Effect of Arteriovenous Aneurysm Upon the Heart—With Report of Case Studied by Prof. Matas, Dr. George Herrmann and the Author, Ann. Surg. 95: 578, 1932.
30. Lewis, T., and Schleiter, H. G.: The Relation of Regular Tachycardias of Auricular Origin to Auricular Fibrillation, Heart 3: 173, 1912.
31. Holman, E.: Arteriovenous Aneurysm; Its Physiologic Effects Upon the Circulation and Their Importance in Relation to Surgical Treatment, Calif. & West. M. 30: 307, 1924.

Department of Clinical Reports

A PROVED CASE OF DEXTROPOSITION OF THE HEART, SHOWING LEFT AXIS DEVIATION IN THE ELECTROCARDIOGRAM*

M. Robinow, M.D.
Chicago, Ill.

IN DEXTROPOSITION of the heart, as in mirror-picture dextrocardia, the expectation is that the electrocardiogram would show a right axis deviation when the apex points to the right. In the case here presented, on the contrary, a left axis deviation was found. A survey of the literature revealed several other reports with a similar axis deviation:

1. A case reported by Owen cited by Lichtman[1] of complete situs inversus with mitral stenosis and left ventricular preponderance.

2. A case reported by Gorter[2] of congenital dextrocardia complicated by congenital malformations showing left axis deviation (in this case due to deep Q_2 and Q_3).

3. A case reported by Meyer[3] of congenital dextrocardia complicated by congenital malformations, showing marked right ventricular hypertrophy and left axis deviation (proved by autopsy).

4. A case reported by Abrahamson[4] of mirror-picture dextrocardia with left ventricular preponderance.

The unusual combination of dextroposition and left axis deviation in our case shows the difficulties of explaining the electrocardiographic findings on the usual concept of the Einthoven equilateral triangle.

CASE REPORT

The patient was first seen in the Mandel Clinic in February, 1931. He complained of dyspnea on exertion, weakness and productive cough. During childhood he had frequent attacks of "croup." At the age of seventeen years he contracted pneumonia and pleurisy. His complaints date back to that illness.

The physical examination at that time revealed an undernourished, narrow-chested white male, twenty-seven years old. Cardiac dullness was noted on the right side, and a forceful apex beat was visible just underneath the right nipple. A short, rough systolic murmur was heard over the base. There was impaired resonance with diminution of breath sounds and moist râles over both lung bases. A pleural friction rub was heard on the left side.

The x-ray examination showed the heart, lungs, trachea, and mediastinum pulled over to the right side. There was marked haziness of the lungs, and bronchiectases

*From the Heart Station, Michael Reese Hospital, Chicago.

were seen with several cavities and extensive adhesions. There was no situs inversus of the abdominal or thoracic organs. The findings were confirmed by fluoroscopy on a subsequent examination.

During the course of the next few years, he had several severe flare-ups of bronchitis but otherwise enjoyed relatively good health and was able to work until March 3, 1936, when he suddenly developed dyspnea and weakness which confined him to bed. On the morning of March 8 he was suddenly seized by extreme weakness and dyspnea and became cyanotic. He was brought to the hospital in the

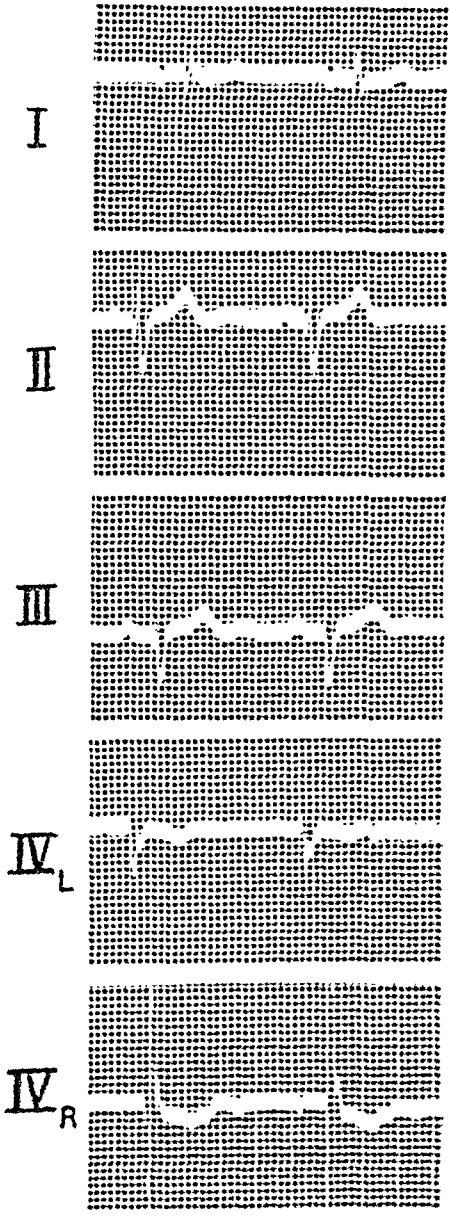

Fig. 1.—This is an electrocardiogram obtained in this patient. The standard leads are labeled I, II and III. IV_L is a standard Lead IV employed by us with the distant electrode on the left leg and the precordial electrode in the fourth interspace to the left of the sternum. IV_R is a lead similar to the previous one with the precordial electrode in the same interspace but to the right of the sternum.

afternoon and admitted on Dr. J. Meyer's service. Digalen, morphine, atropine and caffeine were given, and he was put in an oxygen tent. In spite of every effort, he became stuporous and died two hours after admission.

Autopsy Report (by Dr. O. Saphir).—The heart was displaced to the right and rotated on its long axis, so that the entire heart lay to the right of the sternum. The left lung was markedly emphysematous. Adhesions were present between the

pleura and the pericardium. The heart weighed 280 gm. The mitral valve showed evidence of an old healed mitral valvulitis. The coronary arteries were normal. There was a marked right ventricular hypertrophy. The lungs showed bilateral early bronchopneumonia and marked chronic bronchiectasis in addition to emphysema.

Electrocardiogram.—The curves taken May, 1935 (Fig. 1), and the one taken six months later were almost identical. The outstanding abnormalities were the negative P-wave in Lead I, the marked left axis deviation with QRS inverted in Leads II and III and small in Lead I, the marked slurring and notching of QRS in the standard and precordial leads, and the S-T elevation in Leads II and III. The inversion of QRS in Lead IV_L (the standard Lead IV with precordial electrode in the fourth interspace to the left of the sternum) and the occasional diphasic T in this lead, as well as the notched T in Lead IV_R (where the precordial electrode is in the fourth interspace to the right of the sternum) were all abnormal.

DISCUSSION

While most cases of mirror-picture dextrocardia, congenital dextrocardia without reversal of the heart chambers and dextroposition show right axis deviation, a few, of which this is an example, show the reverse. In this case, as in the one reported by Meyer[3] and presumably also in that of Gorter,[2] there is in addition a marked right ventricular preponderance. Several explanations suggest themselves.

It may be assumed that the combination of right ventricular hypertrophy and shift of the anatomical axis to the right has led to a rotation of the electrical axis of more than 180°. This seems rather improbable.

It is more likely that a counter-clockwise rotation of the heart around its longitudinal axis might be responsible. Such rotation has been shown to cause left axis deviation in animal experiments (Ackerman and Katz[5] and Meek and Wilson[6]) and in man (Nathanson[7] and Katz and Robinow[8]).

Recently, in this laboratory (Katz[9]) we have come to believe that such unexpected findings may be accounted for by changes in the relation between the heart and the structures surrounding it. These structures, namely, the diaphragm, the lungs, the great vessels, the anterior chest wall, and the muscles in front of the spinal column, are not equally good electrical conductors (Katz and Korey[10]). The contact of the different regions of the heart with the good conductors is largely responsible for the appearance of the electrocardiogram (Katz, Gutman, and Ocko,[11] Katz, Sigman, Gutman, and Ocko[12] and Robinow, Katz, and Bohning[13]). In our case there is not only a shift of the heart as a whole to the right but also a shift of some of the structures surrounding it (viz., the lungs and large vessels) and a modification of the contact between the heart and the good electrical conductors (the posterior muscle mass, the diaphragm, and the anterior chest wall). These factors may have altered the electrical field of the body sufficiently to give rise to the left axis deviation.

This case, therefore, is another link in the chain of evidence obtained in this laboratory, supporting the idea of the importance of the nature and the location of the electrical conductors adjacent to the heart and disproving the general applicability of the Einthoven triangle concept.

This case illustrates again that left axis deviation, even of marked degree, is not necessarily associated with a shift of the anatomical axis to the left or with left ventricular preponderance. It may be found with the exact opposite as in the cases here reviewed or in cases with brown atrophy (Katz, Saphir, and Strauss[14]).

SUMMARY

A case of dextroposition of the heart with right ventricular hypertrophy proved post mortem is presented because there was in the electrocardiogram marked left axis deviation. The significance of this finding is discussed.

I wish to thank Dr. L. N. Katz for his guidance in preparing this case report.

REFERENCES

1. Lichtman, S. S.: Arch. Int. Med. 48: 683, 1931.
2. Gorter, E.: Acta paediat. 4: 125, 1925.
3. Meyer, P.: Arch. d. mal. d. coeur 16: 16, 1923.
4. Abrahamson, L.: Quart. J. Med. 18: 335, 1924.
5. Ackerman, W., and Katz, L. N.: Am. Heart J. 8: 490, 1933.
6. Meek, W. I., Wilson, A.: Arch. Int. Med. 36: 614, 1925.
7. Nathanson, M. H.: Proc. Soc. Exper. Biol. & Med. 28: 766, 1931.
8. Katz, L. N., and Robinow, M.: Am. J. M. Sc. 192: 556, 1936.
9. Katz, L. N.: Unpublished.
10. Katz, L. N., and Korey, H.: Am. J. Physiol. 3: 83, 1935.
11. Katz, L. N., Gutman, I., and Ocko, F.: Am. J. Physiol. 116: 302, 1936.
12. Katz, L. N., Sigman, E., Gutman, I., and Ocko, F.: Am. J. Physiol. 116: 343, 1936
13. Robinow, M., Katz, L. N., and Bohning, A.: Am. Heart J. 12: 88, 1936.
14. Katz, L. N., Saphir, O., and Strauss, H.: Am. Heart J. 10: 542, 1935.

CARDIAC RUPTURE ASSOCIATED WITH METASTASES TO THE HEART FROM CARCINOMA OF THE DUODENUM*†

W. L. McNamara, M.D., E. F. Ducey, M.D., and
Lyle A. Baker, M.D.
Los Angeles, Calif.

THE chief interest in the case reported in this paper lies in the fact that rupture of the heart was occasioned by metastatic carcinoma. Of minor interest are the facts that the primary tumor occurred in the duodenum, a site in which the occurrence of carcinoma is comparatively rare, and that there existed, coincidentally, the end stages of rheumatic heart disease, the patient being in a state of extreme decompensation when death occurred.

Because the patient had been under observation and treatment for rheumatic heart disease for a number of years, the gastrointestinal symptoms were readily attributed to the state of cardiac decompensation, and the tumor of the duodenum was not recognized clinically. The death was clearly cardiac, and, when the case came to postmortem examination, there was nothing to indicate that anything beyond the typical pathological changes of rheumatic heart disease would be revealed.

CASE REPORT

W. B. M., a white man, aged forty-eight years, entered the hospital on Oct. 25, 1930, complaining of dyspnea, palpitation and headache.

Family History.—Mother died of cancer of the stomach; father died of kidney disease; three sisters and one brother living and well; one sister had heart trouble. Marital history was negative.

Past History.—The patient had the usual diseases of childhood. There was no history of scarlet fever or rheumatic fever; however he had had rheumatic pains in various joints for many years; he had gonorrhea in 1898 and influenza in 1918.

Present Illness.—The patient stated that he had known he had heart trouble since 1923, when a physician told him he could never do manual labor again. Since that time he had become exhausted on slight exertion and experienced palpitation in the epigastrium on exertion or after eating a heavy meal.

For the past three years he had been incapacitated for work.

Physical Examination.—Physical examination showed a well-developed, poorly nourished man. He was pale and the lips were cyanotic. The chest showed marked muscular atrophy and bilateral restricted motility. The resonance was impaired in both upper lobes posteriorly and breath sounds were subdued.

The examination of the heart showed the apex in the sixth interspace, 3 cm. to the left of the midclavicular line. The heart was greatly enlarged to the left and downward. A loud diastolic rumble was transmitted to the axilla, ending in a loud first sound immediately followed by a soft second sound.

At the base was a soft, systolic murmur heard first in the right interspace. The rhythm was irregular, and the volume of the sounds varied greatly. The blood pressure before exercise was 110/58; after moderate exercise it was 110/60, and the lips showed increased cyanosis.

---

*From the Pathological Laboratory and Cancer Service; published under R. & P. 6969, U. S. Veterans Administration.

†Read before the Los Angeles County Pathological Society, January 14, 1936.

Abdominal examination revealed nothing of interest, nor did examination of the genitals, rectum, or extremities.

The clinical diagnosis of mitral insufficiency and stenosis, with possible tricuspid disease and chronic myocarditis was established. Repeated Wassermann tests were negative. The report on the roentgenographic examination was cardiac hypertrophy and old pleuritis. The electrocardiographic examination on Oct. 30, 1930, revealed auricular fibrillation with evidence of myocardial damage. The patient was given digitalis, and a second electrocardiogram on Nov. 13, 1930, showed evidence of digitalization.

Fig. 1.—Heart, lateral wall of auricle dissected away. Note tumor infiltration of wall, the calcified "fish mouth" type of mitral valve, and the shaggy hemorrhagic exudate covering the epicardium.

The patient was in the hospital for the next three and one-half years. At times he was better and at times worse. He suffered a dull, precordial pain, which at times became sharp, and he required hypodermics on several occasions.

Against advice, he insisted on leaving the hospital in April, 1934. He was readmitted a few weeks later stating that while he was away the pain became worse, he suffered marked vertigo and blurring of vision and could not take care of himself. He developed a chronic cough with sputum, and a marked degree of bloating and heartburn. A burning, epigastric pain developed one to two hours after meals, and he vomited blood on several occasions. Sippy powders gave him no relief. The patient gradually displayed signs of congestive heart failure with edema of the extremities.

The treatment was supportive and symptomatic. Digitalis and sedatives were given as indicated. Decompensation was marked by May, 1934. Cardiac distress became increasingly severe. The patient had been in a relative state of comfort until Oct. 31, 1935, when he suffered "an attack of pain in the heart, difficult breathing and a feeling of internal spasm" (the words of the nurse on the chart). From this time until his death he complained of great agony and received a constant succession of hypodermics of morphine.

He rapidly became moribund and died Nov. 17, 1935. The cause of death was ascribed to cardiac failure in rheumatic heart disease.

Post-Mortem Examination.—The body was that of a well-developed, slightly emaciated, white male.

Fig. 2.—Section of duodenum showing the diffuse infiltrating character of the tumor. (×150.)

Heart.—The pericardial sac was enormously distended, extending from the left anterior axillary line to the right beyond the right sternal border, and was filled with dark red blood clot, and some free unclotted blood, measuring in all about 500 c.c. The heart was greatly enlarged. The surface was covered with reddish, fibrinlike material which was quite firmly adherent to the epicardium. It had the gross appearance of hemopericardium. The heart weighed 700 gm. The left auricle was enormous, measuring 10 cm. in diameter. It was firmly adherent to the parietal pericardium, and, when an attempt was made to remove the heart, the auricular wall tore and a large portion remained attached to the parietal pericardium. The wall of the auricle was thickened to 8 mm. The endocardial surface was covered with a verruca-like growth which covered practically the entire endocardial surface, including the surface of the mitral valve. It also apparently involved the entire wall of the auricle and showed evidence of ulceration. The point of rupture was found on the posterior wall in the portion that was adherent to the pericardium.

There was marked hypertrophy of the left ventricle and a moderate degree of hypertrophy of the right ventricle. The mitral valve showed a fish-mouth type of deformity. The leaflets were fused, leaving a narrow slit, 4.5 cm. in length. The fused leaflets were thickened and showed evidence of calcification. The surface of the valve was covered with the same verruca-like material found involving the wall of the auricle and covering the endocardial surface. The aortic valve showed evidence of some old inflammatory lesion, probably rheumatic. The leaflets were partially fused with a beadlike effect on the edges of contact, causing stenosis and insufficiency. The pulmonary and tricuspid valves showed no gross lesion aside from dilatation. There was quite marked coronary atherosclerosis and moderate atherosclerosis of the aorta.

Fig. 3.—Section taken from the heart wall showing a morphological structure identical to that seen in the duodenal tumor. (×150.)

Lungs.—The combined weight of the lungs was 1,280 gm. Both showed the same picture, a number of ragged adhesions and on section a number of small patches of bronchopneumonia at each base. Mediastinal nodes were not enlarged.

Abdomen.—The peritoneum was smooth; there was no free fluid and no evidence of glandular enlargement. The liver weighed 1,700 gm. It was rather mottled, soft, and friable and on section the nutmeg markings of chronic passive congestion were noted. The spleen weighed 140 gm., was red and quite firm; on section it showed quite marked passive congestion. There was a red infarct at the upper pole, measuring 1 cm. in diameter. The gallbladder, adrenals, pancreas, bladder, prostate, and testes showed no gross pathological lesion.

Genitourinary Tract.—The combined weight of the kidneys was 250 gm., both showing the same picture. The capsule stripped readily, leaving a surface with a number of deep infarction pits. These pits were old and healed. On section

the cortex was rather thin and somewhat irregular. There was a mild vascular thickening.

Gastrointestinal Tract.—The stomach was slightly dilated, otherwise it showed nothing unusual. On the posterior wall on the duodenal side of the pyloric ring, there was noted a small ulcer 5 mm. in diameter. The walls and base were indurated, and the edges were crateriform. The lesion showed active ulceration with some bleeding. The remainder of the gastrointestinal tract showed no gross pathological change. The regional lymph nodes were not enlarged.

Microscopic Examination.—Sections of the duodenal wall at the region of the tumor showed a diffuse, infiltrative type of newgrowth. The cells were round, oval, or polyhedral and showed marked variation in size. The nuclei were relatively large and somewhat hyperchromatic. For the most part the cells were growing in columns and cords and infiltrated diffusely. There was some attempt at alveolar formation, but for the most part it was quite anaplastic. There was practically no desmoplasia. It was noted that the mucosa at the site of the lesion is gastric, rather than duodenal in type. The transition of the characteristics of the gastric to the duodenal mucosa is gradual and, in this instance, while the lesion was geographically duodenal, it was histologically gastric.

Heart.—The myocardium of the left auricle was infiltrated by epithelial cells having the same appearance as those noted in the tumor of the duodenum. Certain microscopic fields in the auricular muscle and in the duodenal tumor were identical in appearance. The endocardium of the left auricle was covered with a layer of closely packed epithelial cells of the same appearance. A section through the mitral valve revealed old fibrosis, calcification and some degeneration. The endocardium of the auricular surface of the valve showed a superimposed layer of anaplastic epithelial cells, identical to those seen in the auricular muscle and in the duodenal tumor. The microscopic study of sections of the various other organs did not reveal evidences of tumor.

COMMENTS

Metastatic carcinoma in the heart is not rare, but it is most frequently a part of a generalized dissemination, rather than the only demonstrable site as in this case. Burke[1] reports a series of fourteen cases found at autopsy among 327 cases of known malignancy. In none of these cases was the metastasis confined to the heart. Our experience is in accord with that of Burke, Heninger,[2] and others, who note that it is practically impossible to diagnose the condition during life. Burke states that the cases in his series had been studied for a period of time prior to death, that x-ray plates of the chest had been made at intervals, and that there was nothing to suggest the presence of metastasis. Osler[3] notes that secondary tumors of the heart are usually without symptoms, even when the disease is extensive.

Rupture of the heart is a rare occurrence in consideration of the great frequency of pathological conditions of the heart. It is, however, not so rare as a scarcity of the report of cases in the literature would indicate. Krumbhaar and Crowell[4] (1925) collected 654 cases. Davenport[5] (1928) was able to collect 710, 35 of which had been reported since 1925 and 50 of which had been omitted by Krumbhaar and Crowell. Spontaneous rupture of the heart is, in the overwhelming majority of cases, the result of coronary disease, and is precipitated by thrombosis or embolism. Benson, Hunter, and Manlove,[6] in

a recent paper stress that, while the outstanding cause of cardiac rupture is coronary sclerosis, rupture of the heart may occur if the myocardium is weakened by disease other than that of the nutrient arteries. These authors note that rupture caused by gummas of the heart have been described chiefly in the older literature. Also, there are authentic reports of rupture caused by lesions of tuberculosis.[7] Among the rare causes of cardiac rupture may be listed echinococcus disease.[8]

The case of cardiac rupture caused by metastatic carcinoma reported in this paper is without parallel in the literature, as far as we can ascertain.

Benson, Hunter, and Manlove note malignancy as a possible cause of cardiac rupture but add that Mayer was unable to find such an instance in the reports to 1888, and Jores in 1924 failed to find any in the more recent literature. In the series studied by Krumbhaar and Crowell, a melanotic sarcoma is ascribed as the cause of cardiac rupture. The reference is not given, and there are no details of the case. In 72 per cent of the series of Krumbhaar and Crowell, death was described as sudden. They note that in certain rare cases, death was reported as occurring days or weeks after the rupture and in one case a month later. Osler described a case of rupture in which the man walked up a steep hill after the onset of symptoms and lived for thirteen hours. In the case reported in this paper, it would appear that the rupture occurred on Oct. 31, 1935, at which time the patient was stricken with severe agony which never ceased until death occurred seventeen days later.

SUMMARY

Metastases to the heart from a primary carcinoma in the duodenum weakened the myocardium and precipitated cardiac rupture in a patient with rheumatic heart disease. The case is without parallel in the literature, as far as we can ascertain.

REFERENCES

1. Burke, E. M.: Metastatic Tumors of the Heart, Am. J. Cancer 20: 33, 1934.
2. Heninger, B. R.: Clinical Aspects of Pericardial Metastases, Ann. Int. Med. 7: 1359, 1934.
3. Osler, William: Principles and Practice of Medicine, New York and London, 1919, D. Appleton & Co.
4. Krumbhaar, E. B., and Crowell, C.: Spontaneous Rupture of the Heart, Am. J. M. Sc. 170: 828, 1925.
5. Davenport, A. B.: Spontaneous Heart Rupture, Am. J. M. Sc. 176: 62, 1928.
6. Benson, R. L., Hunter, W. C., and Manlove, C. H.: Spontaneous Rupture of the Heart, Am. J. Path. 9: 295, 1933.
7. (a) Korybut-Daszkiewicz, B.: La Tuberculose du coeur chez les enfants, Arch. de méd. d. enf. 25: 150, 1922. (Abst. J. A. M. A. 78: 1930, 1922.)
   (b) Oudendal, A. J. F.: Ueber ein Geval van Tuberculose der Hartspier mit Spontane Hartscheur, Nederl. tijdschr. Geneesk. 67: 2087, 1923. (Abst. J. A. M. A. 81: 1060, 1923.)
   (c) Brandi, B.: Spontanruptur für der tuberkulösen rechten Herzwand, Deutsche Ztschr. f. Chir. 231: 255, 1931.
8. Hynd, D.: Echinococcus of the Heart, Brit. M. J. 2: 277, 1924.

ORTHOSTATIC HYPOTENSION TREATED WITH BENZEDRINE*

Report of Case

Horace Marshall Korns, M.D., and William Lloyd Randall, M.D.
Iowa City, Iowa

ONLY about twenty-two satisfactory cases of orthostatic hypotension are on record. The first inklings of this curious syndrome are to be found in C. Laubry's brief mention[1] of a case which was referred to him in 1891 by Babinski. The patient, a man forty-eight years of age, suffered from vertigo and astasia abasia, but no evidence of disease of the central nervous system could be found. Quite by accident, Babinski discovered that the patient's arterial pressure was unusually low, whereupon he sent him to Laubry, whose careful observations demonstrated beyond question the orthostatic nature of the hypotension. In 1932, after Bradbury and Eggleston's definitive study[2] had established the essential characteristics of the syndrome, Laubry[3] reported his case in greater detail.

The pathogenesis of orthostatic hypotension, as Grace Roth[4] points out in her excellent discussion, is still largely a matter of speculation, and no uniformly successful treatment has been discovered. Although ephedrine has helped somewhat in a few cases, including our own, it has failed more often than it has succeeded. Our use of a new drug, together with the fact that the number of recorded cases is so small, prompted us to report the following additional case.

REPORT OF CASE

History.—The symptoms developed in characteristic fashion. In 1930, at the age of fifty-eight years, the patient, whose health had always been excellent, noticed for the first time that he was losing his strength and endurance. His appetite began to fail, and his weight declined slowly, but he did not become completely disabled until, in 1933, he began to experience attacks of faintness, sometimes attended with actual vertigo. He soon discovered that these attacks never occurred except when he was on his feet and could be terminated promptly by sitting or lying down. They kept recurring with increasing frequency, and eventually became so severe that syncope supervened. He always regained consciousness almost as soon as he fell, and, except for transitory weakness, or unless injured by the fall, as he was on several occasions, felt none the worse for the experience. Fatigue was obviously not a factor in these attacks, for they were more likely to occur upon first arising in the morning than at any other time of the day, but there was no doubt about the influence of hot weather, which intensified all the symptoms to such an extent that it was almost impossible for the patient to get on his feet. Yet he never had

*From the Department of Internal Medicine, State University of Iowa.

heat stroke or heat exhaustion. It was perhaps more than a coincidence that, when he became intolerant of heat, he lost the ability to perspire freely. Except for negligible areas in the axillae and lumbar region, his anhidrosis eventually became complete. Nocturnal diuresis, loss of libido, and impotence were additional features of the history.

The syncope was manifestly not epileptic, for it was not attended with convulsions, biting of the tongue, or foaming at the mouth, never occurred while the patient was asleep, and was not preceded by a true aura or followed by somnolence, mental confusion, and headache. Moreover, there was nothing in the history to indicate primary labyrinthine or other intracranial disease, and the fact that no pronounced abnormality of the heartbeat preceded or accompanied the syncope excluded the possibility of cardiac origin. The progressive asthenia, syncope, anorexia, and gradual loss of weight (20 pounds in the course of several years), together with a rather vague story of occasional nausea, vomiting, and colic, suggested Addison's disease, but there had been no abnormal deposition of pigment in the skin or unnatural craving for salt.

Physical Examination.—The patient was a white male, sixty-three years of age. About twenty-four hours before his admission to the University Hospital he was seized with an afebrile diarrhea so severe that when he arrived he was considerably dehydrated, barely conscious, and almost in shock. He had already developed several large hemorrhoids and shortly after admission passed a liquid stool mixed with dark red blood. (Subsequent investigation led to the conclusion that the hemorrhoids must have been responsible for this gross bleeding, as well as for the traces of blood which were present in the feces for months thereafter. This continual loss of blood was probably a factor in his secondary anemia.) With the passage of this bloody stool the diarrhea came to an abrupt end; the patient had never experienced anything of the kind previously, and he has not suffered a recurrence. On admission the arterial pressure measured only 60/40 mm. Hg. but under the circumstances such a low level attracted little attention, more especially because, with the patient confined to bed, it rose to normal within a few days.

After the patient recovered from his acute enterocolitis he was wide-awake and cooperative. The skin was extraordinarily youthful and almost milk white. The sclerae were not icteric. The pupils reacted satisfactorily to light and in accommodation, and the fundi were negative to ophthalmoscopic examination. The head was covered with a plentiful growth of gray hair. The ears, nose, face, lips, tongue, buccal mucosa, palate, and pharynx were not remarkable. The teeth were carious. There was no enlargement of the thyroid gland or cervical lymph nodes. A lipoma of moderate size was present on the nape of the neck.

Examination of the lungs revealed no modification of their extensibility, volume, or density, and no râles. The heart was not enlarged, and there were no endocardial murmurs, but the heart sounds were rather faint. The rate and mechanism of the heartbeat were normal. The aorta was not abnormally accessible. The volume and contour of the arterial pulse were normal. A moderate amount of peripheral arteriosclerosis was present. Examination of the abdomen showed no enlargement of the liver or spleen, no free fluid, and no adventitious masses. Rectal examination disclosed several large internal hemorrhoids. The genitals and extremities were entirely negative, and there were no signs of disease of the central or peripheral nervous system.

Laboratory Examination.—At the time of his admission, when the patient was considerably dehydrated, a somewhat paradoxical situation existed. Anhydremia might well have accounted for the presence in the urine of traces of albumin and a few casts, for the low carbon dioxide combining power of the blood (31.5 volumes per cent), and for the apparent retention of nitrogen (urea 71.4 mg. per cent, uric

acid 7.2 mg. per cent, creatinine 4.5 mg. per cent), but it was difficult to understand how dehydration as severe as this could leave the blood chlorides undisturbed (625 mg. per cent) and not cause an apparent increase in the hemoglobin and cellular content of the blood. The hemoglobin content was 72 per cent; the erythrocyte count, 3,790,000; and the leucocyte count, 9,400; and these figures did not change appreciably after the dehydration had been relieved. Furthermore, the apparent retention of nitrogen vanished completely within seventy-two hours (urea 17.5 mg. per cent, uric acid 4 per cent, creatinine 1.2 mg. per cent), but more than a week elapsed before the albumin and casts disappeared. It is therefore doubtful whether the initial acidosis and nitrogen retention were as pronounced as they were made to appear. Eleven subsequent estimations, made at intervals over a period of three months, never showed any retention of nitrogen.

The blood Wassermann reaction was negative. The gastric juice contained no free hydrochloric acid, even after the ingestion of alcohol and the subcutaneous injection of 1/44 grain of histamine. Roentgenologic examination disclosed no evidence of disease of the stomach, duodenum, colon, adrenal glands, lungs, heart, or aorta. The oxygen consumption was 10 per cent below normal. The electrocardiograms revealed nothing of importance; those made in the erect posture showed inversion of the T-wave in Lead III.

Subsequent Course.—The definite tendency toward hypotension, which became clearer as time went on, made it imperative to exclude, once for all, the possibility of Addison's disease. The fact that a large intake of salt and the administration of 5 c.c. of eschatin per diem for twenty-two days brought about no amelioration was perhaps not conclusive, but crucial evidence was obtained when a salt-free diet rich in potassium was tolerated by the patient for eleven days without the slightest aggravation of his symptoms. The plasma chlorides remained at a normal level throughout the period of chloride deprivation.

After it dawned on us that posture might have something to do with the patient's symptoms, it was discovered that a startling fall of arterial pressure occurred when he assumed the upright position. The following are illustrative of a long series of measurements made over a period of many weeks:

Supine	Sitting	Standing
112/85 mm.	85/60 mm.	55/40 mm.

The lowest pressures occurred in the mornings. Syncope threatened whenever the maximum systolic level fell to 55 mm. Hg, or below. Although the heart rate was not totally unresponsive to changes in posture and blood pressure, as it has been in so many of the cases previously reported, the extent of the response depended largely on what the rate was in the supine position. If it was 80 with the patient lying on his back, it might increase to 88 when he sat up, and to 100 when he stood on his feet, but, if it was 100 when he was recumbent, it did not accelerate appreciably as he stood up. Neither pressure on the carotid sinus nor the intravenous injection of 1/150 grain of atropin had any effect on the heart rate or blood pressure. The administration of 1/8 grain of pilocarpine by mouth exerted almost no diaphoretic effect.

In the midst of his hospital stay the patient developed severe pharyngitis and tonsillitis, accompanied by fever and prostration, and followed by widespread erythema multiforme, from which he recovered completely in two weeks' time.

Summary.—The principal features of the history were the progressive asthenia, anorexia, loss of weight, syncope conditioned on the erect posture, anhidrosis, intolerance of heat, nocturnal diuresis, loss of libido, and impotence, without evidence of craving for salt, pigmentation of the skin, epilepsy, intracranial disease, or disorder of the heartbeat. Examination by clinical and laboratory methods revealed

a pale, not abnormally pigmented skin, carious teeth, a lipoma on the nape of the neck, no evidence of heart disease, a not entirely normal response of the heart rate to changes in posture and blood pressure, orthostatic hypotension with syncope, slight peripheral arteriosclerosis, internal hemorrhoids, no abnormalities of the nervous system, slight secondary anemia, a negative blood Wassermann reaction, no nitrogen retention, achlorhydria, no roentgenologic evidence of disease of the alimentary tract or adrenal glands, a basal metabolic rate of -10 per cent, normal electrocardiograms, and no aggravation of symptoms with a salt-free diet rich in potassium.

Diagnoses.—Orthostatic hypotension; internal hemorrhoids; secondary anemia; intercurrent enterocolitis; intercurrent pharyngitis, tonsillitis, and erythema multiforme.

TREATMENT

The following table summarizes the effect of ephedrine and benzedrine on the arterial pressure. The measurements are representative of a large series; all of them were made at the same time of day.

TABLE I

	SUPINE	SITTING	STANDING
Untreated	112/85	85/60	55/40
Ephedrine			
48 mg. at 6 and 8 A.M.; 24 mg. at 10 A.M., 12 M., and 2 and 4 P.M.	140/88	130/80	80/60
48 mg. at 6, 8, and 10 A.M., 12 M., and 2, 4, and 6 P.M.	150/90	140/90	100/75
Benzedrine			
20 mg. at 5 and 6 A.M.; 10 mg. at 8 and 10 A.M., 12 M., and 2 and 4 P.M.	115/80	100/80	80/60
20 mg. at 6, 8, and 10 A.M., 12 M., and 2, 4, and 6 P.M.	115/80	100/70	70/55
40 mg. at 6 A.M.; 30 mg. at 8 A.M.; 20 mg. at 10 A.M., 12 M., and 2 P.M.; 10 mg. at 4 and 6 P.M.	140/95	120/80	75/65
Ad libitum	120/80	110/75	75/60

On the whole, the patient liked benzedrine better than ephedrine because it made him less tremulous, induced less insomnia, and was perhaps somewhat more effective in dispelling his weakness. However, if amounts of either drug sufficiently large to maintain the blood pressure within normal limits were employed for more than a few days at a time, it became difficult, even with full doses of the various barbiturates, to overcome the consequent insomnia. After the patient returned to his home he continued to take 100 to 150 mg. of benzedrine a day. Except in warm weather, this amount was sufficient to keep him comparatively comfortable. He felt better than he had for many years, and even began to perspire over his back and shoulders. No ill effects of continuous medication with benzedrine were noted.

COMMENT

Our experience in this case suggests that benzedrine is worthy of further trial in the symptomatic treatment of orthostatic hypotension. If it should not actually supersede ephedrine, at least it may prove to be a welcome alternative in some cases.

REFERENCES

1. Laubry, C.: Leçons de sémiologie cardio-vasculaire (Art. Vertige, p. 339), Paris, 1924, G. Doin.
2. Bradbury, S., and Eggleston, C.: Postural Hypotension, Am. Heart J. 1: 73, 1925.
3. Laubry, C., and Doumer, E.: L'hypotension orthostatique, Presse méd. 40: 17, 1932.
4. Editorial on Posture and Blood Pressure, Ann. Int. Med. 9: 638, 1935.

Department of Reviews and Abstracts

Selected Abstracts

Bronk, D. W., Ferguson, L. K., Margaria, R., and Solandt, D. Y.: The Activity of the Cardiac Sympathetic Centers. Am. J. Physiol. 117: 237, 1936.

The activity of the cardiac sympathetic centers has been investigated by recording the action potentials in the cardiac nerves from the stellate ganglia of the cat.

There is a fairly continuous discharge of impulses which exert a "tonic" augmentor and accelerator influence upon the heart. This discharge is, however, largely modified by changes in the chemical composition of the blood and by afferent impulses.

The principal pathways of the impulses from the cord to the stellate ganglion are the third and fourth and to a lesser extent the second and fifth thoracic rami.

The impulse frequency from the individual sympathetic motor nerve cells seldom exceeds ten or fifteen a second, and is usually considerably less. This contrasts with the much higher frequency of discharge from somatic motor nerve cells.

The potential pulses in the postganglionic nerves are of considerable magnitude because of the grouping of impulses which results from the innervation of many postganglionic fibers by a single preganglionic fiber.

There are also much larger potential waves caused by the synchronous activity in very many nerve fibers. It is shown that this is due to the coordinated and rhythmic discharge from large numbers of nerve cells in the centers. This activity is bilaterally synchronous.

The grouped activity is of four types. The volleys may come at irregular intervals or at other times periodically with frequencies varying from 5 to 20 sec. but unrelated to any other obvious rhythm of the organism. Or, on the other hand, the bursts of impulses may be synchronous with the pulse or the respiratory cycle.

The latter two forms of rhythmic cellular activity are largely due to afferent impulses from the viscera: bursts of impulses from the blood vessels initiated by the systolic rise in pressure or the impulses from distention receptors in the lungs.

An example of the marked effect of such afferent impulses upon the activity of the sympathetic centers is found in the observation that it is possible to drive those centers by repetitive stimulation of the central ends of the carotid sinus or aortic nerves, thus causing the motor nerve cells to discharge periodically with the frequency of the afferent impulses. This can be done within a limited range of stimulus frequencies.

The characteristically grouped discharges from the cardiac sympathetic centers cause periodic variations in heart rate only if the bursts of efferent impulses are separated by some seconds. This is due to the inertia of the effector mechanism.

AUTHOR.

Essex, Hiram E., Herrick, J. F., Baldes, Edward J., and Mann, Frank C.: Blood Flow in the Circumflex Branch of the Left Coronary Artery of the Intact Dog. Am. J. Physiol. 117: 271, 1936.

By the use of the thermostromuhr of Rein, experiments have been made on the blood flow in the circumflex branch of the left coronary artery of the intact dog. Observations have been made over periods as long as fourteen days.

Epinephrine causes a transient but marked increase in coronary blood flow, amounting in some experiments to as much as four or five times the control values. The coronary blood flow is doubled by administration of nitroglycerin or amyl nitrite, but the effect is of short duration. In response to appropriate doses of thyroxin, increases in coronary flow as great as 244 per cent above the control values were observed forty-eight to ninety-six hours after injection.

During the digestion of a meat meal the coronary flow was increased to a degree comparable to what has been observed in other vessels of the body. Exercise on a treadmill produced an initial rapid augmentation in coronary flow, which declined to a lower level as the exercise continued but additional work induced by changing the angle of the treadmill again caused a temporary increase in coronary flow, which declined to a lower value as the same degree of exercise continued.

A significant correlation between heart weight and coronary flow or between pulse rate and coronary flow was not found.

AUTHOR.

Donal, John S., Jr., and Gamble, Clarence J.: The Cardiac Output in Man. Am. J. Physiol. 116: 495, 1936.

The simultaneous values of oxygen tension and of carbon dioxide tension in the lungs were computed for hypothetical experiments of the type used in the triple extrapolation method of Redfield, Bock, and Meakins (1922) for estimating the cardiac output in man. When each computed value of carbon dioxide tension was plotted as a function of the computed oxygen tension, the points were found to lie on curves and not on straight lines as is assumed in the triple extrapolation method.

The plotting of analyses of successive samples taken during continuous rebreathing gave curves with the same characteristics as those calculated from theoretical considerations.

Pairs of such curves were constructed from experiments on ten subjects. When these were extrapolated by the linear procedure of the triple extrapolation method the venous tensions found were different from those indicated by the convergence of the curves. Because of the tensions in the rebreathed mixtures chosen for these experiments, these differences were greater for carbon dioxide than for oxygen.

Cardiac outputs of these subjects determined at the same time by the ethyl iodide method agreed more closely with a curved than with a linear extrapolation.

It is concluded from these results that when gases are rebreathed or held in the lungs, variations in carbon dioxide and in oxygen tensions cannot be assumed to be directly proportional to each other. In consequence, the triple extrapolation method for the estimation of blood flow which Redfield, Bock, and Meakins have based on such an assumption cannot be expected to give reliable results.

In eleven rebreathing experiments, return to the lungs of blood abnormally low in oxygen content was evident at an average time of 24.5 sec., after the beginning of rebreathing. Recirculation of blood high in carbon dioxide was less readily detectable and was not evident until a later time.

AUTHOR.

Pfuhl, Wilhelm: The Lapse of Cardiac Contraction as Affected by Intrathoracic Function. Deutsches Arch. f. klin. Med. 247: 179, 1936.

The author states that the emptying of the heart by contraction of the muscle is a relatively simple phenomenon compared with the refilling of the heart during diastole. No original experiments are brought to bear on the subject. Older work is frequently cited, and the paper takes the form of a thorough discussion of the possible factors involved. The conclusions are, however, interesting. He believes that a considerable portion of the energy for filling the ventricles is derived from

the preceding systole in two ways: 1. The shortening of the ventricle pulls down the plane of the valves and draws blood into the auricles. 2. The decrease in size of the heart extends the lungs slightly, and these in returning to their previous state during the next diastole draw blood into the auricles. Then the auricle contracts and fills the ventricle. Only during auricular contraction, therefore, does blood cease to flow into the heart. He concludes also that high negative intrathoracic pressure, through increased filling of the heart, is associated with high systemic arterial pressures.

J. M. S.

Dieckhoff, Josef: The Capacity for Work of Hearts With Insufficient Aortic Valves With and Without Hypertrophy in Heart-Lung Preparations and the Effect of Digitalization. Arch. exper. Path. u. Pharmakol. 182: 268, 1936. **The Sensitivity to Digitoxin and Strophanthin of Hearts With Insufficient Valves With and Without Hypertrophy.** Ibid. p. 285. **The Action of Thyroxin Upon the Capacity for Work and Upon the Strophanthin Sensitivity of the Cat's Heart.** Ibid. p. 292.

Consideration of these three papers together is done for brevity. Each investigation appears to have been planned and executed with care. The animals used were cats. The aortic valves were injured by the method of Rosenbach (thrusting through the valve from the right carotid artery a large club-headed sound). The hearts without hypertrophy were used within one to fifteen days. Hypertrophied hearts were used from 100 to 150 days after operation. The capacity of the hearts for work was tested in heart-lung preparations in three ways: first, by increasing the arterial pressure, second, by increasing the venous pressure (increasing the output), and third, by noting the duration of life of the preparation. Three to five preparations of each type of heart to be compared were used.

In the first paper (1) normal hearts and (2) hearts with aortic insufficiency without hypertrophy, and (3) with hypertrophy were examined.

The hearts with recently injured valves appeared to be impaired according to all three criteria, failing to maintain as high pressures or as large outputs or to live as long as the normal and hypertrophied hearts. The extraordinary capacity of the hypertrophied hearts was emphasized by an ingenious experiment. A rubber valve was substituted for the injured aortic valve. When this was done, the hearts with recently injured valves compared favorably with the normal hearts, and the hypertrophied hearts outlasted the normals in every way. The third series of experiments compared normal hearts with two groups of hearts whose aortic valves were recently injured. In one group the cats had been thoroughly digitalized in the four days prior to the making of the preparation. The capacity of the "prophylactically digitalized" hearts for work was decidedly better than that of the undigitalized hearts with aortic insufficiency but was less than that of the normal hearts.

The second paper deals with the lethal dose of digitoxin and strophanthin administered to the same types of hearts used in the preceding paper. In one set of experiments digitoxin was given to the whole animal, in another set, to heart-lung preparations. The results were clear. Before hypertrophy occurred in the hearts with aortic insufficiency, they exhibited approximately the same sensitivity to digitoxin or strophanthin as normal hearts. After hypertrophy occurred, the lethal dose was diminished by from 22 to 47 per cent and appeared to be related to the degree of hypertrophy. The difference between the group was so marked that whether the dose was reckoned on a basis of the weight of the whole heart, per gram of heart, or per kilogram of animal, made little difference to the conclusions. The results were the same in heart-lung preparations as in intact animals.

The third paper shows, by means of heart-lung preparations, employing the tests used in the first paper for comparing capacity for work, that this function diminishes when thyroxin is fed to the animals for ten days prior to the making of the preparation and that with longer feeding (three weeks) the decline is greater. Furthermore, the sensitivity to strophanthin of hearts of cats which have been receiving thyroxin for longer than three weeks is markedly increased. The conflicting reports of earlier workers on the question of whether thyroxin increases the sensitivity of the heart to the action of strophanthin are explainable because, when thyroxin has been fed for less than two weeks, no change from normal is found.

J. M. S.

Segura, Angel S.: Registration and Interpretation of Cardiovascular Activity in the Normal Infant. Rev. argent. d. cardiol. 3: 3, 1936.

The most striking result obtained by recording optically the heart sounds in 120 normal infants from birth to two years of age was the finding of three sounds per cycle in a great proportion (38 per cent). The moment of occurrence of this third sound and its time relation with the ordinary first and second heart sound and with the P-wave of the electrocardiogram sufficiently warrant the assumption that it is due to auricular systole.

The phonocardiographic records show that the first heart sound of infants and young children has a duration ranging between 0.064 and 0.172 sec., with the majority of the results falling between 0.10 and 0.14 sec., the fundamental frequency being very constantly of about 40 per second. The first heart sound is the most intense on the mesocardiac area.

The second heart sound lasts for between 0.045 and 0.164 sec., the majority of the results ranging from 0.055 to 0.10 sec., its fundamental frequency being also about 40 per second.

The auricular sound (visible in 38 per cent of the cases and easily recognizable as vestigial vibration in another 31 per cent of the total number) is 0.06 ± 0.001 sec. before the onset of ventricular systole. It lasts for about 0.057 sec. and shows a fundamental frequency of about 40 per second (average$=39 \pm 0.68$). The intensity of the auricular sound is the lowest as compared with that of the other sounds.

No true reduplication of either the first or the second sound was ever recorded. There was no instance in the records of the so-called physiological third heart sound.

The duration of the silent periods between the first and second sounds and between the second and the following first was practically the same in all cases.

AUTHOR.

Segura, A. S.: Registration and Interpretation of Cardiovascular Activity in the Normal Infant. Rev. argent. de cardiol. 3: 85, 1936.

Fontanellar Pulse.—Optical tracings (Frank's method) of the fontanellar pulse are easily obtained in infants after the first month of life. The record is somewhat similar to that of the central arterial pulse recorded in adults. It affords important information concerning the rhythmicity of the heartbeat and (if recorded with the heart sounds) the approximate duration of the isometric contraction and ejection phases. The fontanellar pulse starts between 0.04 to 0.05 sec. after the first heart sound, this interval increasing with the age. The same relation can be found with the top of the R-wave of the electrocardiogram simultaneously recorded. The ascending limb is relatively steep, forming a 95° to 110° angle with the horizontal.

Femoral and Tibial Pulses.—An optical record may be obtained by means of a pneumatic cuff, a sphygmoscope, and a segment capsule. The record in both cases

shows a quite simple contour with no evident dicrotic wave. The femoral sphygmogram, showing a rounded top during the first days of life, tends to become angular with the increase of age. It starts between 0.072 to 0.084 sec. (averages according to different ages) after the beginning of the first heart sound. This delay may be still longer in older children. The ascending limb is less steep than the corresponding limb of the fontanellar pulse, the angle ranging between 101° and 130°, with the majority of the results falling between 105° and 125°. The tibial pulse record always shows a rather angular top, its amplitude is smaller, and its delay is longer (0.105 sec.) as compared with the femoral pulse record. Its ascending limb is still less steep.

AUTHOR.

Echague, E. Soaje: Electrocardiographic Alterations Produced by Typhoid Fever in Children. Rev. argent. de cardiol. 3: 122, 1936.

Electrocardiograms recorded in 88 children suffering from typhoid fever showed frequent alterations in 53 per cent ± 3.5 of the patients under observation. The electrical axis was deviated to the right in 11.84 per cent ± 2.51 of the cases during the acme state, the fact coinciding with hypertoxic manifestations. There were not alterations of excitability, a sinus arrhythmia being observed only during convalescence in the proportion of 33.78 per cent ± 4.11. The A-V conduction time was alterated in 10.20 per cent ± 2.35 of the patients during the acme and in 19 per cent during the convalescence. The QRS complex was widened during the acme in 2.63 per cent ± 1.06, and a low voltage of R-wave was encountered during the same period in 11.84 per cent ± 2.51 of cases, these alterations ceasing completely during convalescence. The alternations of T_1 and T_2 reached 18.42 per cent ± 3.01 and also disappeared altogether during the convalescence. Inversion of T_3 in 47.36 per cent ± 3.78 of the cases during the acme period diminished to 40 per cent ± 4.26 during convalescence and finally decreased to 31.06 after recovery. The inversion of P-wave and alternations of the A-V conduction time observed during convalescence always coincided with sinus arrhythmia, giving grounds to the belief that their origin might be imputed to an increased tonus of the vagus. The widening of P-R and QRS in the acme was probably due to toxemia since the alterations are no longer noted after recovery.

AUTHOR.

Schlomka, G., and Reindell, H.: Studies on the Physiological Irregularities of the Heart Beat. Ztschr. f. Kreislaufforsch. 28: 473, 1936.

In young people mild and moderate exertion causes tachycardia but does not abolish sinus arrhythmia. The heart action and respiration are in a sense coupled, since, on one hand, the heart beats faster when the return of blood is greatest, and, on the other hand, the blood flow is fastest when the oxygen alveolar content is greatest, viz, at the end of inspiration. Rhythmic passive abdominal pressure modified the phasic respiratory sinus arrhythmia. This is taken to indicate that the Bainbridge reflex is an important factor in causing sinus arrhythmia.

L. N. K.

Misske, B.: The Electrocardiogram of the Myxedema Heart. Ztschr. f. Kreislaufforsch. 28: 601, 1936.

Eighteen cases are reported with a review of the literature. Of these, eight cases showed a decreased QRS amplitude and six showed abnormalities of the P-wave and T-wave. Six cases, however, showed no change.

L. N. K.

Parkinson, John: Enlargement of the Heart. Lancet 1: 1337, 1936.

This subject was presented as the Lumleian Lectures for 1936, delivered before the Royal College of Physicians in London. It is an extensive review of the well-known facts of heart size and concepts of those influences which change this size, either in the whole heart or in particular regions. This is a full review of the accepted methods of studying cardiac enlargement and considerable emphasis is placed on radiological methods. Little mention is made of palpation in determining cardiac size. The article contains considerable information from the author's own experiences, particularly his analysis of the work of others which has been done under his direction.

The determination of the size of the heart still remains an interesting subject and one which is not yet fully explained. This article is an interesting contribution to the subject.

H. McC.

Clark, Eugene, and Berger, Adolph R.: Hemorrhagic Extravasations Into the Leaflets of the Atrioventricular Valves: Their Relationship to Pulmonary Embolism. Arch. Path. 22: 524, 1936.

Ecchymoses in noninflamed atrioventricular valvular leaflets were observed in four persons. In three who showed pulmonary embolism, the ecchymoses were limited to leaflets of the tricuspid valve. In the fourth, hemorrhages occurred beneath the mural endocardium and in the leaflets of the mitral and tricuspid valves. In all four, some of the ecchymoses involved the vascularized annuli, whereas others were limited to the distal, apparently avascular, regions of the leaflets. It is suggested that the ecchymoses which were limited to the leaflets of the tricuspid valve were related to the coexisting pulmonary embolism.

AUTHOR.

Struthers, R., R., and Bacal, H. L.: Rheumatic Infection in Childhood: Observations on the Sedimentation Rate and the Schilling Count. Canad. M. A. J. 35: 258, 1936.

Observations on 100 cases of rheumatic infection in childhood indicate that the sedimentation rate is a more satisfactory test for the activity of rheumatic infection than is the Schilling differential count. It has also the advantage of simplicity: it is not laborious, and it does not require special technical training. The sedimentation rate is also of greater sensitivity as an index of inactivity of rheumatic infection.

H. McC.

Jobling, James W., and Meeker, Dorothy R.: Further Investigations on Experimental Atherosclerosis. Arch. Path. 22: 293, 1936.

An unsuccessful attempt was made to accelerate and increase the development of cholesterol lesions in the aorta of the rabbit by the following injurious procedures added to cholesterol feeding: (1) intravenous injections of streptococcus toxin, (2) ammonium chloride feeding, (3) production of artificial fever, (4) intravenous injections of peptone, (5) induction of anaphylactic shock, and (6) intravenous injections of uric acid.

Similarly, no effect on the blood vessels of cats could be demonstrated when they were fed cholesterol and, in addition, were treated with (1) peptone or (2) histamine intravenously or were fed (3) ammonium chloride.

AUTHOR.

Landé, Kurt E., and Sperry, Warren M.: Human Atherosclerosis in Relation to the Cholesterol Content of the Blood Serum. Arch. Path. 22: 301, 1936.

The concentration of cholesterol in the blood serum was compared with the degree of atherosclerosis in the aorta, as measured by the lipid content, in 123 healthy persons who had died suddenly from violence. No relationship was evident, and it is concluded that the incidence and severity of atherosclerosis are not directly affected by the level of cholesterol in the blood serum per se.

AUTHOR.

Bargen, J. Arnold, and Barker, Nelson W.: Extensive Arterial and Venous Thrombosis Complicating Chronic Ulcerative Colitis. Arch. Int. Med. 58: 17, 1936.

One of the very serious complications of chronic ulcerative colitis is extensive thrombosis of the blood vessels. Among 1,500 cases thrombophlebitis or arterial thrombosis which was extensive enough to become a grave clinical problem occurred in 18. The last 6 cases are described in detail. Three of the 6 patients died. All of the deaths were believed to be caused by toxemia and not by embolism.

H. M.

Scupham, George W., and de Takats, Geza: Peripheral Vascular Diseases: A Review of Some of the Recent Literature and a Critical Review of Surgical Treatment. Arch. Int. Med. 58: 531, 1936.

This is a carefully prepared, extensive review, which presents an important contribution to this subject. It is recommended for careful reading and is not subject to abstracting.

H. McC.

de Takats, Geza: Acute Arterial Occlusions of Extremities. Am. J. Surg. 33: 60, 1936.

The differential diagnosis between embolism and thrombosis of peripheral arteries is discussed. Emphasis is laid on the importance of recognizing traumatic segmental vessel spasm and venous or lymphatic block with secondary vessel spasm. Evidence for a reflex arc of collateral vessel spasm is its interruption by novocaine block of peripheral nerves, by spinal anesthesia, and by sympathetic ganglionectomy. The afferent arc is postulated to consist of the ordinary sensory nerves, with which the vessels are well supplied, and the entire arc completed by way of the posterior root ganglion, the posterior root, the connector neuron to the lateral horn, and the ganglion cells of the efferent sympathetic fibers which are relayed in the sympathetic ganglionated trunk and go by way of the somatic nerves to the blood vessels.

The spasm which follows acute arterial occlusion can be relieved in some cases by the use of intravenous papaverine and by means of alternating negative and positive pressure apparatus. Of 5 cases treated by means of the former method, marked and lasting benefit was obtained in 3; in 5 by the latter, of which 3 were late and hopeless, a definite immediate benefit was not derived. Embolectomy should be resorted to early in selected cases, but not until after a brief trial with heat and papaverine.

H. M.

Collens, William S., and Wilensky, Nathan D.: Two Quantitative Tests of Peripheral Vascular Obstruction. Am. J. Surg. 34: 71, 1936.

The authors believe that previous tests offer no information regarding degrees of vascular obstruction and are of no use in following the progression of vascularity in an extremity under treatment. They have devised two tests: (1) the venous filling time and (2) claudication time.

Changes in these times indicate changes in rate of blood flow.

H. M.

Lazarus, Joseph A.: Mesenteric Vascular Occlusion. Report of a Case of Complete Occlusion of Superior Mesenteric Artery With Involvement of Entire Small Intestine. Am. J. Surg. 33: 129, 1936.

The case was that of a diabetic woman. There was complete closure of the main stem of the superior mesenteric artery by a thrombus and involvement of the entire small intestine, cecum, and ascending colon. An autopsy report is included.

AUTHOR.

Jirka, Frank J., and Scuderi, Carlo S.: Glomus Tumor. Report of a Case. J. A. M. A. 107: 201, 1936.

This case, one of seventy in the literature, is briefly but adequately presented, and includes photographs of the histological slides. In this instance the tumor was on the inner aspect of the arm, of the size of a split pea, and with a pinhead-sized bluish area which was exquisitely painful when touched.

H. M.

Clark, Eugene, Graef, Irving, and Chasis, Herbert: Thrombosis of the Aorta and Coronary Arteries, With Special Reference to the "Fibrinoid" Lesions. Arch. Path. 22: 183, 1936.

Homogeneous masses which exhibited the tinctorial properties of fibrin were frequently encountered on the surface and within the superficial fibrous regions of intimal aortic plaques of atherosclerosis and syphilitic aortitis.

In the lipoid zones of aortic plaques material which stained like fibrin frequently occurred in a fibrillar or homogeneous form. This material was commoner in ulcerated or eroded plaques, but it was present also in sections of plaques which appeared intact.

Homogeneous masses staining like fibrin were observed forming a layer between the formed elements of the thrombi and the plaques in eight of nine cases of parietal aortic thrombosis. In many instances identical masses were encountered within the fibrous or lipoid zones of the underlying plaques.

The evidence reviewed leads us to the belief that the homogeneous fibrin-staining ("fibrinoid") masses, occurring on the surface of fibrous plaques or the fibrous covering on atheromas, represent compressed and hyalinized blood elements and that the subsurface "fibrinoid" masses in most instances are the remnants of an organizing surface deposit. The "fibrinoid layer" beneath aortic thrombi represents laminated surface deposits of blood elements which have undergone a variable degree of organization.

It is suggested also that in other instances in which there is ulceration of the plaque or a loss of endothelial lining and a loosening and separation of the superficial collagenous fibers, the subsurface fibrin-staining masses may represent coagulated blood plasma which has penetrated the plaque from the lumen of the vessel.

As a result of repeated deposition of blood elements on the surface of the plaques and progressive organization of such hyalinized elements, the plaques of syphilitic aortitis and atherosclerosis may undergo a progressive increase in size. A thrombus of formed elements and orthodox configuration may frequently supervene on such laminated, hyalinized and partially organized surface deposits.

No differences could be discerned between the tinctorial behavior of these "fibrinoid" masses and that of the fibrinous component of thrombi. It is believed that these masses owe their tinctorial properties to their fibrinous component. There is no evidence at present to support the view that the deposits of homogeneous fibrin-staining material in the intimal aortic plaques of atherosclerosis or syphilitic aortitis represent altered or necrotic collagenous fibers.

Study of serial sections of eleven thrombosed coronary arteries has revealed differences in the character of the intimal plaque at the site of initial thrombosis. In some a fresh break in the inner collagenous lining of the atheroma was demonstrated; in others the fibrous lining was thinned out, and the collagen fibers were widely separated. In the presence of congestive heart failure the thrombi were deposited on intimal plaques which were apparently intact. In one case a fresh thrombus was deposited on a plaque containing partially organized surface deposits of blood elements.

We could find no evidence to support the view that the fibrin-staining material in the plaques of coronary arteries represents altered or necrotic fibrous tissue. As in the plaques of atherosclerotic and syphilitic aortas, such fibrin-staining masses either represent the remnants of an organizing surface deposit of fibrin or are due to the penetration into the plaque of blood elements.

AUTHOR.

Paterson, J. C.: Vascularization and Hemorrhage of the Intima of Arteriosclerotic Coronary Arteries. Arch. Path. 22: 313, 1936.

Vascularization of the intima of coronary arteries by discrete capillaries which arise from their lumens is a common finding in association with atherosclerosis. It is particularly marked in thrombosed coronary arteries. It has not been found in normal coronary arteries or in those affected by early nodular endarteritis.

Hemorrhagic lesions within the intima, which had occurred into atheromatous foci, have been observed in a number of arteriosclerotic coronary arteries, including those from nine consecutive patients with recent coronary thrombosis. When the hemorrhage was recent, capillary channels were found in the inner layers of the intima in close proximity to the extravasated blood. The sequence of events in the production of intimal hemorrhage appears to be (1) endarteritis with vascularization of the intima, (2) atheroma with resultant softening of the intercapillary stroma, and (3) capillary rupture. Because discrete intimal capillaries, atheroma, and intimal hemorrhage have been found in practically every coronary artery showing recent thrombosis in this series, it is suggested that these factors represent a chain of events which lead to thrombosis, the immediate cause being damage to the endothelium by the extravasation of blood into the intima.

AUTHOR.

Yater, Wallace M.: Demonstration of a Ruptured Popliteal Aneurysm by Thorium Dioxide Arteriography. South. M. J. 29: 973, 1936.

Report of a case in which simple arterial and venous punctures, instead of aneurysmal puncture, were used to demonstrate an aneurysm radiographically. The aneurysm was well visualized. No danger in the use of direct aneurysmal puncture is implied.

H. M.

Böger, A., and Wezler, K.: The Elasticity of the Arterial "Windkessel" (Balloon) at Different Ages in Man. Ztschr. f. Kreislaufforsch. 28: 554, 1936.

The elasticity coefficient of the *Windkessel* declines from its peak in childhood until the age of twenty-five years, and at that time a minimum is reached. It then increases again until the age of thirty-five years and remains constant thereafter. This is a result of interference between the growth curve on the one hand and the change in volume elasticity module of the arteries and the volume of the *Windkessel* on the other. The growth curve slows down after twenty years of age, the volume elasticity module changes most rapidly between the ages of twenty and thirty-five years, and the volume of the *Windkessel* keeps pace with the volume elasticity module. Methods are described for calculating these factors from measurements of pulse wave velocity of the aorta, the duration of the femoral pulse, and the x-ray cross-section of the aorta.

The *Windkessel* volume is smaller than the stroke volume of the heart and is consequently under considerable tension. The increase in length and cross-section of the *Windkessel* compensates for the loss of elasticity of the arterial wall with age and explains why the arterial pressure changes so little as the normal person grows up and senescence appears.

L. N. K.

Kramer, Kurt: Measurement of the Velocity of Blood Flow in Unopened Arteries. Arch. f. d. ges. Physiol. 238: 91, 1936.

The method depends upon the use of a pair of photometers adapted by the author for registering changes in the oxygen saturation of the arterial blood. The instrument is very sensitive and rapid, and it records, when coupled with an electrically operated optical system, a curve of the fluctuations in oxygen content with each respiration. The photometers were connected, 10 to 15 cm. apart, with the femoral artery of a dog. Simultaneous records of the respiratory waves of oxygen saturation were obtained on a single piece of photographic paper, and the difference in time between similar points on the curves measured. The distance between the two photometers was measured, and the speed of the movement of blood was readily calculated as frequently as the rate of respiration permitted. He found velocities varying from 10 to 20 cm. per second in the femoral arteries of dogs narcotized with barbiturates. Two exceptionally good curves are reproduced. He realized that mixing of the blood in its forward movement might introduce an error, but, because the values obtained by gas analysis agreed so closely with those obtained from the photometer, such an error seemed unlikely. He could not, as he had hoped, calculate change in rate of blood flow because of simultaneous variations in the cross-section of the artery.

J. M. S.

Dorsey, John L.: Control of the Tobacco Habit. Ann. Int. Med. 10: 628, 1936.

The consequences of abuse of tobacco are now being recognized and discussed in current medical literature. The ill effects of nicotine are believed to play a part in such conditions as peripheral vascular disease, organic and functional diseases of the stomach, pregnancy, headache, hyperglycemia, rhinitis, hypertension, asthma, cirrhosis of the liver, deafness, amblyopia, ether anesthesia, and others. Limitation of the use of tobacco seems much more difficult than the complete withdrawal. The use of lobelia or Indian tobacco is found to be effective in lessening the acute discomforts which result from the sudden withdrawal of tobacco. The drug is used in the form of lobeline sulphate, 0.008 gm. (⅛ gr.), given by mouth in capsule form immediately following a meal. This dose is repeated as often as the patient feels the urge to smoke.

E. A. H.

The American Heart Journal

Vol. 13 February, 1937 No 2

Original Communications

DISSECTING ANEURYSM OF THE AORTA

A Clinical and Anatomical Analysis of Nineteen Cases (Thirteen Acute) With Notes on the Differential Diagnosis*

Robert Earle Glendy, M.D.,† Benjamin Castleman, M.D., and Paul D. White, M.D.
Boston, Mass.

INTRODUCTION

An uncommon but important vascular lesion that has received far too little attention clinically is partial rupture of the wall of the aorta with dissection of its coats, designated generally as dissecting aneurysm of the aorta. A recent experience with several cases has changed our attitude from one of remote academic interest in the pathological aspects of the subject to one of lively practical attention to the possibility of making an ante-mortem diagnosis. It is this experience and an analysis of the cases that have come to autopsy at the Massachusetts General Hospital in the last thirty-eight years that we shall present.

For many years the lesion has been well known to pathologists, having been recognized clearly for the first time by Maunoir[1] in 1802 and established on a firm foundation as a pathological entity by Peacock[2] in 1843. Shennan's recent comprehensive monograph on dissecting aneurysms[3] has made it unnecessary to give here a lengthy review of the literature on the subject.

Clinical observations in this condition have been, with few exceptions, incomplete, and the diagnosis has been made almost exclusively at post-mortem examination. For an explanation we have only to consider the conditions under which the majority of these patients are observed. The disease comes suddenly and often with such overwhelming severity that its victim dies in a short time or is rendered so ill that no accurate account of his symptoms can be obtained. Often in deference to a very sick patient the physician postpones the complete examination which may give valuable diagnostic leads. That the diagnosis is so rarely made

*From the Cardiac and Pathological Laboratories of the Massachusetts General Hospital.

†Dalton scholar, Massachusetts General Hospital.

clinically, being confused with various intrathoracic and intraabdominal conditions, notably coronary thrombosis, indicates the present need of further contributions to our knowledge of the subject. Almost every condition with which it is confused is less likely to be rapidly fatal than dissecting aneurysm of the acute type. Therefore, if for no other reason than to establish a more accurate prognosis, we should be on the alert for this condition. On the other hand, dissecting aneurysm may not be immediately fatal, even when extensive. Shennan cites case after case from the literature in which, at post-mortem examination, healing or organization had occurred with persistence of the dissected sac to a greater or lesser extent, and in only 2 of some 75 cases was the diagnosis made during life.

In his analysis of 300 cases of dissecting aneurysm of all types, including 17 of his own, Shennan considered the diagnosis as having been correctly made in 6 cases during life. These were made by Swaine[4] (1855-56), Bahrdt[5] (1872), Wyss[6] (1869), Davy and Gates[7] (1922), Moosberger[8] (1924), and Barton[9] (1930). Sampson[10] (1931) and Kellogg and Heald[11] (1933) have each reported additional cases in which the diagnosis was correctly made during life. Weiss[12] (1935), in a recent review of the clinical course of spontaneous dissecting aneurysm of the aorta, reports three cases personally observed, in one of which the condition was clinically recognized. Lounsbury[13] (1935) and Gurin and his coauthors[14] (1935) have also reported cases in which an antemortem diagnosis was made. There are probably others, besides these eleven cases, which have not come to our attention.

It has been our own unusual experience to encounter recently several cases of dissecting aortic aneurysm clinically, in two of which the diagnosis was made during life. One case of this group, diagnosed incorrectly as coronary thrombosis, has been reported in detail by two of us (P. D. W. and B. C.),[15] and another, diagnosed correctly, was referred to in a footnote of the same communication. During the preparation of this paper another case included herewith was observed and correctly diagnosed during life by one of our associates, Dr. William Paul Thompson. This brings the total number of cases recognized during life to thirteen or more,* excluding those cases referred to as traumatic in origin, of which there are a fair number in the literature.[10, 16, 17]

The present report is an analysis of the clinical and anatomical features of thirteen cases of dissecting aortic aneurysm directly related to the death of the patient and six cases found incidentally among 8,200

*Since this paper was written, five additional cases of acute dissecting aortic aneurysm, diagnosed ante mortem, have come to our attention. Four of these have been observed within the past few months by Dr. Soma Weiss (personal communication) at the Boston City Hospital and the fifth by Dr. Lewis A. Conner (personal communication) at the Staten Island Hospital in New York City. This brings the total number of cases correctly diagnosed ante mortem to eighteen or more.

necropsies of subjects of all ages at the Massachusetts General Hospital.* Hereafter, the former group will be referred to as "acute," the latter group as "incidental." The case histories and important autopsy findings are given in abstract form in Tables I and II. Appended to Table II is one case in which the intima of the descending branch of the left coronary artery was slit for a short distance, resulting in dissection and thrombus formation between the coats of the vessel. This was the only instance of a dissecting process in a smaller vessel in which there was not also aortic dissection. There was, however, no microscopic examination made in that case.

ANALYSIS OF TABLES

Frequency, Age, Sex, and Occupation

The actual frequency of acute dissecting aneurysm in our series was approximately one in 630 autopsies of all ages, or, if the 6 incidental cases are included, one in 430 autopsies. The former ratio is intermediate in position among the incidences recorded by various authors: Walker and Walker[18] 1:2,500; Ames and Townsend[19] 1:500 in patients of all ages; and Weiss[12] 1:300 in adults.

The thirteen acute cases reported here occurred in persons over forty years of age with one exception, a young man aged twenty-nine years, who had rheumatic aortic and mitral valve disease. Four patients were in the forties; five in the fifties; two over seventy; and one over eighty. All of the incidental cases were over fifty years old; one in the fifties; two in the sixties; and three over seventy. This is in accord with the age incidence reported in the literature.

Among the acute cases eleven were males and two were females; this is the usual incidence. There were four males and two females among the incidental cases.

Of the acute cases, eight patients had relatively sedentary occupations, five were of the laboring class.

Symptoms and Signs

The very sudden, definite onset of symptoms is one of the striking features of acute dissecting aneurysm. In only two of our thirteen acute cases were the symptoms of such gradual onset and development as to leave any doubt regarding the time of onset. In five, or nearly 40 per cent, a history was obtained of effort or excitement immediately preceding the onset of symptoms, which included stooping to pick up a heavy object in two cases, vomiting in one, sexual intercourse in one, and arguing a case in court in another.

Pain.—In the majority of the acute cases (nine), the pain originated above the diaphragm, less often in the abdomen or flank (four). But regardless of the origin of the pain, in no two cases in our series was

*Some of the cases recorded here have been reported separately from time to time in *The New England Journal of Medicine* under the "Case Records of the Massachusetts General Hospital." Since the present report includes all of the cases occurring at the Massachusetts General Hospital up to September, 1936, duplication can be avoided in future tabulations by not counting these individual case reports.

TABLE

THIRTEEN CASES OF ACUTE DISSECTING ANEURYSM OF THE

NO. (YEAR)	AGE	SEX (RACE)	OCCUPATION	HISTORY	PHYSICAL FINDINGS	COURSE	SURVIVAL AFTER ONSET
1 (1897)	40	M (C)	Waiter	Sharp pain across front of chest 4 days before entry, worse on taking a breath. Subsequent cough and dyspnea. Pain continued severely, mostly on the left side. Hoarseness from shortly after the onset.	Pale, slightly dyspneic; respirations, 32. Dull to flat on percussion over left back from angle of scapula to apex, with harsh breath sounds and numerous râles. Fine râles over the front of both lungs. Coarse râles over right back. Heart said to be normal. Rate 88. Blood pressure not taken.	Pain continued. No response to supportive treatment. Breathing became progressively more difficult and he died, the heart having been said to be normal ½ hour before death.	6 days
2 (1902)	42	M (W)	Architect	Sudden onset of sharp, agonizing pain in right lumbar region, constant for one week before entry, relieved only by large doses of morphia. No further history.	No examination made for stated reason that patient was in such great pain. Pulse, 100.	2½ hours after entry he sat up in bed crying out with pain, following which he lost consciousness, became cyanotic, and died within thirty minutes.	7 days

the radiation exactly the same. In three instances in which the pain originated substernally, there was no radiation in one; another had pain extending to both sides of the chest, more on the left; and in the third, the pain radiated through to the interscapular region, upward into the left jaw, and later down into the thighs. In two patients in whom the pain was described as "precordial" in origin, one had radiation of the pain into the back and right chest, and the other lateral radiation equally to the two sides of the chest. Of the four remaining patients in whom the pain originated above the diaphragm, one developed interscapular pain first, with radiation anteriorly to the region beneath the sternum; the second had initial pain in the right lower chest and flank, with a slight radiation to the right shoulder; the third had pain originat-

I

AORTA DIRECTLY RELATED TO THE DEATH OF THE PATIENT

TEMPERATURE	LABORATORY DATA	CLINICAL DIAGNOSIS	PERTINENT AUTOPSY FINDINGS IN AORTA	ANATOMICAL DIAGNOSES
98-100° F.	Hgb., 33% (T.); R.B.C., 3,324,000; W.B.C., 20,800. Urine, small amount of albumin and numerous casts.	Bronchopneumonia. Chronic pleurisy. Diffuse nephritis.	Small sheath dissection on posterior portion of thoracic aorta at level of bifurcation of trachea, with small intimal opening 8 cm. from the arch, and rupture into mediastinum surrounding the trachea and esophagus. Slight arteriosclerosis of aorta. Microscopic examination negative for syphilis.	Ruptured dissecting aneurysm of aorta. Adhesive pericarditis. Hypertrophy of left ventricle. Chronic glomerular nephritis.
No data	No data	None made	Sheath dissection of media from median portion of arch downward for 7 cm., with rupture of adventitia into posterior mediastinum and retroperitoneal tissues. Intimal tear in arch (presumably). Also intimal tear in right iliac with small dissection. Moderate arteriosclerosis of aorta.	Dissecting aneurysm of thoracic portion of aorta with extensive hemorrhage into posterior mediastinum, subpleural, and retroperitonal tissues. Dissecting aneurysm, right common iliac artery. Hypertrophy of heart.

ing over the posterior aspect of the right shoulder, radiating to the left shoulder and thence down the anterolateral aspects of the chest, settling with greatest intensity in both lower abdominal quadrants; and the fourth had pain which began in the right ear and mastoid region, radiating down the neck to the whole back and chest, worse on the right. The last mentioned patient, incidentally, was the only one who complained at any time of pain in the arms, and this was of a vague aching nature associated with other vague pain throughout the thorax and trunk; in another patient, however, the left arm became numb and weak.

In three patients the pain began in the abdomen. In one of these, in whom there was total occlusion of the aorta just above its bifurcation, the radiation was described as being to the whole body, but particularly

TABLE I

NO. (YEAR)	AGE	SEX (RACE)	OCCUPATION	HISTORY	PHYSICAL FINDINGS	COURSE	SURVIVAL AFTER ONSET
3 (1917)	70	F (W)	Cook	On the day before entry, sudden onset of stabbing pain in interscapular region radiating through to lower part of sternum, occurring intermittently, but with a constant dull ache in between attacks of sharp pain. Dyspnea and orthopnea. Vomiting shortly after onset.	Obese. Râles at left lung base. Heart enlarged both to the right and left. Increased supracardiac dullness (8 cm.). Heart sounds of fair quality, rhythm irregular, rate 100. Short presystolic murmur at the apex. Blood pressure 260/140. Edema over the shins.	Improved somewhat with rest, digitalis, and the nitrites. Pain ceased after the 17th day, and she was discharged on the 37th day. Nine weeks later (15 weeks after initial attack), following vomiting after each meal for 3 days, she was taken suddenly with agonizing substernal pain radiating through to the back and died 9 hours later, shortly after her second admission to the hospital, and before any pertinent observations were made.	105 days after formation of dissecting aneurysm, 9 hours after its rupture.
4 (1917)	53	M (W)	Laborer	On the day before entry, while on a ladder bending over to fix a pipe, he was suddenly seized with severe stabbing pain in the left chest, just below and outside the nipple. The pain quickly increased in intensity radiating to the back and right chest, was worse on lying down, and was associated with great dyspnea. He was given cathartics and enemas without relief and later sent to the hospital.	Obese. Anxious facies and in great distress from substernal pain. Few râles at left lung base in front. The apex impulse of the heart was neither seen nor felt. The apical heart sounds were quite faint; no sounds were audible at the base. The rhythm was regular, the rate, 120. Questionable systolic murmur at the apex. Blood pressure, 190/120. Slight peripheral arteriosclerosis. Extreme epigastric tenderness. Reflexes normal. Respirations, 35.	Agonizing seizures of pain, as described, continued on slight movement or spontaneously. Became hoarse and later lost his voice entirely. Dyspnea was marked. B. P. fell to 100/78 after venesection, and there was partial syncope. Intractable distention developed and a "surgical abdomen" was considered. Though apparently in extremis his B. P. remained elevated (160) and the pulse fairly strong until 1 hour before death on the 6th day.	6 days

—CONT'D

TEMPERATURE	LABORATORY DATA	CLINICAL DIAGNOSIS	PERTINENT AUTOPSY FINDINGS IN AORTA	ANATOMICAL DIAGNOSES
99-100.8° F.	Hgb., 80% (S.); W.B.C., 13,000-15,000. Wassermann, negative. Urine, low Sp. G., trace of albumin. X-ray (7 ft. chest plate) on 19th day after onset. Interpretation: Well-marked cardiac enlargement. Great vessels measured 11.6 cm. Aneurysm of descending aorta (type not specified).	Angina pectoris. Arteriosclerosis. Chronic nephritis. N.B.—Apparently the x-ray diagnosis was not given much consideration.	Irregular cleft in intima at junction of arch and thoracic portion with sheath dissection of the media, proximally to the right coronary mouth and distally to a point 9 cm. below the arch. Rupture into mediastinum and retropleural spaces. Marked atheroma of aorta. Microscopic examination negative for syphilis.	Dissecting aneurysm of aorta with great hemorrhage into periaortic and retropleural spaces. Hemopericardium. Arteriosclerosis.
100-100.5° F. with gradual return to normal.	Hgb., 90% (S.); W.B.C., 18,500; N.P.N., 56 mg. %. Urine, slight trace of albumin, few casts. P.S.P. excretion, 35%. Wassermann, negative. Stool, positive guaiac test on 2 occasions. X-ray of chest on 5th day showed heart and great vessels much enlarged, and an area of dullness in the right mid-chest. The film was regarded as unsatisfactory, and a 2nd one taken post mortem was also unsatisfactory.	Pneumonia. Chronic nephritis. Arteriosclerosis. ? Aneurysm. ? Subdiaphragmatic abscess.	Elongated crevice in aortic intima at junction of arch and ascending portion in the region of an arteriosclerotic ulcer with sheath dissection of the media of irregular contour extending down as far as the inferior mesenteric artery; rupture into the mediastinum and both pleural cavities. Moderate arteriosclerosis of the aorta, in some places marked. Microscopic examination: Levaditi stain negative although there was some suggestion of syphilis in the aorta.	Dissecting aneurysm of aorta with extensive hemorrhage into pleural and pericardial tissues and pleural cavities. Hypertrophy of heart. Arteriosclerosis. Edema of lungs.

TABLE 1

NO. (YEAR)	AGE	SEX (RACE)	OCCUPATION	HISTORY	PHYSICAL FINDINGS	COURSE	SURVIVAL AFTER ONSET
5 (1921)	29	M (W)	Carpenter	Seven weeks before entry sudden onset of severe pain in right ear and mastoid region radiating down over back of neck. Pain was sharp in character and quickly spread over whole back and chest, worse on the right side and on deep inspiration. Intense dyspnea. Sat up for 48 hours gasping for breath. Continued orthopneic. Some edema, cough, and night sweats. On 5 occasions a total of 200 oz. of fluid removed from left pleural space, the last tap being bloody. These taps were done before his entry to M. G. H.	Apprehensive. Marked orthopnea. Head jerked with each heartbeat. Mucous membranes pale and cyanotic. Marked pulsation of great vessels. Well-marked Corrigan and capillary pulses. Signs of fluid in left chest. Heart greatly enlarged, rhythm regular, rate 115, diffuse heaving impulse. Systolic and diastolic murmurs at apex and base. Blood pressure, 170/20.	Continued apprehensive, complaining of aching pains in thorax, shoulders, face, and left arm. On the 9th day after entry, without warning sign or symptom, he fell back dead.	56 days
6 (1927)	84	F (C)	Housewife	Indigestion (dysphagia, gas, occasional vomiting) for one year. For 2 weeks had been able to take only liquids. For 1 week had complained of aching pain in the right flank and lower thorax without relation to breathing. Some dyspnea on effort.	Emaciated. Marked arcus senilis. Poor chest expansion. Lungs hyperresonant and clear. Heart slightly enlarged to left, rhythm regular, rate 80, sounds of fair quality. Loud systolic murmur over left precordium. Radial and brachial artery walls thickened. Pulse of poor volume. Blood pressure 60/40. Irregular liver edge 4 cm. below costal margin. Respirations, 25.	Continued to complain of pain as previously described. Also complained of some pain in the right shoulder and of a burning sensation high in the epigastrium. She was found dead by a nurse 18 hours after admission.	7 days

—CONT'D

TEMPERATURE	LABORATORY DATA	CLINICAL DIAGNOSIS	PERTINENT AUTOPSY FINDINGS IN AORTA	ANATOMICAL DIAGNOSES
Normal during period of observation. Temperature at onset not known.	R.B.C., 5,300,000; W.B.C., 7,000 (7 wk. after onset). Blood smear, normal. N.P.N., 31.5 mg. %. Urine, normal. P.S.P. excretion, 40%. Left thoracentesis on day before death yielded fluid, studies on which were inconclusive.	Rheumatic heart disease. Aortic insufficiency. Mitral insufficiency. Hydrothorax (left). ? Pericarditis. ? Pulmonary embolism.	Intimal and underlying medial degeneration in ascending portion of aorta, 5 cm. in length and from 4 mm. to 2 cm. in width. Short medial dissection and irregular perforation through adventitia into pericardial cavity. Descending thoracic and abdominal portions negative. Microscopic examination: Colloid degeneration of the media. No evidence of syphilis.	Degeneration of wall of ascending aorta with old and recent ruptures. Hemopericardium. Chronic endocarditis of mitral and aortic valves. Chronic adhesive pericarditis. Hypertrophy of heart.
99.2-100.2° F.	Hgb., 65% (T.); R.B.C., 4,176,000; W.B.C., 12,600. Blood smear, normal. N.P.N., 45 mg. %. Wassermann, negative. Stool, negative.	Arteriosclerosis, general. Arteriosclerotic heart disease.	Rupture of intima 4 cm. in length and 1.5 cm. above base of aortic valve. Medial dissection posteriorly with rupture into pericardium. Extensive calcified atheromatous plaques throughout aorta, some showing ulceration. Microscopic examination negative for syphilis.	Dissecting aneurysm of aorta (ruptured). Hemopericardium. Arteriosclerosis.

TABLE I

NO. (YEAR)	AGE	SEX (RACE)	OCCUPATION	HISTORY	PHYSICAL FINDINGS	COURSE	SURVIVAL AFTER ONSET
7 (1930)	51	M (W)	Teacher	Onset sudden on day of entry with terrific but rather dull pain over entire lower abdomen quickly spreading to both legs, chest, and shoulders. Desire to move bowels: Went to bath room twice unassisted. Within 10 minutes was paralyzed from waist down. Numbness began in feet and rapidly ascended to a point just above the symphysis pubis. Chest and shoulder pain quickly disappeared, but lower abdominal pain persisted.	Pale, ashen cyanosis. In much pain across lower abdomen. Complete flaccid paralysis both legs. Feet and lower legs waxy white and cold. Skin above this to level of symphysis pubis bluish red and cool. No dorsalis pedis or femoral artery pulsations on either side. Systolic and diastolic murmurs all over precordium, loudest at base. Blood pressure 220 systolic (140 soon after onset of symptoms). Abdomen not rigid or tender. Sensation and reflexes absent in lower extremities. Tendon jerks in arms present. Pulse, 90-120. Respirations, 20.	Death occurred on the operating table during the course of a proposed iliac embolectomy 9 hours after the onset of symptoms. The blood pressure fell gradually from 190/90 to 80/60 during the course of the operation.	½ day

to both legs, to the upper chest, and to both shoulders. Another developed epigastric pain which later became generalized over the abdomen and was associated with some substernal distress. In a third, the description was that of vague abdominal pain, worse across the upper abdomen on deep breathing. Only one patient complained of pain in the right lumbar region without radiation.

The character of the pain as described was for the most part severe and sharp or stabbing. However, it was variously described as at first dull, but later severe, constricting and penetrating; terrific but dull; oppressive; aching and vague. One patient, a physician, who described his symptoms quite accurately, likened the onset in its severity to the blow of a sledge hammer on the chest.

—CONT'D

TEMPERATURE	LABORATORY DATA	CLINICAL DIAGNOSIS	PERTINENT AUTOPSY FINDINGS IN AORTA	ANATOMICAL DIAGNOSES
100.2° F.	No data	Embolism, iliac arteries (bilateral).	T-shaped tear in intima 1.5 cm. above right posterior aortic cusp with sheath dissection of media of the whole aorta to 4 cm. above its bifurcation where a massive clot within the wall of the vessel occluded the lumen. Microscopic examination negative for syphilis.	Dissecting aneurysm of aorta. Arteriosclerosis. Aortic valve stenosis (calcareous).

In eleven out of the thirteen patients the pain was more or less constant from its inception until death occurred. The remaining two were relieved after a few hours by morphia.

In seven patients in whom the effect of respiration on the pain was known, it was made worse in four, and in three there was no effect.

Dyspnea was present in eight out of nine cases in which this symptom was noted.

The degree of *prostration* and apparent *shock* is extreme in most cases, yet the blood pressure may be maintained at a very high level. Loss of consciousness is common, and in those in whom this does not occur the suffering is so intense that often little information can be obtained from them regarding the details of their illness.

TABLE I

NO. (YEAR)	AGE	SEX (RACE)	OCCUPATION	HISTORY	PHYSICAL FINDINGS	COURSE	SURVIVAL AFTER ONSET
8 (1932)	54	M (W)	Lawyer	History of slowly advancing hypertension with renal involvement for 15 years. On day of entry awoke with dull pain over precordium. At 11 A.M., while trying a case in court, was suddenly seized with severe constricting and penetrating pain over left lower chest in front, extending to right of chest, associated with weakness and numbness of entire left arm. He was brought to the hospital in a state of collapse.	Pale, apprehensive. Reflexes normal. Lungs clear. Heart moderately enlarged, rhythm regular, rate 90, sounds of good quality. Aortic second sound slightly exaggerated, slight aortic systolic murmur. No edema. Blood pressure, 200/100. Respirations, 20.	Blood pressure remained elevated (210/135-120) for 3 days, then fell gradually to 160/100. Vague upper and mid-abdominal pain continued more or less constantly, but he appeared to be doing fairly well until his sudden death on the 8th day after the onset of symptoms.	8 days

Hypertension is almost invariably present. It was found in eight out of eleven of our acute cases, in which the blood pressure was determined. Four who were known to have had preexisting hypertension maintained the hypertension to a greater or lesser degree after dissection of the aorta took place; in one of these, a man aged twenty-nine years, aortic insufficiency of rheumatic origin was present. In three patients of whom we had no previous knowledge of the blood pressure, hypertension was present shortly after the onset of the acute attack, falling off gradually, but later in two of these, attaining a higher level again before death occurred. One patient, in whom the aorta was totally occluded near its bifurcation, developed in the period of one hour a systolic pressure of 220 mm. of mercury, the original pressure being 140 mm. of mercury. In this case the diastolic pressure was never greater than 90. In one patient the blood pressure was normal when first deter-

—CONT'D

TEMPERATURE	LABORATORY DATA	CLINICAL DIAGNOSIS	PERTINENT AUTOPSY FINDINGS IN AORTA	ANATOMICAL DIAGNOSES
99-100°. F.	W.B.C., 19,000-16,400. Wassermann, negative. Electrocardiogram, within normal limits on 3 occasions (1st, 2nd, and 5th days after entry).	Coronary thrombosis.	Horizontal intimal tear, almost complete, 7 cm. below arch, and partial horizontal tear 3.5 cm. below arch; also 2 ulcerations with perforation, one at junction of arch and descending portions, the other 2.5 cm. below this. Almost complete sheath dissection of descending thoracic aorta beginning at distal portion of arch and partial dissection for 6 cm. below this with a sac of the following dimensions (6 by 1 by 0.2 cm.) extending into both common iliac arteries. Rupture into mediastinum and right pleural cavity. Moderate arteriosclerosis of aorta. Microscopic examination negative for syphilis.	Dissecting aneurysm of aorta and iliac arteries. Rupture of descending thoracic aorta. Hemothorax (right). Hypertrophy of heart. Arteriosclerosis. Acute endocarditis of mitral and aortic valves.

mined a few weeks after the onset, and fell off gradually. Two patients had very definitely low pressures when seen in the acute attack, but there was good reason to believe, in these instances as in the majority of cases, that the blood pressure had been elevated. In small dissecting aneurysms occurring as incidental findings at autopsy, the incidence of hypertension was equally high, being present in four out of five of our cases in which the blood pressure was recorded.

The *pulse rate* in more than one-half of the cases (seven) was between 80 and 104 per minute. In one case the pulse rate was 70; in one, 110; and in the remaining four, 120 to 140. In those with higher initial pulse levels who lived for several days, the rate came down gradually. In only three cases was there a positive or negative statement regarding the peripheral pulsations other than the radial pulses. In all of these cases symptoms and signs were present directing attention to the lower

TABLE I

NO. (YEAR)	AGE	SEX (RACE)	OCCUPATION	HISTORY	PHYSICAL FINDINGS	COURSE	SURVIVAL AFTER ONSET
9 (1932)	44	M (W)	Laborer	Previous history of hypertension of unknown duration. Choking sensations with slight pain in upper chest, occurring at rest for 5 months. Blood pressure known to be 220/116 for 8 weeks. While sitting on bench in clinic waiting to be seen, he was suddenly seized with a severe sense of oppression in the chest, perspired freely, and became very dyspneic. There was a sense of impending death and great weakness. He was admitted to the hospital at once.	Slight cyanosis of the lips. Moderate respiratory distress (after morphia). Slight sclerosis of optic vessels. Marked left precordial bulge. Moderate enlargement of heart, rhythm regular, rate 90, sounds of fair quality. Loud systolic, and moderately loud short diastolic murmurs heard over base of heart (these had been noted 8 weeks previously). Blood pressure, 210/100. Lungs clear.	Responded to morphia but remained weak and perspired freely. A few hours later he suddenly became very cyanotic, lost consciousness, and died.	4 hours
10 (1934)	57	M (W)	Physician	Known hypertension for several years. Onset sudden while picking up box from floor. Severe substernal pain, coming abruptly like the blow of a sledge hammer, radiating into back between the shoulder blades, into the left upper jaw, and later into thighs, lasting about 5 hours in spite of morphia.	Slightly ill, heart moderately enlarged, sounds of good quality, aortic 2nd sound accentuated, soft systolic murmur at apex and base, very slight early diastolic murmur all along left sternal border. Pulse full and soft, rate 70. Dorsalis pedis arteries well felt. Blood pressure, 140/100. Knee jerks, normal.	He remained fairly comfortable with morphia, but died suddenly on the third day while talking to a friend.	2 days

—CONT'D

TEMPERATURE	LABORATORY DATA	CLINICAL DIAGNOSIS	PERTINENT AUTOPSY FINDINGS IN AORTA	ANATOMICAL DIAGNOSES
No data	Hinton reaction, negative. X-ray, 7 foot plate, 8 weeks before onset showed hypertrophy of heart to the left and dilatation of ascending aorta.	Hypertensive heart disease. Aortic insufficiency (relative). Cardiac asthma.	Saw-toothed intimal tear 2 cm. in length. 1 cm. above aortic valve on posterior wall with sheath dissection involving ½ of circumference of aorta posteriorly extending the whole length of the aorta, distally into the iliacs and proximally to the aortic ring. The dissection involved also the whole innominate artery and extended for 3 cm. along the left subclavian artery. Microscopic examination showed cystic degeneration of the media (medionecrosis aortica cystica) with only the muscle layer affected. Rupture into pericardium. No evidence of syphilis.	Dissecting aneurysm of aorta (ruptured). Hemopericardium. Medionecrosis aortica cystica. Hypertrophy of heart.
100° F.	W.B.C., 18,000. Electrocardiogram (on 2nd day), normal rhythm, rate 100, low T_1, flat T_2, high origin with slight late inversion of T_3, inverted P_3 and QRS_3.	? Dissecting aneurysm of aorta. ? Coronary thrombosis.	Longitudinal tear 3 cm. in length just above posterior aortic cusp with sheath dissection involving three-fourths of the circumference of the aorta posteriorly and extending its entire length into iliacs, into innominate, and proximally involving the right coronary orifice.	Dissecting aneurysm of aorta involving iliacs, innominate, and right coronary arteries.

TABLE I

NO. (YEAR)	AGE	SEX (RACE)	OCCUPATION	HISTORY	PHYSICAL FINDINGS	COURSE	SURVIVAL AFTER ONSET
11 (1935)	70	M (W)	Retired	Weakness and vague abdominal pain of six weeks' duration. No other details of history available.	Emaciated and appeared quite weak and ill. Mentally confused. Sclerotic fundi. Heart greatly enlarged, action forceful, rate 130, rhythm regular, loud systolic murmur at apex and aortic area. Second sound of poor quality. Respirations, 30; râles at both lung bases. Abdomen distended, poorly localized tenderness in RLQ near the midline. Blood pressure, 144/100.	He failed rapidly, sinking into stupor from which he could not be aroused. The blood pressure fell to a point that could not be determined. The chest filled with large râles and he died on the third day after admission.	? 42 days. Onset indefinite.
12 (1935)	52	M (W)	Laborer	Incomplete. Known to have had generalized abdominal pain with nausea and vomiting for three days before entry. Also subsequently some precordial pain. On account of a distended tender abdomen, he was sent to the hospital for surgical consideration. No record of blood pressure before entry.	Acutely ill, pulse 140, temperature 101.6° F., respirations, 34. Heart and lungs said to be normal. Blood pressure, 100/60. Abdomen very stiff and generally tender but not more on one side than on the other. Reflexes normal.	Before an exploratory laparotomy could be done, he went into shock, blood pressure falling to 40 systolic. He sank rapidly into coma and died in spite of a transfusion and other intravenous therapy. He could not void, and no urine was obtained by catheter.	3 days

extremities. In two of them, the preoperative diagnosis of iliac embolism was made, and surgery was resorted to in an attempt to relieve the arterial obstruction.

Of twelve cases the *heart sounds* were good in seven, fair in four, poor in one. *Heart murmurs* of various types were present in ten of twelve

—CONT'D

TEMPERATURE	LABORATORY DATA	CLINICAL DIAGNOSIS	PERTINENT AUTOPSY FINDINGS IN AORTA	ANATOMICAL DIAGNOSES
98-101.2° F.	Hgb., 60% (T.); R.B.C., 3,850,000; W.B.C., 30,000. N.P.N., 87 mg. %. Blood sugar, 130 mg. %. Urine, very slight trace of albumin, occasional R.B.C. in sediment.	Chronic nephritis. Uremia.	3 cm. tear in intima opposite renal arteries with sheath dissection downward for 8-10 cm. Slightly below intimal tear is a rupture of the adventitia with much extravasated blood invading all tissues and cleavage planes in vicinity and extending upward through diaphragm into right pleural cavity. Extensive arteriosclerosis of aorta from above downward. Microscopic examination negative for syphilis.	Dissecting aneurysm of abdominal aorta (ruptured). Hemothorax, right. Arteriosclerosis, general. Cardiac hypertrophy. Calcification of aortic valve.
101.6° F.	W.B.C., 17,400 to 34,000 (terminal). X-ray film of the abdomen gave no significant information.	General peritonitis probably due to ruptured appendix.	4 cm. transverse tear in intima 1.5 cm. above aortic ring with sheath dissection of entire aorta (complete for 3.5 cm. just distal to celiac axis) extending down to iliacs and proximal dissection with hemorrhagic infiltration into myocardium around right coronary orifice. No external rupture. Microscopic examination negative for syphilis.	Dissecting aneurysm of thoracic and abdominal aorta. Hemorrhage, aortic, into myocardium about right coronary artery.

cases. In three of these there was significant valvular disease—the young man, aged twenty-nine years, with rheumatic heart disease referred to previously, and two older patients with calcareous changes in the aortic valve. Aside from the case of rheumatic heart disease in which there were both systolic and diastolic murmurs at the apex and

TABLE I

NO. (YEAR)	AGE	SEX (RACE)	OCCUPATION	HISTORY	PHYSICAL FINDINGS	COURSE	SURVIVAL AFTER ONSET
13 (1935)	44	M (W)	Salesman	Sudden onset, while walking, of severe pain over posterior aspect of right shoulder, which within two minutes coursed across his back to a similar location on the left shoulder, then down the anterolateral aspects of his chest on both sides, down the sides of his abdomen, where it finally settled and remained with greatest intensity in both lower abdominal quadrants. The legs became numb and cold; the skin over them blue; and the slightest movement caused great pain in the right leg.	Obese. Unable to walk. Moderate degree of shock. Marked cardiac enlargement. Heart action regular at rate of 104, sounds of fair quality, blowing systolic murmur at apex. Blood pressure, 190/110. Lungs clear. Abdomen tympanitic. Both legs cold at first; several hours later the left leg became warm again. No pulsations could be felt in the right leg, and they were weaker than normal in the left leg. The right leg was without sensation from the hip down.	A diagnosis of embolism of the right common iliac artery was made sixteen hours after the onset. A clot 3 inches in length was removed from the right common iliac artery, but blood failed to flow from the proximal segment. His condition was poor following operation; blood pressure, 100/50. He developed pulmonary edema and died 36 hours after the onset of symptoms.	1½ days

base, the most common murmurs were systolic and diastolic combined over the base of the heart (noted three times). In one of these, aortic stenosis of calcareous origin was present. In another a diastolic murmur had been noted eight weeks previous to the onset of symptoms. Presumably in the third the diastolic murmur was the result of sudden altered conditions in the aortic ring, or as suggested by Resnick and Keefer,[20] may have been the result of the same factors which produce murmurs in arteriovenous aneurysm. A systolic murmur alone over the base of the heart was heard in two cases, and a systolic murmur at the apex in three; a diastolic murmur at the apex, in a man aged seventy years, is perhaps to be explained on the basis of left ventricular dilatation.

Hoarseness occurred in two of our thirteen acute cases. In both there was rupture of the dissecting aneurysm with hemorrhage into the mediastinum.

—CONT'D

TEMPERATURE	LABORATORY DATA	CLINICAL DIAGNOSIS	PERTINENT AUTOPSY FINDINGS IN AORTA	ANATOMICAL DIAGNOSES
No data	None reported except for total hematuria in a catheter specimen of urine taken on arrival at the hospital.	*Right iliac embolism* (by surgical service). Dissecting aortic aneurysm (by cardiac consultant).	*Transverse tear 5 cm.* in length, 10.5 cm. from aortic valve at junction of arch and descending portion. Media is dissected by a homogeneous blood clot, the separation involving only the posterior and lateral aspects of the aorta. Short dissection (8 mm.) into media of left renal artery. On the right the dissection stops 7 cm. above the bifurcation of the aorta; on the left it continues down into the left common iliac artery for 3.5 cm. where it ruptured through the intima into the lumen again. Moderate atheromatous change throughout entire course of descending aorta. Microscopic examination negative for syphilis.	Dissecting aneurysm of thoracic and abdominal aorta; partial dissection of renal and common iliac arteries. Cardiac hypertrophy, hypertensive type. Pulmonary edema. Gastric ulcers.

In eleven cases with adequate examination there were seven with no significant signs over the lungs. Two patients had signs interpreted as pneumonia; both of these had hemorrhage into the mediastinum, and one into the pleural cavities as well. In one patient who survived for fifty-six days after the onset, left hydrothorax was present.

A *low grade fever*, with the temperature ranging from 99° to 101.6° F., was present in all cases for a few days following the onset.

Survival After Onset

In ten (76 per cent) of our thirteen acute cases, the survival after the onset of symptoms was 6, 7, 6, 7, ½, 8, ½, 2, 3, and 1½ days, respectively, an average of 4.15 days. Of the remaining three cases (24 per cent), one lived for 105 days after the formation of the dissecting aneurysm and died suddenly twelve hours after its rupture. Another

TABLE II

SIX CASES OF DISSECTING ANEURYSM OF THE AORTA FOUND INCIDENTALLY AT AUTOPSY, AND ONE CASE OF DISSECTING ANEURYSM OF A CORONARY ARTERY

NO. (YEAR)	AGE	SEX (RACE)	OCCUPATION	HISTORY	PHYSICAL FINDINGS	COURSE	CLINICAL DIAGNOSIS	PERTINENT AUTOPSY FINDINGS	ANATOMICAL DIAGNOSES
14 (1909)	52	M (W)	?	No history suggestive of dissecting aneurysm. Hemiplegia 3 days before entry.	Heart enlarged, rate rapid, rhythm irregular, sounds of poor quality. Blood pressure, 200 systolic.	Gradual downhill course, coma, and death on the third day after entry with a terminal temperature of 100° F.	Cerebral hemorrhage. Hypertension.	In the thoracic aorta near the third left intercostal artery a 5 mm. opening in the intima admitted a probe into a small pouch the outer covering of which was adventitia. No perforation. Marked arteriosclerosis of aorta. Microscopic examination negative for syphilis.	Small dissecting aneurysm of aorta. Cerebral hemorrhage. Arteriosclerosis, general. Cardiac hypertrophy.
15 (1916)	75	M (W)	?	Health allegedly good up to present illness. Right renal colic for one week before entry.	Recorded as negative except for tenderness and spasm in the right flank. Bladder stones found on cystoscopy. No record of blood pressure.	Did very poorly. On 27th hospital day he had a cerebral hemorrhage with left hemiplegia and died.	Cerebral hemorrhage. Nephrolithiasis.	Medial dissection of left side of aorta forming a separate healed sac extending from the isthmus along the left side of aorta and opening into the left common iliac artery at a	Healed dissecting aneurysm of aorta. Arteriosclerosis. Cardiac hypertrophy. Ureterolithiasis. Cholelithiasis. (Cerebral hemorrhage.)

TABLE II—CONT'D

								point just where it is given off from the aorta. The sac varied in circumference from 8.5 to 2 cm. and was 1 cm. in diameter at its outlet into the iliac artery. It contained blood. Both the aorta and the sac showed fibrocalcareous changes. Microscopic examination negative for syphilis.	
16 (1921)	66	M (W)	Metal worker	No cardiovascular history.	Heart normal in size, shape, and sounds, except for a slight systolic murmur. Pulse rate, 100. Blood pressure, 140/76. Moderate peripheral arteriosclerosis.	Died on 4th day after operation. (Posterior gastroenterostomy.)	Carcinoma of stomach. Pulmonary edema.	Perforation of atheromatous patch at isthmus with splitting and separation of the wall with blood for a very short distance. Moderate arteriosclerosis of aorta. Microscopic examination negative for syphilis.	Small dissecting aneurysm of arch of aorta. Arteriosclerosis. Carcinoma of stomach. Pulmonary edema.

TABLE II—CONT'D

NO. (YEAR)	AGE	SEX (RACE)	OCCUPATION	HISTORY	PHYSICAL FINDINGS	COURSE	CLINICAL DIAGNOSIS	PERTINENT AUTOPSY FINDINGS	ANATOMICAL DIAGNOSES
17 (1921)	65	F (W)	House-keeper	Coronary heart disease with angina pectoris and several episodes of congestive failure over a period of 7 years. Also paralysis agitans.	Obese. Large heart. Auricular fibrillation. Anasarca. Blood pressure, 185/100.	Died on 3rd day after entry from congestive heart failure.	Arteriosclerotic heart disease. Hypertension. Angina pectoris. Arteriosclerosis, general. Paralysis agitans.	Atheromatous patch in the lower part of the arch, at the base of which there is a small area where the adventitia is dissected for a short distance. The small adventitial sac is intact and contains blood. Marked arteriosclerosis of aorta. Microscopic examination negative for syphilis.	Small dissecting aneurysm of aorta. Arteriosclerosis, general. Cardiac hypertrophy.
18 (1923)	72	M (W)	Auditor	Fell, striking head on sidewalk 10 days before entry. Unconsciousness for a short time thereafter, followed by headache and gradually increasing weakness.	Cyanotic. Large heart. Blood pressure 190/110. Slight left hemiplegia.	Gradually sank into deep coma and died.	Cerebral hemorrhage. Bronchopneumonia.	2 cm. crevice in an atheromatous area just above bifurcation of aorta opening into the cavity of a dissecting aneurysm which extends downward into the common iliac artery for 9 cm. Moderate arteriosclerosis of aorta. Microscopic examination negative for syphilis.	Small dissecting aneurysm of abdominal aorta. Chronic internal pachymeningitis with extensive hemorrhage. Arteriosclerosis. Cardiac hypertrophy.

TABLE II—CONT'D

19 (1925)	74	F (W)	House-wife	Several attacks of acute gallbladder colic. Admitted for operation.	Obese. Jaundiced. Heart slightly enlarged. Poor sounds. Blood pressure 170/90.	Developed pulmonary edema and died on the 4th day after operation. (Cholecystectomy.)	Acute cholecystitis. Cholelithiasis.	Fibrocalcareous patch 1.5 cm. in diameter in arch, at the base of which there is a small, dissecting aneurysm. Periadventitial tissues slightly infiltrated with blood. Moderate arteriosclerosis in remainder of aorta. Microscopic examination negative for syphilis.	Small dissecting aneurysm of lower end of aortic arch. Arteriosclerosis. Cardiac hypertrophy. Cholecystitis with necrosis of bladder wall. Cholelithiasis.
20 (1902)	51	M (W)	?	Slowly advancing myocardial insufficiency for 10 years, worse for 6 months prior to entry. No history of chest pain.	Large heart, forceful. Gallop rhythm. Aortic 2nd sound accentuated. Dependent portions of body everywhere edematous. No record of blood pressure.	Failed rapidly and died on 5th day after entry of congestive heart failure.	Arteriosclerotic heart disease. Congestive heart failure.	Small slit 4 mm. long in descending branch of left coronary artery containing a thrombus between the coats of the vessel. Microscopic examination not reported.	Dissecting aneurysm descending branch of left coronary artery. Cardiac hypertrophy. Right auricular and right and left ventricular thrombi. Subacute glomerular nephritis.

lived 56 days after the onset of symptoms and then died suddenly. In the third case the actual time of onset was uncertain, but the onset probably took place about thirty-six days before death occurred.

At this point, one case among those found incidentally at autopsy deserves special mention. It is an instance of the so-called "double-barreled aorta" in a man aged seventy-five years, who admitted no previous serious illness, although a detailed past history was not taken. He entered the hospital because of renal colic, and stones were found in the urinary bladder. He died on the twenty-seventh day following a cerebral hemorrhage. For details of the changes in his aorta, see Table II, Case 15.

Cause of Death

In six of our thirteen acute cases, death was the result of rupture into the mediastinum with or without extension into the pleural or retroperitoneal spaces. Rupture into the pericardium occurred in four cases. One patient died from complete occlusion of the aorta near its bifurcation without rupture; in another there was rupture back into the lumen of the aorta, death resulting from shock and pulmonary edema; while in the thirteenth case the death was due to complete anuria of unknown cause. In this last case there was dissection in the region of the renal arteries, but they were apparently not directly involved, and there was no rupture.

Of the six incidental cases, death was due in three to cerebral hemorrhage, in one to coronary heart disease, in one to carcinoma of the stomach, and one patient died postoperatively, following a cholecystotomy.

Laboratory Data

The *white blood cell count* in eight acute cases averaged 20,000, with extremes of 12,600 and 34,000. An additional patient seen six weeks after the onset had a count of 7,000 which remained at this level. In extensive dissections, or when rupture occurs, the red blood cell count falls.

The Wassermann or Hinton reaction was determined in nearly one-half (6) of the acute cases and in two-thirds (4) of the incidental cases and was always found to be negative.

Electrocardiograms were taken in only two of our thirteen acute cases. In one of these in which the clinical diagnosis was coronary thrombosis, the tracings were essentially normal on the first, second, and fifth days. On the eighth day, when apparently improving, the patient died suddenly. The other case, following shortly after the one just mentioned, was correctly diagnosed on the basis of the clinical characteristics of his illness though the electrocardiogram showed slight T-wave changes in Leads II and III, suggestive of cardiac infarction of the posterior or diaphrag-

matic type. The probable reason for the slight abnormality was revealed when at autopsy the aortic dissection was found extending proximally to involve the opening of the right coronary orifice.

X-ray examinations were made in three cases. In one of these a diagnosis of aneurysm of the descending aorta (type not specified) was made by the roentgenologists, but the possibility of a dissecting aneurysm was entirely overlooked by the clinicians. This patient lived for more than three months after the formation of the dissecting aneurysm and then died within a few hours after it had ruptured. In a second case, the aortic arch on the left was reported as prominent, but the interpretation was equivocal. Here, rupture had occurred into the mediastinum and both pleural cavities. A third patient had a flat x-ray plate of the abdomen to determine the presence of gas beneath the diaphragm, but this gave no important information. Dissection was present in the thoracic and abdominal aorta.

PATHOLOGY, ETIOLOGY, AND PATHOGENESIS

The aorta often shows a transverse, irregular tear from 1.5 cm. to 2 cm. in length and about 1.5 cm. above the valve ring. This tear extends through the intima and part way through the media into which blood penetrates until it finds a plane of cleavage and begins to dissect. The dissection lies almost always between the middle and outer thirds of the media, involves about one-half or two-thirds of the circumference of the vessel, and extends distally along the greater part or the entire course of the aorta, quite often into the iliac arteries, less often into the vessels of the arch, and only rarely into the renal or other smaller branches. Occasionally the blood dissects backward down to the valve ring to impinge upon one of the coronary mouths. This occurred in two of our cases (Cases 10 and 12, Table I) and in one apparently produced anginal pain. In Case 7, Table I, the aneurysm compressed the lumen of the abdominal aorta 4 cm. above the bifurcation, with subsequent paralysis of the lower extremities.

The blood enclosed in this sheath composed only of adventitia and a small portion of the media is likely to perforate it at some point, not necessarily in immediate relationship to the intimal tear. If the perforation is close to the heart, rupture will be into the pericardium; if more distal, into either pleural cavity or occasionally into the retroperitoneal tissues and then into the abdomen. This external perforation is often difficult to demonstrate when it is not within the pericardium because of the blood clot in the loose surrounding tissues. Very rarely the blood may reenter the original lumen and thus produce a double-barreled tube; these are the cases that occasionally organize and heal (see Case 15, Table II). At autopsy the aneurysmal sacs occasionally

are found to be filled with blood clots of ante-mortem or post-mortem origin; very often the thin dissected channel has emptied following the last heartbeat.

The microscopic pathological changes are so intimately associated with the pathogenesis that they will be discussed together.

Originally the explanation that seemed most obvious, and actually the one that was first expounded by Virchow, was that most dissecting aneurysms arise on the basis of atheromatous ulcers. However, the fact that many of these cases occur in fairly young individuals without significant arteriosclerosis and that the majority of them begin in the ascending portion, where arteriosclerosis is minimal, has recently led to almost complete elimination of arteriosclerosis as an etiological factor. In our series, however, there is definite evidence that in four cases the primary intimal tear was on the basis of an arteriosclerotic ulcer, but in none of these did it occur in the ascending portion. In these four cases, moreover, the dissection was very short (except in one where it extended for 9 cm.), and the aneurysms did not penetrate the adventitia, reenter the original lumen, produce symptoms, or cause death. From this small group, therefore, one might infer that although arteriosclerosis is one cause of dissecting aortic aneurysms, it is responsible for only a small percentage of them (in Shennan's series, 6 out of 218 cases) and that, when it is the primary cause, the resultant aneurysm is usually small and asymptomatic and is not a factor in the patient's death. However, Shennan's cases show that this is not invariably the course in such cases.

Another theory, and one which is seldom mentioned in the literature, is that inflammation, that is, aortitis, is responsible. Theoretically there is no reason why an acute or chronic inflammation of the media should not weaken the wall sufficiently to predispose it to rupture. In two of our acute cases (Cases 4 and 10, Table I) there was a fairly diffuse infiltration of the media and adventitia with polymorphonuclear leucocytes and lymphocytes (Fig. 1). In both cases the Wassermann tests were negative, and the cells were not selectively distributed around the vasa vasorum, so that syphilis can fairly well be ruled out. The appearance slightly suggested a rheumatic aortitis, but in neither case was there any evidence, either clinically or pathologically, of rheumatic fever. Whether this degree of inflammation was a factor in the production of the aneurysm in these cases is still problematical. Can periarteritis produce enough damage to the vasa vasorum to diminish the medial blood supply and thus weaken the wall? Against this idea is the fact that syphilitic aortitis is almost never found as a background in cases of dissecting aneurysm. Tyson[21] has shown that the vasa vasorum may be obliterated either by arteriosclerosis or by a low grade inflammatory process with resultant medial hematoma and dissection without intimal tear. His findings are very suggestive that affections of the vasa vasorum may play an important rôle.

Closely allied with this last mentioned idea is what is now accepted as the most common etiological factor, namely, medial degeneration, or what has been termed by Erdheim[22] "medionecrosis aortae idiopathica cystica." The lesion was present in varying degrees in eight of our cases, six of which were in the acute group. This condition has been described so adequately by Erdheim, and recently in this country by Moritz,[23] that only a brief statement need be made here. The lesion consists of focal, and occasionally fairly diffuse, mucoid or hyaline degenerations of the media which result in cyst formation or what has often been called "faults." (Figs. 2, 3, and 4.) The whole sequence of these lesions can very easily be seen if numerous sections are taken. The etiology of these degenerations is still unsettled. Moritz was able to find them in 10 per cent of seventy adult aortas, but not in such a



Fig. 1.—Case 10. A microscopic section of an involved area showing dissection through the media. Note the subintimal atheromatous deposit, the emptied dissected channel, and the cellular infiltration of the adventitia. (×25.)

marked degree as those found in his three cases of dissecting aneurysm. He believes that it is associated with senility. Similar lesions, however, have been found in young individuals (for example, our Case 5, Table I), and have been produced experimentally in rabbits by the use of adrenalin. The consensus of opinion is that they are produced by various toxic agents associated with previous infections.

Granting the presence of some disease in the aorta—arteriosclerosis, infection, or degeneration—what is the immediate incitant that produces the aneurysm? Many observers have stressed overexertion, either physical or mental, especially associated with a hypertension. In our series of thirteen acute cases, five gave such a history: vomiting, sexual intercourse, trying a case at court, and in two cases, stooping to pick up a heavy object.

The frequent location of the initial tear in the ascending aorta about 1.5 cm. from the valve has suggested another theory for its cause, namely, the effect of the repeated diastolic recoil. This idea was first suggested by Löffler and is quoted by Shennan as follows: "When the aortic valves have closed, the abrupt recoil of diastole must bring about



Fig. 2.—Case 9. A microscopic section of the aorta showing medial cystic necrosis. (×25.)



Fig. 3.—Case 9. A higher power view of Fig. 2 taken at the extreme left of the section, stained to demonstrate the elastica, showing degeneration of the elastic and muscle fibers. (×160.)

a longitudinal stretching of the ascending aorta, and must forcibly drive the aortic valve, along with the origin of the aorta, downwards and away from the transverse part." Somewhat against this idea is the fact that during diastole the base of the heart rises, releasing the tension on the ascending aorta. In our series of thirteen acute cases the tear

occurred in six in the ascending portion close to the valve. The perforation of the adventitia frequently occurred also in the ascending portion and very often at the same level as that of the original intimal tear. In our six cases, two aneurysms did not perforate at all, but the other four all perforated close to the initial tear.

According to Shennan, the reentrance of blood from the distal end of the dissected sac into the lumen of the vessel permits circulation through the new channel and is the most important determining factor in the process which leads to healing and the production of a separate channel. This is assisted by the circumstance that the new channel passes through tissues well supplied, at least on the outer aspect, with blood vessels from which organization can take place. Just how rapidly a new lining will form in the new channel is uncertain. However, the

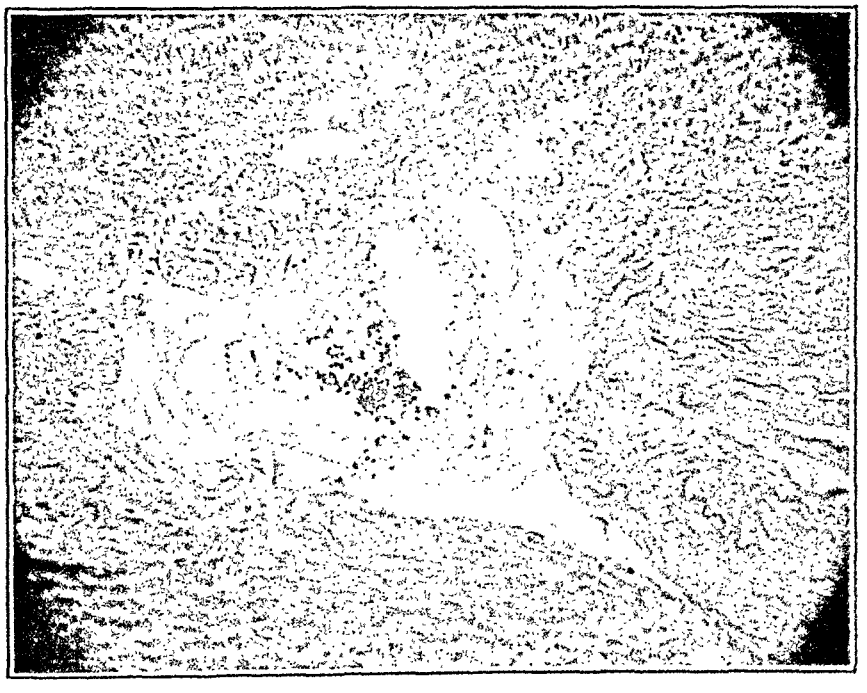

Fig. 4.—Case 9. One of the cysts. (×160.)

probable sequence of events is as follows. At first, a thin layer of thrombus is deposited on the damaged surfaces which then organizes to fibrous connective tissue. Extension of endothelium into the new channel from the mouths of ruptured aortic branches has been described by Shennan and others. It has also been suggested that the endothelial lining may develop in part at least from the new fibrous connective tissue lining the sac.

DIAGNOSIS

The clinical recognition of dissecting aneurysm of the aorta is dependent on the following points, several of which must be present before the diagnosis is justified: (1) The sudden onset, with pain reaching its maximum intensity at once or very quickly; (2) tearing or crushing pain located more often in the thorax, front or back, less often in the

abdomen; (3) wide radiation of pain, as a rule, from front of chest to back, or vice versa, often *downward* into the lower abdomen or legs, but almost never into the arms; (4) long-standing pain, hours to days, which responds poorly to the usual pain-relieving measures; (5) a history of considerable long-standing hypertension in most cases; (6) moderate to severe prostration, with or without loss of consciousness, even in the presence of extreme hypertension, which is often maintained for a varying length of time after the onset; (7) slight to moderate fever and leucocytosis for several days at least; (8) physical findings which may reveal little other than an extremely ill patient with a rapid, enlarged heart and hypertension or, in addition, evidence of blocking of the circulation to some part of the body, mainly the legs or head, as if by arterial embolism; (9) in some cases anuria, indicating dissection of the renal vessels; (10) electrocardiographic findings which are not characteristic of coronary thrombosis; (11) and, except in rare instances, sudden death a few hours to a few days after the onset of the illness as a result of rupture of the aneurysm externally into pericardium, pleura, mediastinum, or elsewhere.

DIFFERENTIAL DIAGNOSIS

The diagnosis was correctly made in only two of our thirteen acute cases. In the remaining eleven it was not even suspected. The following are the principal diagnoses considered in our series; pneumonia (2), angina pectoris (before coronary thrombosis was being diagnosed), coronary thrombosis, arteriosclerotic heart disease, hypertensive heart disease with acute congestive failure (cardiac asthma), chronic nephritis with uremia, embolism of iliac arteries, pulmonary embolism, pericarditis, and generalized peritonitis.

Coronary thrombosis is the condition with which dissecting aneurysm of the aorta is most often confused because of the thoracic location of the prolonged severe pain, which is attended by prostration and followed by slight fever and considerable leucocytosis in a middle-aged or elderly man. The following points are helpful in the differentiation: (a) the history of angina pectoris in most of the cases of coronary thrombosis and rarely in those of dissecting aneurysm; (b) the immediately overwhelming pain in the cases of dissecting aneurysm in contrast to the more gradually developing pain of coronary occlusion; (c) the widespread location and radiation of the pain of dissecting aortic aneurysm, often in or to the back, head, or abdomen, and to the legs, but rarely to the arms, which last mentioned radiation is commonly encountered in coronary thrombosis; (d) the frequent persistence of the hypertension in the case of dissecting aneurysm; (e) the evidence of very early obstruction of the arterial circulation to some part of the

body other than the heart in cases of dissecting aneurysm; and (f) the pathognomonic evidence, most important of all, of coronary thrombosis shown by daily electrocardiograms. It is of much interest that, whereas three out of every four patients with coronary thrombosis survive the acute attack, only one out of every four persons with dissecting aortic aneurysm survives.

Embolism of some part of the body, especially of the iliac, cerebral, or pulmonary arteries, is another condition likely to be confused with dissecting aortic aneurysm. The very severe pain in thorax or abdomen, without much breathlessness, the suddenness of the onset of trouble without previous evidence of disease of heart or veins which might provide a source for embolism, and the commonly fatal course of the illness serve to distinguish dissecting aneurysm in most cases. Conversely, a recent case,[24] incorrectly diagnosed as dissecting aortic aneurysm, at autopsy proved to be one of paradoxical embolism with occlusion of vessels to the left side of the head and left arm.

A surgical abdominal emergency, so called, is a diagnosis suggested by dissecting aneurysm, when it involves the abdominal aorta in particular. The suddenness of the severe pain which is likely to radiate downward on both sides, the old history of hypertension, and the absence of any previous trouble with the abdominal viscera or kidneys should at least arouse a suspicion of the correct diagnosis of dissecting aneurysm.

Pneumonia was diagnosed incorrectly in two of our cases, but the differentiation should generally be easy, because of (a) the suddenness of the onset with very severe pain, (b) the absence of evidence of pulmonary consolidation, and (c) the low fever and slight or absent cough, when dissection of the aortic wall takes place.

It should be noted finally that death in a number of cases of dissecting aneurysm has come rapidly either from vasomotor shock or from aortic rupture, so that dissecting aortic aneurysm must be added to the causes of fairly sudden death. Conversely, slight tears and small dissections may apparently take place with little or no clinical evidence, such lesions, acute or healed, being incidental necropsy findings in patients who have died of other causes.

PROGNOSIS

Dissecting aortic aneurysm of the "acute clinical type" is an overwhelming illness ending suddenly in death within a few hours or days. Among the cases with rather extensive aortic dissection in this series, only one in fourteen recovered completely (Case 15, Table II). Occasionally the dissecting aneurysm may not rupture externally for several weeks or months, permitting a longer survival. Rarely, when spontaneous rupture back into the lumen of the aorta or one of its large

branches occurs, there is recovery with survival for months or years. Such a case is included in this report in which no antecedent clinical event pointed to the existence of an old, healed "double-barreled" aorta.

Clinically, as a rule, the patients are extremely ill and run a steady downhill course. Loss of consciousness is not uncommon. The few patients who survive the initial attack and show some improvement later die suddenly without warning sign or symptom. The exceptional case that comes to post-mortem examination showing an extensive healed dissecting aneurysm, obviously not the cause of death, has not to our knowledge been observed or diagnosed correctly during life. Undoubtedly, small dissections occur without producing significant signs of symptoms.

TREATMENT

The only rational medical treatment of dissecting aneurysms of the aorta consists of keeping the patient absolutely quiet under opiates and sparing him every effort that might further increase the strain on the outer wall of the dissected portion of the vessel.

A recent case reported by Gurin and his associates[14] opens up the possibility of surgical intervention in certain cases in which the dissection has extended into the large vessels of the pelvis. In Gurin's case, the aortic dissection had advanced into the right external iliac artery involving one-third of the circumference of the vessel on its lateral aspect and opposing the intimal surfaces so as to cause nearly complete obstruction to the flow of blood to the lower extremity. An undissected area of the vessel was incised, and when the lumen was found so reduced by pressure from blood within the coats of the vessel, the intima was also incised, allowing the flow of blood from the dissected cavity back into the lumen of the vessel, thus relieving the increased pressure from above within the vessel wall and restoring the circulation to the extremity, which was maintained until death six days later. This is, in effect, precisely what occurs spontaneously at times, thus preventing external rupture which is so invariably fatal. The occasion to attempt such a measure surgically will be rare and will occur in the experience of only a few of us. But, when dealing with such a highly fatal condition, it is well to remember that such a possibility exists.

SUMMARY AND CONCLUSIONS

A clinical and anatomical analysis has been made of thirteen cases of dissecting aortic aneurysm directly related to the death of the patient, and of six other cases found incidentally among 8,200 necropsies of patients of all ages at the Massachusetts General Hospital. Included also is the report of a case in which dissection occurred between the coats of the wall of a coronary vessel. Among the thirteen "acute"

cases the diagnosis was made correctly during life in two, bringing the total of correct ante-mortem diagnoses recorded in the literature to thirteen or more.

Dissecting aortic aneurysm occurs predominantly in males between forty and sixty years of age in whom there is an antecedent history of hypertension. Whereas the clinical picture does not conform strictly to a pattern, there are certain features that, when combined, should point to the correct diagnosis. Among these are (1) sudden onset of severe tearing or crushing pain, usually thoracic, reaching its maximum intensity at once, in a person with a history of hypertension; (2) wide but variable radiation of the pain to the head, back, abdomen, or lower extremities, or to all of these, but rarely to the arms; (3) moderate to extreme collapse, and occasionally unconsciousness, even though the blood pressure may be maintained for some time at a high level; (4) evidence of arterial obstruction to the head, extremities, or kidneys when dissection along the branches of the aorta has occurred; (5) a rapid, enlarged heart, with or without significant murmurs; (6) slight to moderate fever and leucocytosis; (7) occasionally hoarseness, when rupture has occurred into the mediastinum; and (8) a variety of signs and symptoms which must be interpreted in the light of other evidence in each individual case. Coronary thrombosis and peripheral arterial embolism, particularly of the iliac, cerebral, or pulmonary vessels, are the two conditions most likely to be confused with dissecting aortic aneurysm.

Survival after the onset of symptoms, among the acute cases, averaged approximately four days, with three exceptions in whom the duration of life was six, eight, and fifteen weeks respectively. Among the incidental cases there was one patient who showed, at autopsy, a "double-barreled" aorta, which condition was unrelated to his death.

Pathologically, the predominant features are (1) intimal rupture near the aortic valve ring, (2) dissection of the medial coat of the aorta, and (3) some degree of medial degeneration. Medionecrosis aortae idiopathica cystica (Erdheim) was present in nearly one-half (six) of our acute cases and in two of our six incidental cases. Syphilis was not found as an etiological factor in any case. Proximal dissection involving the mouths of the coronary vessels occurs at times and may cause confusion in differentiating dissecting aneurysm and coronary thrombosis.

Clinical interest in this dramatic condition is mounting as shown by the increasing number of reports of correctly diagnosed cases in recent years. In paying particular attention to the clinical aspects of the disease, it is our hope that further reports of this nature will be forthcoming to add to our increasing knowledge and diagnostic acumen.

REFERENCES

1. Maunoir, J. P.: *Mémoires physiologiques et practiques sur l'aneurisme et la ligature des artères*, Geneva, 1802.
2. Peacock, T. B.: Cases of Dissecting Aneurism, or That Form of Aneurismal Affection in Which the Sac Is Situated Between the Coats of the Vessel, Edinburgh M. & S. J. 60: 276, 1843.
3. Shennan, T.: Dissecting Aneurysms, London, 1934, H. M. Stationery Office.
4. Swaine, Keyworth, and Latham: Case of Dissecting Aneurysm of Aorta, Trans. Path. Soc. London 7: 106, 1856.
5. Bahrdt, R.: Aneurysma dissecans der Bauchaorta mit lethaler Berstung zwischen die Mesocolonblätter des Colon descendens, Arch. der Heilk. 13: 473, 1872.
6. Wyss, O.: Aneurisma dissecans der Aorta ascendens, Arch. der Heilk. 10: 490, 1869.
7. Davy, H., and Gates, N.: Dissecting Aneurysm of Aorta, Brit. M. J. 1: 471, 1922.
8. Moosberger, W.: Zur Symptomatologie des Aneurysma dissecans, Schweiz. med. Wchnschr. 54: 327, 1924.
9. Barton, E. M.: *Dissecting Aneurysm of the Aorta, Arch. Path. 10: 983, 1930.*
10. Sampson, P. C.: Dissecting Aneurysms of the Aorta, Including the Traumatic Type: Three Case Reports, Ann. Int. Med. 5: 117, 1931.
11. Kellogg, F., and Heald, A. H.: Dissecting Aneurysm of the Aorta; Report of Case Diagnosed During Life, J. A. M. A. 100: 1157, 1933.
12. Weiss, Soma: Clinical Course of Spontaneous Dissecting Aneurysm of Aorta, M. Clin. North America 18: 1117, 1935.
13. Lounsbury, J. B.: Clinical Symptoms and Signs of Dissecting Aneurysm, With Report of Case Diagnosed During Life, Yale J. Biol. & Med. 7: 209, 1935.
14. Gurin, D., Bulmer, J. W., and Derby, R.: Dissecting Aneurysm; Diagnosis and Operative Relief of Acute Arterial (Iliac and Femoral) Obstruction Due to This Cause, New York State J. Med. 35: 1200, 1935.
15. White, P. D., Badger, T. L., and Castleman, B.: Dissecting Aortic Aneurysm Wrongly Diagnosed Coronary Thrombosis, J. A. M. A. 103: 1135, 1934.
16. Etling, R.: Contribution à l'étiologie des aneurysmes de l'aorte: traumatisme, 1904-05, Paris Theses, No. 98.
17. Mager, W.: Ein Beitrag zur Lehre von den Erkrankungen der Aorta, Ztschr. f. Heilk. (Path.-anat.) 24: 323, 1903.
18. Walker, C., and Walker, L.: Sudden Detachment of Aortic Intima (So-called Dissecting Aneurysm), Brit. M. J. 2: 200, 1919.
19. Ames, D., and Townsend, W. G.: Spontaneous Rupture of the Aorta Exclusive of Ruptured Aneurisms; With an Analysis of Fifty Cases, Maryland M. J. 37: 199, 1897.
20. Resnick, W. H., and Keefer, C. S.: Dissecting Aneurysm With Signs of Aortic Insufficiency; Report of Case in Which Aortic Valves Were Normal, J. A. M. A. 85: 422, 1925.
21. Tyson, M. D.: Dissecting Aneurysms, Am. J. Path. 7: 581, 1931.
22. Erdheim, J.: Medionecrosis aortae idiopathica cystica, Virchows Arch. f. path. Anat. 276: 187, 1930.
23. Moritz, A. R.: Medionecrosis Aortae Idiopathica Cystica, Am. J. Path. 8: 717, 1932.
24. Mallory, T. B.: Case Records of Massachusetts General Hospital, New England J. Med. 214: 1052, 1936.

ELECTROCARDIOGRAPHIC CHANGES IN NORMAL ADULTS FOLLOWING DIGITALIS ADMINISTRATION*

KAJ LARSEN, M.D., FRITZ NEUKIRCH, M.D., AND NIELS A. NIELSEN, M.D.
COPENHAGEN, DENMARK

THERE are available in the literature only comparatively few observations on changes in the electrocardiogram following digitalis administration, and the results reported are not in complete agreement. We have therefore carried out a series of investigations on this problem, observing in a group of healthy individuals the effect of administration of a therapeutic dose of a well-defined constant digitalis preparation.

In this paper an account will be given of the effect of digitalis on each of the different parts of the electrocardiogram, and the conclusions of previous investigators will be considered in relation to the report on our own observations.

METHOD

The study includes observations on 15 individuals (14 men and 1 woman) between the ages of nineteen and thirty-one years. None of the subjects had previously presented any cardiac symptoms, and a thorough clinical examination, including auscultation of the heart, reading of blood pressure, electrocardiography and roentgenography, had failed to reveal anything abnormal.

The digitalis preparation used was "Tabl. folii digitalis (Pharmacopea danica 1933)." This preparation is made of leaves from digitalis purpurea. The leaves are purchased in large quantities, and standardized by the eventual addition of extracted leaves, so as to obtain a constant strength, deviating by less than 5 per cent from 2,000 frog units per gram (tested on specially selected frogs).

To each one of the first ten subjects examined, 1 gm. of this preparation was given as a single dose. To subjects Nos. 11 and 12, 1.4 gm. was given, 0.6 gm. as an initial dose, followed after twenty-four hours by a dose of 0.8 gm. The remaining three subjects (Nos. 13 to 15) received a total of 3 gm. during a period of two weeks (0.8, 0.6, 0.4 and 0.2 gm. during the first four days, followed by 0.10 gm. daily for ten days).

The electrocardiograms were obtained under as constant conditions as possible, always in the morning (with the exceptions given below), the individuals fasting, and after at least a half an hour's complete relaxation in the electrocardiography room. The usual leads were taken from the extremities of the reclining person. Electrocardiography was performed three to five times previous to the digitalis administration, and 1, 2, 4, 8 and 24 hours and 2, 3, 4, 7 days and so on afterward with decreasing frequency, if possible until the disappearance of the electrocardiographic changes.

The electrocardiograms were obtained by means of an amplifier apparatus, which permitted the simultaneous registration of all three leads. Each electrocardiogram was standardized for a test potential of 1 mv. for determination of the millivoltage of the waves (1 mv. = 19 – 22 mm.). The height of the waves was measured with

*From the Medical Clinic B, University of Copenhagen (Chief physician, Professor E. Warburg, M.D.).

a pair of compasses and a diagonal ruler; the measurements were always performed on five to seven consecutive complexes in each electrocardiogram, and the height of the waves calculated as the mean value, expressed as millivolts.

The time indication represented 0.05 sec. As the velocity of the film was 7 to 8 cm. per second, the length of the various intervals could be measured with an accuracy of 0.005 sec. Also for these determinations the mean value of 5 to 7 consecutive complexes was calculated. The length of the intervals was estimated in Lead II only.

CHANGES OF THE P-WAVE

Cohn and Fraser[4] in all their subjects studied observed changes of the P-wave, but no report is available concerning the nature of these changes. Routier and Puddu[16] found changes of the P-wave in four out of twelve healthy subjects, the wave becoming lower, diphasic, or negative; these changes usually occurred in Leads II and III. In contrast to these findings White and Sattler[20] observed no changes of the P-wave in ten healthy young men.

In the present studies no definite changes in the height or shape of the P-wave were seen.

CHANGES OF THE LENGTH OF THE P-Q INTERVAL

Whereas Stewart and Cohn[18] found no increase in the length of the P-Q interval in six normal individuals following ingestion of a single dose of 0.8 to 1 gm. of digitan, such increase was observed by most other investigators in at least some of the subjects studied. Thus Cohn and Fraser[4] found prolonged P-Q interval in each of four normal individuals after doses corresponding to 2 to 4 gm. of digitalis leaves. White and Sattler[20] observed increases of 0.01-0.02 sec. in the P-Q interval in seven out of ten healthy young men following ingestion of 2 to 3 gm. of digitalis leaves during a period of seven to eleven days. Dieuaide, Tung, and Bien[7] found the P-Q interval prolonged by 0.01-0.04 sec. in four normal subjects after doses of digitalis corresponding to 1 to 1.2 gm. of digitalis leaves. Finally van Dyke and Li[8] observed in four normal individuals increases of 0.005-0.015 sec. following digitalis administration in doses, which are not reported in their paper. In all instances the duration of P-Q was below 0.20 sec. McCulloch and Rupe,[6] after digitalis administration to thirty-six children presenting no evidence of heart disease, following a schedule of dosage outlined in their paper, observed in 9 cases a characteristic change in the length of the P-Q interval, the length varying with the diastole, being shorter after a long diastole and longer after a short diastole. This abnormality was classified as "sinus arrhythmia," and it was expressly stated that the duration of the R-R and P-Q intervals was independent of the respiratory phase. In three other children prolonged P-Q interval was likewise found, but not varying with the length of the diastole. Brams and Gaberman[2] once observed prolonged conduction time (P-Q = 0.34

sec.), and once a 2-to-1 block. Finally it should be mentioned that McCulloch and Rupe,[6] Georgopoulus,[10] Samet and Tezner[17] each observed one case of sino-auricular block following the administration of digitalis to normal individuals.

In four out of fifteen subjects examined during the present study, definite prolongation of the P-Q interval was found, e.g., increases above 0.01 sec. (Table I). In two individuals (Nos. 1 and 8) the prolongation was only moderate (0.015 and 0.011 sec., respectively), and the duration of the P-Q interval did not exceed 0.20 sec. Each of the two other subjects (Nos. 2 and 13) had a slow pulse rate previous to the digitalis administration (50.5 and 42.5 beats per minute) and P-Q intervals of a duration of 0.205 and 0.197 sec., respectively, and low P-waves. In both these individuals the digitalis ingestion caused changes quite similar to those classified by McCulloch and Rupe as "sinus arrhythmia." In subject No. 13, a marked respiratory arrhythmia was noticed on the second day following the digitalis administration (Table II), with varying duration of P-Q, the interval being short (0.215 sec.) after a long diastole, and long (0.28 sec.) after a short diastole. If the person was made to stop breathing, the P-Q interval became of the same length (0.27 sec.) with each heartbeat. In subject No. 13 similar observations were made on the eleventh and twelfth days of the experiment, e.g., after ingestion of 2.7 to 2.8 gm. of digitalis. In this individual deep and slow breathing caused no respiratory arrhythmia, but the duration of P-Q varied with the respiratory phase from 0.16 to 0.23 sec. This variation disappeared when the subject was made to stop breathing; under these conditions a marked shortening of the P-Q interval was noticed (0.12 to 0.14 sec.), the duration of the interval being shorter than at any other time during the whole experimental period (Table II). In subject No. 15 a varying length of the P-Q interval was observed both before and after the digitalis administration; this individual had a definite respiratory arrhythmia and a very low P_1; the pulse rate was 51 to 68.

CHANGES OF THE QRS COMPLEX

According to Georgopoulus, the height of the initial complexes increases in normal individuals after digitalis administration.

In the present investigations no notable changes of the QRS complex were observed. In three individuals the R_1-wave from the second to the fifth day following the digitalis ingestion was 0.15-0.25 mv. (3-5 mm.) lower than before the administration and long time afterward. In two of these three subjects the R_2-wave at the same time was a little higher. In subject No. 13, who had received 3 gm. of digitalis, the R_1- and R_2-waves, twenty-five days after the digitalis ingestion, still were definitely lower than before the administration; at this time the observations were

TABLE I

MAIN ELECTROCARDIOGRAPHIC CHANGES FOLLOWING DIGITALIS ADMINISTRATION TO FIFTEEN NORMAL ADULTS

INDIVIDUAL NO.	BEFORE OR AFTER DIGITALIS ADMINISTRATION	P-Q (SEC.)	S_1-T_1	S_2-T_2	T_1 (MV.)	T_2 (MV.)	T_3 (MV.)		LENGTH OF Q-T INTERVAL PER CENT*	HEART RATE
1	Before	0.120	positive	positive	0.48	0.38	+0.40		100.6	60
	After	0.135	lower	lower	0.30	0.24	+0.32		96.0	46
2	Before	0.205	isoelectric	isoelectric	0.10	0.28	0.26		101.0	51
	After	0.275	negative	negative	0.02					
					+0.01	0.09	0.13		87.0	50
3	Before	0.170	positive	positive	0.20	0.35	0.21		100.0	59
	After	0.175	isoelectric	isoelectric	0.07	0.18	0.10		88.0	48
4	Before	0.167	positive	positive	0.29	0.44	0.22		103.5	52
	After	0.173	lower	lower	0.21	0.22	0.09		94.5	53
5	Before	0.171	positive	positive	0.35	0.54	0.30		100.5	43
	After	0.171	lower	lower	0.25	0.39	+0.06	+0.08	89.5	42
6	Before	0.155	positive	positive	0.18	0.40	0.28		97.5	59
	After	0.164	unchanged	unchanged	0.19	0.38	0.20		92.5	52
7	Before	0.149	isoelectric	positive	0.15	0.21	0.20		102.5	62
	After	0.151	unchanged	isoelectric	0.09	0.15	+0.12	+0.05	94.5	51
8	Before	0.147	positive	positive	0.38	0.68	0.42		93.0	67
	After	0.158	unchanged	lower	0.31	0.41	0.15		84.5	56
9	Before	0.158	positive	positive	0.15	0.31	0.20		104.5	57
	After	0.165	unchanged	lower	0.12	0.15	+0.05	+0.05	98.0	52
10	Before	0.140	positive	isoelectric	0.33	0.34	+0.10	+0.15	101.5	58
	After	0.146	lower	negative	0.18	0.19	+0.22	+0.08	94.5	56
11	Before	0.140	positive	positive	0.37	0.40	+0.05	+0.05	97.0	51
	After	0.138	lower	lower	0.20	0.23	+0.10	+0.10	90.5	48
12	Before	0.169	positive	positive	0.21	0.36	0.25		100.0	62
	After	0.173	lower	isoelectric	0.08	0.10	+0.19		91.5	51
13	Before	0.197	positive	positive	0.42	0.60	0.30		103.5	43
	After	0.230	lower	isoelectric	0.24	0.33	0.14		93.5	33
14	Before	0.180	positive	positive	0.38	0.58	0.33		101.5	60
	After	0.182	lower	lower	0.27	0.40	0.12		89.0	60
15	Before	0.14-0.17	positive	positive	0.18	0.52	0.35		104.5	68
	After	0.14-0.17	lower	lower	0.15	0.23	0.12		91.0	52

*The percentage values are calculated for the respective heart rates from the equation given by Fridericia.

discontinued because of external causes. On the other hand, no changes in the height of the initial complexes were seen in subjects Nos. 14 and 15, who had likewise received 3 gm. of digitalis.

CHANGES OF THE S-T INTERVAL

Changes of the S-T interval appear to have been only rarely the subject of special consideration in the literature. Pardee[15] observed depression of the S-T interval in eight individuals presenting no evidence

TABLE II

The Length of the $R\text{-}R_2$, $P\text{-}Q_2$, and $Q\text{-}T_2$ Intervals in 14 Successive Heartbeats, in Two Individuals Presenting Prolonged Conduction Time Due to Digitalization. Under Normal Breathing and During Cessation of Respiration

INDIVIDUAL NO. 2				INDIVIDUAL NO. 13			
BEAT NO.	PRECEDING $R\text{-}R_2$ INTERVAL (SEC.)	$P\text{-}Q_2$ (SEC.)	$Q\text{-}T_2$ (SEC.)	BEAT NO.	PRECEDING $R\text{-}R_2$ INTERVAL (SEC.)	$P\text{-}Q_2$ (SEC.)	$Q\text{-}T_2$ (SEC.)
			Normal Respiration				
1	1.17	0.22	0.36	1	–	0.21	0.44
2	0.88	0.25	0.35	2	1.74	0.23	0.43
3	0.96	0.28	0.355	3	1.78	0.17	0.45
4	1.405	0.215	0.36	4	1.78	0.16	0.45
5	1.235	0.215	0.36	5	1.77	0.18	0.44
6	0.88	0.25	0.36	6	1.76	0.20	0.45
7	0.925	0.28	–	7	1.76	0.23	0.45
8	1.40	0.215	0.36	8	1.75	0.22	0.44
			Cessation of Respiration				
9	1.105	0.24	0.36	9	1.79	0.16	0.45
10	0.94	0.27	0.355	10	1.83	0.15	0.45
11	1.075	0.27	0.355	11	1.82	0.13	0.45
12	1.105	0.26	0.36	12	1.78	0.14	0.44
13	1.015	0.27	0.35	13	1.76	0.14	0.46
14	0.96	0.27	0.35	14	1.75	0.12	0.45

of heart disease, and Routier and Puddu[16] observed changes in eight out of twelve normal persons: the nature of these changes is, however, not specified.

In the present study the changes in the S-T interval were found to be closely connected with changes in the height of the T-wave. As will be seen from Table I, the $S\text{-}T_1$ and $S\text{-}T_2$ lines in most of the cases examined were a little above the isoelectric line before the digitalis administration and after the ingestion usually approached or reached this line. Only in two instances did the S-T line descend below the isoelectric line, in one of the cases in both Lead I and Lead II, in the other case in Lead II only; in both the cases the S-T line was isoelectric before the digitalis ingestion. In those instances where no change was observed in the S-T interval no changes were seen either in the corresponding T-waves. This occurred four times in Lead I and once in Lead II.

CHANGES OF THE T-WAVE

Although the statements in the literature concerning the effect of digitalis administration on the shape of the T-wave in normal subjects on the whole are in good agreement, all possible variations have been reported. Thus Nicolai and Simons[14] found T_1 lower in one and higher in four normal individuals after administration of 1.5 gm. of digitalis during a period of five days. Samet and Tezner[17] in their observations on children occasionally found the T-wave unchanged or higher, although there were clinical symptoms of intoxication present. Some of the children were stated to be in good health, whereas others had just recovered from pneumonia. Brams and Gaberman[2] gave digifolin intravenously to nine healthy individuals until the appearance of symptoms of intoxication. In four cases the T-waves remained unchanged, in five cases the waves became 1 to 3 mm. lower, but these moderate changes were interpreted by the authors as being due to extracardial conditions, for instance, changes of position. Several investigators observed flattening of the T-waves in most of the persons examined (White and Sattler,[20] Kahlson,[12] Grünbaum[11]). Others have noticed even greater changes. Both Cohn[5] and Pardee[15] found inversion of the T-waves in normal individuals following digitalis administration, but their publications contain no information concerning the number of cases in which this change was observed, nor is it reported whether the individuals showed any signs of intoxication. The dose of digitalis used by Cohn was 2 to 3 gm. of digitalis leaves, given in the course of five to seven days, whereas Pardee gave 1 minim by mouth of digitalis tincture per pound of body weight (1.25 c.c. = 1 cat unit). Marvin, Pastor, and Carmichael[13] gave preoperatively to thirty patients during two to three days a total of 1.5 gm. of digitalis leaves per 45 kilograms of body weight, and in twenty-nine of these cases observed "a characteristic inversion of the T-wave or of the S-T interval"; only five of the thirty patients suffered from unquestionable heart diseases. Routier and Puddu[16] found inversion of the T-wave in six out of twelve normal subjects following the daily intravenous administration of 0.0002 gm. digitaline cristallisée for five or ten days. Finally Stewart and Cohn,[18] Grünbaum,[11] Cheer and Dieuaide[3] each observed one case of inversion of the T-waves. In some of these cases the subjects had been digitalized until the occurrence of symptoms of intoxication.

In the present investigations changes in the shape of the T-waves were found in fourteen of the fifteen individuals studied (Table I).

In Lead I the T-wave was found unchanged in six cases and lower in nine cases, in one of these diphasic.

In Lead II the T-wave was found unchanged in two cases and lower in thirteen cases.

In Lead III the T-wave was found unchanged in three cases; in seven cases a positive T_3 became lower, but remained positive; in three cases a positive T_3 became diphasic, and in one case negative. Finally in one case an original diphasic T_3 became practically negative during the influence of the digitalis.

It should be mentioned that the T-waves have been classified as lower only in those cases in which on measurement a reduction of at least 0.1 mv. was found as compared with the average height before the digitalis administration; in the electrocardiograms taken before the ingestion, the variations in the height of the T-waves were always less than 0.1 mv. The T-waves were found reduced to 33 to 67 per cent of their original height, or a reduction of 0.1 to 0.25 mv., corresponding to a 2 to 5 mm. reduction in the electrocardiogram, a change which is easily perceptible with the naked eye.

CHANGES IN THE LENGTH OF THE Q-T INTERVAL

In later years several Chinese investigators (Cheer and Dieuaide,[3] Dieuaide, Tung and Bien,[7] van Dyke and Li,[8]) have studied the length of the Q-T interval under various conditions. They have employed the equation of Bazett,[1] according to which $Q\text{-}T = K \sqrt{R\text{-}R}$. Changes in the length of the Q-T interval which are caused by changes in the pulse rate will be expressed as variations of the constant K. After administration of digitalis to thirteen normal individuals, these investigators in all instances observed a shortening of the Q-T interval.

In the present investigations a relative shortening of the Q-T interval was found in all the cases studied (Table I).

According to Fridericia[9] there exists in normal individuals the following relationship between the length of the Q-T interval and the pulse rate: $Q\text{-}T = 8.22 \sqrt[3]{R\text{-}R}$. Our measurements show a very good agreement with this equation, the length of the Q-T interval in fourteen of the individuals before the digitalis administration being 97-104.5 per cent of the value calculated from the equation, whereas in subject No. 8 an interval was found equaling 93 per cent of the calculated value. While the digitalis influence was at its maximum the Q-T interval was reduced to only 87-98 per cent of the calculated value, all the individuals, as seen from Table I, presenting a relative shortening amounting to 4.6 to 14 per cent. This shortening bore no relation to the degree of flattening of the T-waves.

It will be noticed that only three of the individuals studied presented a shortening of or exceeding 0.045 sec. in relation to the value calculated from the equation. According to Fridericia, the deviation must exceed 0.045 sec. to be classified as abnormal. However, the observed digitalis effect appears unquestionable as it was found in all the individuals in a series of electrocardiograms taken shortly after the digitalis adminis-

tration, whereas the changes were not present in the electrocardiograms obtained before, or a long time after, the administration. The observance by White and Mudd[19] of a similar strictness in the requirements as those laid down by Fridericia explains the statement of these authors of having observed no shortening of the Q-T interval after administration to normal individuals of 2 to 3 gm. of digitalis leaves, a dose which caused moderate symptoms of intoxication. By looking over their figures it will be seen, however, that a relative shortening of the Q-T interval took place in four of the five individuals studied, the reduction ranging from 3 to 6.5 per cent.

CHANGES OF THE HEART RATE

According to Pardee,[15] changes in the pulse rate are observed less frequently than changes in the shape of the T-waves. Nevertheless, several investigators, including Stewart and Cohn,[18] Brams and Gaberman,[2] Routier and Puddu,[16] claim to have observed a slower pulse rate in nearly all the individuals studied. On the other hand White and Sattler[20] noticed a slower pulse in only four out of ten healthy young men, and McCulloch and Rupe[6] found a reduction of the pulse rate amounting to 15 beats or more per minute in only nine of thirty-six children who presented no evidence of heart disease.

In the present investigations the heart rate was found to decrease by 5 beats or more per minute in nine out of fifteen subjects studied. In six of the nine cases the reduction valued 10 beats or more per minute, the decreases being calculated as the differences between the minimum values before and after digitalis administration.

CHANGES OF RHYTHM

The occurrence of arrhythmia in normal individuals following digitalis administration appears to be infrequent. The occurrence of 2-to-1 block in the case observed by Brams and Gaberman[2] was followed by transitory auricular fibrillation. A case of paroxysmal auricular fibrillation in a child is reported by Samet and Tezner.[17]

As mentioned above, one of the subjects studied during the present investigations had a marked respiratory arrhythmia following the digitalis administration. Other types of arrhythmia were not observed.

TIME OF APPEARANCE AND DURATION OF THE CHANGES

The duration of the electrocardiographic changes following digitalis administration appears to be of special interest. According to Cohn,[5] the T-waves had returned to normal from five to twenty-two days after the digitalis ingestion. In the cases observed by White and Sattler,[20] the changes lasted for ten to nineteen days. However, in most of Grünbaum's cases[11] the changes persisted for a few days only, although in one case with inversion of the T-waves they lasted for thirty days.

According to Cheer and Dieuaide,[3] the shortening of the Q-T interval appears simultaneously with the flattening of the T-waves but again disappears before the T-waves regain their initial height.

Of the ten subjects who received 1 gm. of digitalis as a single dose three persons presented changes of the Q-T interval within two hours after the digitalis administration; in four the changes appeared after four hours, in two cases, after eight hours, and in one case, not until twenty-four hours after the ingestion. The maximum change was observed from twenty-four to seventy-two hours after the digitalis administration; the length of the Q-T interval was returned to normal after five to twenty-nine days.

In the two individuals receiving 1.4 gm. of digitalis in fractional doses, the change in the length of the Q-T interval appeared twenty-four and thirty-three hours after the first administration and was at its maximum from the second to the sixth day. The length of the Q-T interval was returned to normal twenty-two and ten days after the digitalis ingestion had been discontinued.

In the three individuals receiving 3 gm. of digitalis the first electrocardiogram after the digitalis administration was obtained twenty-four hours after the first dose had been given. At this time the Q-T interval was found shortened in all the three cases. The maximum shortening was observed four days after the first ingestion and persisted during the whole period of digitalis administration. In No. 13 the Q-T interval was returned to its normal length twenty-five days after the last dose, and in No. 14 after thirty days, whereas in No. 15 the shortening was still present thirty days after the last administration, at which time the observation was discontinued due to external conditions.

The flattening of the T-waves was frequently found to occur simultaneously with the shortening of the Q-T interval, but might appear a little earlier or later. In some instances the height of the T-waves returned to normal slightly before the Q-T interval had regained its normal length, in other cases these changes took place simultaneously, and in still other cases the T-waves remained flattened after the Q-T interval had again become normal. In one individual, who had received 3 gm. of digitalis, a marked flattening of the T-waves still persisted twenty-five days after the digitalis administration, at which time the observations were discontinued. After the ingestion of 1 gm. of digitalis the flattening of the T-waves lasted for twenty-one days at the most.

Concerning the time of appearance of the other changes it can be stated that the changes in the S-T interval usually occurred simultaneously with the changes in the T-waves. Reduction of the pulse rate and changes in the length of the P-Q interval were observed simultaneously with the maximum reduction of the height of the T-waves; these changes persisted, however, for a shorter period than the flatten-

ing of the T-waves. In the two instances where an increase of the length of the P-Q interval was found, varying with the respiratory phase, this change persisted for only five and two days, respectively.

SYMPTOMS OF INTOXICATION

Four of the subjects studied presented slight symptoms of intoxication. Thus No. 3 and No. 15 claimed slight dyspnea on exertion eight to ten hours after intake of 1 and 1.4 gm. of digitalis, respectively. No. 6, ten hours after the ingestion of 1 gm. of digitalis, experienced slight nausea and dizziness. No. 13, after receiving approximately 2 gm. of digitalis through a period of five days, suffered slight nausea and palpitations during the successive four to five days; these symptoms occurred three to four hours after the ingestion of a daily dose of 0.1 gm. of digitalis and usually lasted for about half an hour. No special changes were observed in the electrocardiogram at the time of appearance of these symptoms.

DISCUSSION

In all the subjects studied a relative shortening of the Q-T interval was observed after digitalis administration. Only a few investigators have measured this interval, but they all have noticed this shortening; only in one of the five individuals studied by White and Mudd no reduction of the length of the Q-T interval was seen following digitalis administration. It must therefore be considered as established that digitalis produces a shortening of the systole as compared with the pulse period. This fact is in agreement with the demonstration by Wiggers and Stimson[21] of a shortening of the systole following strophanthin administration to vagotomized dogs, whose heart rate was kept constant through electric stimulation of the atrium.

In regard to the changes in the height of the T-waves, the results of some investigators are not in agreement with our observations. The finding by Nicolai and Simon[14] of higher T-waves in normal individuals following digitalis administration appears to be exceptional. However, consideration should be made of the fact that this publication dates from 1909, e.g., from the earliest days of electrocardiography, and that no information is given concerning the electrocardiographic technic, particularly the standardization of the electrocardiograms. It therefore appears possible that this exceptional finding may be explained by a deficient technic. Several investigators have observed more marked changes of the T-waves (inversion) than was found in the present study, although the doses of digitalis given were of the same size and the way of administration similar, large single doses being given. However, the clinical data for the individuals studied are scarce. In the group of subjects examined by Marvin, Pastor, and Carmichael[13] patients of all age groups, suffering from diseases necessitating major

operations, were included, most of the individuals, however, presenting no signs of heart disease. The other authors merely state that the subjects suffered from no diseases of the circulatory system, but no information is given concerning the age of the individuals. In contrast to this all the individuals studied in the present investigations were young and healthy.

The other changes in the electrocardiogram observed during the present studies were found in a few individuals only. Our observations therefore permit the conclusion that different individuals may behave differently toward the same dose of digitalis.

The electrocardiographic changes were found to persist up to a period of about one month, a fact which must be considered in interpretation of electrocardiograms from patients who have received digitalis.

SUMMARY

1. Electrocardiograms were obtained in fifteen young, healthy individuals following the administration of a therapeutic dose of digitalis.

2. In all the individuals studied, a relative shortening of the Q-T interval was found.

3. In fourteen of the fifteen individuals studied, the T-waves became lower in one or more leads, but in one case remained unchanged.

4. The heart rate became slower in nine of the fifteen cases.

5. In four cases the conduction time increased. In two of these cases the P-Q interval was above 0.20 sec.; in both these instances the length of the interval varied with the respiratory phase.

6. Electrocardiographic changes were noticed, at the earliest, two hours after the digitalis ingestion.

7. The electrocardiographic changes persisted for a period up to thirty days.

REFERENCES

1. Bazett, H. C.: An Analysis of the Time-Relations of Electrocardiograms, Heart 7: 353, 1920.
2. Brams, W. A., and Gaberman, P.: The Effect of Digitalis on the T-Wave of the Electrocardiogram: An Experimental Study in Human Beings, Am. Heart J. 6: 804, 1931.
3. Cheer, S. N., and Dieuaide, F. R.: Studies on the Electrical Systole ("Q-T" Interval) of the Heart. III. The Effect of Digitalis on Its Duration in the Normal Heart. Chinese J. Physiol. 5: 217, 1931.
4. Cohn, A. E., and Fraser, F. R.: Certain Effects of Digitalis on the Heart, J. Pharmacol. & Exper. Therap. 5: 512, 1913-14.
5. Cohn, A. E.: Clinical and Electrocardiographic Studies on the Action of Digitalis, J. A. M. A. 65: 1527, 1915.
6. McCulloch, H., and Rupe, W. A.: Studies on the Dosage of Digitalis in Children, Am. J. M. Sc. 162: 231, 1921.
7. Dieuaide, F. R., Tung, C. L., and Bien, C. W.: A Study of the Standardization of Digitalis. I. A Method for Clinical Standardization, J. Clin. Investigation 14: 725, 1935.
8. Van Dyke, H. B., and Li, R. C.: A Study of the Standardization of Digitalis. II. The Relationship Between Laboratory Methods of Assay and Potency as Determined by Experimental Cumulative Poisoning and Clinical Standardization, J. Clin. Investigation 14: 733, 1935.

9. Fridericia, L. S.: Die Systolendauer im Elektrokardiogramm bei normalen Menschen und bei Herzkranken, Acta med. Scandinav. 53: 469, 1920.
10. Georgopoulus, M.: Ueber den Wert der Kontrolle der Digitalisbehandlung durch die Elektrokardiographie, Deutsches Arch. f. klin. Med. 176: 348, 1934.
11. Grünbaum, F.: Kontrolle der Digitalisbehandlung durch das Elektrokardiogramm, Ztschr. f. klin. Med. 116: 746, 1931.
12. Kahlson, G.: Beitrag zur Diagnose der Herzmuskelschwäche, Verhandl. d. deutsch. Gesellsch. f. inn. Med. p. 421, 1928.
13. Marvin, H. M., Pastor, R. B., and Carmichael, M.: The Electrocardiogram and Blood Pressure During Surgical Operation and Convalescence. Effect of Routine Preoperative Digitalization, Arch. Int. Med. 35: 782, 1925.
14. Nicolai, G. F., and Simons, A.: Zur Klinik des Elektrokardiogramms, Med. Klin. 5: 160, 1909.
15. Pardee, H. E. B.: Rate of Absorption of Digitalis From the Gastro-Intestinal Tract: Clinical Study, J. A. M. A. 75: 1258, 1920.
16. Routier, D., and Puddu, V.: Étude clinique de l'action de la digitale sur l'électrocardiogramme, Arch. d. mal. du coeur 29: 800, 1935.
17. Samet, B., and Tezner, O.: Ueber Digitaliswirkung bei gesunden und kranken Kindern ohne Herzinsuffiziens, Monatschr. f. Kinderh. 31: 300, 1925.
18. Stewart, H. J., and Cohn, A. E.: Studies on the Effect of the Action of Digitalis on the Output of Blood From the Heart: I. The Effect on the Output in Normal Human Hearts, J. Clin. Investigation 11: 917, 1932.
19. White, P. D., and Mudd, S. G.: Observations on the Effect of Various Factors on the Duration of the Electrical Systole of the Heart as Indicated by the Length of the Q-T Interval of the Electrocardiogram, J. Clin. Investigation 7: 387, 1929.
20. White, P. D., and Sattler, R. R.: The Effect of Digitalis on the Normal Human Electrocardiogram, With Special Reference to A-V Conduction, J. Exper. Med. 23: 613, 1916.
21. Wiggers, C. J., and Stimson, B.: The Mechanism of Cardiac Stimulation by Digitalis and g-Strophanthin, J. Pharmacol. & Exper. Therap. 30: 251, 1927.

AURICULAR FIBRILLATION WITH CONGESTIVE FAILURE AND NO OTHER EVIDENCE OF ORGANIC HEART DISEASE*

I. C. Brill, M.D.
Portland, Oregon

IN RECENT years it has become generally recognized that auricular fibrillation may occur in an otherwise normal heart. Among the more important publications relating to this problem are those of Parkinson and Campbell,[1] Fowler and Baldridge,[2] Friedlander and Levine,[3] and Orgain, Wolff and White.[4] It is less commonly appreciated, however, that auricular fibrillation, apart from any other disease of the heart, may cause severe congestive failure and that upon cessation of the arrhythmia, the congestive failure may be followed by complete and lasting recovery. Such clinical occurrences are admittedly uncommon, yet their recognition is exceedingly important, since a prompt diagnosis and immediate application of appropriate therapy make possible a favorable prognosis in what might otherwise prove a serious and disabling illness.

In view of the above considerations the following report is presented.

REPORT OF A CASE

History.—A married woman, aged forty-three years, was first seen June 11, 1935. On June 1, 1935, she had consulted her family physician with the complaints of shortness of breath, weakness, and fatigue. Her father had died of angina pectoris at sixty-three years, her mother, of breast cancer at fifty-seven years, and her brother, aged forty-six years, was living and well. In childhood she had had mumps, measles, and chickenpox. She had also suffered frequent sore throats, which ceased after a tonsillectomy at the age of fourteen years. She had never had rheumatism or chorea, but during the past fifteen years she had had several attacks of "sinus trouble," and her antrums were punctured several times. Menstruation began at thirteen years and had always been normal.

She was married twenty-five years ago. Her husband, and two children aged twenty-three years and fifteen years, respectively, are living and well. There were no miscarriages. On several occasions during the past eight or ten years, she has consulted her family physician for the purpose of obtaining a diet to reduce her weight. This was for purely esthetic reasons. In fact, her weight was never excessive, usually fluctuating between 135 and 140 pounds. On one of these occasions her basal metabolic rate was determined and found to be −7 per cent. On the advice of her physician she did not diet severely, nor did she take thyroid extract or any other reducing drug. Her urine and blood pressure have been examined frequently, during her pregnancies and on various occasions since, and have always been found normal.

Her present illness is traced back to about the middle of January, 1935, when she suffered an attack of "sinus trouble," lasting two to three weeks. There was

*From the Department of Medicine, University of Oregon Medical School.

slight fever at the onset. During that illness she was under the care of an otolaryngologist, who kept her at rest for two or three days and thereafter treated her at his office for about two weeks. Her antrums were washed several times during that period. In a comparatively short time she resumed her normal activities and considered herself fairly well, but she noticed that she tired more easily than she had in the past.

About the middle or the end of March, 1935, she began to experience some difficulty in going to sleep because of a peculiar uneasiness in her chest, of which she would become aware upon retiring. She often found it more comfortable sitting up in a chair than lying in bed. She attributed those symptoms to "just nervousness" and continued a rather active social life for another two months; but about the middle of May, 1935, she noticed that she was getting short of breath and that she was gaining weight. At first she gained about two pounds per week, but early in June, the gain in weight became very rapid, and on June 11, 1935, she weighed 160 pounds, showing an increase of 25 pounds in less than a month.

Examination.—On June 11, 1935, physical examination revealed evident dyspnea at rest, moderate ankle edema, and signs of fluid in the pleural, pericardial and peritoneal cavities. The heart rate at the apex was 160 per minute; the rhythm was

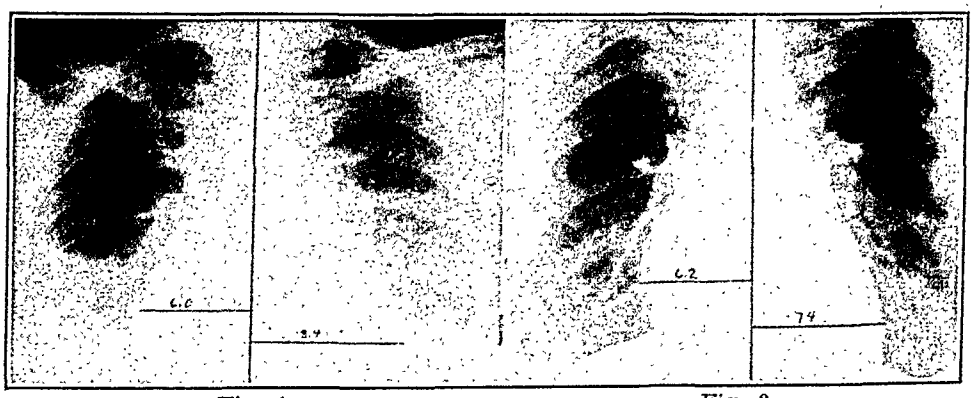

Fig. 1. Fig. 2.

Fig. 1.—Film taken June 8, 1935, showing passive congestion and fluid in pleural cavities. The transverse diameter of cardiac shadow measures 14.4 cm.

Fig. 2.—Film taken June 17, 1935, showing slight passive congestion. No sign of fluid in pleural cavities. The width of the cardiac shadow is now 13.6 cm.

grossly irregular, and there was a systolic apical murmur. An x-ray film of her chest (Fig. 1) taken on June 8, three days before this examination, reveals essentially the same condition, though not so far advanced as the changes found June 11, 1935.

Diagnosis.—The existence of auricular fibrillation with congestive failure was obvious; but the underlying anatomical and physiological pathology remained obscure, since no clue to their identity could be discovered either in the history or by physical examination.

The patient was at her home at the time of this examination, and, since she had already received small doses of digitalis during the preceding two or three days, it was thought best to complete the digitalization before removing her to the hospital for further observation. Adequate digitalization during the ensuing six days caused great diuresis, accompanied by a loss of 15 pounds in weight, and a reduction of the pulse rate to 85 per minute. The patient's condition improved greatly, and on June 17, 1935, she was removed to St. Vincent's Hospital. An x-ray film of her chest (Fig. 2) taken on that day confirmed the clinical evidence of the disappearance of the pleural and pericardial effusions and the marked reduction in passive

congestion. An electrocardiogram (Fig. 3) made the same day showed the presence of auricular fibrillation, but except for the digitalis effect the ventricular complexes were normal. Her temperature and respirations were normal.

Laboratory Findings.—The basal metabolic rate (June 18) was +2 per cent. The urine, blood count, Kahn and Kolmer reactions were all normal.

Treatment.—On June 18, 1935, at 2:00 P.M., the patient was given a "test" dose of 0.2 gm. (3 grains) of quinidine sulphate. When examined two hours later, the heart was found beating at a rate of 60 per minute, and the rhythm was entirely normal.

The following day the electrocardiogram (Fig. 4) confirmed the presence of sinus rhythm, and, but for slight digitalis effect, no deviation from the normal was indi-

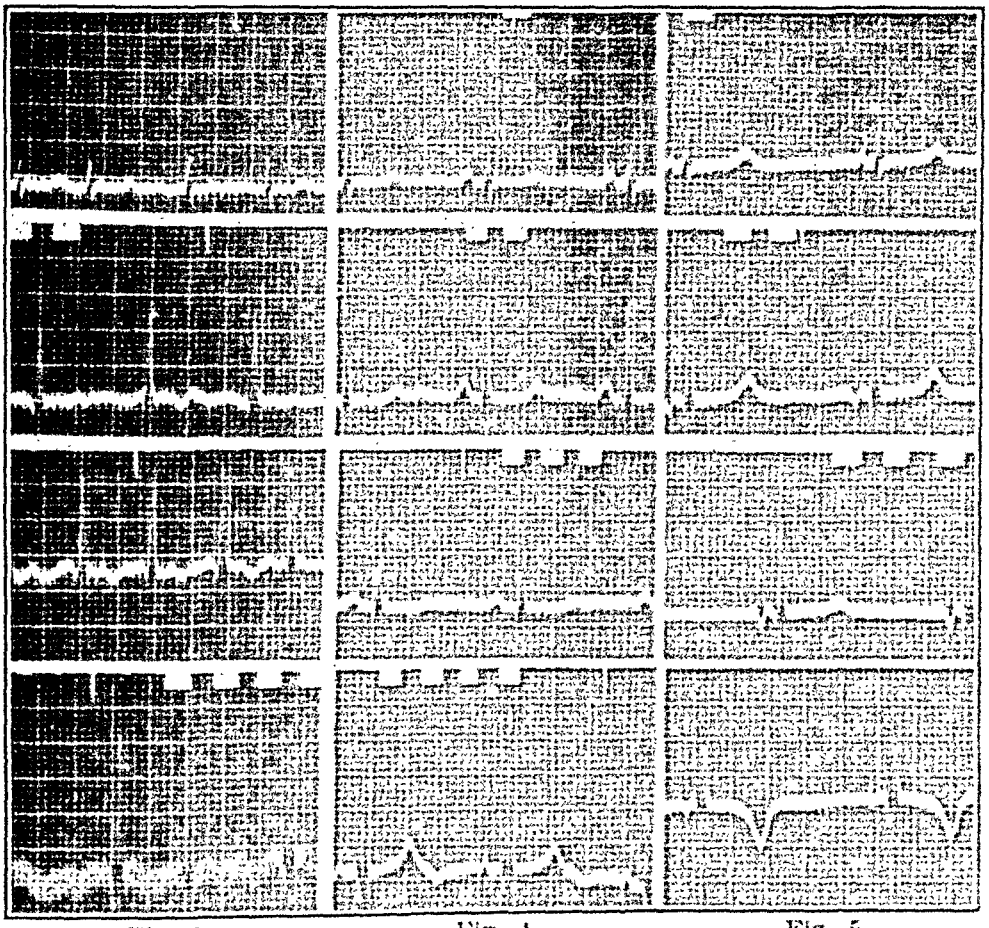

Fig. 3. Fig. 4. Fig. 5.

Fig. 3.—Electrocardiogram taken June 17, 1935, showing auricular fibrillation and some evidence of digitalis effect. Ventricular rate, 110.

Fig. 4.—Electrocardiogram taken June 18, 1935, showing sinus rhythm and some evidence of digitalis effect. Ventricular rate, 75.

Fig. 5.—Electrocardiogram taken July 11, 1935, showing normal tracing except for inverted P-waves in Leads II and III. Ventricular rate, 75.

cated. The same day the patient was sent home with instructions to take quinidine, grain ½, three times daily, for two days. Thereafter all medication was stopped, and recovery was rapid and uninterrupted.

Three weeks later (July 11, 1935) the patient walked into the hospital, climbing many stairs with no difficulty whatever. The heart was normal, and no murmurs were heard. The blood pressure was normal (systolic 130, diastolic 80). The radial pulse was of good quality, and the artery itself was too soft to be palpated. The retinal vessels appeared entirely normal. The electrocardiogram on that day

(Fig. 5) was normal except for inverted P-waves in Leads II and III. This alteration has never recurred and was not considered significant of any structural change. The digitalis effect had disappeared.

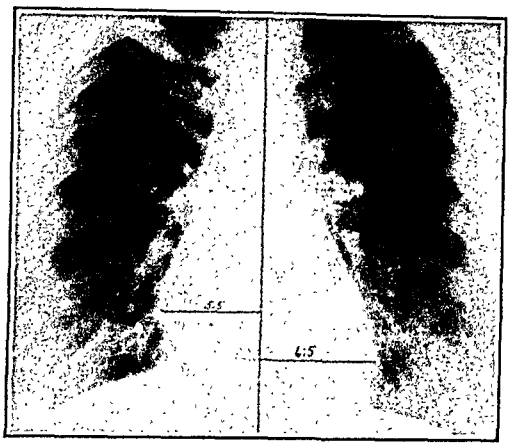

Fig. 6.—Film taken April 14, 1936, showing no passive congestion, and heart normal in size, shape, and position. Width of cardiac shadow is now 12 cm.

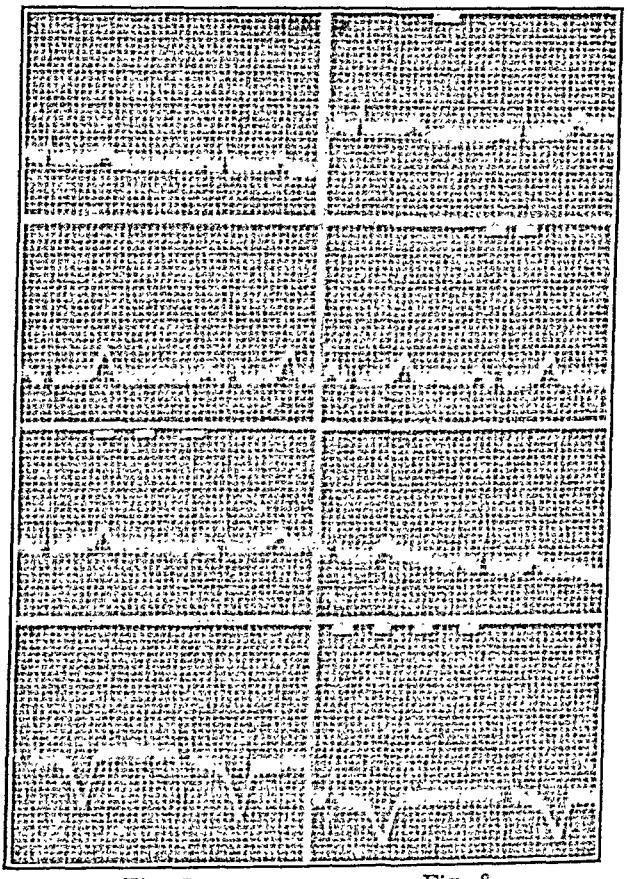

Fig. 7. Fig. 8.

Fig. 7.—Electrocardiogram taken April 14, 1936, showing normal tracing. Ventricular rate, 60.

Fig. 8.—Electrocardiogram taken April 29, 1936, showing normal tracing. Ventricular rate, 60.

From that day to the present (more than one year since all treatment was discontinued) the patient has lived an active life, involving the care of a home and

large social responsibilities, with no discomfort whatsoever. Her home is located on a hill, and she negotiates the climb without any difficulty. Repeated radiological and electrocardiographic examinations of her heart (Figs. 6, 7, 8) reveal normal findings. To ordinary physical examination and the usual tests for functional capacity, such as exercise and vital capacity determination, she always responds in a normal manner.

DISCUSSION

Auricular fibrillation is usually classified as persistent (or permanent) and paroxysmal (or transient). The former variety is regarded as the more serious and is more likely to be associated with grave organic heart disease. Clinically, the distinction between the two is based on the duration of the attack. Friedlander and Levine[2] regard an attack of fibrillation as persistent if it lasts longer than seven days, for it is assumed that if an attack lasts longer than seven days it is not likely to cease spontaneously. Parkinson and Campbell[1] in a series of 200 cases of paroxysmal fibrillation found that in only eight patients (4 per cent) one of the typical recurrent paroxysms lasted more than four days, and in only six of these were there attacks which lasted longer than one week. It seems, therefore, fair to classify the attack of fibrillation described above as belonging to the persistent variety; for it is definitely known that the heart was fibrillating on June 1, 1935, and from the available history, it appears highly probable that the attack began sometime in March, 1935.

The matter of etiology presents a more difficult problem. Although it is now well known that fibrillation of either variety may occur in an otherwise normal heart, the development in this case of severe congestive failure makes it necessary to consider every factor which is known to play a part in the genesis of this arrhythmia. Clinical and pathological studies by Frothingham,[5] Yater,[6] Cookson,[7] Brown,[8] Evans,[9] and others demonstrate that, while auricular fibrillation is not accompanied by specific or uniform pathological lesions, clinically the arrhythmia is most commonly associated with rheumatic valvular disease (especially mitral stenosis), hypertensive disease, and thyrotoxicosis. Peripheral arteriosclerosis and syphilis are much less important factors, and still less significant is coronary disease. An exception to the latter observation is the fairly common occurrence of transient fibrillation during the early course of acute coronary occlusion (Levine[10]).

A careful study of the case record under discussion furnishes convincing proof that the various clinicopathological conditions listed above, with which fibrillation is commonly associated, are not present in this instance. On the contrary, the evidence presented tends to establish the fact that apart from the fibrillation episode the heart in this case is apparently normal. This fact in itself is not unusual, since, as was shown by Parkinson and Campbell,[1] Friedlander and Levine,[2] and Orgain, Wolff and White,[4] between 6 and 15 per cent of all cases

of fibrillation are associated with hearts which are normal apart from the fibrillation. However, the extraordinary circumstance in this instance is the development of severe congestive failure, which is ordinarily regarded as indicative of grave organic heart disease. A comprehensive review of the literature yielded but one example comparable to this case. The instance referred to is that of Case 186 reported by Parkinson and Campbell.[1] Their patient was a man who "had tonsillitis as a child, but never acute rheumatism, or any serious illness. When twenty-three (1912) he awoke one morning with severe palpitation, breathlessness, and weakness. His doctor found nothing abnormal except the rapid irregular pulse, which he attributed to the strain of hunting, and kept him in bed for a month though the pulse was regular after two days. From 1913 to1918 he had only five more attacks, each lasting for some hours, and he was able to serve as a combatant officer in France. He remained well enough to lead a normal life until 1920 when fibrillation started again as he was running upstairs. A week later an EC showed fibrillation, with a ventricular rate of about 100. Fibrillation persisted, but there were no signs of failure, and he was able to get about with few restrictions. In 1922, after three days' fever (influenza?), he became very ill with heart failure. The ventricular rate was 180; he had Cheyne-Stokes breathing and seemed to be dying. With intravenous strophanthin he gradually improved and left his bed three weeks later. He continued to take digitalis, but was more or less an invalid, having to give up all sports. In 1925, in the fifth year of persistent fibrillation, he was treated with quinidine by Dr. Cotton and his heart became regular on the sixth day. In 1930, after another five years of normal rhythm, he wrote: 'I was soon able to resume my normal activities, and have continued hunting and playing tennis, hockey, and polo matches without any trouble whatever.' His present capacity for exertion and the absence of signs demonstrate that his heart is sound functionally; no doubt his dangerous illness in 1922 was due to a temporary general infection, but his condition at other times from 1920 to 1925 shows how much disability may be produced by fibrillation, apart from any other disease of the heart."

The significant point in this remarkable story is the fact that although he continued to take digitalis, this patient was practically an invalid for five years (from 1920 to 1925). But by means of quinidine, even after five years of persistent fibrillation, he was restored to apparently perfect health.

It seems quite probable that our patient, had she been treated with digitalis alone, might also have remained chronically incapacitated. Friedlander and Levine[2] have pointed out that in established fibrillation digitalis is practically never effective in restoring normal rhythm. There appears to be little reason to doubt that the small quantity of

quinidine administered to this patient was the *remedium magnum* in this case. This is worth emphasizing, since quinidine is considered (and rightly so) as being contraindicated, or at least without significant benefit, in the presence of serious organic heart disease (Kohn and Levine[11]); and congestive failure is usually regarded as signifying the presence of such cardiac pathology. The experience with this case illustrates the importance of seeking to establish in patients with fibrillation the presence or absence of organic heart disease, and of bearing in mind that congestive failure of even severe degree may develop in either instance and must not be regarded of itself as necessarily indicative of organic or structural change.

The onset of the arrhythmia in this case might have been related to the "sinus trouble" suffered by the patient in January, 1935. There was "slight fever" associated with that attack, and the patient frequently remarked that she had never felt quite well since that illness. "Infection" and "toxic" conditions were thought by Parkinson and Campbell[1] to have been possible etiological factors in 12 of their 30 patients with fibrillation and otherwise normal hearts. In the remaining 18 patients, there was no apparent cause. In a similar group of 35 patients studied by Friedlander and Levine[3] gastrointestinal disturbances, alcohol, and upper respiratory infections were deemed the inciting factors in 15 cases, but no ascribable cause was discernible in the remaining 20 patients. In the 49 cases reported by Orgain, Wolff, and White,[4] the onset of the arrhythmia in some of the patients appeared to "be related to pneumonia, malarial chill, pelvic abscess, alcohol, ether, burns, gallbladder colic, vomiting, surgical operation, exertion, and emotion." However, in many of the cases there were no definite etiological factors.

The rapid response of our patient to the single dose of 0.2 gm. of quinidine is not without example. Kohn and Levine[11] have pointed out that there was no constant ratio between the duration of the arrhythmia, the clinical condition of the patient, and the amount of quinidine necessary to produce a normal rhythm. They found 0.2 gm. of quinidine sufficient in one patient with moderate cardiac enlargement and congestive failure, in whom fibrillation was known to have existed for two and one-half months. In another patient whose arrhythmia was of but a few days' duration 10.5 gm. of the drug were required to restore normal rhythm.

PROGNOSIS

The outlook in patients with fibrillation without other evidence of heart disease appears quite favorable. The mortality from the arrhythmia or from subsequently developing cardiac disease is negligible.[1, 3, 4] This is in striking contrast to the grave prognosis held by patients with fibrillation and advanced organic heart disease. The

average duration of life in the latter is from two and one-half to seven years (Cookson[7] and Stroud, Laplace, and Reisinger[12]). It should be noted, however, that this grave outlook is governed chiefly by the underlying cardiovascular disease and is perhaps only slightly augmented by the presence of the arrhythmia.

SUMMARY

The report of a case is presented, with evidence tending to prove that auricular fibrillation in an otherwise normal heart may of itself cause severe congestive failure. Diagnosis, treatment and prognosis are discussed.

REFERENCES

1. Parkinson, J., and Campbell, M.: Paroxysmal Auricular Fibrillation: A Record of 200 Patients, Quart. J. Med. 23: 67, 1930.
2. Fowler, W. M., and Baldridge, C. W.: Auricular Fibrillation as the Only Manifestation of Heart Disease, Am. Heart J. 6: 183, 1930.
3. Friedlander, R. D., and Levine, S. A.: Auricular Fibrillation and Auricular Flutter Without Evidence of Organic Heart Disease, New England J. Med. 211: 624, 1934.
4. Orgain, Edward S., Wolff, Louis, and White, Paul D.: Uncomplicated Auricular Fibrillation and Auricular Flutter, Arch. Int. Med. 57: 493, 1936.
5. Frothingham, C.: The Auricles in Cases of Auricular Fibrillation, Arch. Int. Med. 36: 437, 1925.
6. Yater, W. M.: Pathologic Changes in Auricular Fibrillation and in Allied Arrhythmias, Arch. Int. Med. 43: 808, 1929.
7. Cookson, H.: The Etiology and Prognosis of Auricular Fibrillation, Quart. J. Med. 23: 309, 1930.
8. Brown, Morton G.: The Relationship of Coronary Arteriosclerosis to Auricular Fibrillation With Special Reference to the Term Arteriosclerotic Heart Disease, New England J. Med. 212: 963, 1935.
9. Evans, William A.: Long-Standing Cases of Auricular Fibrillation With Organic Heart Disease; Some Clinical Considerations, Ann. Int. Med. 9: 1171, 1936.
10. Levine, Samuel A.: Clinical Heart Disease, Philadelphia and London, 1936, W. B. Saunders Company.
11. Kohn, Cecil M., and Levine, Samuel A.: An Evaluation of the Use of Quinidine Sulphate in Persistent Auricular Fibrillation, Ann. Int. Med. 8: 923, 1935.
12. Stroud, W. D., Laplace, L. B., and Reisinger, J. A.: The Etiology, Prognosis, and Treatment of Auricular Fibrillation, Am. J. M. Sc. 183: 48, 1932.

THE USE OF CHEST LEADS IN CLINICAL ELECTROCARDIOGRAPHY

I. Normal Variations*

Eliot Sorsky, M.D.,† Fresno, Calif.
and
Paul Wood, M.B.(Melb.), M.R.C.P.(London),‡ London, England

In 1932 Wolferth and Wood[1, 2] reintroduced chest leads as an adjunct to the three standard leads in clinical electrocardiography. They claimed that additional information could thereby be gained in certain cases. In America and on the continent this revival was followed by many enthusiastic reports, some of which have been sharply criticized by Roth[3] in a recent review of the subject. There is still lack of agreement as to which chest leads yield the most information, as to the limits of normal variation of electrocardiograms obtained with these leads, and indeed as to the value of chest leads at all. It was with the hope of clarifying these three points that the present work was undertaken.

It has been shown[4, 5, 6] that, when one electrode (the exploring electrode) is applied over the anterior chest wall in the region overlying the heart, differences of electrical potential arising within the heart may be recorded, which differences are but little influenced by the position of the other electrode (the indifferent electrode). Wolferth and Wood[1] originally placed their exploring electrode over the apex beat, and their indifferent electrode over the posterior chest wall medial to the angle of the left scapula. They called this Lead IV. In Lead V they shifted the indifferent electrode to the left leg. Subsequent investigators have noted no important differences between these two leads, and Lead V has the advantage of greater simplicity. Different electrocardiograms are obtained, however, if the exploring electrode is shifted to the right of the apex beat, and we therefore decided to confine our attention to the exploring electrode, fixing the indifferent electrode to the left leg or to the right arm.

The procedure was simple. After recording the three standard leads, the left arm electrode was transferred to the apex beat and was coupled first with the right arm and then with the left leg. The exploring electrode was then moved to a point midway between the apex beat and the midline at the level of the fourth intercostal space and subsequently over the right border of the sternum at the same

*From the Department of Medicine, British Postgraduate Medical School, Hammersmith Hospital.
†From Fresno County Hospital.
‡First Assistant, British Postgraduate Medical School, Hammersmith Hospital.

level, on each occasion being coupled first with the right arm and then with the left leg. Thus nine leads were employed with each subject, three standard leads and six chest leads.

In a later paper the clinical value of each of these leads will be discussed on the basis of a series of pathological subjects; the present report deals only with the presentation of the limits of normal variation of electrocardiograms obtained with these leads in 150 normal individuals.

Small silver electrodes, measuring 2 by 1½ inches, were used, and skin resistance was reduced by means of a special paste. All records were obtained with the Standard Cambridge Electrocardiograph, the subjects being placed in the recumbent position, and the usual standard calibration being employed.

TABLE I

ANALYSIS OF 114 NORMAL CONTROLS—STANDARD LEADS

LEAD	P-WAVE HEIGHT (MM.)	P-WAVE DURATION (SEC.)	P-R (SEC.)	Q (MM.)	R (MM.)	S (MM.)	QRS DURATION (SEC.)	T (MM.)	S-T DURATION (SEC.)
Lead I									
Average	0.9	0.075	0.15	1.0	6.8	2.5	0.07	2.8	0.28
Maximum	2.0	0.1	0.21	3.0	17.0	7.0	0.09	4.0	0.36
Minimum	0.3	—	0.10	0.5	2.0	0.5	0.04	1.0	0.20
Absent	2			53		14			
Lead II									
Average	1.3	0.08	0.16	1.1	11.5	2.5	0.075	3.3	0.29
Maximum	3.0	0.10	0.22	2.5	22.0	10.0	0.10	8.5	0.37
Minimum	0.5	—	0.12	0.4	4.0	0.5	0.05	1.0	0.24
Absent	4			55		16			
Lead III									
Average	+0.8 -0.6	0.07	0.155	2.1	7.4	2.2	0.07	+1.3 -1.1	0.28
Maximum	+1.5 -1.0	0.09	0.22	2.5	18.0	6.0	0.10	+3.0 -2.0	0.33
Minimum	—	0.10	—	0.5	1.5	0.5	0.04	—	0.22
Absent				59	1	48			

In Lead III:	*Positive*	*Negative*	*Biphasic*	*Isoelectric*
P-wave	71	12	7	24
T-wave	77	15	1	21

RESULTS

The investigation was carried out upon 150 normal subjects ranging in age between five and seventy years, there being 100 children under sixteen years of age and 50 adults. There were 129 males and 21 females. The electrocardiograms obtained with the standard leads were within the accepted limits of normal variation. Eleven showed slight axis deviation, ten left and one right. Slight slurring or notching of QRS was common at the base and in the lead of lowest voltage,

TABLE II

ANALYSIS OF CHEST LEADS FROM 114 NORMAL SUBJECTS

LEAD	P-WAVE HEIGHT (MM.)	P-WAVE DURATION (SEC.)	P-R (SEC.)	Q (MM.)	R (MM.)	S (MM.)	QRS (SEC.)	T (MM.)	S-T (SEC.)	RS-T TAKE-OFF ELEV. (MM.)	RS-T TAKE-OFF DEP. (MM.)	RS-T TAKE-OFF ISO.
Apex—right arm lead												
Average	1.4	0.08	0.17	1.5	15.8	7.4	0.07	6.9	0.29	0.8	0.7	
Maximum	2.5	0.1	0.22	5.0	23.0	17.0	0.10	14.0	0.36	2.0	1.0	
Minimum	—	—	0.10	0.5	1.5	2.0	0.05	3.0	0.24	—	—	
Present	113			25	114	114				47	4	63
Apex—left leg lead												
Average	+0.6 −0.6	0.05	0.15	10.5	8.7	0.5	0.07	−4.0	0.29	0.6	0.7	
Maximum	+1.0 −2.0	0.08	0.22	18.0	17.0	0.5	0.1	−15.0	0.34	1.0	1.2	
Minimum	—	—	0.08	2.0	1.0	0.5	0.05	−0.5	0.24	—	—	
Present	23+ 49− 8±			114	114	2				5	34	75
Left pectoral—right arm lead												
Average	0.8	0.08	0.16	1.2	11.3	9.8	0.08	5.2	0.29	0.8	0.7	
Maximum	2.0	0.12	0.22	1.5	25.0	17.0	0.10	15.0	0.35	2.0	1.0	
Minimum	0.5	—	0.10	1.0	2.0	4.0	0.06	2.0	0.24	—	0.5	
Present	114			2	114	114				61	0	53
Left pectoral—left leg lead												
Average	+0.8 −0.5	0.05	0.16	6.4	11.8	0.7	0.08	−2.8 +1.8	0.28	0.6	0.7	
Maximum	+2.0 −1.0	0.08	0.22	15.0	20.0	1.0	0.10	−14.0 +3.5	0.34	1.0	2.0	
Minimum	—	—	0.08	1.0	4.0	0.5	0.06	—	0.22	—	—	
Present	20+ 55− 15± 24 iso.			114	114	2		13+ 85− 16±		0	53	61
Right pectoral—right arm lead												
Average	1.2	0.08	0.16	—	7.5	9.2	0.08	3.0	0.28	0.7	0.3	
Maximum	2.0	0.10	0.22	—	17.0	18.0	0.10	8.0	0.35	2.0	0.3	
Minimum	0.2	—	0.10	—	1.0	2.0	0.06	0.5	0.24			
Present	114			0	114	114				46	0	68
Right pectoral—left leg lead												
Average	+0.9 −0.6	0.05	0.16	4.7	12.4	1.0	0.08	−2.0 −2.0	0.28	1.2	0.6	
Maximum	+1.5 −1.0	0.08	0.22	11.0	25.0	1.0	0.10	+3.5 −5.0	0.32	2.0	1.5	
Minimum	—	—	0.08	0.5	0.8	—	0.06	—	0.22	0.5	—	
Present	14+ 59− 22± 0 iso.			114	114	2		51+ 35− 23± 2 iso.		0	42	79

but occurred only once at or near the apex of the maximum QRS deflection. M or W complexes were seen 16 times in Lead III but did not occur in other leads. A more exact analysis of 114 of the cases is presented in Table I.

An analysis of the records obtained with the six chest leads upon the same 114 cases is presented in Table II. No electrocardiograms were rejected because their deflections failed to fall within the limits of normal as given by other authors.[1, 5, 7-13]

We agree with these authors that for the apex-left leg lead (the electrodes being arranged so that relative negativity of the exploring electrode gives an upward deflection on the electrocardiogram) the common appearances include (Fig. 1).

1. A very small frequently inverted P-wave.
2. A prominent Q-wave.
3. A biphasic QR complex with no S-wave.
4. A large sharply inverted T-wave.

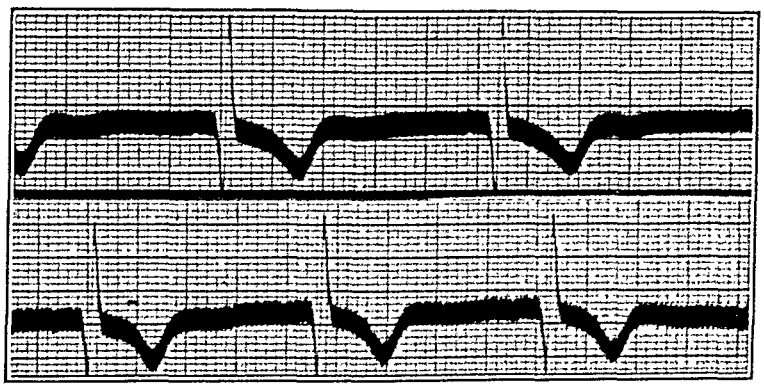

Fig. 1.—Common appearances of apex—left leg leads.

We do not agree with certain authors[8, 9, 10] in respect to the criteria which they have laid down as evidence of abnormality. If chest lead electrocardiography is to be of help, it is essential to appreciate the variations of normal. For this reason we have deemed it wise to deal with some of these criteria in detail.

A. An Upright P-Wave.—Table III shows that an upright P-wave is common.

TABLE III

P-WAVE IN 114 NORMAL CONTROLS

LEAD	POSITIVE	NEGATIVE	BIPHASIC	ISOELECTRIC
Apex—left leg	23	49	8	34
Left pectoral—left leg	20	55	15	24
Right pectoral—left leg	14	59	32	9

In the right arm coupled leads the P-wave was always upright. It is worth noting that P never exceeded 2.5 mm. in height in any lead. The right pectoral lead has been called the auricular lead. This

is presumably because, in certain cases of mitral stenosis the P-waves, and in certain cases of auricular fibrillation the *f*-waves, are unusually large in this lead; but they are not large in normal controls.

B. A Very Small Q-Wave or Nearly Monophasic QRS Complex[10] (Figs. 2 and 3).—Our minimum normal Q-wave was 2 mm. in depth in the apex—left leg lead, and was 1 mm. in depth in the left pectoral —left leg lead. When the main QRS deflection was downward, our minimum upward deflection was 1 mm. in height. It would therefore appear wiser to consider abnormal only an absolutely monophasic de-

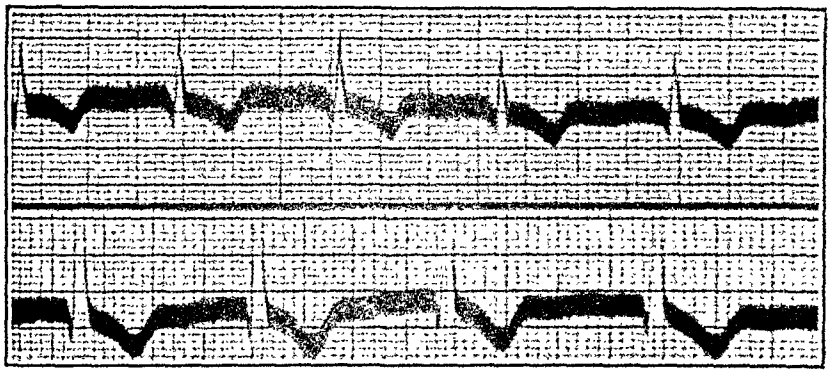

Fig. 2.—Apex—left leg leads. Note small Q-waves.

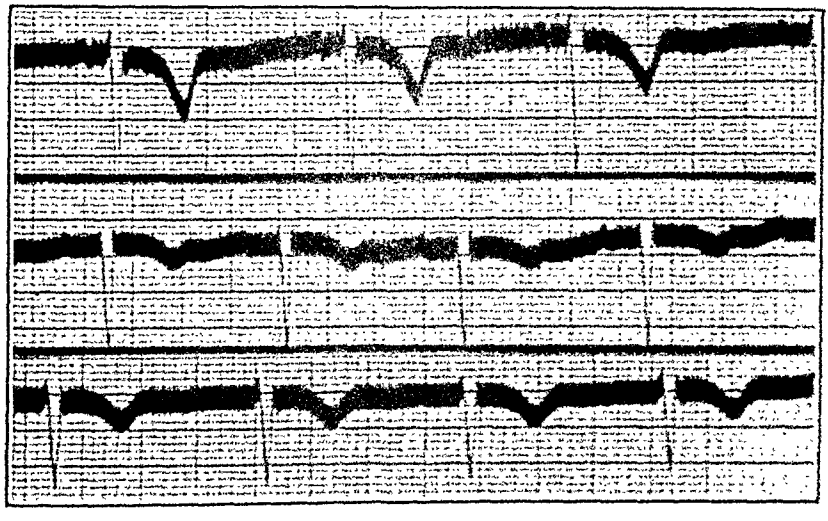

Fig. 3.—Apex—left leg leads. Almost monophasic downward deflections.

flection which did not occur once in our series of 150 cases, nor in any other series of normal controls reported.

C. Notching of the QRS Complex[5, 7, 8] (Fig. 4).—We agree with Shipley and Hallaran,[12] and with Master and his coworkers[13] that this is a normal variation. In our series of 150 controls, notching, which did not include slurring, occurred in one or more leads in 52 subjects, or in 34 per cent, and bore no relationship to notching in the standard leads. Its incidence in the various leads is given in Table IV.

TABLE IV

LEAD

DEFLECTION NOTCHED	APEX—R. ARM	APEX—L. LEG	L. PECT.—R. ARM	L. PECT.—L. LEG	R. PECT.—R. ARM	R. PECT.—L. LEG
Q	0	10	0	9	0	1
R	1	4	1	14	4	18
S	0	0	1	0	3	0

D. M or W Complexes.[10]—Again we agree with Shipley and Hallaran,[13] and with Master and his coworkers[15] that these are not uncommon normal variations. These writers described a small initial

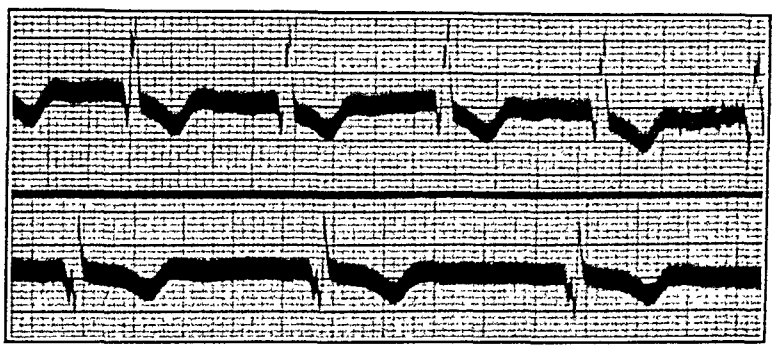

Fig. 4.—Notching in apex—left leg leads.

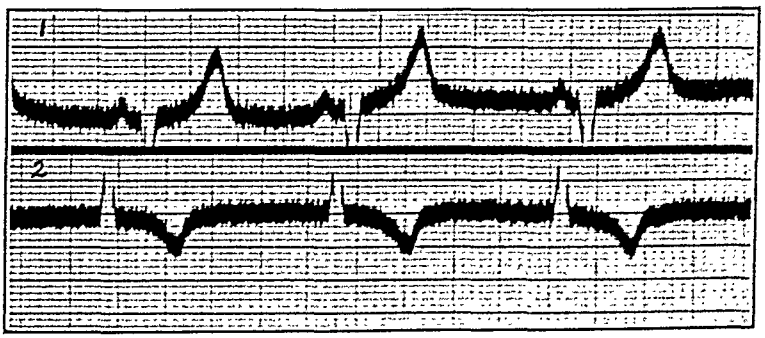

Fig. 5.—*1*, Apex—right arm lead, initial downward deflection; *2*, apex—left leg lead, initial upward deflection.

upward deflection preceding what would otherwise have been a normal Q-wave in the apex—left leg lead. We found this extra deflection in 20 out of 150 cases in the apex—left leg lead and its counterpart, an initial downward deflection, in 30 out of 150 cases in the apex—right arm lead. In the other leads it was rare. An example of this extra deflection is shown in Fig. 5.

E. Elevation of the R-T Segment[8, 9, 10] (Fig. 6).—There have been frequent allusions to the normal depression of the R-T segment in the apex—left leg lead, the limit of which has been drawn at 2 mm. Elevation of any degree has been considered abnormal. By means of

a special electrode paste we were able to reduce skin resistance sufficiently to ensure a tight string so that overshooting was avoided. With this technic 66 per cent of our 114 analyzed cases showed an isoelectric R-T take-off in the apex—left leg lead, and in another 18 per cent the depression measured only 0.5 mm. from the isoelectric line. Depression of more than 1 mm. occurred in only one case in this lead. The findings in the other leads are tabulated below.

Slight elevation of the R-T take-off in the apex—left leg lead was found in five cases, or in 4.4 per cent. It amounted to more than 0.5 mm. in only one instance when it measured 1 mm. In standard Lead II slight elevation of the S-T take-off was found in 6 per cent of 150 cases and measured 0.5 mm. in all but one, in which it was 1 mm. In standard Leads I and III deviation of the S-T take-off was a little less frequent, and in all three leads elevation was more common than depression.

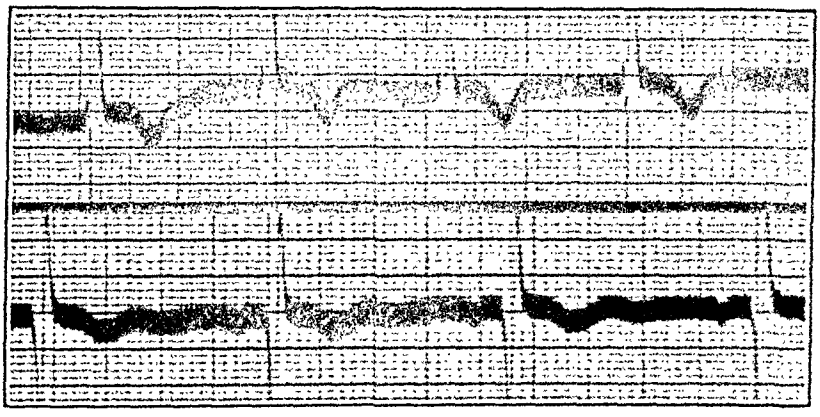

Fig. 6.—Apex—left leg leads. Slight elevation of the R-T take-off.

TABLE V

R-T OR S-T TAKE-OFF (114 CONTROLS)

DEVIATION FROM THE ISOELECTRIC LINE	LEAD					
	APEX—R. ARM (ELEV.)	APEX—L. LEG (DEP.)	L. PECT.—R. ARM (ELEV.)	L. PECT.—L. LEG (DEP.)	R. PECT.—R. ARM (ELEV.)	R. PECT.—L. LEG (DEP.)
nil	63	75	53	61	68	70
0.5 mm.	15	21	25	30	22	31
1.0 mm.	28	12	33	24	24	13
1.5 mm.	2	0	1	1	1	0
2.0 mm.	2	1	2	1	2	0

NOTE.—Four cases in the apex—right arm lead showed slight depression. Five cases in the apex—left leg lead showed slight elevation.

F. T-Wave of Greater Amplitude Than 9 mm.[5, 9, 10] (Fig. 7).—Our maximum T-wave measured 15 mm. in amplitude, and there were several over 10 mm. There was no reason to suppose that these large T-waves were abnormal.

G. Biphasic or Isoelectric T-Waves.[10]—Before considering the normal variations of the T-wave in chest-lead electrocardiograms, it is necessary to understand the effects produced by shifting the exploring electrode. The effect upon the QR complex has been noted by Hoffman

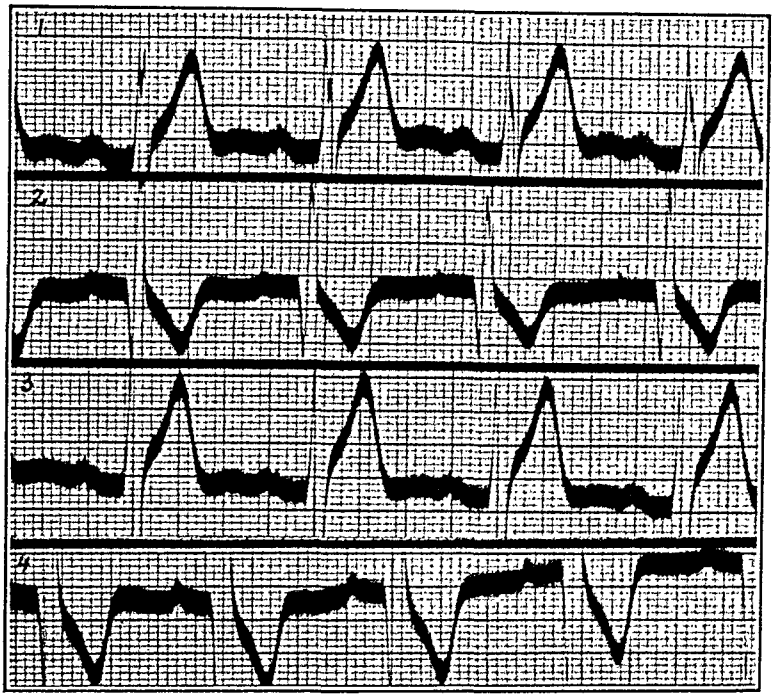

Fig. 7.—Large T-waves. *1*, Apex—right arm lead; *2*, apex—left leg lead; *3*, left pectoral—right arm lead; and *4*, left pectoral—left leg lead.

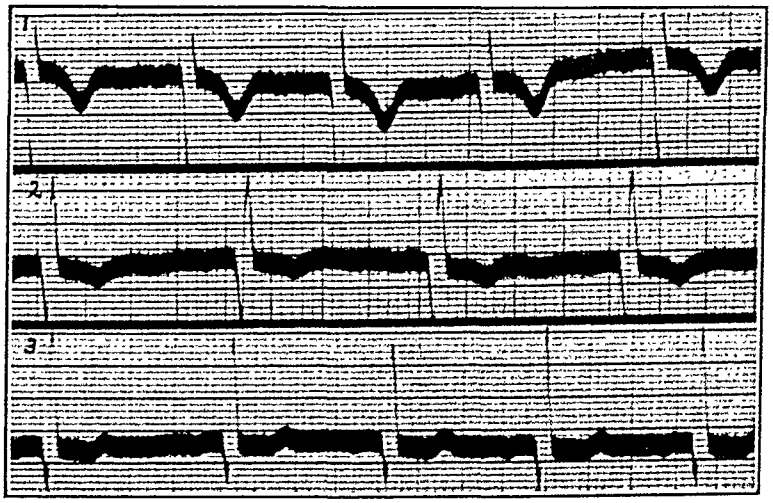

Fig. 8.—Showing the effect of shifting the exploring electrode. *1*, Apex—left leg lead; *2*, left pectoral—left leg lead; and *3*, right pectoral—left leg lead.

and Delong,[6] by Shipley and Hallaran,[13] by Kossmann and Johnston,[16] and others. In the majority of instances it is found that, in a normal subject with the electrodes arranged so that relative negativity of the exploring electrode results in an upright deflection on the electro-

cardiogram, a lead taken from some point overlying the heart yields a truly biphasic QR complex with Q equal to R in amplitude, and that, within certain limits, shifting the exploring electrode to the right results in a relatively smaller Q and in a relatively larger R-wave, whereas shifting it to the left has the opposite effect (Fig. 8).

From a clinical point of view a more important effect of this shift is the alteration in size, shape, and direction of the T-wave[15] (Fig. 8). Table VI illustrates this effect in 86 normal children between eight and sixteen years old and in 50 normal adults.

It may be seen that in no instance was the T-wave upright in the apex—left leg lead, although it was biphasic in six children. On shifting the exploring electrode to the right, the T-wave tended to

Fig. 9.—1, Apex—left leg lead; *2*, left pectoral—left leg lead; and *3*, right pectoral—left leg lead. T biphasic in apex—left leg lead.

become upright; thus in the left pectoral lead it was biphasic in 18 per cent and was upright in 21 per cent of the children and in two slim young female adults; and in the right pectoral lead it was upright in 65 per cent of the children and in 58 per cent of the adults.

TABLE VI*

LEAD	DIRECTION OF THE T-WAVE		
	INVERTED	BIPHASIC	UPRIGHT
86 Normal Children			
Apex—left leg	80	6	nil
Left pectoral—left leg	52	16	18
Right pectoral—left leg	20	10	56
50 Normal Adults			
Apex—left leg	50	nil	nil
Left pectoral—left leg	48	nil	2
Right pectoral—left leg	17	4	29

*Figs. 9 to 12 show the possible combinations of upright and inverted T-waves in the three left leg coupled leads.

If the T-wave showed any tendency to become upright in one lead, it was invariably more upright on shifting the exploring electrode to the right. These findings agree fairly well with those of Rosenblum and Sampson,[12] who noted an upright T-wave in 34 out of 50 normal children between the ages of one month and sixteen years, for these authors placed their exploring electrode at the left border of the sternum.

It is well known that inversion of the T-wave in the third standard lead is often associated with a horizontal position of the heart consequent upon a high diaphragm. In view of this we decided to determine if the position of the heart in relation to the thorax was in any way related to the behavior of the T-wave in chest lead electrocardiograms. For this purpose a group of 86 schoolboys was studied. Of these, 72 were selected for fluoroscopy and were divided into three groups according to their electrocardiograms. In Group 1 there were 18 boys in whom the T-wave was upright in both left and right pectoral—left leg leads; in Group 2 there were 36 in whom T was upright only in the right pectoral lead; and in Group 3 there were 18 in whom T remained inverted in the right pectoral lead. Obviously the radiological appearances of all these hearts were within the limits of normal variation and an estimation of their relative sizes and shapes was entirely a question of judgment. Of 5 pendulous hearts none were seen in Group 3; of 7 hearts characterized by an exaggeration of the pulmonary arc, none occurred in Group 3, whereas 4 were from Group 1; in contrast, of nine transverse hearts associated with a high diaphragm, 5 were from Group 3; and of 13 relatively large hearts, 6 occurred in Group 3 against only 2 from Group 1. Thus in Group 3, 10 out of 18 had either relatively large hearts or transverse hearts associated with a high diaphragm, as compared with four out of eighteen in Group 1. If any conclusions can be drawn from these findings, it would appear that an upright T-wave in the left pectoral—left leg lead tends to be associated with small or with pendulous hearts, or with hearts characterized by an exaggeration of the pulmonary arc, whereas a T-wave which remains inverted in the right pectoral—left leg lead tends to be associated with relatively large hearts or with transverse hearts associated with a high diaphragm. If this be true, then T should be inverted in the right pectoral—left leg lead in cases of hypertensive heart disease and of aortic valvular disease, and it should be upright in the left pectoral—left leg lead in cases of mitral stenosis and of heart disease secondary to emphysema. So far as our investigations have proceeded in pathological subjects, this rather appears to be the case.

The configuration of the chest was also studied in the group of 86 schoolboys. Anteroposterior and lateral external measurements were obtained by means of obstetrical calipers; the subcostal angle was

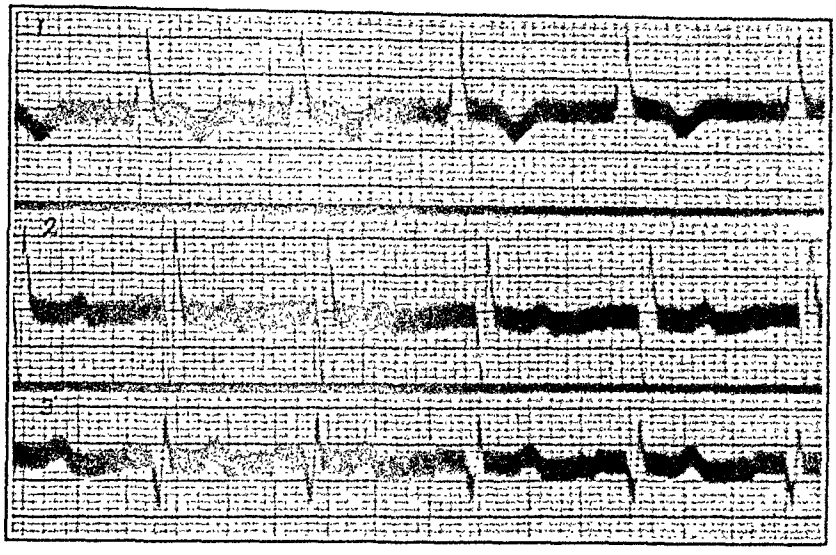

Fig. 10.—*1*, Apex—left leg lead; *2*, left pectoral—left leg lead; and *3*, right pectoral—left leg lead. T upright in left pectoral—left leg lead but inverted in the apical lead.

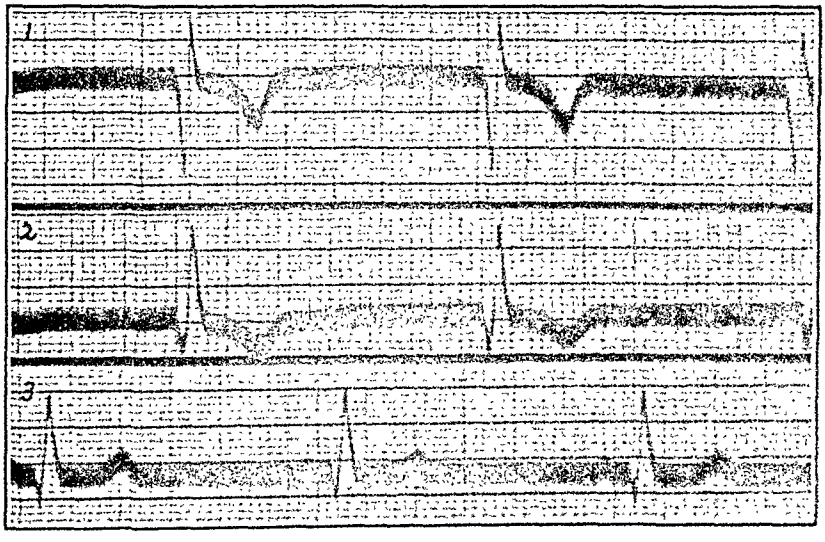

Fig. 11.—*1*, Apex—left leg lead; *2*, left pectoral—left leg lead; and *3*, right pectoral—left leg lead. T upright only in the right pectoral lead.

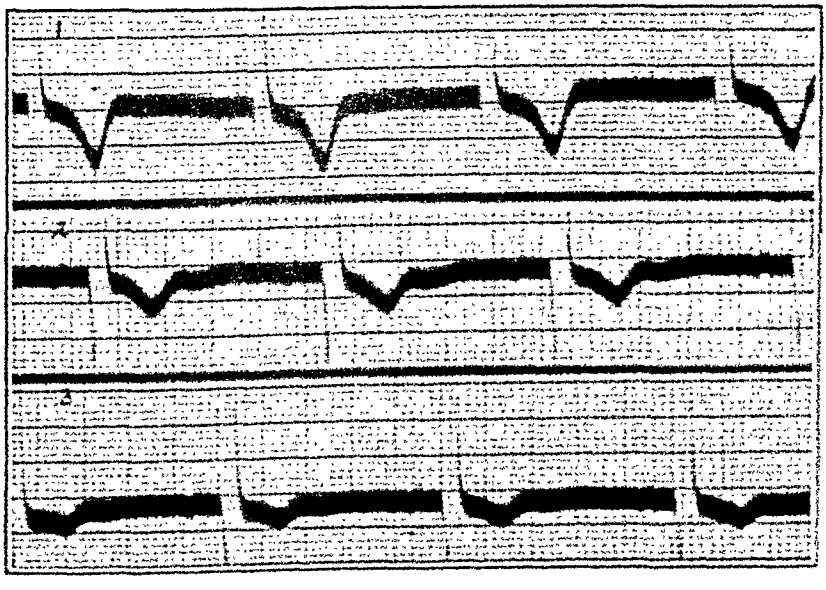

Fig. 12.—T inverted in all three leads. *1*, Apex—left leg lead; *2*, left pectoral—left leg lead; and *3*, right pectoral—left leg lead.

measured; the length of the thorax was better gauged by means of x-ray films; the height and weight of each boy were measured. The results permitted a certain grouping, and an attempt was made to ascertain if any particular group or combination of groups showed a similar behavior of the T-wave in the chest lead electrocardiogram. Apart from the fact that the three fattest boys showed an inverted T-wave in the right pectoral—left leg and that no slim boys showed this, no correlation could be found.

We may now consider the normal variations of the T-wave in chest lead electrocardiograms. We agree that an upright T-wave is abnormal in the apex—left leg lead in subjects over eight years of age, but in leads internal to the apex beat upright or diphasic T-waves are common normal variations, particularly in children under sixteen years of age. Before interpreting an upright T-wave as evidence of abnormality it is necessary to check the position of the exploring electrode.

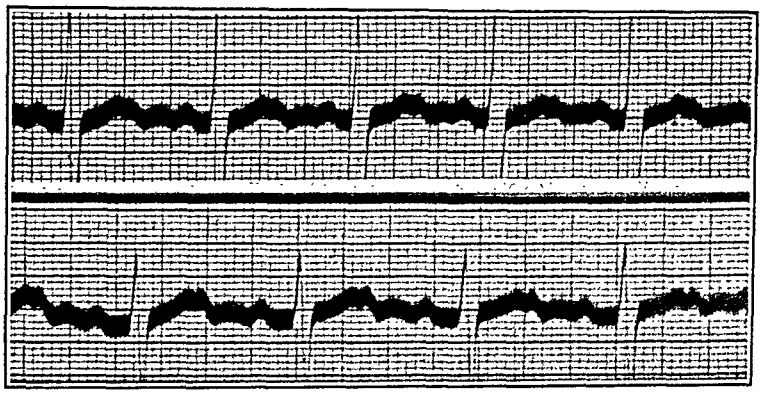

Fig. 13.—Bifid T-wave. Right arm—left pectoral leads.

There are two other points about the T-wave: first, from its point of origin the S-T or R-T segment ran almost immediately into the upright or inverted T-wave when this was large, but in other instances there was an appreciable isoelectric interval. Second, the T-wave was bifid in 15 records, usually in the left pectoral—right arm lead (Fig. 13).

SERIAL CHEST LEAD ELECTROCARDIOGRAMS

It follows from what has been said that in chest lead electrocardiography no two records are comparable unless the exploring electrode is in exactly the same position on both occasions. Levy and Bruenn[8, 9] have found serial chest lead electrocardiograms useful in following the activity of cases of rheumatic carditis, and they state, "By far the most frequently observed changes in Lead IV were alterations in the direction or voltage of the T-wave." Now these are just the changes which occur on slight shift of the exploring electrode which in their cases was placed close to the left border of the sternum, and

we should place no reliance on such changes unless some means were adopted whereby the position of the exploring electrode relative to the underlying heart could be exactly controlled, for more than due care is needed.

RIGHT ARM COUPLED LEADS

For the most part, the electrocardiograms obtained when the exploring electrode was coupled with the right arm were the reverse of those obtained with the left leg, being due to simple reversal of current through the galvanometer. This applied most strictly to apical leads but did not hold for the right pectoral leads. Now when the left arm electrode is used for the exploring electrode, the object in coupling it with the right arm electrode is to turn the QR complex into the more familiar RS complex and to bring the T-wave upright. Wolferth and Wood thought that this was optional, and Lieberson and Liberson preferred the more familiar appearances. It seems to us, however, that it is advantageous to be able to recognize a chest lead electrocardiogram at a glance and that therefore we should adhere to the more correct arrangement of Wolferth and Wood in which the connections are such that relative negativity of the exploring electrode yields an upward deflection on the electrocardiogram.

DURATION OF DEFLECTIONS

Reference to Tables I and II shows that the time limits adopted for the duration of the various phases of the standard lead electrocardiogram hold good for the respective phases of the chest lead electrocardiogram. The average duration of QRS, however, is slightly longer in the latter.

PRESENTATION OF NORMAL APPEARANCES

In conclusion we would represent the appearances of the chest lead electrocardiogram, with the leads arranged so that relative negativity of the exploring electrode produces an upward deflection on the record, as follows:

1. A small, frequently inverted P-wave, which may however be upright, biphasic, or isoelectric.

2. A biphasic QR complex which may be nearly all Q or nearly all R according to the position of the exploring electrode. An extra initial upward deflection may sometimes occur. Notching or slurring of any portion of the waves is common.

3. The R-T take-off is usually isoelectric but may be depressed to a maximum of 2 mm., or rarely may be slightly elevated.

4. There is commonly no appreciable isoelectric period of the R-T component unless the T-wave is small, biphasic, or upright.

5. The T-wave is usually sharply inverted and of considerable amplitude. Under certain conditions, especially in children, it may be upright or biphasic, according to the position of the exploring electrode.

6. Within certain limits shift of the exploring electrode to the right yields a relatively smaller Q-wave, a relatively larger R-wave, and a less inverted T-wave; shift of the exploring electrode to the left has the opposite effect.

SUMMARY

1. The normal appearances of chest lead electrocardiograms have been described from material recorded from 150 normal subjects. There were 50 adults and 100 children.

2. Particular attention has been paid to the position of the exploring electrode. The indifferent electrode was fixed to the right arm or to the left leg.

3. The changes which occur in the QR component as the exploring electrode is shifted from the apex beat to the right have been confirmed; more striking may be the change in the direction of the T-wave.

4. In view of the difficulty of fixing the exploring electrode in a constant position in relation to the underlying heart, great caution must be exercised in the interpretation of serial chest lead electrocardiograms.

5. An attempt was made to find some factor which might influence the direction of the T-wave when the exploring electrode was placed internal to the apex beat.

6. Certain criteria which have been supposed to denote abnormality have been criticized on the grounds that these may be normal variations.

NOTE.—No reference is made to the recent study by Drs. Robinow, Katz and Bohning (The Appearance of the T-Wave in Lead IV in Normal Children and in Children with Rheumatic Heart Disease, AM. HEART J. 12: 88, 1936) because that paper was published after the present study had been completed.

REFERENCES

1. Wolferth, C. C., and Wood, F. C.: Am. J. M. Sc. 183: 30, 1932.
2. Idem: M. Clin. North America 16: 161, 1932.
3. Roth, I. R.: AM. HEART J. 10: 798, 1935.
4. Wilson, F. N.: AM. HEART J. 5: 599, 1930.
5. Master, A. M.: AM. HEART J. 9: 511, 1934.
6. Hoffman, A. M., and Delong, E.: Arch. Int. Med. 51: 947, 1933.
7. Katz, L. N., and Kissin, M.: AM. HEART J. 8: 595, 1933.
8. Levy, R. L., and Bruenn, H. G.: Proc. Soc. Exper. Biol. & Med. 32: 559, 1934.
9. Idem: AM. HEART J. 10: 881, 1935.
10. Bohning, A., and Katz, L. N.: Am. J. M. Sc. 189: 833, 1935.
11. Goldbloom, A. A.: Am. J. M. Sc. 187: 489, 1934.
12. Rosenblum, H., and Sampson, J. J.: AM. HEART J. 11: 49, 1936.
13. Shipley, R. A., and Hallaran, W. R.: AM. HEART J. 11: 325, 1936.
14. Lieberson, A., and Liberson, F.: Ann. Int. Med. 6: 1315, 1933.
15. Master, A. M., Dack, S., and Jaffe, H. L.: Proc. Soc. Exper. Biol. & Med. 32: 1529, 1935.
16. Kossmann, C. E., and Johnston, F. D.: AM. HEART J. 10: 925, 1935.

HEART DISEASE AMONG SEAMEN*

H. Arenberg, M.D.
Ellis Island, N. Y.

About a million alien seamen enter and leave the ports of the United States yearly; one-half of them pass through the port of New York. It is estimated that together with foreign and American merchant seamen there are as many as 20,000 seamen in the port of New York on an average day, coming and going to and from all parts of the world.[1] The greater part of all medical care of seamen ill in our ports is rendered by the United States Public Health Service through the Marine Hospitals which are situated at all important ports. There are as many as 3,000 admissions to the Marine Hospital at Ellis Island yearly and about as many to the Marine Hospital at Staten Island, while tens of thousands are treated yearly at the out-patient Marine Hospital at Hudson Street.

Heart disease is the leading cause of death among seamen, as it is among other groups of the population.[2] By their mode of life, economic status, strenuous occupation, habits, sex life, and geographic distribution, seamen make up a unique group for the etiologic study of heart disease. No other group presents such a diversification of known and theoretical factors in the etiology of heart disease. Any comparatively small group presents almost a complete cross-section of the population of the world. Syphilis, which is an important factor in heart disease, is probably more prevalent among seamen than any other group in this hospital.[3] Alcohol and tobacco, though not definitely established as etiologic agents in arteriosclerosis and hypertension, are at least theoretically considered as such by many.[4] More than 90 per cent of seamen smoke, many of them excessively, and more than 50 per cent of them are heavy drinkers, as observed in this hospital. If any of the above factors are at all influential in the etiology of cardiovascular disease, they are present here in abundance.

This study is based on a clinical investigation of 485 cases, including 50 autopsies, selected from over 5,000 seamen patients who had been subjected to a special cardiovascular examination regardless of the ailments for which they were admitted to the hospital. In almost every instance either a fluoroscopic examination or an x-ray film of the heart was made, and at least one electrocardiogram was taken. There were only 5 females. There were 45 colored males and 435 white males. Forty-one per cent of the group were native Americans, representing almost every state in the Union, and 59 per cent were foreign, coming from all parts of the world (Table I).

*From the United States Public Health Service.

TABLE I

ETIOLOGIC CLASSIFICATION BY NATIONALITY

NATIVITY	HYPER-TENSIVE	RHEU-MATIC	ATHERO-SCLEROTIC	SYPH-ILITIC	MISCEL-LANEOUS	TOTAL
Australia	-	-	1	-	-	1
Austria	2	1	2	1	-	6
Argentina	1	-	-	-	-	1
Belgium	1	-	-	-	-	1
British West Indies	8	2	1	1	-	12
Canada	1	-	2	1	3	7
Cape Verde Islands	1	-	-	1	-	2
Chile	-	-	-	-	1	1
China	1	-	-	-	-	1
Cuba	-	1	-	-	-	1
Denmark	4	1	-	-	1	6
Dutch West Indies	2	1	1	1	-	5
England	13	4	8	2	2	29
Esthonia	-	1	1	1	-	3
Finland	-	1	2	-	-	3
France	2	-	1	-	-	3
Germany	18	2	6	4	1	31
Greece	8	1	1	3	-	13
Holland	1	1	1	2	1	6
Hungary	1	-	-	-	-	1
Ireland	8	2	5	1	1	17
Italy	7	6	4	2	1	20
Jamaica	1	-	-	-	-	1
Jugoslavia	2	1	-	1	-	4
Korea	-	1	-	-	-	1
Malta	1	-	-	-	-	1
Newfoundland	2	1	1	-	-	3
Norway	9	3	6	4	2	24
Palestine	-	-	-	1	-	1
Panama	1	-	-	1	-	2
Peru	1	-	-	-	-	1
Philippine Islands	-	1	1	-	1	3
Poland	3	4	-	1	1	9
Puerto Rico	1	2	-	3	2	8
Portugal	4	-	-	-	-	4
Roumania	2	-	-	2	-	4
Russia	1	2	-	-	2	5
Salvador	-	-	1	1	-	2
Santo Domingo	-	1	-	-	-	1
Singapore	-	-	-	-	1	1
Spain	4	2	2	2	1	11
Sweden	7	4	7	2	-	20
Syria	1	1	-	-	-	2
Turkey	1	-	-	-	-	1
Virgin Islands	2	-	-	-	-	2
Venezuela	1	-	-	-	-	1
United States	79	56	34	19	15	203
Total	201	102	88	57	36	485

Out of 485 patients 130, or 26 per cent, had active or latent syphilis; 44 per cent of these had cardiovascular syphilis. The prevalence of syphilis among the colored cardiac patients was 57 per cent and among the white cardiac patients 23.6 per cent. All patients in this study were adults ranging in age from nineteen to seventy-six years.

HYPERTENSIVE GROUP

The hypertensive group was the largest. Included in this group were those only in whom cardiac hypertrophy was demonstrated by x-ray film or fluoroscopic examination in addition to the presence of or history of hypertension. There were 202 patients, or 41.6 per cent, in this group: 21 were colored and 181 were white. Only 37 per cent were Americans. About 25 per cent were asymptomatic when first examined, and 14 per cent had either latent or active syphilis, while 26 out of 202 had coronary disease complications.

The age extremes were twenty-nine and seventy-six years, with the greatest number in the fifth and sixth decades of life.

RHEUMATIC GROUP

In this group there were 102, or 21.3 per cent; 55 per cent were Americans, in comparison with 37 per cent among the hypertensive group, and 41 per cent of the total number. There were 9 colored and 93 whites. The foreign group represented 24 different countries. Only a small number were from the tropical or subtropical regions, while 50 of 56 Americans were from the northeastern states. Sixty-nine had histories of rheumatic fever, and 11, histories of chorea.

The age extremes were nineteen and sixty-two years, the average age being thirty-five years, and the greatest number being in the third and fourth decades of life. There were 27 asymptomatic patients in this group, and 21 had latent or active syphilis, while 23 had auricular fibrillation.

ATHEROSCLEROTIC GROUP

In this group were included all cases of coronary disease, coronary thrombosis, myocardial damage, sclerosis of the aortic valve, and nonsyphilitic aneurysm. There were 88, or 18 per cent, in this group, representing 21 different countries, 38 being native Americans. The tropical and subtropical countries were almost entirely unrepresented. There were 4 colored and 84 whites.

The age extremes were thirty-seven and seventy-five years, the average age being fifty-seven years, and the greatest number being in the sixth and seventh decades. In contrast to the other groups there were only twelve asymptomatic cases. As a class of patients, seamen fall in the hyposensitive group with reference to pain. There were 2 aneurysms among the patients in this group.

CARDIOVASCULAR SYPHILIS

There were 57 patients, or 11.7 per cent of the total, in this group, 55 of whom had positive serology and 2 of whom had positive histories with negative serology. There were 10 colored and 47 whites. Twenty-six had had one or two courses of antisyphilitic treatment or none at all. There were 11 asymptomatic cases.

The age extremes were twenty-six and sixty-eight years, with an average age of forty-five years, the greatest number being in the fifth decade. There were 8 patients with aneurysm, only 2 of whom gave a history of antisyphilitic treatment prior to this observation.

MISCELLANEOUS GROUP

There were 36 cases under this heading. Among these were five cases of aortic insufficiency in which a history of rheumatic infection or syphilis could not be obtained. The etiology was thus considered as undetermined. There were six cases of auricular fibrillation without any other demonstrable cardiac disease.[5] The patients' ages were between forty-six and seventy-one years. All except one of these cases were asymptomatic.

There was one case of beriberi heart[6] and 6 of congenital cardiac lesions, with patent ductus and transposition. There were 3 cases of adherent pericarditis, one of which was considered Pick's disease. There were 2 cases of bacterial endocarditis, both being fatal. There were 2 cases of chronic cor pulmonale and 3 cases of paroxysmal tachycardia. In addition there were 6 thyroid heart conditions, in one of which auricular fibrillation was noted, and 2 cases of cardiac hypertrophy of undetermined cause.

Auricular fibrillation was the most frequent disturbance in rhythm. There were 49 cases of permanent fibrillation; 23 in the rheumatic group, 14 among the hypertensive group, 6 of undetermined origin, 5 in the atherosclerotic group, and one in the thyroid group. There were only 3 patients with auricular flutter, one established, the other two paroxysmal. One of the latter, which had been previously reported, showed 1:1 rhythm with a rate of 240.[7] There were 23 cases of heart-block, bundle-branch or mixed types; most of them were in the coronary group.

There were 71 deaths, 50 of which came to autopsy, distributed as follows: In the hypertensive group there were 29 deaths and 17 autopsies. Two had coronary thrombosis and two spontaneous rupture of the aorta. In the atherosclerotic group there were 21 deaths and 16 autopsies. Among the autopsied cases one had metastatic carcinoma of the myocardium obstructing the descending ramus of the left coronary artery. One had aortic stenosis and insufficiency considered as syphilitic insufficiency ante mortem, and one had an aneurysm. The others had various degrees of myomalacia from coronary obstruction or myocardial fibrosis from coronary atherosclerosis and insufficiency.

There were 13 deaths among the rheumatics, and 8 autopsies. One case, considered rheumatic mitral insufficiency, was found to have been congenital malformation of the mitral valve resulting in marked insufficiency. One other patient was found to have had syphilitic aortitis with insufficiency in addition to old mitral and aortic rheumatic endo-

carditis. The other six in this group which came to autopsy had mitral stenosis with insufficiency of various degrees. The remaining autopsied cases were two of acute endocarditis of staphylococcic origin, one with tuberculous pericarditis and one with chronic cor pulmonale. There were 7 deaths among the syphilitic cardiac patients and 7 autopsies; 3 had aneurysms, one ruptured, the others were cases of aortic insufficiency.

SUMMARY

Four hundred eighty-five cases of heart disease among seamen are presented. These men represent every continent and 49 different countries and islands. The incidence of heart conditions among seamen is as great as, if not greater than, among landsmen. Hypertension seems to be more frequent among seamen than among other groups in New York, and less frequent than it is in the Northwest.[5, 9] Rheumatic heart disease is about as frequent as among the general population, but American seamen are apparently more susceptible to it than seamen from other countries. The frequency of cardiovascular syphilis among seamen is two to three times as great as that among adult males of the general population.[8]

REFERENCES

1. Public Health Reports 55: 15, April 11, 1930.
2. Public Health Reports 49: 31, p. 912, Aug. 3, 1934.
3. Jour. Social Hygiene 19: 3, 1933.
4. Singer, R.: Wien. klin. Wchnschr. 48: 353, 1935.
5. Fowler, W. M., and Baldridge, C. W.: Auricular Fibrillation as the Only Manifestation of Heart Disease, Am. Heart J. 6: 183, 1930.
6. Keefer, Chester S.: The Beriberi Heart, Arch. Int. Med. 45: 1, 1930.
7. Arenberg, H.: Paroxysmal Auricular Flutter With 1:1 Auriculoventricular Ratio, Ann. Int. Med. 8: 951, 1935.
8. White, Paul D.: Heart Disease, New York, 1931, The Macmillan Co., p. 362.
9. King Robert L.: Northwest. Med. 34: 154, 1935.

THE DIPHASIC QRS TYPE OF ELECTROCARDIOGRAM IN CONGENITAL HEART DISEASE*

L. N. Katz, M.D., and H. Wachtel, M.D.
Chicago, Ill.

While there are a number of reports dealing with the electrocardiographic appearance of congenital heart disease, no characteristic picture has been described other than the occurrence of large voltage and axis deviation.[1-11] Of course, the mirror-image appearance of Lead I in certain cases of dextrocardia and the presence of heart-block and other abnormalities in the electrocardiogram are well known. Recently, we have seen several instances with a peculiar type of diphasic QRS complex in congenital heart disease. A survey of the literature failed to reveal any references to this peculiarity except for the casual mention by Talley and Fowler[12] that a diphasic QRS occurred in the case of congenital heart disease reported by them and their reference to several cases reported by Petit.

It was decided to make a more systematic survey of this peculiarity. For this purpose we have taken 43 typical cases of congenital heart disease from our Heart Station files. Of these, 11 were in their first year of life; 17 were between one and six years of age; 9 were between seven and fifteen years of age; and 6 were between twenty and forty-five years of age. The cases selected for this study had several of the following findings: a history of cyanosis at or near birth; the presence of "heart trouble" at this time; the presence of heart enlargement, cardiac murmurs, or thrills which could not be readily explained by an acquired lesion; and the finding of characteristic roentgenographic alterations. The electrocardiograms of these 43 cases were then analyzed in detail and the results tabulated.

RESULTS

The essential findings in the QRS and the abnormalities in the S-T segment and T-wave are summarized in Table I. There were 16 instances of right axis deviation and 5 of left axis deviation. In 13 instances the amplitude of QRS was large, being over 18 mm. in more than one lead (cf. Fig. 1). Marked slurring of QRS occurred in 13 instances, and in 7 of these the slurring occurred in all leads (Figs. 1 and 2). No abnormalities in rhythm were found in this series except for the occurrence of auricular premature systoles in one case. Abnormalities in the T-wave and the S-T segment were not common. T was tall in 10 cases, 6 cases in Lead II only, 1 in Lead I only, 1 in

*From the Heart Station, Michael Reese Hospital.

Lead III only, and 2 in both Leads II and III. T was small in 7 instances, 6 in Lead I only (cf. Fig. 1) and 1 in all leads. T was negative or diphasic in Leads I and II twice, both having mirror dextrocardia, diphasic in Leads II and III once (cf. Fig. 1) and negative in Lead I once. T was notched in 3 cases, twice in Lead I only,

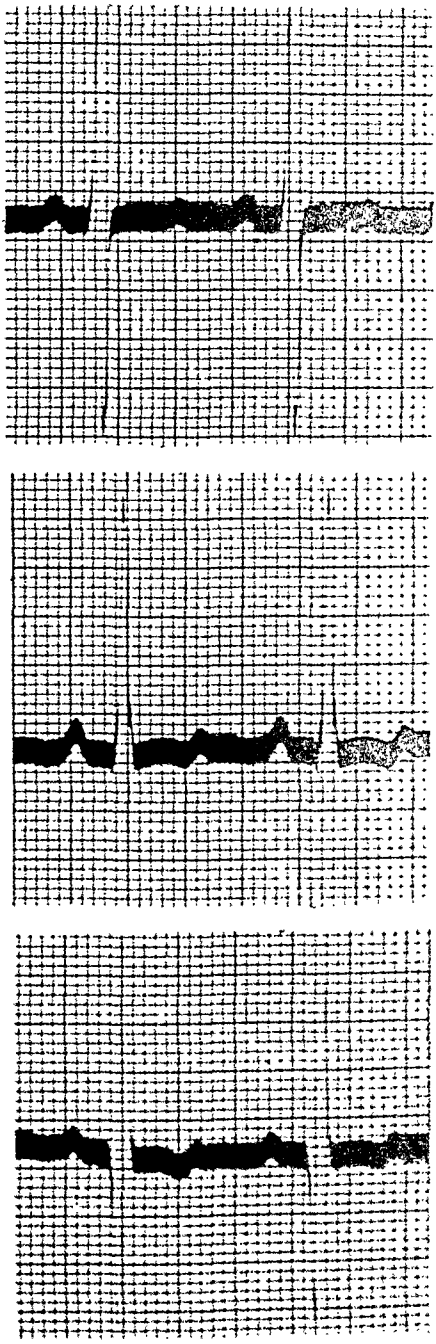

Fig. 1.

Fig. 3.

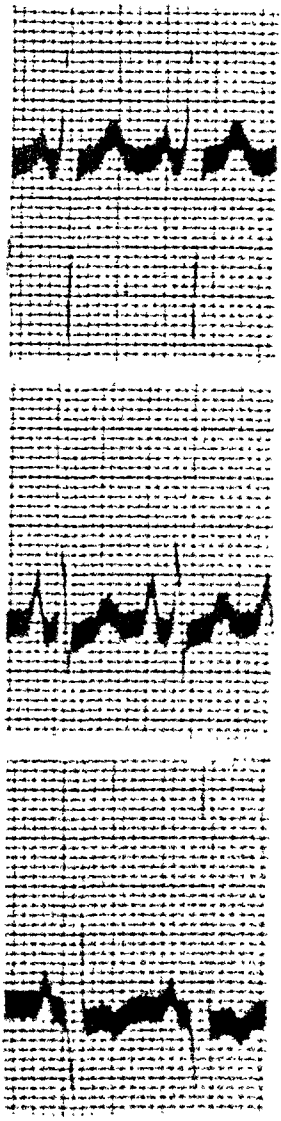

Fig. 2.

Fig. 1.—Note that in Lead III the diphasic QRS is not well reproduced; the first phase is negative, and the second is positive and taller than the size of the print.

and once in all leads. S-T was negative in 7 cases, once in Lead I only (cf. Fig. 2), 3 times in Lead III only, once in Leads I and II, and 3 times in Leads II and III (cf. Figs. 1 and 3). S-T was abnormally positive in one case in Leads II and III (cf. Fig. 2).

While diphasic QRS complexes were very common, we have restricted the term diphasic QRS in this analysis to those diphasic QRS complexes in which the smaller phase had an amplitude of one-fourth or more of the larger phase. The data are assembled in Table I.

TABLE I

AGE	QRS AMPLITUDE IN MM.			T AND S-T CHANGES
	LEAD I	LEAD II	LEAD III	
3 days	+ 3 -10	+12	+18	T_1 small (aur. ext. syst.)
4 days	+ 5 - 5	+17	+15	T_1 tall S-T_3 neg.
14 days	- 8	+ 4 - 5	+ 8	
1 mo.[2]	+10 -12	+ 9 - 9	- 7 + 7	S-T_1 neg. S-T_2 and S-T_3 pos.
6 wk.	+ 5 -15	- 5	+ 3 -18	
2 mo.	+ 5 -12	+16 - 7	+21	T_2 tall
3 mo.	+ 6 -12	- 2 + 2	- 7 +12	T_3 tall
7 mo.[4]	+15 -10	- 2 +15 -7	- 8 +14	
9 mo.	+ 5	+ 4 -10 +1	+ 7 -15 +1	T_1 small
10 mo.	+ 6 - 4	+12	- 3 +12	T small all leads
1 yr.	+10 - 2	+18	- 2 +13	T notched all leads
18 mo.	+10 - 5	+20	- 4 + 8	T_2 and T_3 tall
18 mo.	+ 4	- 2 +20	+12	S-T_2 and S-T_3 neg.
20 mo.	- 2 +11	+14 -10	+ 9 -18	T_1 small and notched
2 yr.	+ 5 - 2	+10	+ 8	
2 yr.	+ 5 -10	- 6	- 7 + 8	
3 yr.	+ 9	+ 1 - 1	- 9	T_1 small
3 yr.	+ 8	+18	+ 8	
4 yr.	+ 3 -13	+10 - 3	- 3 +22	T_1 small and notched
4½ yr.	+ 4 -16	+ 8 - 3	+17	
5 yr.	+ 6 - 5	+12 - 3	+12	
5 yr.	+ 4 -16	+ 9 - 2	- 5 +14	T_2 and T_3 tall
5 yr.	+ 3 - 8	+ 9	- 2 +15	
5½ yr.[3]	+11 -16	+ 8 - 3	- 8 +24	S-T_2 and S-T_3 neg. T_3 neg.
5½ yr.	+ 7 - 4	+ 7	+ 5	
6 yr.	+ 4 - 5	+22	- 4 +24	
6 yr.	+ 5 -13	- 1 +15 -6	- 2 +15	S-T_3 neg.
6 yr.	+ 9	+ 8 - 8	- 8	T_2 tall
8 yr.	+ 3 - 3	+10 - 5	+ 7	
9 yr.	- 5	- 3 +14	+24	
10 yr.	- 2 + 3	+14	+13	T_2 tall
11 yr.[1]	+20 -20	+25	-16 +23	T_1 tiny, T_2 and T_3 diphasic S-T_2 and S-T_3 neg. QRS duration 0.10
11 yr.	- 1 + 6 -5	+18	- 2 +15	
11 yr.	+10	+12 - 4	+ 6 - 8	S-T_1 and S-T_2 neg.
12 yr.	+11	+11	+ 2 - 3	T_2 tall
14 yr.	+ 4 - 3	+19 - 6	+15 - 8	
14 yr.	- 8	+ 8	+13	
23 yr.	+ 1 - 1	- 2 +15	- 1 +15	
25 yr.	- 2 +10	+15	+ 8 - 4	T_2 tall
25 yr.	-12	+ 3	+13	T_1 and T_2 neg. (dextrocardia)
25 yr.	+ 5 - 6	+ 6	+ 8	T_2 tall
32 yr.	- 1 +14	+14 - 1	+ 4 - 4	
44 yr.	- 8	- 8	+ 6 - 2	T_1 neg. T_2 diphasic (dextrocardia)

[1]Fig. 1.
[2]Fig. 2.
[3]Fig. 3.
[4]Fig. 4.

These diphasic QRS complexes were divided into two types; viz., the plus-minus where the first phase was upright and the minus-plus where the first phase was negative. When these diphasic QRS complexes occurred in more than one lead, they were again divided into two types of which the isocyclic was where the signs of the two phases were in the same order in the several leads and the heterocyclic where the signs of the two phases in one lead were the reverse of that in another.

There were 56 instances of diphasic QRS out of a possible total of 129: 26 in Lead I, 14 in Lead II, and 16 in Lead III. The plus-

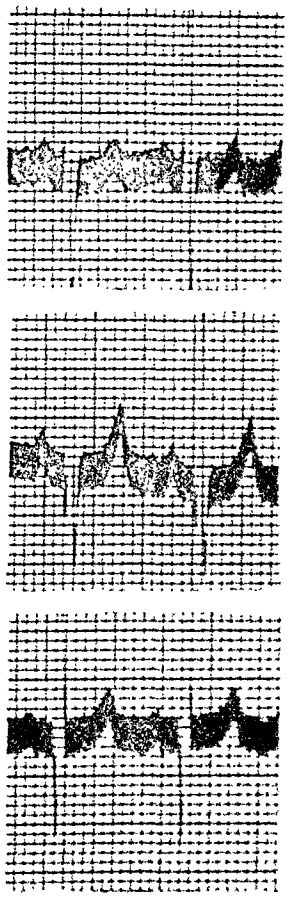

Fig. 4.

minus type was more frequent; viz., 45 instances, 25 in Lead I, 13 in Lead II, and 7 in Lead III. The minus-plus type was less frequent; viz., 11 instances, 1 each in Leads I and II, and 9 in Lead III. Diphasic QRS complexes occurred in more than one lead in 17 cases: in 5 in Leads I and II, in 6 in Leads I and III; in 2 in Leads II and III; and in 4 in all leads. Isocyclic types occurred in 8 cases, one involving all leads, the others Leads I and II or Leads II and III. Heterocyclic types occurred 9 times, 3 involving all leads and 6, Leads I and III. The isocyclic types were all of the plus-minus type. The heterocyclic type had a plus-minus in Lead I and a minus-plus in Lead III.

Several of the more striking examples of these diphasic QRS complexes are shown in Figs. 1 to 4. It is our impression that when changes as marked as those shown in these illustrations are seen, they are pathognomonic of congenital heart disease. Less marked examples in children should arouse suspicion and can be used as confirmatory evidence. Diphasic QRS complexes occur in the absence of congenital heart disease, notably in coronary artery disease (Leads I and III) and in left axis deviation (Lead II). A diphasic QRS in precordial leads is a normal finding. Normal children show diphasic QRS complexes as often as monophasic, triphasic or polyphasic, but a diphasic QRS with the two phases bearing a ratio of less than 1 to 4 is exceptional, if it occurs at all. Hence, it is of diagnostic value in congenital heart disease. In our small series this diphasic QRS was not found associated with any particular type of congenital heart disease.

The mechanism behind the diphasic QRS is unknown, and for the present it is not justifiable to speculate about its cause. It would seem, however, that it might well be a persistence of the embryonic pattern of invasion of the ventricles which would be more likely to persist in hearts whose development was partially checked in the form of other congenital defects.

SUMMARY

A diphasic QRS (with the size of the two phases being of the order of less than 1 to 4) was a frequent finding in congenital heart disease. The presence of such a diphasic QRS is confirmatory of this diagnosis, and, when the two phases are large and of equal extent, the finding is pathognomonic.

REFERENCES

1. Stariopulo, T.: Ztschr. f. exper. Path. u. Therap. 7: 467, 1910.
2. Einthoven, W.: Zentralbl. f. Herz.-u. Gefässkr. 7: 101, 1915.
3. McCulloch, H.: Am. J. Dis. Child. 12: 30, 1916.
4. Alexander, A. A., White, H. F., and Knight, P. D.: Arch. Int. Med. 36: 712, 1925.
5. Roesler, H.: Wien. Arch. f. inn. Med. 15: 487, 1926.
6. Parkinson, J., and Clark-Kennedy, A. E.: Quart. J. Med. 19: 113, 1926.
7. Irvine-Jones, E. I. M.: Am. Heart J. 2: 121, 1926.
8. Brandenburg, V.: Med. Klin. 38: 1464, 1929.
9. Roesler, H.: Wien. Arch. f. inn. Med. 21: 271, 1931.
10. Roesler, H.: Wien. Arch. f. inn. Med. 21: 284, 1931.
11. Burnett, C. T., and Taylor, E. L.: Am. Heart J. 11: 185, 1936.
12. Talley, J. E., and Fowler, K.: Am. J. M. Sc. 191: 618, 1936.

EXTREME CARDIAC ENLARGEMENT*

J. S. GOLDEN, M.D., AND WILLIAM A. BRAMS, M.D.
CHICAGO, ILL.

A CAREFUL search of the literature for records of hearts weighing 1,000 gm. or more revealed that only 38 such instances were reported in the past century. This is partly to be accounted for by the fact that large hearts are often mentioned only incidentally in case reports and as such are difficult to locate in the literature. This apparent infrequency is in striking contrast to our experience at the Cook County Hospital where nine patients with such hearts were admitted since 1928. The difference in frequency and the observation of a patient on our medical service whose heart weighed 1,475 gm. prompted us to report this patient in detail and to summarize the essential features in the nine cases with extreme cardiac enlargement admitted to the Cook County Hospital in the past eight years.

The largest heart on record was removed from a middle-aged man and was mentioned by Sedgwick[1] and again by Wood.[2] The specimen was said to have weighed 5 pounds and was placed in the museum of St. George's Hospital, London. Inquiry of the curator[3] elicited the information that the specimen has been lost and no information is available about the heart or the patient. A summary of the more interesting features of the remaining thirty-seven reports in the literature is found in Table I. It will be seen that all but one of the 38 patients previously reported were males, a finding which agrees with that in our series. Twenty-two of the thirty-eight cases reported were in patients under forty years of age, while two-thirds of our patients were above that age. This discrepancy may be due in part to a greater incidence of syphilis and hypertension in our group.

Further analysis of the patients reported in the literature reveals that the most frequent predominant lesions were adhesions of the pericardium and deformity of the aortic valve. Adhesions of the pericardium were present in seventeen instances and were the sole etiological factor responsible for the enlargement in five, the remaining twelve having associated valvular changes, particularly aortic insufficiency. Pericarditis without adhesions as a single lesion was associated with enlargement of the heart in two instances and was associated with valvular disease in another. Deformity of the aortic leaflets with resulting aortic insufficiency was the most frequent valvular change and was the sole causative factor for cardiac enlargement in six instances. The largest hearts showed a combination of aortic

*From the Department of Medicine, Northwestern University Medical School, the Pathologic Institute, Cook County Hospital, Dr. Richard H. Jaffe, Director, and the Cardiovascular Department, Michael Reese Hospital, Chicago, Illinois.

TABLE I

REPORTS OF HEARTS WEIGHING 1,000 GM. OR MORE OBTAINED FROM THE LITERATURE ON CARDIAC HYPERTROPHY

AUTHOR DATE	AGE OF PATIENT	SEX	HEART WEIGHT	THICKNESS OF VENTRICLES LEFT	RIGHT	PATHOLOGICAL ALTERATIONS
Stokes[4] 1869	25	M	1980	3.75 cm.		Deformed aortic valve; aortic insufficiency; pericardium thickened and cartilaginous in places; acute pericarditis.
Smith[5] 1850	28	M	1755 with sac	2.5 cm.		Pericardial adhesions; mitral valve thickened; aortic valve covered with "adventitious" deposits.
Robinson[6] 1883	39	M	1590 with sac	3.0 cm.		Pericardial thickening, no adhesions mentioned; deformed aortic valve; aortic insufficiency; mitral valve thickened; slight renal granulation.
Sedgwick[1] 1854	26	F	1507	4.4 cm.		Pericardial adhesions; mitral and aortic valves deformed; no aortic insufficiency; aorta dilated; aortic stenosis?
Bristowe[7] 1861	22	M	1395	2.1	0.4 cm.	Pericardial adhesions; thoraco-pericardial adhesions; deformed aortic valve; aortic insufficiency.
David[8] 1862	42	M	1395			Right pleural adhesions and effusion; pericardial effusion; intense endocarditis of both sides of heart.
White[9] 1885	middle age	M	1380	2.5 cm.		Aortic valves thick and incompetent; no vegetations; one cusp turned on itself; mitral valve insufficient but not deformed; kidneys slightly granular.
Bell[10] 1847	40	M	1350 with sac			Mitral valve slightly thickened and opaque; all chambers hypertrophied; pericardium healthy.
King[11] 1845	29	M	1335			Pericardial adhesions; deformed aortic and mitral valves; aortic insufficiency and stenosis; aorta thinned and slightly dilated.
Cabot[12] 1926	31	M	1328			Pericardial and mediastinal adhesions; aortic valve 7 cm.; double murmur over precordium.
Metcalfe[13] 1852	24	M	1320	3.75 cm.		Pericardial adhesions; deformed aortic valve; aortic insufficiency; free edges of mitral valve thickened; fatty degeneration of myocardium and kidneys.
Cabot[12] 1926	30	M	1273			Pericardial and mediastinal adhesions; aortic orifice enlarged; acute endocarditis (aortic); deformed aortic and mitral valves; double murmur everywhere; subacute glomerulonephritis.

TABLE I—CONT'D

Gardere and Rousset[14] 1928	56	M	1270			Serous pericarditis; pulmonary tuberculosis; pleural effusion; tuberculous peritonitis.
Peacock[15] 1854	65	M	1248	3.6	0.9 cm.	Slight atheromatous degeneration of aortic and mitral valves and aorta.
Brack[16] 1931	42	M	1210			No macroscopic scars; no microscopic done.
Dulles[17] 1884	18	M	1200			Pericardial adhesions; double mitral murmur; kidneys large, congenitally lobulated.
Hodenpyl[18] 1890	21	M	1200 about			Pericardial adhesions; deformed aortic valve; aortic insufficiency (?).
Kinney[19] 1884	60	M	1200	2.5	0.6 cm.	Mitral and aortic valves insufficient; no valvular deformities mentioned; myocardium at apex thin; kidneys enlarged and lobulated; cysts of left kidney; inflammatory rheumatism when young.
Howard[20] 1892	20	M	1180			Pericardial adhesions; deformed aortic and mitral valves; aortic and mitral insufficiency; nephritis; scars of myocardium; coronaries dilated.
Cabot[12] 1926	19	M	1158 with sac			Pericardial and mediastinal adhesions; valve orifices enlarged; chronic nondeforming endocarditis, aortic; double murmur; Corrigan and pistol shot.
Cabot[12] 1926	52	M	1150			Pericardial adhesions; valve orifices enlarged; systolic at apex (loud); acute endocarditis, aortic, mitral and tricuspid.
Cabot[12] 1926	31	M	1140			Pericardial and mediastinal adhesions; valve orifices enlarged; chronic nondeforming endocarditis; double murmur; aortic second loud and ringing.
Banks[21] 1863	18	M	1140	5.0 cm.		Pericardial adhesions; aortic and mitral valve deformity; aortic and mitral insufficiency; fatty infiltration of myocardium.
Gola[22] 1847	48	M	1140	2.9 cm.		Aneurysm of aorta; no valve disease; mitral insufficiency; hypertrophy of left ventricle.
Van der Byl[23] 1857	28	M	1080	2.9 cm.		Deformed aortic valve; aortic insufficiency; mitral valve slightly thickened; kidneys partly granular.
Smith[24] 1871	37	M	1080			Deformed aortic valves; aortic stenosis and insufficiency; kidneys large and indurated.
Leuf[25] 1885	29	M	1080 with sac			Pericardial adhesions; aortic and mitral lesions; aortic and mitral stenosis and insufficiency.
Balzer[26] 1875	30	M	1070	2.9 cm.		Aortic valve deformed; aortic insufficiency.

TABLE I—CONT'D

AUTHOR DATE	AGE OF PATIENT	SEX	HEART WEIGHT	THICKNESS OF VENTRICLES LEFT	RIGHT	PATHOLOGICAL ALTERATIONS
Blackford, Bryan, and Hollar[27] 1936	36	M	1070	2-3 cm.		Calcified aortic valves; mitral valve thickened and scarred but not calcified; small area of pericardial adhesions (5 cm.); systolic and diastolic murmurs at the base.
Rondier and Langenieux[28] 1928	73	M	1020			Tuberculous pericarditis; no adhesions.
Peacock[15] 1854	55	M	1020	3.25	1.6 cm.	Aortic valve deformed; aortic insufficiency.
Wallace[29] 1880	21	M	1020	2.1 cm.		Deformed mitral valve; admits one finger; deformed aortic valve with vegetations some of which were calcified; vegetations extend for 1 inch on anterior ventricular wall.
Grant[30] 1933	49	M	1020 with aorta			Syphilitic aortitis; aortic insufficiency.
Willius and Smith[31] 1934	40	M	1017			Deformed aortic valve; aortic stenosis.
Roussy[32] 1903		M	1010	2.5 cm.		Aortic and mitral insufficiency and stenosis; aorta moderately dilated.
Cabot[12] 1926	19	M	1000			Pericardial and mediastinal adhesions; aortic stenosis.
Cabot[12] 1926	50	M	1000			Syphilitic aortitis; aortic regurgitation; aneurysm.

insufficiency and pericardial adhesions. Five specimens were either inadequately described or were associated with insufficient change to account for the extreme enlargement.

The nine cases constituting our series, summarized in Table II, differed in some respects from those reported in the literature. There was only one instance of pericardial adhesions. Aortic valve deformity with insufficiency was present in six instances, in one of which a mitral valve defect coexisted, and in four arteriosclerosis was also present. Nephrosclerosis with hypertension but without pericardial adhesions or valvular deformity was present in two patients. The associated lesions in our series thus differed in several respects from those described in the literature. This may be due to the older age of our patients, to the greater incidence of syphilis and hypertension, and to the more frequent recognition of syphilitic lesions as compared with observations made in the nineteenth and very early part of the twentieth centuries. Routine blood pressure observation has been the rule for the past twenty-five years but was hardly practiced before that time. A further factor in the difference between the two

TABLE II

SPECIMENS OBTAINED AT COOK COUNTY HOSPITAL

CASE	AGE	SEX	RACE	HEART WT.	BODY WT. (Kg.)	HEIGHT	EDEMA	THICKNESS OF VENTRICLES LEFT	THICKNESS OF VENTRICLES RIGHT	BLOOD PRESSURE	PATHOLOGICAL ALTERATIONS
1	33	M	C	1475	88	182	+ +	2.5	1.0 cm.	170/55	Slight fibroplastic deformity of aortic valve leaflets; aortic insufficiency; focal areas of myocardial fibrosis and atrophy; septic staining of all organs; renal arteriolosclerosis.
2	57	M	W	1200	200.5	175	+ +	2.5	0.6 cm.	230/125	Renal arteriolosclerosis; chronic emphysema; obesity; nodose goiter; left coronary: + + hyaline, fatty and calcific plaques.
3	50	F	C	1150	45.5	161		2.1	0.4 cm.	250/160	Malignant nephrosclerosis; focal supravalvular syphilitic aortitis; light yellow fatty plaques in coronaries.
4	41	M	C	1120 with sac	86	171	+ +	2.5	0.9 cm.		Pericardial adhesions; syphilitic aortitis; moderate coronary sclerosis; slight atheroma of aorta and pulmonary artery; renal arteriolosclerosis.
5	46	M	W	1100	84	174	+			155/135	Syphilitic aortitis; aortic insufficiency; moderate renal arteriolosclerosis; epicardial fibrosis with calcification in some areas.
6	66	M	W	1060	130	175	+ +	2.6	0.8 cm.		Syphilitic aortitis, aortic insufficiency; coronary ostia stenosis; coronary and aortic sclerosis; renal arteriolosclerosis.
7	28	M	W	1050	54	170	+	2.5	1.0 cm.	160/50	Deformity of aortic and mitral valves; aortic and mitral stenosis and insufficiency; hyaline plaques in coronaries.
8	52	M	C	1020	93.5	182	+ +			115/85	Syphilitic aortitis; aortic insufficiency; slight coronary sclerosis.
9	43	M	C	1000	80	181	+ +	2.0	0.7 cm.		Syphilitic aortitis; aortic insufficiency; coronary ostia stenoses; renal arteriolosclerosis; myocardial degeneration; mitral insufficiency.

series is the fact that five of our nine patients were negroes, in whom syphilitic cardiovascular disease and hypertension are very common.

The occurrence of extreme cardiac enlargement with insufficient pathological change in the heart or other structures to account for such increase in weight has been reported by several observers including Cabot,[33] Whittle,[34] Levy and Rousselot,[35] and Brack.[16] A diagnosis of extreme idiopathic hypertrophy is probably inadequate in most instances in adults. Kugel and Stoloff[36] in their survey of congenital idiopathic hypertrophy found only seventeen "true" instances, in which few of the patients lived beyond two years of age, the oldest being nine at death. There are, nevertheless, instances in

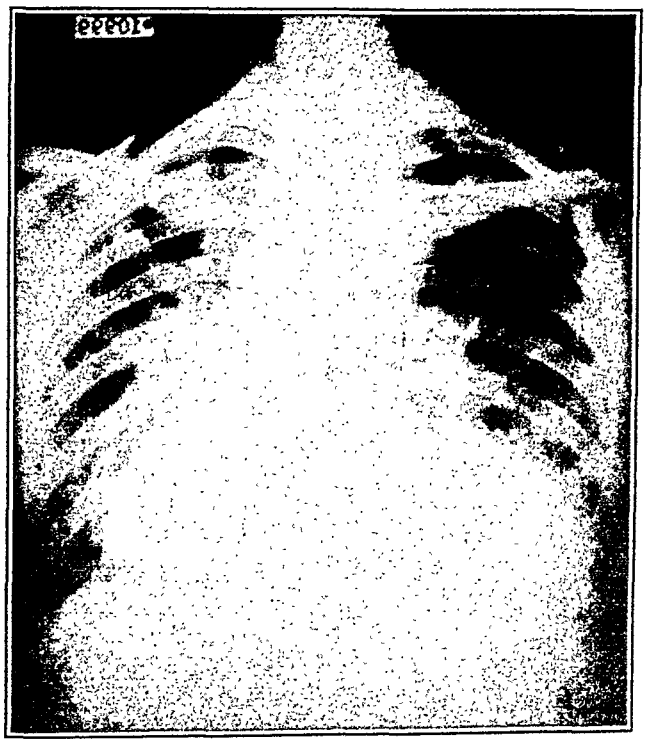

Fig. 1.—Teleoroentgenogram showing enormous boot-shaped heart, enlargement of the right auricle, widening of the aortic shadow, extension of the ventricular shadow to the left, and marked hilus congestion.

which an adequate anatomical or functional cause cannot be found with our present methods of examination, the following case report being such an example.

REPORT OF CASE

P. R., a colored laborer, thirty-three years of age, entered the Cook County Hospital Feb. 8, 1935. Three years previously he had noted "fluttering of the heart" and orthopnea for which he had been treated with digitalis until the present. His symptoms became progressively worse and were particularly severe in the three months preceding admission to the hospital.

In 1919, at eighteen years of age, the patient had a peritonsillar abscess with subsequent frequent recurrent tonsillitis until one year ago, when a tonsillectomy was performed. He had malaria in 1915, a Neisserian infection in 1922 and admitted receiving antisyphilitic treatment.

On admission the patient was dyspneic and orthopneic. The pupils were regular and equal and reacted to light. The mucous membranes were pale. Fine crepitant râles were present at both lung bases; the liver was tender and extended almost to the umbilicus; and there was edema of the lower extremities, genitals, abdominal wall, and lower back. Auricular fibrillation was noted, the ventricular rate averaging about 90 per minute. The transverse diameter of the heart was enormously increased as was the extent of dullness across the upper sternum. Systolic and diastolic thrills and corresponding rough murmurs were noted at the aortic area and over the carotid arteries. There was a diastolic murmur at the apex as well as a systolic murmur, the latter being transmitted to the axilla and back. The pulmonic second tone was accentuated.

A teleroentgenogram (Fig. 1) of the chest revealed an enormously enlarged boot-shaped heart. The Wassermann reaction was negative. Albumin, a few red and white blood cells, and an occasional hyaline and granular cast were present in the

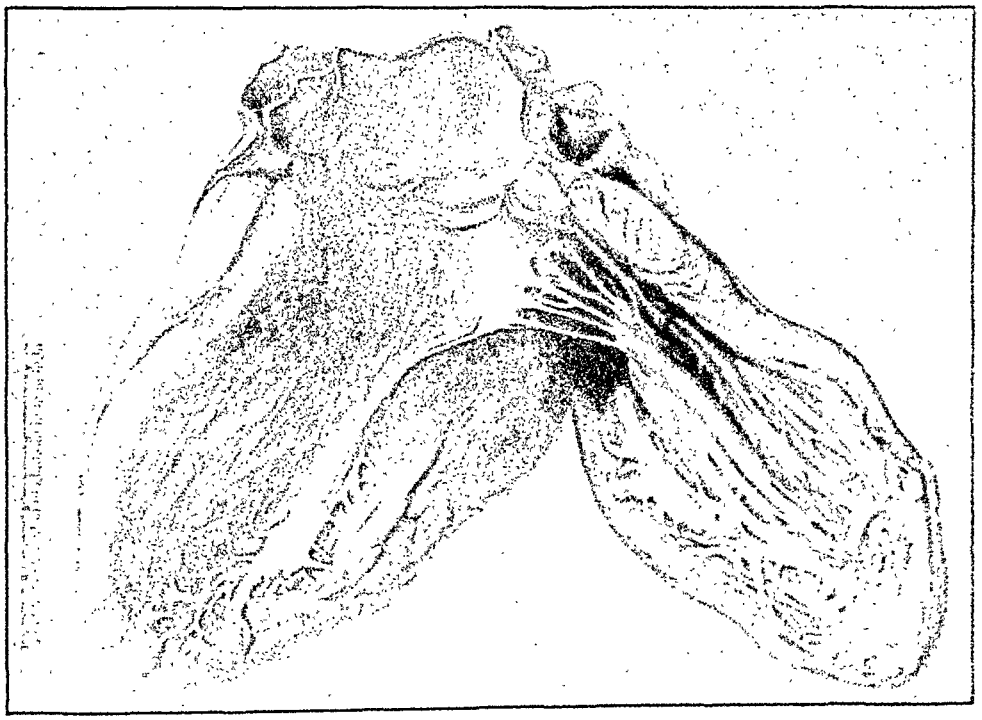

Fig. 2.—Drawing showing extreme enlargement of the heart, marked thickening of the ventricular walls, and comparatively insignificant changes of the aortic leaflets.

urine. The blood urea was 33.3 and the creatinine, 2.15 mg. per 100 c.c. A single blood pressure determination was 170/55 but was unreliable because of the existing auricular fibrillation.

The clinical diagnosis was chronic rheumatic heart disease; double mitral and aortic lesions; marked cardiac hypertrophy; auricular fibrillation; anasarca; syphilitic aortic regurgitation was considered as a possible factor.

One week after entrance the patient contracted erysipelas and died Feb. 17, 1935.

Necropsy revealed the following: The pericardial sac extended 8 cm. to the right of the midsternal line and to the left midaxillary line. The sac contained 250 c.c. of serosanguineous fluid.

The heart weighed 1,475 grams (Fig. 2). The left ventricle was 25 mm. thick and the right 10 mm. The myocardium was purple gray, very soft, and edematous. The aortic leaflets were slightly rolled. The commissures, especially between the left and middle aortic leaflets, were obliterated by firm synechiae. The endocardium of the

left ventricle was deep purple red, mottled with purple gray. The trabeculae were flattened. The aortic ring was 99 mm. in circumference. The intima of the aorta was discolored cherry red and studded with isolated hyaline plaques in the ascending portion. The intima of the descendens was smooth and stained deep cherry red. The circumference of the pulmonic ring was 100 mm. The intima of the pulmonary artery was smooth and stained red. Both coronary arteries were thin walled and their intimae smooth.

The kidneys weighed 525 gm. Their capsules stripped with ease leaving a smooth purple red surface. The sectioned cortex averaged 7 mm. The architectural markings were indistinct. At the upper pole of the right kidney the renal vein was occluded by an adherent thrombus. The thyroid showed no abnormal changes.

The microscopic report by Dr. Richard H. Jaffe is as follows:

"The fibers of the myocardium (Fig. 3) are considerably increased in thickness. The longitudinal striation is very prominent, but the cross-striation is often obscured. The nuclei are of irregular shape and rich in chromatin with a small amount of golden yellow pigment about the poles of the nuclei. The muscle fibers are atrophic



Fig. 3.—Photomicrograph (×90) of the myocardium of heart weighing 1,475 gm., showing the hypertrophy of the muscle fibers, small focal areas of muscle atrophy, and increase in interstitial connective tissue.

in small focal areas, but the interstitial tissue is increased, dense and scarlike. Outside of these areas the muscle fibers are separated by a scanty and moderately cellular stroma. The connective tissue septums about the larger vessels are thickened and contain recent extravasations of blood. The arteries and arterioles do not show any abnormal findings. The endocardium is slightly thickened. Special stains to demonstrate glycogen in the myocardium failed to reveal abnormal deposits of this substance.

"The glomeruli of the kidney are of moderate cellularity and the capsular space is empty. The epithelium of the convoluted tubules shows marked autolytic disintegration. There is a moderate thickening of the walls of the afferent and interlobular arterioles and insignificant thickening of the intimae of the arciform and interlobar arteries."

Anatomical Diagnosis.—Erysipelas; very marked hypertrophy and dilatation of the heart; septic staining of all the organs especially of the aortic intima; slight fibroplastic deformity of the aortic leaflets with insufficiency of the valve; chronic passive

congestion of the lungs, liver, and kidneys; anemic infarct of the spleen; thrombosis of a branch of the right renal vein to the upper pole; chronic hyperplasia of the spleen; chronic cholecystitis and cholelithiasis; slight hydropericardium.

DISCUSSION

The striking frequency of adhesions of the pericardium in the patients previously reported and the equally striking infrequency of this finding in our series of very large hearts is another example of how misleading such statistics based on relatively few cases can be. Rheumatic infection was more common in the younger patients who form such a large proportion of the cases of very large hearts previously reported. Our series consisted of proportionally more colored patients and persons more than forty years old. There was, therefore, a greater incidence of syphilitic aortic valve involvement and hypertensive phenomena, but this does not explain the comparative infrequency of pericardial adhesions in our series. Close study of the anatomical descriptions, incomplete as they are in many instances in the literature, reveals that pericardial adhesions alone were present in only five instances, although such adhesions are reported in almost half of the series. A valvular defect, usually aortic insufficiency, was also present in many and was probably partly responsible for cardiac enlargement.

The pathologist, as well as the clinician, is sometimes confronted by the impossibility in given instances to explain the cause of cardiac enlargement. Hypertension, thyroid disease, or other causes *assumed* to have existed previously are merely assumptions and therefore do not really explain the changes found in the heart. Disturbances of glycogen metabolism have been associated with enlargement of several organs, including the heart, but were excluded in our first patient. It may be incorrect to state that no cause can be found for extreme cardiac enlargement in some instances, but we must admit that present methods of investigation failed to reveal a satisfactory cause for the large heart found in our patient. We are forced to report this case as idiopathic cardiac enlargement, an instance in which the pathological changes found at autopsy were far from adequate to serve as a complete explanation for the extreme size of the heart.

SUMMARY AND CONCLUSIONS

1. Although only thirty-eight reports of hearts weighing 1,000 gm. or more could be found in the literature of the past century, nine such specimens were observed in patients admitted to the Cook County Hospital in the past eight years.

2. The unreliability of statistics based on small numbers of patients is again emphasized when our group of nine hearts weighing 1,000 gm. or more is compared with the reports in the literature.

3. Only one of our nine large hearts was associated with pericardial adhesions, while almost half of those previously reported were sup-

posedly due to pericardial adhesions, either alone or in combination with valvular disease.

4. The great predominance of males in both series is striking and cannot be easily explained.

5. Aortic valve deformity, usually insufficiency, was the most frequent valvular lesion found in our patients and in those previously reported.

6. A patient whose heart weighed 1,475 grams is reported in detail, and the point is emphasized that no adequate explanation can be offered either from clinical or anatomical study of this case. The term "idiopathic" is probably appropriate in this instance as we do not know the cause, and the anatomical changes are far from adequate to explain such extreme enlargement and hypertrophy.

NOTE.—We are indebted to Ashton Miller, Esq., St. George's Hospital, London, for kindly furnishing the information concerning the large heart formerly at the museum of the hospital, and we wish to acknowledge the suggestions of Dr. L. N. Katz in the preparation of this report.

REFERENCES

1. Sedgwick, W.: Lancet 2: 332, 1854.
2. Wood, G. B.: Treatise on Practice of Medicine, Philadelphia, 1866, J. B. Lippincott, Vol. 2, p. 190.
3. Miller, Ashton: Personal communication.
4. Stokes: Brit. M. J. 1: 152, 1869.
5. Smith: Referred to by Clark: New York J. Med. 55: 207, 1850.
6. Robinson, B.: M. Rec. New York 24: 663, 1883.
7. Bristowe: Trans. Path. Soc. London 13: 32, 1861-62.
8. David: Referred to by Gibbs: Trans. Path. Soc. London 13: 30, 1861-62.
9. White, W. Hale: Trans. Path. Soc. London 36: 126, 1884-85.
10. Bell, C.: London M. Gaz. (n. s. 4) 39: 209, 1847.
11. King, C.: Dublin M. Press 14: 405, 1845.
12. Cabot, R. C.: Facts on the Heart, Philadelphia and London, 1926, W. B. Saunders Co., pp. 429-432.
13. Metcalfe: New York M. Times 2: 317, 1852.
14. Gardere, H., and Rousset, J.: Lyon méd. 141: 13, 1928.
15. Peacock, T. B.: Month. J. M. Sc., Lond.-Edinb. 19: 193, 1854.
16. Brack, E.: Ztschr. f. Kreislaufforsch. 23: 80, 1931.
17. Dulles, C. W.: Boston M. & S. J. 110: 16, 1884.
18. Hodenpyl, E.: Proc. New York Path. Soc. 8: 29, 1890.
19. Kinney, E. C.: Proc. Connecticut M. Soc. (n. s. 3) 1: 43, 1884.
20. Howard, W. T., Jr.: Johns Hopkins Hosp. Rep. 3: 265, 1892-3.
21. Banks: Dublin J. M. Sc. 35: 168, 1863.
22. Gola, D.: Gazz. med. di Milano 14: 117, 1847.
23. Van der Byl: Trans. Path. Soc. London 1: 173, 1857-58.
24. Smith, D. B.: Indian M. Gaz. 6: 237, 1871.
25. Leuf, D. H. P.: Trans. Brooklyn Path. Soc. 1: 93, 1885-86.
26. Balzer, V.: Bull. Soc. anat. 3s 10: 172, 1875.
27. Blackford, L. M., Bryan, W. W., and Hollar, E. D.: J. A. M. A. 107: 18, 1936.
28. Rondier, C., and Langenieux, J.: Lyon méd. 141: 213, 1928.
29. Wallace, W.: Proc. Med. Soc. County of Kings 5: 33, 1880.
30. Grant, R. T.: Heart 16: 275, 1933.
31. Willius, F. A., and Smith, H. L.: AM. HEART J. 10: 190, 1934.
32. Roussy, M. G.: Bull. Soc. anat. (6s) 5: 539, 1903.
33. Cabot, R. C.: New England Med. J. 205: 1199, 1931.
34. Whittle, C. H.: Lancet 1: 1354, 1929.
35. Levy, R. L., and Rousselot, L. M.: AM. HEART J. 9: 178, 1933.
36. Kugel, M. A., and Stoloff, E. G.: Am. J. Dis. Child. 45: 828, 1933.

curves in which the main initial deflection was downwardly directed. In Lead III the main initial deflection was negative when stimulating various sites on the posterior surface of both ventricles and various sites on the anterior inferior portion of the left ventricle. It was positive when stimulating the rest of the anterior surface of the heart.

In order to rule out the possibility that this might be a species peculiarity limited to the cat, it was decided to repeat the experiments in the dog's and the monkey's hearts; the latter, in many respects, being more like the human heart than that of any other experimental animal. In the experiments on the dog it was possible to obtain other information concerning the effect on the electrocardiographic contour of these ectopic beats by changing the position of the heart and, also, by altering the nature of the electrical conductors in contact with it. This last was done in order to determine whether or not such a procedure would modify the contour of the ectopic beats as it does that of normal beats (Katz and Korey[11] and Katz, Gutman, and Ocko[12]).

In this report, therefore, three lines of investigation are presented: (1) further data as to the basic factors underlying the electrocardiographic form of experimentally produced ectopic ventricular contractions in the monkey and dog; (2) the effect produced upon the contour of these ectopic beats by displacing the heart from its normal experimental position; and (3) the effect produced upon their contour by altering the normal electrical field surrounding the heart (a) by the application of shunts between certain sites on its epicardial surface and distant portions of the body and (b) by placing an insulator between the heart and the posterior muscle mass.

METHOD

The experiments were performed upon three rhesus monkeys and six dogs, the former being anesthetized by the intraperitoneal injection of dial (0.6 c.c. per kilogram of body weight), the latter by the intravenous injection of sodium barbital. This series was considered large enough since the results were generally consistent and since an almost unlimited number of points could be studied in each animal. The preliminary steps were similar to those described in a previous paper.[10] Artificial respiration was begun, and the heart was exposed by removing the sternum and adjoining portions of ribs and cartilages. The pericardium was slit and used to make a hammock for the heart. Stimuli were then applied by means of an electrode consisting of a No. 26 hypodermic needle with a fine insulated wire passing through the center. The outer tube and the inner wire were each led to the terminals of a secondary coil of an inductorium. The entire electrode was insulated except for the free edge of the needle and the tip of the wire. When the posterior wall was being stimulated, a similar type of electrode was utilized except that it had a 90° bend close to its tip; the normal position of the heart further being maintained by light pressure on its anterior surface with a gloved hand. A series of ectopic ventricular contractions for each site of study was obtained by means of the Lewis interruptor connected to an inductorium, the effective stimuli being break shocks produced at a rate slightly greater than that of the sinus pacemaker. The

or small diphasic initial complexes were joined, it was found that a line of transition consisting of two limbs could be mapped out, one running on the anterior surface of the ventricles from base to apex, the other on the posterior surface, with both meeting at the apex of the heart. As in the cat,[10] this line of transition in both the monkey and the dog did not conform to any anatomical boundaries between the two ventricles. It ran for the most part obliquely on the left ventricle some distance to the left of the interventricular grooves, except that in the case of the monkey's heart, the basal portion of the anterior limb tended to extend onto the right ventricle over the conus region (Fig. 1), a finding not as constant in the dog.

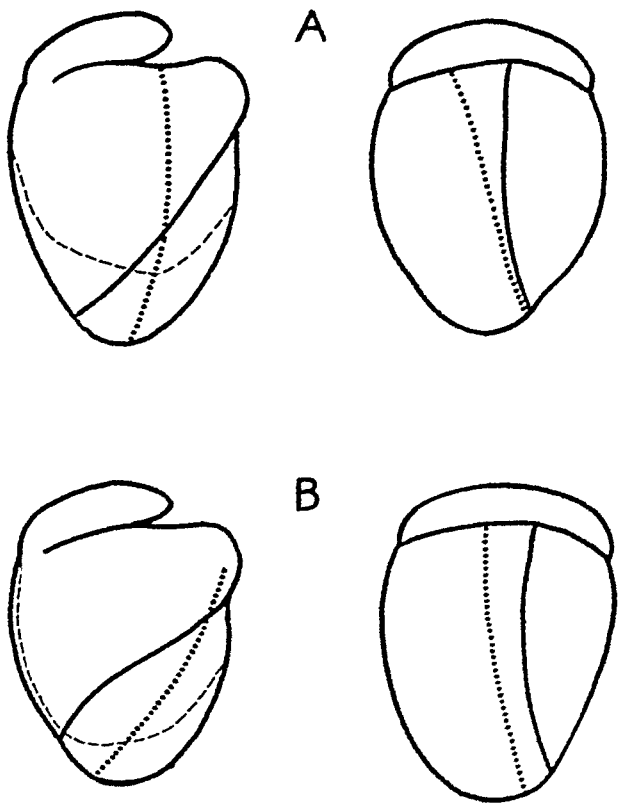

Fig. 1.—Diagrams of anterior and posterior aspects of the heart of the monkey *A*, and the dog, *B*, to show the average position of the lines of transition. The anterior aspects of the hearts are on the left and the posterior on the right. Dotted lines represent line of transition for Lead I and dash lines for Lead III. Discussed in text.

A line of transition, which followed a different course from that of Lead I, was similarly mapped out for Lead III. It was found that the direction of the main initial deflection of the curves obtained from the basal anterior surface of both the right and left ventricles was consistently positive, and only when the stimulating electrode approached the lateral borders of the ventricles did a transition occur. This transition consisted of the appearance first of a diphasic initial complex with a small negative wave and a large positive wave; then the negative phase gradually increased in size and the positive phase

were in the same direction. Furthermore, the width of the initial complex in these instances was generally within normal limits or only slightly increased, and the amplitude of the wave even less than that of the normal QRS complex. In other words, the curves of ectopic ventricular beats obtained by stimulation near the line of transition of a lead did not possess any of the characteristics usually associated with such electrocardiographic records. The differences between the so-called typical and atypical type of configuration were clearly brought out when simultaneous tracings of Leads I and III were taken. Figure 2 which presents curves (Curves *3* and *6*) obtained by stimulation in the vicinity of the anterior and posterior interventricular grooves, points near the line of transition for Lead I, exemplifies the difference in the time span of the deflections in the two leads and also demonstrates that the time of onset and offset of the initial and terminal waves in both is definitely out of phase. In the light of the above, therefore, it must be stressed that the designation of one of these tracings (i.e., Lead III) as typical of a record of a premature ventricular contraction and the other (i.e., Lead I) as atypical is not justifiable, since there are numerous sites, stimulation of which will produce curves falling into the latter category.

Examination of Fig. 1 reveals that a so-called right ventricular type of curve, i.e., one with a main deflection that is positively directed in Lead I, can be obtained not only from the entire right ventricle but also from a strip of left ventricle adjacent to the interventricular grooves on both surfaces. Further, in the monkey a left ventricular type of curve could be obtained from the conus region of the right ventricle. In other words, in the case of the dog and monkey, as well as in the cat, one cannot localize with certainty the origin of a premature ventricular contraction to either ventricle merely on the basis of direction of the main initial deflection. The information derived from Lead III will help to limit the site of impulse origin to one or the other aspect of the heart, although here again the anterior inferior portion of the left ventricle is an exception, in that stimulation in this region produces a type of curve similar to that obtained from the entire posterior surface of the ventricles, i.e., one containing a negatively directed main initial deflection.

The so-called concordancy and discordancy relationship which was first emphasized by Lewis[5] and to which has been attached considerable significance by subsequent investigators[1, 9] appears in the light of the above findings to be merely a fortuitous one. In other words, the fact that the direction of the main deflection in Leads I and III is the same (concordant) or dissimilar (discordant) by itself does not add to the information which can be obtained by an examination of each lead in succession. However, since the lines of transition for Leads I and III intersect, the surface of the heart can thus be divided

surface. Thus, the line of transition for Lead I seemed to retain its relation to the body and to the recording lead line (i.e., a line extending between the two shoulders anteriorly) within narrow limits during these rotations, although its exact position on the heart surface varied, of course, with the degree and direction of rotation. On the other hand, when the apex of the heart was moved to the right or to the left, without permitting rotation of the heart on its own long axis, or when the apex was elevated sternad or depressed vertebrad, very little change took place in the location of the line of transition for Lead I on the heart surface. Obviously then, the relation of this line to the body and to the recording line of Lead I was altered by these last procedures, contrary to what occurred when the heart was rotated on its own long axis.

In the case of Lead III, the greatest change in the site of the line of transition was also observed when the heart was rotated on its own long axis. Under these conditions the line was displaced from its location on the lateral wall of the ventricles onto their anterior or posterior surface depending upon the direction of rotation. Again the position of the line of transition altered little with respect to the body. With elevation or depression of the apex of the heart, a slight change in the location on the heart of the inferior portion of the line was noted, but none occurred when the apex was displaced to the right or left without rotation of the heart on its own long axis. In other words, with these latter procedures, the line of transition changed with respect to the body. It would, therefore, appear that only when the heart is rotated on its own long axis and not disturbed otherwise will there be no shift in the relationship of the lines of transition to the recording lead lines and to the body as a whole.

Effect Upon the Electrocardiographic Contour of Ectopic Ventricular Beats by Altering the Electrical Conductors in Contact With the Heart.—In order to determine whether altering the conditions under which the electrical currents are conducted away from the heart would in turn affect the type of curve produced by ectopic beats elicited from the ventricles, an attempt was made to introduce an artificial effective pathway to distant portions of the body by means of a shunt. Second, by placing a rubber sheet under the heart, the effect was also noted of eliminating to some degree one of the most important electrical conductors of the heart currents, the posterior muscle mass.[11]

It was found that, when a shunt was made in the dog between the anterior surface of the right ventricle and the right axilla (i.e., near the right arm electrode), practically no alteration was noticed in the curves recorded with Lead III. However, in the case of Lead I there was a definite change in the location of the line of transition. Its anterior limb, instead of running downward over the left ventricle,

ventricle in Lead I resembling that obtained from the left ventricle. In other words, in the dog and monkey, as in the cat, one cannot with certainty localize the site of impulse formation to one or the other ventricle merely upon the contour of the electrocardiographic record of Lead I. With regard to Lead III, the form of the record appeared to depend upon whether the anterior or posterior surface of the heart was stimulated, an exception being the anterior apical portion of the left ventricle, stimulation of which in this lead gave curves resembling those from the posterior surface. The terms "concordancy" and "discordancy," as applied to the relative direction of the main deflection of ectopic ventricular beats in Leads I and III, did not contribute any more information in localizing the site of impulse initiation than could be obtained from an analysis of each lead separately. Their usage, therefore, appears to be superfluous. Stimulation in the vicinity of a line of transition for a lead resulted in tracings which contained initial and terminal complexes that were of small amplitude, at times in the same phase and generally only slightly widened. Since these curves could be obtained from numerous sites on the epicardial surface of the ventricles, their designation as atypical records of premature ventricular contractions has no real basis.

With rotation of the heart on its own long axis, the line of transition for both Leads I and III remained practically unaltered with respect to the long axis of the body, although the actual location of the lines on the heart surface was changed depending upon the degree and direction of the displacement.

When, however, other types of change in the position of the heart were produced by shifting the apex, this constancy of the lines of transition were then found to remain practically fixed on the heart and to alter in relation to the body in proportion to the angular displacement of the heart. Besides these latter displacements of the heart, alterations in the character of the electrical conductors in contact with it affected the contour of electrocardiographic records of the ectopic ventricular contractions, and accordingly, the location of the lines of transition on the heart surface and also their location with respect to the body.

These results do not conform wholly with the generally accepted concept of localization of ectopic ventricular beats. They support the idea that besides the location of the site of origin of ectopic beats with respect to the recording lines of the standard leads and the mass of ventricular muscle as a whole, the position of various regions of the heart to the good and poor electrical conductors in contact with it plays a significant rôle in determining the electrocardiographic contour. The relation of the point of stimulation to the two networks of Purkinje appears to exert only a minor influence.

The observations here reported give a systematic perspective of the way in which the location of ectopic ventricular beats should be derived from the electrocardiographic records obtained with the indirect leads.

REFERENCES

1. Barker, P. S., Macleod, A. G., and Alexander, J.: Am. Heart J. 5: 720, 1930.
2. Marvin, H. M., and Oughterson, A. W.: Am. Heart J. 7: 471, 1932.
3. Vander Veer, J. B.: Am. Heart J. 8: 807, 1933.
4. Lewis, T.: Phil. Trans. Roy. Soc., B. 207: 279, 1916.
5. Lewis, T.: Phil. Trans. Roy. Soc., B 207: 247, 1916.
6. Katz, L. N., and Ackerman, W.: J. Clin. Investigation 11: 1221, 1932.
7. Kountz, W. B., Prinzmetal, M., Pearson, E. F., and Koenig, K. F.: Am. Heart J. 10: 605, 1935.
8. Kountz, W. B., Prinzmetal, M., and Smith, J. R.: Am. Heart J. 10: 614, 1935.
9. Kountz, W. B., Prinzmetal, M., and Smith, J. R.: Am. Heart J. 10: 623 1935.
10. Abramson, D. I., and Weinstein, J.: Am. J. Physiol. 115: 569, 1936.
11. Katz, L. N., and Korey, H.: Am. J. Physiol. 111: 83, 1935.
12. Katz, L. N., Gutman, I., and Ocko, F.: Am. J. Physiol. 116: 302, 1936.
13. Lewis, T.: The Mechanism and Graphic Registration of the Heart Beat, New York, ed. 3, 1925, Paul B. Hoeber, page 216.

DISPLACEMENT OF THE ESOPHAGUS BY CARDIAC LESIONS OTHER THAN MITRAL STENOSIS*

ANDREW BABEY, M.D.†
BROOKLYN, N. Y.

THE advantage of radiological study of the left auricle in the first (or right) oblique position, with barium in the esophagus, is established by the literature which has slowly accumulated on the subject.[2, 24, 29] It is especially serviceable in the diagnosis of mitral stenosis. Yet in this clinic we have been impressed by other forms of heart disease which may cause backward displacement of the esophagus similar to that resulting from mitral stenosis but without the same significance in diagnosis. The conditions most commonly found to give rise to confusion are *congenital heart disease, aortic stenosis and incompetence,* hypertensive heart disease, auricular flutter and fibrillation, and heart-block. Rarely, a cardiac aneurysm has a similar effect.

These observations deal only with alterations in the barium-filled esophagus as seen in the first (right) oblique position, i.e., with the patient turned about 45° to the left with the *right* shoulder toward the screen. Occasionally rotation to 60° to 80° shows displacement better than rotation to 40° to 60°. For visualization of the esophagus citobaryum of the consistency of thin paste was used. Radioscopy was used as a preliminary in all cases and teleradiograms were then taken in the standing posture during full inspiration, though this does straighten out the esophagus and tends to diminish any curvature present.

ANATOMY

There are five important structures which may affect the contour and position of the esophagus (Figs. 1, 2). From above downward, they are the aortic arch, the pulmonary artery (with the left bronchus), the left auricle, the left ventricle, and the descending aorta, which impinges on the esophagus as the latter crosses in front of the aorta before penetrating the diaphragm. No attempt beyond certain necessary generalizations will be made to review the detailed anatomy. For this we refer the reader to the work of Parkinson and Bedford[19] and Evans,[10] and for the topographical anatomy, to Corning,[6] particularly his Figures 248, 249, 253, and 307. The right auricle, even when massive (Fig. 3), does not appear to press upon the esophagus, nor has the right ventricle any direct relation with it. The left auricle (or atrium) constitutes the major portion of the posterior aspect of the

*From the Cardiac Department of the London Hospital; Dr. John Parkinson, Chief.
†Bowen Scholar, New York Academy of Medicine.

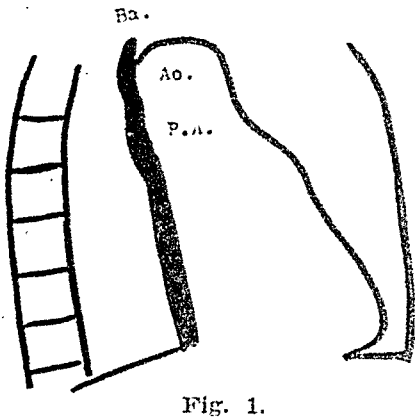

Fig. 1.

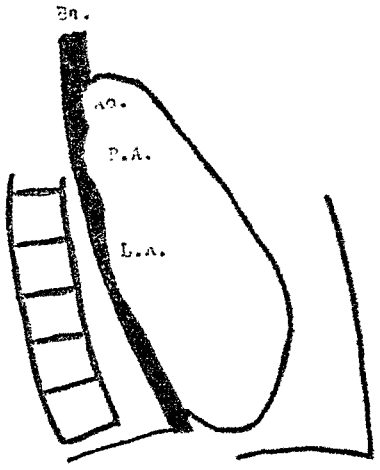

Fig. 2.

Fig. 1.—Course of normal esophagus in man, aged forty-four years, with no heart disease. Note straight descent of esophagus below pulmonary artery (left bronchus) impression.

Ao., aortic impression; *P.A.*, pulmonary artery (left bronchus) impression; *Ba.*, barium-filled esophagus.

Fig. 2.—Normal straight descent of esophagus in male, aged nineteen years, with no evidence of heart disease. A left auricular impression similar to this is occasionally seen in normal patients. There is no displacement of the esophagus.

L.A., left auricular impression. Other abbreviations same as in Fig. 1.

Fig. 3.—Massive right auricle in male, aged thirty-eight years. Necropsy proof. No deviation of the esophagus in first (right) oblique position.

heart, and it is to changes in its size or position or both that alterations in the esophagus are to be attributed (Fig. 4). According to Rigler,[25] the posterior portion of the left ventricle is in contact low in the thorax with the anterior wall of the esophagus over a distance of about 2-3 cm. Evans[10] feels, however, that it is rare for the left ventricle of a healthy subject to make contact with the esophagus. In heart disease associated with a large left ventricle this contact is not uncommon, as will be shown, and it produces an impression situated below that caused by a large left auricle.

CONGENITAL HEART DISEASE

Congenital heart disease, as noted by Paterson[22] and by Brown and McCarthy,[4] very infrequently affects the position of the esophagus. In our series, three cases were found presenting backward deviation of the esophagus. One patient had coarctation of the aorta, a large left ven-

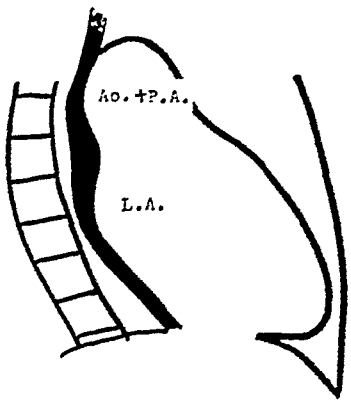

Fig. 4.—Mitral stenosis and aortic incompetence in female, aged twenty-six years. Note combined aortic and pulmonary artery (left bronchus) impression and sharp angulation caused by left auricle. Prominent conus.

tricle and striking deviation of the esophagus (Fig. 5); the second had a patent ductus arteriosus, large heart (Fig. 6) and a slight general bend in the esophagus; the third had an interatrial septal defect. The patient with coarctation of the aorta came to necropsy and a massive left ventricle and normal left auricle were found, though the x-ray appearance suggested a large auricle. The congenital lesion which most readily deforms the esophagus like mitral stenosis is interatrial septal defect. Rösler's case[28] presented a curve in the barium-filled esophagus exactly like that of mitral stenosis, and at autopsy the left auricle was enlarged. Dr. Hoyle and Dr. Stibbe have kindly lent me records of a patient with congenital heart-block and interatrial septal defect in which the deformity of the esophagus was remarkably like that produced by mitral stenosis (Fig. 7). At necropsy the left auricle was found to be much enlarged.

mitral stenosis was entertained. In one instance of pure aortic stenosis there was slight, gentle, backward displacement of the esophagus (Fig. 8). Another similar case was seen recently. Aortic stenosis was present, and the left auricle was moderately enlarged by radioscopy. Death followed an attack of scarlet fever; at necropsy the mitral valve was normal, advanced aortic stenosis was present and the left auricle was moderately enlarged.

AORTIC INCOMPETENCE

There is an occasional reference in the literature to displacement of the esophagus by the large heart of aortic incompetence.[15, 26, 32] White[30] has described a case of pure aortic insufficiency of rheumatic origin in which the esophagus was displaced to the right on anterior view. At necropsy an enlarged left auricle was found, due, according to White, to the chronic failure of the left ventricle. Hinterreger's case[14] was

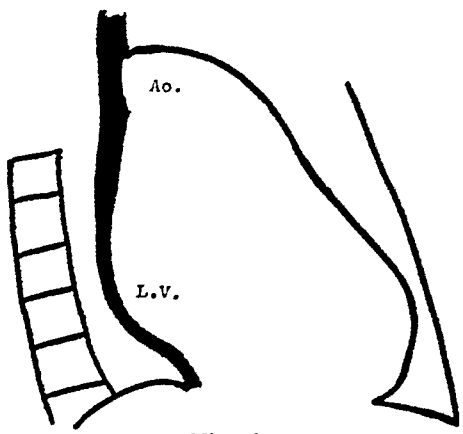

Fig. 9.

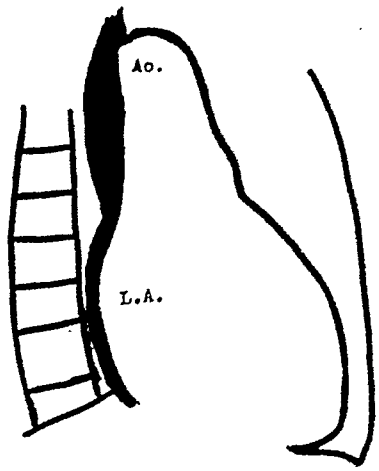

Fig. 10.

Fig. 9.—Syphilitic aortic incompetence in male, aged sixty years. Blood pressure, 170/80. Wassermann reaction, positive. Slow backward deviation of esophagus with a more sharp angulation lower down over the region of the left ventricular impression.

Fig. 10.—Aortic incompetence, probably syphilitic, in male, aged sixty-three years. Gradual backward shift of esophagus, the change occurring appreciably below the usual site of the pulmonary artery (left bronchus) curve which is not seen here.

one of syphilitic aortic insufficiency with marked stenosis of the esophagus. At necropsy there was moderate dilatation of the left auricle as well as a large left ventricle.

In this clinic we have noted several examples of backward shift of the esophagus in patients with aortic insufficiency in whom there was no fibrillation, no congestive failure, nor any evidence of mitral disease (Figs. 9 and 10).

HYPERTENSION

Kovács and Stoerk,[15] Brown and Reinecke,[5] and others recognized that some abnormality in the course of the esophagus might be seen in advanced hypertension, but pointed out its slight character com-

THYROTOXICOSIS

Uncomplicated thyrotoxicosis may, if severe and of long standing, modify the shape of the heart and cause slight enlargement, especially in the area of the pulmonary conus, so that in the anterior view the heart may resemble that of mitral stenosis. However, the left auricle in the first oblique position is not enlarged,[17, 20] though Meyer-Borstel[16] reported a regular increase in its size which made it difficult or impossible to exclude mitral stenosis. It is in the group of cases designated thyrotoxic hypertension by Parkinson and Hoyle[21] that alterations in

Fig. 13.

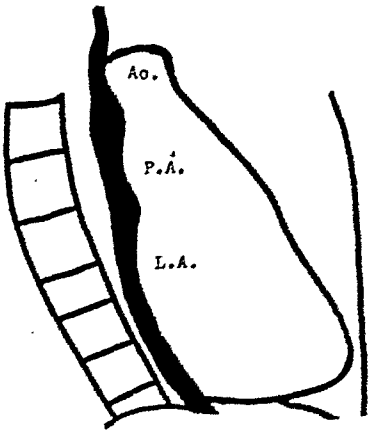

Fig. 14.

Fig. 13.—Auricular fibrillation for nine years in male, aged sixty-two years. Displacement of esophagus over region of left auricle. Very little change in early films.

Fig. 14.—Auricular flutter for three years in male, aged seventy-two years. Normal rhythm for ten months. Prominent left auricular bulge beginning sharply below the pulmonary artery (left bronchus) curve. Heart not much enlarged.

position of the barium-filled esophagus may occur. If, in addition to a large left ventricle, fibrillation or failure, or both, are present, the displacement of the esophagus may be very striking and somewhat suggestive of mitral stenosis (Fig. 15).

It is important in thyrotoxic hypertension to exclude the presence of mitral stenosis. On physical examination this may occasionally be difficult, for both hypertension and thyrotoxicosis may cause deceptive signs at the apex. It is in such cases that a study of the barium-filled

placed. Bedford (personal communication) had a similar case in which barium studies showed a marked displacement of the esophagus, as in mitral stenosis. An aneurysm of the heart may also affect the esophagus directly as in the case reported by Wolferth and Wood.[31] In their patient radioscopic study showed "slight obstruction to the passage of barium in the lower end of esophagus," which was ascribed to pressure of an extremely enlarged heart. At autopsy "a large aneurysm protruded from the posterior surface of the left ventricle."

COMMENT

The explanation of the changes in esophageal contour and position herein described rests partly on increase in size of the left ventricle, partly on increase in size of the left auricle, and partly on displacement backward of a normal or hypertrophied left auricle. Occasionally, as in one case of aortic insufficiency, the large left ventricle alone causes a depression low down in the course of the esophagus which is not difficult to interpret. Occasionally, as in hypertension, the left auricle, taking part in the general cardiac enlargement, causes an abnormal impression on the esophagus. If, as not infrequently happens, the left ventricle is very large, it displaces backward this hypertrophied left auricle to cause either a more prominent depression over the area of the left auricle or a more diffuse displacement over the region of the left auricle and left ventricle. If fibrillation of the auricles or pulmonary congestion is present, these are other factors making for greater prominence of the left auricular impression. We may expect low indentation, a middle indentation or a diffuse, slow, general curve, depending on how many factors are playing a part. The low curve is easy and the general curve usually not difficult to distinguish, for it is not abrupt or sharp in its origin as in mitral stenosis. The middle curve, where the pulmonary veins and left auricle play the chief parts, is most difficult and frequently quite impossible to distinguish, for the deviation of the esophagus may be exactly as in mitral stenosis. Particular attention must then be paid to absence of a prominent pulmonary conus and absence of the square-shaped heart so common in mitral stenosis. All available evidence must be properly appraised before a diagnosis is made.

In the nonvalvular, nonhypertensive cases with backward displacement of the esophagus other phenomena explain the curve. Fibrillation and flutter place a special strain on the auricles, which may dilate and produce a bulge in the esophagus. Interatrial defect may mechanically do the same thing and the picture closely simulate mitral stenosis. In heart-block general increase in heart size, with ballooning of the left auricle, explains the backward deviation. Aneurysm of the heart produces its effect directly, when it is due to a posterior infarction, or indirectly when it is an anterior infarction.

Department of Reviews and Abstracts

Selected Abstracts

Liddell, E. G., and Carleton, H. M.: Dietary and Emotional Factors Affecting the Blood Pressure of Cats, Observed by Exteriorization of the Carotid Artery. Quart. J. Exper. Physiol. 26: 155, 1936.

Cats are naturally better subjects for experiments on the physiological effects of meat and liver than rabbits because they retain such food much better and are able to store protein rapidly in their muscles. An operative procedure is described for exteriorizing the carotid artery of cats. The effect on the blood pressure of feeding cats raw meat has been studied in some animals for as long as twenty months. During the time of observation there was no permanent rise in blood pressure after a raw meat diet. The effect of emotion and hunger on the blood pressure was much more marked than the effect from a raw meat diet.

E. A. H.

Hoff, E. C., and Green, H. D. Cardiovascular Reactions Induced by Electrical Stimulation of the Cerebral Cortex. Am. J. Physiol. 117: 411, 1936.

The blood pressure and heart rate were recorded by mercurial and optical manometers during the stimulation of the cerebral cortex of forty cats, eighteen monkeys, and one chimpanzee under light ether anesthesia. The data obtained indicate that there is a cortical mechanism which can influence the state of the cardiovascular system and that the organism may bring this into play to make adjustments in the activity of the heart and circulation. That these responses are initiated by stimulation of nerve elements in the cortex is indicated by the fact that pressor and depressor points were localized within 3 or 4 mm. of each other; local anesthesia abolishes the responses. Undercutting of the stimulated area eliminates responses from this area and removal of the overlying cortex with subsequent degeneration of the underlying efferent fiber tracts prevented vasomotor responses from stimulation of these tracts. The effects can be elicited in noncurarized animals and epileptiform changes of muscular response are observed to occur without changes in blood pressure.

E. A. H.

Udvardy, L.: Changes in Form and Size of the Heart in Pulmonary Disease—Pulmonary Sclerosis. Fortschr. a. d. geb. d. Röntgenstrahlen 52: 115, 1935.

Bronchial asthma and chronic pneumonia, by destroying alveoli, increase pulmonary arterial pressure and cause hypertrophy and dilatation of the right heart. In emphysema the heart at first looks smaller because of the inspiratory position of the diaphragm. Later the right heart becomes enlarged, and then both sides of the heart are enlarged to give a picture resembling the heart in mitral disease.

Pulmonary sclerosis occurs often in emphysema. Pulmonary sclerosis may be primary or secondary. The heart appears bullet shaped, and the pulmonary bow

Nathanson, M. H.: Pathology and Pharmacology of Cardiac Syncope and Sudden Death. Arch. Int. Med. 58: 685, 1936.

Structural changes in the heart are usually inadequate to explain either temporary or fatal cardiac syncope.

There are two physiological mechanisms in the heart which may cause sudden cessation of the circulation: (1) cardiac standstill and (2) ventricular fibrillation. In the present study it was possible to manipulate the human cardiac mechanism (1) mechanically, producing cardiac standstill by reflex vagus stimulation, and (2) chemically, inducing a prefibrillation state in the ventricles by sympathetic stimulation with epinephrine administered intravenously. It has been demonstrated that both of these physiological states may be definitely modified by drugs.

Drugs of the epinephrine series in proper dosage will prevent cardiac standstill.

Prefibrillation rhythm may be prevented by the use of quinidine or of acetyl-beta-methylcholine.

Protection of the sympathetic nervous mechanism by general measures is indicated.

These studies suggest an approach by drug therapy and by general measures toward the prevention of cardiac syncope and sudden death.

AUTHOR.

Steinberg, Bernhard, and Mundy, Carll S.: Experimental Pulmonary Embolism and Infarction. Arch. Path. 22: 529, 1936.

The introduction of a large number of emboli into the pulmonary arterial tree of a dog is not followed by any untoward symptoms nor is it incompatible with life, at least over one and one-half years, the maximum period of observation in these experiments. As much as 79 per cent of the dog's total lung by weight can be deprived of its pulmonary arterial circulation without causing death of the animal. The obstruction produced in these experiments was not of the main pulmonary trunk (as with other investigators) but of the branching tree of the arteries. As far as the dog is concerned, under the conditions of our experiments there is no justification for the concept that multiple emboli as such cause either immediate or delayed death by their presence in the lung or by a reflex.

Iodized oil injected into the pulmonary arteries of a living animal outlines the arterial tree and determines the areas of the lung to which the circulation is shut off. Apparently, because of the extensive vascularity of the lungs, emboli do not close the blood supply unless they are introduced in fairly large numbers. A small number of emboli may, however, interfere in part with the circulation to a given area of the lung. The mere introduction of foreign bodies into the pulmonary arteries should not lead to the assumption that an infarct must develop at the site of embolism.

The lung tissue deprived of its pulmonary blood supply shows some restoration after a period of three or more weeks. The pulmonary arteries in the areas of infarction become visualized on injection of iodized oil, and canalization and newly branching arteries become more profuse with time.

The bronchial circulation may be outlined by injection of iodized oil in a living animal. In a normal dog the bronchial arteries are very indistinctly outlined. In infarcted areas the bronchial vessels are well visualized, denoting dilatation. It is assumed that the dilated bronchial circulation is responsible for the failure of infarcts of the lung to proceed to complete necrosis and scar formation. The bronchial arteries dilate irrespective of the size, location, or multiplicity of infarcted areas.

Grossly and microscopically all the criteria of hemorrhagic infarcts are present in the lungs of dogs with sufficient emboli to produce complete obstruction of the

photoelectric cell and a moving picture is projected. This method is useful for teaching since the student synchronizes auditory and visual images and can thus correlate the sounds with the electrocardiogram.

L. N. K.

Sikl, H.: Eosinophilic Myocarditis—An Idiosyncratic Allergic Disease. Frankfurt. Ztschr. f. Path. 49: 283, 1936.

This is a case report of a thirty-six-year-old woman in whom a severe dermatitis developed following the use of bismuth and neosalvarsan in treating a possible case of syphilis. At autopsy a diffuse myocarditis was found with an unusually marked eosinophilic infiltration. Necrosis, tuberculoid nodules, and numerous myogenic "Riesen" cells were found. A second similar case of a twenty-two-year-old man with primary syphilis is also reported. No tubercle bacilli or spirochetes could be demonstrated. The author believes that this condition is not a flare-up of syphilis but an idiosyncrasy to salvarsan in the nature of an allergic reaction. The literature is thoroughly reviewed.

L. N. K.

Sohval, Arthur R., and Gross, Louis: Calcific Sclerosis of the Aortic Valve. Arch. Path. 22: 477, 1936.

There have been described in this report the findings in eighteen hearts with so-called Monckeberg's calcific sclerosis of the aortic valve, in nineteen hearts with a grossly polyvalvular extinct rheumatic process, and in thirteen hearts with a grossly monovalvular extinct rheumatic process. Attention is drawn to the essentially different gross and microscopic features of the Monckeberg and rheumatic valvular lesions. It has been shown that the heart with the uncomplicated Monckeberg process shows practically none of the stigmas of extinct rheumatic fever and no other evidence which would indicate that the process is secondary to inflammatory changes. A discussion is given of the possible mechanisms concerned in the development of the essential Monckeberg process, from which it appears that this is purely and primarily degenerative, its occurrence and extent depending in all probability on individual predisposition to collagen involution and lipoid and calcium deposition. The findings in three hearts with submarginal aortic commissural bridging of noninflammatory nature suggest that stress and strain in the aortic valve may serve as additional factors predisposing to degenerative processes. It is suggested that in certain persons in whom there exists a predisposition toward the deposition of lipoid and calcium, inflammatory lesions with subsequent deformity of the aortic valve may impose sufficient strain on the valve to initiate the Monckeberg process.

AUTHOR.

Gross, Louis, and Friedberg, Charles K.: Nonbacterial Thrombotic Endocarditis: Classification and General Description. Arch. Int. Med. 58: 620, 1936.

A study was made of one hundred fifty cases with autopsy in which the condition was diagnosed anatomically as indeterminate, terminal, or thrombotic endocarditis. In forty-seven cases there was microscopic evidence of fresh thrombotic vegetation, with little or no recent valvular reaction, without bacteria and without associated clinical or pathological evidence of recent rheumatic infection or of atypical verrucous endocarditis. The condition was termed "nonbacterial thrombotic endocarditis." The remaining one hundred three of the original one hundred fifty cases considered were discarded because careful histological

This report deals with one of these groups, comprising four cases, in which the disease was characterized by prolonged fever, polyarthritis, inflammation of serous membranes (pleura, pericardium, peritoneum, endocardium, and synovial membrane), and a variety of vascular lesions.

The clinical course was that of a general infection, but cultures of the blood were sterile. The onset was marked by inflammatory polyarthritis involving the large and small joints. Ankylosis and deformities developed in two of the four cases. There were pleural and pericardial effusions. Symptoms of endocardial involvement were indefinite. Symptoms of renal and cerebral involvement were frequent. The differential diagnosis lay between a general infection, subacute bacterial endocarditis, rheumatic fever, and tuberculosis.

At necropsy there were adhesive pleuropericarditis with obliteration of the pleural and pericardial cavities; an excessive quantity of fluid in the peritoneum; perihepatitis, and perisplenitis, with adhesions between the liver and the diaphragm, between the spleen and the diaphragm, between the intestines, and between the parietal and the visceral peritoneum. The synovial membranes, in the two cases in which these were available for examination, were thickened and edematous and showed marked endothelial hyperplasia and cellular inflammation with occasional perivascular infiltrations. The heart showed nonbacterial thrombotic deposits on one or more of the valves. There was no evidence that these were of rheumatic origin. There were a variety of vascular lesions in many organs, including endothelial proliferation, endothelial desquamation with granular degeneration and swelling, narrowing or obstruction of the lumen by plugs, intimal proliferation, and actual necrosis of the vessel wall.

The clinical and pathological features suggested that some infectious agent with a pronounced toxic effect on structures lined by endothelium was being dealt with.

AUTHOR.

Segura, A.: Registration and Interpretation of Cardiovascular Activity in the Normal Infant. Rev. argent de cardiol. 3: 167, 1936.

The following heart rates (average and probable error) have been found according to age:

Within the first week, 150 ± 1.97; between nine and thirty days, 167 ± 3.37; from thirty-one days to three months, 154 ± 4.24; from the third month up to the sixth month, 155 ± 2.36; from the sixth month up to one year, 140 ± 2.63; from one to two years, 138 ± 6.59.

There are no significant differences between any two successive groups (except between the fourth and fifth), but there are if two separate groups are compared.

This shows that the heart rate decreases as the infants grow, and also that within the first week the rate is comparatively slower.

The phases of the cardiac cycle: According to age, the cardiac systole lasts between 0.205 ± 0.010 and 0.236 ± 0.008 sec., with a tendency to increase as the infants grow older. The following formula, modified from Lombard and Cope, allows a prediction of the duration of the systole when the heart rate is known:

$$S = 0.025 + \frac{60}{26\sqrt{R}}$$

S being the duration of the systole and R, the heart rate.

The S/C ratio is higher in infants than in adults showing a comparatively longer systole in the former. The ejection phase lasts 0.174 ± 0.004 between one and three months of age; 0.171 ± 0.0002 between six and twelve months; and 0.186 ± 0.008 between one and two years.

Findlay, F. M.: Hypertension: Its Surgical Approach. California & West. Med. 45: 334, 1936.

The important factors which appear to operate in the production of hypertension are discussed. The various types of surgical procedures used for the treatment of hypertension and the probable results to be expected from each operation are described. A modification of surgical procedures is suggested, based upon the author's past experience and facts concerning the autonomic nervous system.

E. A. H.

Smith, Beverly C.: Relief of Pain by Peripheral Nerve Block in Arterial Diseases of the Lower Extremities. Ann. Surg. 104: 934, 1936.

Forty-six cases of occlusive arterial disease, including patients with arteriosclerosis with and without diabetes mellitus or with thromboangiitis obliterans, were treated by peripheral nerve block in the lower third of the leg. Pain was entirely relieved in 97 per cent of the patients with thromboangiitis obliterans, 90 per cent of the patients with arteriosclerosis without diabetes mellitus, and 81 per cent of the patients with arteriosclerosis with diabetes. In three cases the nerve block was repeated for recurrence of painful ulceration, with satisfactory relief of pain. In only three cases was healing of the wound delayed. Paralysis of the intrinsic muscles of the foot has not interfered with normal locomotion, but this weakness necessitates the subsequent use of properly fitted shoes with corrected weight-bearing. The relief of pain prevented the necessity of a major amputation in 50 per cent of the patients with arteriosclerosis and in 20 per cent of the patients with arteriosclerosis with diabetes. No amputations were performed in the group with thromboangiitis obliterans.

E. A. H.

Andrus, Frank C.: The Relation of Age and Hypertension to the Structure of the Small Arteries and Arterioles in Skeletal Muscle. Am. J. Path. 12: 635, 1936.

The degree of fibrosis of the media of small arteries and arterioles was studied in specimens of pectoral muscle taken from 137 individuals. The degree of fibrosis was most marked in cases of severe hypertension. There was a somewhat greater average amount of fibrous tissue in the walls of the arterioles in hypertensive than in nonhypertensive patients of the same age. All patients with hypertension did not show marked fibrosis. No cases of marked fibrosis were seen before the twenty-ninth year of life. After that age it was encountered with increasing frequency. It was not possible to distinguish between hypertensives and control patients by the degree of fibrosis found.

H. M.

Short, James J., Bruger, Maurice, and Jaffe, Louis: Production of Intimal Changes in the Arteries Attempted in the Rat by Prolonged Feeding of Aceto-acetic Acid. Arch. Path. 22: 543, 1936.

It appeared important to learn whether an excess of acetone bodies in the blood, as frequently occurs in diabetes, is a factor in softening the intimal cement substance, thereby favoring the imbibition and deposition of lipoids, particularly cholesterol esters. Reasoning from the results on eight rats fed aceto-acetic acid, and from six controls, ketosis is probably not a factor in altering the structure of the intima.

H. M.

changes in blood flow were made. In the 3 cases in which venous filling time was measured before and after treatment, there was objective evidence of increase in blood flow. In the one case reported, there was a rise in skin temperature of 4° F.

H. M.

Böger, A., and Wezler, K.: The Central Position of the Pressure-Equalizer ("Windkessel") in the Circulation. Klin. Wchnschr. 15: 1185 and 1241, 1936.

The authors restate their conclusion, based on previous work, that the contraction of smooth muscle in the larger muscular arteries lowers the modulus of elasticity —that is to say, makes the artery more distensible. This statement is necessary for an understanding of the present problem which is concerned with changes in the effective or functional size and position of the pressure equalizer or elastic reservoir *(windkessel)* of the circulation, which includes, as has been known since the time of E. H. Weber (1850), the aorta and the first portions at least of the primary branches. A lengthy, rather involved, discussion of the theoretic considerations involved in calculating the effective *(wirksam)* length of the elastic reservoir follows. The length (L) is taken as $\frac{\lambda}{4}$ where λ is the fundamental wave length of the arterial system. λ is obtained by multiplying the velocity of transmission of the pulse along the aorta by the duration of the wave as recorded in the femoral pulse by a Frank capsule. The duration of the wave or the period of oscillation shows itself in reflected waves superimposed upon the pulse wave and is identical in length for any individual whether measured in the carotid or femoral pulse. Furthermore, the modulus of elasticity (η) = Velocity^2 multiplied by the specific gravity of the blood and the effective coefficient of elasticity of the pressure equalizer can then be considered as $\frac{\eta}{V}$ wherein V is the volume of the pressure equalized obtained as the product of the cross-section of the root of the aorta and the effective length as calculated from the equation given above.

Pulse wave tracings were obtained simultaneously from the carotid, femoral, and radial arteries followed immediately by blood pressure readings in many individuals of various ages and sizes, after the intravenous administration of adrenalin and sympathol, and in a few patients with hypertension. The pulse wave velocities, effective lengths, and coefficients of elasticity of the pressure-equalizer were calculated.

The conclusions follow:

A. The decrease in distensibility of the predominantly elastic part of the arterial system which is known to occur with increase in blood pressure and with age is compensated for by several other simultaneous changes.

1. Increase in size (length and cross-section) of the pressure-equalizer; in youths the length extends to 10 cm. above, in elderly persons to 10 cm. below Poupart's ligament.

2. Contraction of the smooth muscle in the portion included in the pressure-equalizer which increases its distensibility; this is exemplified by the small decrease in distensibility observed to follow sympathol, as compared to the large decrease following adrenalin. It is assumed that sympathol exerts a more powerful constrictor action on smooth muscle. It is this contraction which preserves the distensibility of the pressure-equalizer (aorta and large branches).

These two factors serve to make possible the small changes in blood pressure in relation to the large increase in rigidity of the peripheral arteries as age advances.

arteries of the extremities. It also followed ligation of the coronary arteries and was due, they believed, to stimulation of the periarterial nerves. The assay of acetylcholin was carried out by injection of the substance to be tested into a leech sensitized with physostigmine.

In the present study increase in the amount of acetylcholin was found to occur in the brain stem and in cisternal fluid following the same procedure. It was also shown (1) that previous injection of ergotamine prevented the increase, (2) that the increase in acetylcholin occurred following the injection of adrenalin and tetrahydrox β-naphthylamine without stimulation of the aorta, and (3) that adrenalin is also liberated in the cisternal fluid following stimulation of the aorta. Their inference is that liberation of acetylcholin is secondary to the liberation of adrenalin by the aortic stimulus as a counterregulatory mechanism.

J. M. S.

Gay, L. K., and Hardesty, J. T.: Tests for Vasomotor Control. California & West. Med. 45: 331, 1936.

The various tests in current use for determining vasomotor control are described. Indirect methods of observation on the peripheral vessels include examination of peripheral pulse, postural color changes, blood pressure determination, cutaneous histamine reaction, the plethysmograph, and reactive hyperemia. Useful tests for direct observation of the peripheral vessels are surface temperature studies, tobacco test, overcooling, cold stimulation test, immersion of the forearms in warmed water, blanket method of Coller and Maddock, induction of artificial fever, the oscillometer, spinal anesthesia, and arteriography. The method of carrying out each test is described in detail.

E. A. H.

Moore, John W., and Kinsman, J. Murray: Studies on the Circulation: The Dye Injection Method. J. Lab. & Clin. Med. 22: 165, 1936.

In ten cases with apparently normal cardiovascular systems, the hemodynamics was studied before, and twenty-four hours after, the oral administration of from 1 to 1.2 gm. of digitalis (digitora tablets).

By the use of the dye-injection output method, it was possible to determine simultaneously the velocity of blood flow, the flow per minute, the total circulating blood volume, the volume of circulating blood in the lungs and heart, the cell volume, and the specific gravity of the plasma. It was possible also to obtain almost at the same time, and certainly without any change in position of the patient, the venous and arterial blood pressures, the vital capacity, and the cardiac silhouette area.

In all of the factors studied, it was found that digitalis may cause an increase, a decrease, or no change at all in the individual values. The median of any group may show a decided trend; nevertheless the spread about the initial normal was prominent. This was particularly true of the venous pressure and flow per minute. In the former the median value was 60 per cent of the initial normal, whereas one patient was 150 per cent of the initial normal; in the latter, the median value was 88 per cent of the initial normal, whereas one patient was 121 per cent of the initial normal. When the venous pressure and the flow per minute are plotted against each other, there exists a fairly close linear relationship in about 70 per cent of the cases.

There was evidence of some correlation between work and cardiac silhouette area, flow per minute and cardiac silhouette area, specific gravity of the plasma and the cell volume, and total circulating blood volume and the circulating blood

Recovery from the process of shock is associated with progressive improvement in the circulation of blood to the periphery. The therapy of surgical shock should be directed toward the reestablishment of an adequate supply of oxygenated blood to the body tissues.

AUTHOR.

Esser, C.: The Kymographic Appearance of the Cardiac Apex in Marked Dilatation. Fortschr. a. d. geb. d. Röntgenstrahlen 52: 213, 1935.

Normally, the author finds that the apex shows a larger systolic retraction than the base of the left ventricle. In pathological states, the reverse is true, and the apex in addition later actually shows systolic expansion. This latter type the author found in 27 of the 350 records of marked dilatation.

L. N. K.

Battro, A., and Menendez, E. Braun: Radiokymography in Total Auriculoventricular Block. Rev. argent de cardiol. 3: 199, 1936.

Roentgenkymography allows a study of the volume changes of each cardiovascular segment, its application being particularly fruitful in cases of heart block.

The main radiokymographic features of the left ventricle, right auricle, median arch, vena cava, and aorta in three cases of complete A-V block are here described. They show (1) that the filing of the ventricle is definitely influenced by auricular contraction and (2) that the c-wave of the venous pulse may be partially caused by an aortic impact since the influence of the aortic pulse can be observed on the superior vena cava.

AUTHOR.

Key, Eimar: Embolectomy of the Vessels of the Extremities. Brit. J. Surg. 24: 350, 1936.

By a modification of Carrell's method for embolectomy the author performed 48 embolectomies. The greater proportion of emboli were in the femoral, iliac, popliteal, and axial and brachial arteries. In most there was some degree of cardiac damage. Death occurred shortly after operation in five cases in spite of three's having improved circulation. Death occurred within a month in fourteen other cases in spite of four's having improved circulation. Ten cases had gangrene and lived for at least a month postoperatively. In the greater number of these cases an amputation was done. In nineteen cases the circulation was restored, the extremity saved from gangrene, and the patient lived. Twenty-four of the forty-eight embolectomies were performed within ten hours after the onset of symptoms; out of these nineteen regained normal circulation.

H. M.

Morawitz, P.: Medicinal Therapy in Undecompensated Heart Muscle Disease. Deutsche med. Wchnschr. 61: 1, 1935.

Digitalis is useful only in heart failure. The prophylactic use of digitalis prior to operation in a healthy heart does no harm but is to be avoided in elderly subjects with coronary sclerosis. The author questions the value of Christian's suggestion that all individuals with degenerative heart disease get protracted small doses of digitalis. Digitalis therapy should be individualized. Digitalis should be used only in auricular fibrillation with a rapid ventricular rate and not when the ventricle beats slowly. It should be used cautiously for extrasystoles and in heart block. Digitalis is not very effective in hyperthyroid states. Digitalis should be used to meet definite needs and not for heart disease!

Book Reviews

ATLAS OF CONGENITAL CARDIAC DISEASE. By Maude E. Abbott, B.A., M.D., F.R.C.P. (Canada), McGill University, Montreal, Canada. 72 pages containing frontispiece and 25 plates embodying over 200 figures with descriptive text forming a volume 11 × 14 inches, bound in cloth. Published by the American Heart Association, New York, N. Y., August, 1936, price $5.50.

This atlas is "a pictorial retrospect of the author's personal experience" in the field of congenital heart disease. Part I—a small section—deals with the development and comparative anatomy of the heart. The remainder, Part II, entitled "Clinical Classification of Congenital Cardiac Disease," presents the various defects arranged according to Dr. Abbott's classification of (1) acyanotic, (2) cyanose tardive, and (3) cyanotic groups.

Half the space is devoted to illustrations and the remainder is nearly equally divided between brief discussions of the cardiac defects and legends explaining the figures. For example, in the presentation of patent ductus arteriosus, there is a page of text and a page of figures facing each other. The figures include schemata of normal and fetal circulation and that of patent ductus. There are also one x-ray picture, six orthodiagrams, an electrocardiogram, two drawings of the defect and a chart to show the auscultatory findings in detail. Thus, without even turning a page, one has presented clearly all the salient features, in a simple form, easy to remember. This general plan is followed throughout. At the end of the atlas Dr. Abbott's valuable chart, containing statistical data on congenital heart disease, based on an analysis of 1,000 cases, is reproduced.

In this atlas, Dr. Abbott has epitomized her monumental knowledge of congenital cardiac disease and has presented it clearly and simply in the combination of text and superb illustrations. The book is recommended to all with any interest in the subject of heart disease and should be in the library of the general practitioner as well as the specialist. It is destined to become a medical classic.

DISEASES OF THE CORONARY ARTERIES AND CARDIAC PAIN. Edited by Robert L. Levy, M.D., Professor of Clinical Medicine, College of Physicians and Surgeons, Columbia University; Associate Visiting Physician and Cardiologist, Presbyterian Hospital, New York City. Cloth. Price $6, 445 pages, New York, 1936, The Macmillan Company.

This timely and welcome volume represents a praiseworthy effort to present a comprehensive view of the present state of our rapidly growing knowledge of the coronary arteries and their diseases, as well as of the nature and mechanism of cardiac pain.

The book, edited by Dr. Levy, is the product of some fourteen contributors, each of whom is eminently qualified in his special field.

After a thoughtful introduction by A. E. Cohn and an interesting historical note by J. B. Herrick, there follows a detailed and authoritative consideration of the normal coronary circulation. The chapter on the anatomy of the coronary vessels is furnished by J. T. Wearn; those on the physiology and the pharmacology of the coronary circulation, by C. J. Wiggers and F. M. Smith, respectively; that on the pathology of the coronary arteries, by W. C. von Glahn.

ELEMENTS OF ELECTROCARDIOGRAPHIC INTERPRETATION WITH THIRTY-EIGHT PLATES ILLUSTRATING THE MORE IMPORTANT DEVIATIONS FROM THE NORMAL, SELECTED FROM THE FILES OF THE MICHAEL REESE HOSPITAL. By Louis N. Katz, A.M., M.D. Physiologist and Director of Cardiovascular Research, Michael Reese Hospital, Chicago; Assistant Professor of Physiology, University of Chicago; and Victor Johnson, Ph.D., Instructor in Physiology, the University of Chicago. Ed. 2, paper, price $1, the University of Chicago Press, Chicago, Ill.

The purpose of this booklet is to present a brief graphic outline of the more important electrocardiographic deviations from the normal. It is made up of thirty-eight plates, with full descriptive legends, and covers all the more important departures from the normal electrocardiograms. The descriptive legends are clear and easily understood. The booklet provides a concise and authoritative reference atlas for the practicing physician whose chief interests lie outside the field of electrocardiography and for the student beginning the study of cardiac physiology.

WILLIAM WITHERING: THE INTRODUCTION OF DIGITALIS INTO MEDICAL PRACTICE. By Louis H. Roddis, M.D., Commander, Medical Corps, United States Navy. 131 pages, 8 illustrations. Paul B. Hoeber, Inc. Medical Book Department of Harper & Brothers, New York, 1936.

The life and work of William Withering deserve more general appreciation and understanding of the medical profession than they have hitherto received.

This pleasantly written little volume merits a wide welcome, therefore, as making readily available the essential features of both the life and the work of a truly great physician.

Like so many other great English physicians of his period Withering won distinction in fields other than that of medicine. He would have been known as a distinguished botanist and mineralogist if his contributions to these sciences had not been overshadowed by his reputation as a practitioner and as the discoverer of the value of digitalis in medicine.

In reading his own statements as to the indications for the use of the drug, its method of administration, its limitations, and its possible dangers, one can but be amazed that so complete and so accurate an understanding of the drug should have been derived merely from the clinical observations of a single man.

"In spite of opinion, prejudice, or error, Time will fix the real value upon the discovery and determine whether I have imposed upon myself and others or contributed to the benefit of science and mankind." Time has spoken in no uncertain voice.

LA PRESSION MOYENNE DE L'HOMME A L'ÉTAT NORMAL ET PATHOLOGIQUE. By H. Vaquez and P. Gley. Masson et Cie., Paris, 1936. 126 pages with 57 figures. Price, 25 francs.

Believing that a proper understanding of the blood pressure can never be obtained from a study of the maximum and minimum pressures only, the authors have devoted much time and study to the mean arterial tension. They believe that the study of the mean arterial tension is important clinically as well as experimentally. They discuss the mean tension under normal and abnormal conditions and describe a syndrome, "hypertension moyenne solitaire." The greater part of the book is given over to a discussion of methods and tracings, the latter part to clinical applications.

Books Received

ESTUDIO FUNCIONAL DEL HIGADO AFECTADO POR EL ESTANCAMIENTO SANGUINEO EN LAS CARDIOPATIAS. Severo R. Amuchastegui. 166 pages, imprenta de las Universidad Nacional de Cordoba, 1936.

The American Heart Journal

Vol. 13 March, 1937 No. 3

Original Communications

THE VASCULAR COMPLICATIONS OF POLYCYTHEMIA*

Irvin L. Norman, Lieutenant, Medical Corps, United States Navy,
and
Edgar V. Allen, M.D.
Rochester, Minn.

POLYCYTHEMIA vera was first described by Vaquez[24] in 1892. As early as 1903, Osler[22] described it as a new clinical entity and recognized the frequency with which vascular complications occurred. These vascular complications are largely the result of an increased tendency to thrombosis resulting from a slowed circulation[2, 11, 13] in a vascular bed which is distended by the greatly increased blood volume. Another important factor may be increase in the number of platelets, and an increase in the serum calcium, shown by Brown and Roth,[6] may be a contributory factor. It is also possible that the intima is injured by a disturbed blood supply to it, or from excessive wear and tear by a fluid of increased viscosity, which Oppenheimer[21] believed may facilitate the formation of premature arteriosclerosis. Such changes in the intima naturally encourage thrombosis. Furthermore, most patients with polycythemia are at the age when arteriosclerosis is common. As will be pointed out subsequently, thrombosis may occur in vessels in many parts of the body, such as in the peripheral, cerebral, coronary, portal, hepatic, mesenteric, and splenic blood vessels. Such complications in polycythemia vera may frequently be the cause of death.

Parkes-Weber[24] in 1922 and Harrop[15] in 1928 reviewed the literature extensively. We have reviewed the literature dealing with vascular complication subsequent to 1928 only. Thrombosis of part of the splenic artery is the commonest cause of pain in the upper left quadrant of the abdomen in the presence of polycythemia. It occurs in a considerable number of cases during the course of the disease or during treatment with phenylhydrazine, as pointed out by Giffin,[12] and is a common finding at necropsy. The severe pain of mesenteric thrombosis may simulate

*From the Division of Medicine, the Mayo Clinic.

that of perforation of a viscus or that of cholecystic disease. Adams,[1] in a report of nine cases, described three in which intraabdominal thrombosis was noted; one patient underwent an exploratory operation twice for severe abdominal pain. Nothing was found but an acutely enlarged spleen, which probably was the result of splenic infarction. Roch and Epstein[28] reported a case of thrombophlebitis of the gastroepiglottic veins that simulated perforation of the stomach. Patients suffering from thrombosis of the portal or mesenteric veins frequently have ascites and enlargement and cirrhosis of the liver. Other reports dealing with thrombosis of intraabdominal vessels have been made by A. Jacobi,[17] Oppenheimer,[21] Cole,[8] Singer,[30] Cory[9] and Parkes-Weber.[25] In this connection, the suggestion first proposed by Lommel,[19] that stagnation of the portal circulation as a result of portal thrombosis may be the primary cause of polycythemia vera, should be mentioned. It is believed by most writers that ordinarily the causal relationships are reversed, and that thrombosis, when it occurs, is the result rather than the cause of polycythemia. However, Tumen[33] reported a case of polycythemia in which the patient was a negress. In this case there was occlusion of the inferior vena cava by a large uterine fibroid; he attributed the polycythemia to this occlusion. There was no evidence, however, of a causal relationship in this report, as the patient died soon after the operation, before observation could be made relative to the permanency of the polycythemia. Poll[27] reported a case in which the clinical findings were of pulmonary thrombosis only; the patient was a woman, aged fifty-four years, who was receiving treatment for polycythemia vera and coincidental pyelonephritis. In this case, the polycythemia vera long preceded the pulmonary thrombosis, and in no sense was caused by it.

Coronary thrombosis does not appear to occur with as great frequency as does thrombosis in vessels of other organs. This may be due to the fact that stagnation is not as marked in the vessels of a muscular organ in active contraction as it is in vessels of a less active organ, even though other factors that increase the liability to clotting are operative. Oppenheimer[21] reported a case in which the clinical studies revealed coronary thrombosis with a pericardial rub, fever, leucocytosis, and electrocardiographic changes. Parkes-Weber[25] reported a case in which gout, migraine, and intracardiac thrombosis were observed. Christian,[7] Sloan,[31] and Adams,[1] in separate reports, have pointed out the frequency with which cerebral vascular accidents are the cause of neurological symptoms, and Elschnig and Nonnenbruch[10] reported a case in which embolism of the central artery of the retina occurred simultaneously with a cerebral vascular accident. Migrating phlebitis, according to Lüdeke,[20] frequently is a complication of polycythemia vera. He reported sixty cases of phlebitis, in ten of which there were definite evidences of polycythemia. Brown and Giffin[5] have pointed out the frequent occurrence

of complications in the peripheral vascular system. They reviewed 100 cases of polycythemia vera that had been observed at the Mayo Clinic from 1912 to 1929, and placed the cases with peripheral vascular complications into groups in which the symptoms simulated arteriosclerosis obliterans, thromboangiitis obliterans, erythromelalgia, and Raynaud's disease. Brown[3] emphasized that erythromelalgia may be a symptom of polycythemia vera, and Horton and Brown[16] described the association of thromboangiitis obliterans and polycythemia. It is interesting to note that Osler[23] in 1908 mentioned the fact that the "red painful neuralgias" of the extremities which occur in cases of polycythemia vera may simulate erythromelalgia. Other recent reports of peripheral vascular complications have been made by Oppenheimer,[21] Jacobi,[18] Sloan,[32] and Griffith.[14]

Geisbok's disease, or polycythemia hypertonica, has been considered to be a complication of polycythemia vera, but Rowntree, Brown, and Roth[29] believed it to be a coincidental association of hypertension and polycythemia vera. Peacock[26] found that in polycythemia vera the average values for the blood pressure of patients of different ages were not significantly raised above normal, and that there was no correlation between increased blood pressure and blood volume. Brown and Giffin[4] reached a similar conclusion in a study made in 1926.

Hemorrhage occurs often in polycythemia vera; epistaxis and excessive hemorrhage following alveolectomy are common. Hemorrhage from dilated esophageal veins may occur. That hemorrhage should be common in a disease in which the tendency to clotting is increased seems paradoxical until it is realized that great distention occurs in the vascular bed, which undoubtedly is the most important factor in the causation of hemorrhages. Harrop[15] believed that there may be a variability in the tendency to clotting, and that at one time a tendency to clotting, and later a tendency to hemorrhage, may be observed in the same case.

In our study we have followed the criteria of Rowntree, Brown, and Roth.[29] In a study of the volumes of whole blood and of blood corpuscles, they found normal standards of 80 to 100 c.c. for each kilogram of body weight, and a hematocrit value of 40 to 48. In polycythemia vera the blood volume, the volume percentage, the viscosity of the blood, the value for the hemoglobin, and the number of erythrocytes in each cubic millimeter of blood are increased. Similar changes are present in relative polycythemia, except that the blood volume is approximately normal.

POLYCYTHEMIA VERA

In the seven years between Jan. 1, 1929, and Jan. 1, 1936, ninety-eight cases of polycythemia vera were observed at the Mayo Clinic. In thirty-three, or approximately 34 per cent, vascular complications occurred. For purposes of study, these vascular complications were

classified as follows: with intraabdominal thrombosis, six cases; with diseases of the coronary arteries, five; with diseases of the cerebral vessels, six; with peripheral occlusive vascular disease, seven; with erythromelalgia and burning paresthesia, eight; and with vasospastic phenomenon, one case.

Polycythemia Vera With Intraabdominal Thrombosis.—Although intraabdominal thrombosis was suspected in all of these six cases, it was proved in only two (by necropsy in Case 3 and by operation in Case 5), as opportunities for direct observation of the intraabdominal vessels by necropsy or operation was afforded in none of the remaining cases in this series. However, the clinical history and findings were highly suggestive of intraabdominal thrombosis in all (Table I). Additional vascular complications were noted in Case 1 (erythromelalgia) and in Case 4 (hemiplegia).

CASE 3.—A white woman, aged fifty-four years, was admitted to the clinic May 13, 1934, because of an enlargement of the spleen which had been present for five years. Ten months prior to her admission, she had received treatment elsewhere for polycythemia vera; this treatment had consisted of the application of roentgen therapy to the long bones. Ten days prior to her admission, a severe pain had occurred in the left lower quadrant of the abdomen, and two days later rapidly increasing anasarca had developed.

Examination of the patient at the clinic revealed ascites, slight icteric tinting of the conjunctiva, and enlargement of the liver and spleen. There was acute tenderness over the spleen and in the left lower quadrant of the abdomen. The value for the blood pressure in millimeters of mercury was 170 for the systolic and 110 for the diastolic, and pitting edema of the legs was noted. Examination of the retinal veins revealed marked engorgement and cyanosis. The results from study of the blood may be noted in Table I. The blood volume for each kilogram of body weight was obviously low because of increased weight of the body due to ascites and edema. Urinalysis revealed a large amount of albumin, a few casts, and pus cells. The concentration of urea in the blood was normal, and that of bilirubin was 4.0 mg. per 100 c.c. of serum. Following a Congo red test, there was a 28 per cent loss of dye from the blood stream in one hour, which excluded amyloidosis as the cause of the albuminuria.

On May 16 abdominal paracentesis was carried out, and 1,450 c.c. of clear, straw-colored fluid was removed before it became bloody, at which time the operation was terminated. Injection of the ascitic fluid into a guinea pig did not produce evidence of tuberculosis. In spite of the administration of diuretics and supportive treatment, the condition of the patient became gradually worse, and she died May 20.

At necropsy there was 700 c.c. of hemorrhagic amber-colored fluid in the abdomen. The heart was enlarged, and weighed 325 gm. (calculated normal weight, 250 gm.), and there was generalized sclerosis of the coronary arteries. The spleen was enormously enlarged; it weighed 1,576 gm. (calculated normal weight, 150 gm.), and microscopic examination revealed chronic fibrous splenitis with reticular proliferation. Several branches of the splenic artery were plugged with organizing thrombi, and there were many small splenic infarcts. The liver weighed 2,560 gm. (calculated normal weight, 1,600 gm.), and canalized thrombosis of the hepatic veins was noted. Microscopic examination of the liver revealed marked acute passive congestion and

TABLE I

POLYCYTHEMIA VERA ASSOCIATED WITH INTRAABDOMINAL THROMBOSIS

CASE	AGE (YEAR) AND SEX	SYMPTOMS OF INTRAABDOMINAL THROMBOSIS	DIAGNOSIS	STUDIES OF THE BLOOD				
				HEMOGLOBIN, GM. PER 100 C.C. OF BLOOD	ERYTHROCYTES, MILLIONS, IN EACH C.MM. OF BLOOD	HEMACRIT READING	VISCOSITY OF WHOLE BLOOD	VOLUME OF BLOOD IN C.C. FOR EACH KG. OF BODY WEIGHT
1	F 61	Recurrent episodes of pain in upper part of abdomen associated with emesis of blood	Intraabdominal thrombosis?*	20.3	6.63	71	11.2	110
2	F 41	Pain in splenic region	Splenic thrombosis?	19.1	9.0	69	11.6	131
3	F 54	Ascites, edema of legs, hematuria	Thrombosis of hepatic veins†	17.5	6.03	66	7.0	117
4	M 42	Ascites and abdominal pain	Mesenteric thrombosis?‡	18.5	5.30	60	6.7	102
5	M 26	Severe abdominal pain projected to back	Mesenteric thrombosis proved by operation elsewhere	17.8	6.62	60	9.0	141
6	F 30	Ascites, nausea and vomiting	Portal thrombosis? Cirrhosis of liver?	17.6	5.82	56	6.9	119

*Erythromelalgia of right foot.
†Diagnosis made at necropsy.
‡Left hemiplegia.

TABLE II

POLYCYTHEMIA VERA WITH DISEASE OF CORONARY ARTERIES

CASE	AGE (YR.) AND SEX	SYMPTOMS OF CORONARY ARTERIAL DISEASE	DIAGNOSIS	STUDIES OF THE BLOOD				
				HEMOGLOBIN, GM. PER 100 C.C. OF BLOOD	ERYTHROCYTES, MILLIONS, IN EACH C.MM. OF BLOOD	HEMACRIT READING	VISCOSITY OF WHOLE BLOOD	VOLUME OF BLOOD IN C.C. FOR EACH KG. OF BODY WEIGHT
7	F 61	Pain in precordium and numbness of left arm	Angina pectoris*	16.9	4.5	50		71
8	F 69	Dyspnea on exertion; swelling of legs	Arteriosclerotic heart disease with congestive failure*†	17.2	5.8	59	7.0	108
9	M 53	Bilateral pain in thorax with extension down left arm, occurrence with exercise or rest; relief with amyl nitrite and nitroglycerin	Coronary sclerosis with angina pectoris‡	22.1	5.4	74	10.2	141
10	M 47	Pain in left side of thorax followed by dyspnea and ascites	Thrombosis of coronary arteries diagnosed elsewhere*	8.5	4.5		3.1	79.6
11	F 44	Exhaustion	Hypertensive and arteriosclerotic heart disease with auricular fibrillation	16.9	5.6	59	8.8	114

*Polycythemia diagnosed and treated elsewhere.
†Arteriosclerotic occlusion of dorsalis pedis arteries bilaterally.
‡Thrombosis of the coronary artery discovered at necropsy.

marked congestion in the sinusoids, with central atrophy of the hepatic cords. Many intrahepatic vessels were occluded by well-organized thrombi. The marrow of the ribs was packed with erythrocytes, but otherwise appeared normal.

Plycythemia Vera With Disease of the Coronary Arteries.—Two of the patients in this series had angina pectoris, and one of these had evidence of myocardial infarction which was discovered at necropsy (Table II). In one case, thrombosis of a coronary artery was diagnosed elsewhere; in one case there was evidence of arteriosclerotic heart disease; and in another case there was evidence of arteriosclerotic and hypertensive heart disease. In one case, an additional complication of absence of pulsations in the dorsalis pedis arteries was noted bilaterally.

CASE 9.—A white man, aged fifty-three years, was admitted to the clinic June 30, 1932, because of headaches, intolerance to heat, nervousness which had been present for the past four years, and episodes of severe substernal pain which had been present for the preceding four or five weeks. The pain, which had been severe and had occurred even while the patient was at rest, often during the day, had been situated in the left anterior and posterior walls of the thorax and had extended down the left arm.

Examination of the patient at the clinic revealed evidence of polycythemia. Several small adenomas were palpable in each lobe of the thyroid gland, and the spleen was enlarged and extended approximately 2½ inches (6.25 cm.) below the left costal margin. The results of studies of the blood may be observed in Table II. A roentgenogram of the thorax revealed that the heart was enlarged and that there was congestion at the bases of both lungs. An electrocardiogram revealed the presence of sinus tachycardia, with a rate of 96 beats each minute, left ventricular preponderance, inverted T-wave in Lead III, diphasic T-wave in Leads I and II, exaggerated P-waves, and notched QRS complexes in Leads II and III. A diagnosis of polycythemia vera and angina pectoris was made.

The patient was treated in the hospital with phenylhydrazine hydrochloride. The attacks of angina, which occurred with increasing frequency, were completely relieved by the administration of amyl nitrite and nitroglycerin, and the patient took about forty 1/100 gr. (0.0006 gm.) tablets of nitroglycerin daily. On July 25, after the patient had received 4.5 gm. of phenylhydrazine, the erythrocytes numbered 4,300,000 per cubic millimeter of blood; the hematocrit reading was 43.7 volume per cent; and the viscosity was 5.4. The patient died suddenly.

Necropsy revealed enlargement of the liver and spleen. Generalized fibrous scarring of the myocardium and generalized sclerosis of the coronary arteries were present. A thrombus of recent origin was found in the left coronary artery.

Polycythemia Vera With Symptoms of Cerebrovascular Disease.—Of the six patients in this group, five had histories suggestive of, or clinical evidence of, cerebrovascular hemorrhage or thrombosis. In one case the clinical history suggested spasm of a cerebral artery, although hemorrhage or thrombosis could not be excluded. In another case the additional vascular complication of thrombophlebitis affecting the left leg was present (Table III).

CASE 16.—A man, aged forty-four years, was admitted to the clinic Aug. 20, 1930, because of weakness, loss of deep sensibility and coordination of the muscles of the

TABLE III

POLYCYTHEMIA VERA WITH SYMPTOMS OF DISEASE OF CEREBRAL VESSELS

CASE	AGE (YR.) AND SEX	SYMPTOMS OF DISEASE OF CEREBRAL VESSELS	DIAGNOSIS	STUDIES OF THE BLOOD				
				HEMOGLOBIN, GM. PER 100 C.C. OF BLOOD	ERYTHROCYTES, MILLIONS, IN EACH C.MM. OF BLOOD	HEMACRIT READING	VISCOSITY OF WHOLE BLOOD	VOLUME OF BLOOD IN C.C. FOR EACH KG. OF BODY WEIGHT
12	M 64	Attacks of unconsciousness, and of numbness of right hand	Cerebral arteriosclerosis with thrombosis of left parietal region	18.8	4.89	63		133
13	M 47	Paralysis of right side of face and paresthesia of left side of face lasting one-half day	Cerebrovascular spasm	23.1	7.85		14.2	
14	M 54	Aphasia and right hemiplegia	Cerebrovascular thrombosis or hemorrhage*	21.6	7.24	76	12.8	216
15	M 48	Sudden paresthesia of left hand followed by partial paralysis of left hand	Cerebrovascular thrombosis or hemorrhage	22.1	6.93	80	9.2	147
16	M 44	Numbness and weakness of right hand and partial aphasia	Arterial thrombosis or hemorrhage in the left temporo-parietal area	25.0	6.45	73	10.6	139
17	M 60	Paralysis of right arm and hand, and aphasia; right homonymous hemianopia	Cerebrovascular hemorrhage or thrombosis	20.6	6.35	64	7.4	110

*Thrombophlebitis of the left leg.

right hand and forearm, which had been present for the past ten months, and on account of difficulty in speaking and poor memory, which had been present for the past four months.

Examination of the patient revealed evidence of polycythemia. The spleen and heart were enlarged. Results of studies of the blood may be noted in Table III. Examination of the eyegrounds revealed cyanotic and engorged veins. Roentgenograms of the thorax and head were normal. The Wassermann reaction of the blood was normal, and urinalysis did not reveal any abnormality. On neurological examination, motor and sensory aphasia, marked alexia and agraphia, and some apraxia were noted; the right arm was weak. The diagnosis was cerebral softening in the left parietotemporal region, caused by a vascular lesion. The patient was treated in the hospital with phenylhydrazine hydrochloride. During treatment the weakness of the right hand and the aphasia increased. Weakness of the right leg and a positive Babinski sign developed on that side. When 3 gm. of phenylhydrazine had been given, the concentration of hemoglobin was 95 per cent; erythrocytes numbered 6,920,000 per cubic millimeter of blood; the hematocrit reading was 60 per cent; and the viscosity of the blood was 8.4. The patient became despondent and refused to stay longer. On dismissal, there were marked paralysis of the right hand and arm, weakness of the right leg, and both motor and sensory aphasia.

Polycythemia Vera With Occlusive Vascular Disease of the Legs.—Of the seven patients in this group, four had phlebitis, and three had evidence of chronic occlusive arterial disease indistinguishable from arteriosclerosis obliterans. In addition, one patient had had symptoms of erythromelalgia, and one had hypertension and cardiac enlargement (Table IV).

CASE 23.—A white man, aged sixty-one years, was admitted to the clinic Nov. 27, 1930. He had suffered for the past five years from burning distress over the heads of the metatarsal joints when walking, which had not been relieved by rubber pads or arch supports. Four years before his registration at the clinic he had received an injection of calcium chloride into one of the veins of his right leg. The injection had been followed in an hour by numbness and whiteness of the right foot and severe pain that had extended from the foot to the knee. Gangrene had developed, and amputation in the region of the middle of the thigh had been necessary. Healing had occurred promptly. Three years before he came to the clinic, he had injured the fifth toe of the left foot; infection and gangrene had set in, which had necessitated amputation of this toe. For the past year, there had been persistent coldness and burning in the sole of the left foot. Four months prior to his admission, the big toe had become blue and cold, but after a month the normal color had returned. Two weeks previous to examination at the clinic, pain and cyanosis had developed at the tip of the second left toe, and on admission the pain in this toe was continuous.

Examination of the patient revealed evidence of polycythemia. The value for the blood pressure expressed in millimeters of mercury was 160 for the systolic and 100 for the diastolic; the heart was enlarged. There was reddish blue discoloration of the tissues of the first and second left toes, and both were cold. The left fifth toe had been amputated previously. Pulsations were absent in the left dorsalis pedis artery and diminished in the posterior tibial artery. The results from study of the blood may be noted in Table IV. Roentgenological examination revealed evidences of calcification of the arteries of the left leg. The flocculation test for syphilis gave negative results. Urinalysis revealed the presence of moderate albuminuria. The concentration of urea in the blood was normal. The diagnosis was polycythemia vera and arteriosclerosis obliterans.

TABLE IV

POLYCYTHEMIA VERA WITH OCCLUSIVE VASCULAR DISEASE OF LEGS

CASE	AGE (YR.) AND SEX	SYMPTOMS OF VASCULAR DISEASE OF LEGS	DIAGNOSIS	STUDIES OF THE BLOOD				
				HEMOGLOBIN, GM. PER 100 C.C. OF BLOOD	ERYTHROCYTES, MILLIONS, IN EACH C.MM. OF BLOOD	HEMACRIT READING	VISCOSITY OF WHOLE BLOOD	VOLUME OF BLOOD IN C.C. FOR EACH KG. OF BODY WEIGHT
18	F 53	Thrombosis, tenderness and redness of varicosities	Thrombosis in varices	21.3	6.72	76	13.6	261
19	F 53	Edema of legs following left nephrolithotomy; pain in thorax	Bilateral thrombophlebitis; pulmonary embolus with infarction*	15.9	7.52	59	7.6	98
20	M 68	Bilateral claudication in calf of each leg	Arteriosclerosis obliterans with bilateral occlusion of popliteal, dorsalis pedis and posterior tibial arteries	20.9	6.78	68		120
21	F 62	Ulcer of left leg over first metatarsal phalangeal joint; intermittent claudication in calf of left leg; pallor and cyanosis of thumb and first two fingers of left hand	Chronic arterial disease with occlusion of left dorsalis pedis and posterior tibial arteries and superficial venous thrombosis; chronic arterial disease with occlusion of left radial artery	21.0	8.77	75	16.0	186
22	F 57	Pain in right popliteal space	Popliteal thrombophlebitis proved surgically	15.2	4.23	46	5.8	124
23	M 61	Pain, cyanosis and gangrene of left second toe; amputation of leg necessary	Occlusive arterial disease†	16.6	6.44	75	12.2	113
24	F 47	Pain in calves of legs; swelling of legs	Bilateral thrombophlebitis‡ Hypertension and cardiac enlargement	18.0	6.5	68	8.6	114

*Polycythemia vera diagnosed and treated elsewhere.
†Previous episode (three months) of erythromelalgia.
‡Patient receiving phenylhydrazine.

Phlebotomy was performed several times to reduce the blood volume, and treatment was carried out to increase circulation to the leg. However, there was evidence of progressive diminution in arterial circulation, and gangrene of the second toe developed. Amputation of the toe was not followed by healing, and amputation of the leg was necessary, following which healing occurred promptly.

Polycythemia Vera With Symptoms of Erythromelalgia and Burning Paresthesia.—According to our criteria, the diagnosis of erythromelalgia is justified only when sensations of burning in the feet are associated with actual increase in the temperature of the skin. When subjective burning occurs without increase in cutaneous temperature, we consider the correct diagnosis to be paresthesia. Following these criteria, there were three cases of erythromelalgia and four cases of paresthesias in this series (Table V). In Case 32, erythromelalgia probably was present, since the patient said there was objective evidence of increase of temperature of the skin, but we could not demonstrate this with a thermometer. One patient had vascular complications of gastric hemorrhage and bilateral thrombophlebitis of the legs (Case 28); another had angina pectoris and phlebitis in varices (Case 31); and a third gave a history of phlebitis and absence of pulsations in the left posterior tibial artery (Case 32).

CASE 25.—A Russian Jew, aged forty-seven years, was admitted to the clinic July 15, 1931, because of sharp, stabbing pain in the plantar surfaces of both feet and in the distal half of the left foot; this pain came in attacks; and there was complete relief between attacks. Elevation of the feet and application of cold did not produce any relief, and the patient had not noted associated changes in color or temperature. Symptoms of peptic ulcer had been present.

Examination of the patient at the clinic revealed an enlarged spleen, marked erythrosis of the mucous membranes and hands, engorged retinal veins, and diminished pulsation of both dorsalis pedis arteries. Results of studies of the blood may be noted in Table V. Roentgenological examination revealed evidence of a duodenal ulcer. Study of the temperature of the skin of the painful areas during an attack showed an increase of about 2° C.

The duodenal ulcer was treated medically, and phenylhydrazine hydrochloride was given for the polycythemia. Excellent response of the blood to phenylhydrazine occurred, and, as the blood returned almost to normal, the distress in the feet disappeared.

The patient returned to the clinic April 26, 1933. He had not followed instructions relative to the use of phenylhydrazine, and the polycythemia and erythromelalgia had recurred. Treatment of the polycythemia with phenylhydrazine was again instituted with good results, but the distress in the feet persisted. Subsequently, the polycythemia was well controlled with phenylhydrazine, and the distress in the patient's feet disappeared shortly after his dismissal from the clinic May, 1933.

Polycythemia Vera With Vasospastic Phenomena.—Case 33 was the only case in this category. In this case there was evidence of auricular fibrillation, which apparently was the result of arteriosclerotic heart disease. We hesitate to indicate that this case is representative of true Raynaud's disease, since the patient was a man, and since only one phase, color reaction, namely cyanosis, had occurred. It is probable

TABLE V

POLYCYTHEMIA VERA WITH SYMPTOMS OF ERYTHROMELALGIA AND WITH BURNING PARESTHESIA

CASE	AGE (YR.) AND SEX	SYMPTOMS OF ERYTHROMELALGIA	DIAGNOSIS	STUDIES OF THE BLOOD				
				HEMOGLOBIN, GM. PER 100 C.C. OF BLOOD	ERYTHROCYTES, MILLIONS, IN EACH C.MM. OF BLOOD	HEMACRIT READING	VISCOSITY OF WHOLE BLOOD	VOLUME OF BLOOD IN C.C. FOR EACH KG. OF BODY WEIGHT
25	M 45	Episodes of severe pain in both feet; temperature of skin of feet increased during pain	Erythromelalgia	19.9	6.05	66	11.2	127
26	M 54	Burning pain in right toe with exercise; no increase in temperature of skin	Burning paresthesia	18.9	8.12	66	9.0	115
27	M 55	Episodes of burning involving distal half of right foot and left great toe; elevation of cutaneous temperature during attacks	Erythromelalgia	19.2	5.18	63	10.6	109
28	F 70	Burning sensation of feet	Burning paresthesia*	23.9	8.2	74	14.6	172
29	F 49	Attacks of burning associated with elevation of temperature of skin involving hands and feet	Erythromelalgia	18.2	5.28	56	7.0	148
30	M 59	Burning sensation in soles of feet; no increase in temperature of the skin	Burning paresthesia	19.2	6.81	64	10.4	184
31	M 58	Episodes of burning in left foot not associated with increased cutaneous temperature	Burning paresthesia†	21.7	7.44	74	14.8	132
32§	M 38	Episodes of burning in left foot; not always associated with elevation of cutaneous temperature	Erythromelalgia?‡ Paresthesia?	20.5	6.53	60	8.4	109

*Gastric hemorrhage; bilateral thrombophlebitis of legs.
†Angina pectoris; history of phlebitis affecting varices.
‡Left posterior tibial artery occluded, history of phlebitis; thromboangiitis obliterans (?).
§Case 33 is not included in the tables but is discussed in the text.

that the patient had an organic disease of the digital arteries, and, unless this possibility is excluded by arteriography, the diagnosis of Raynaud's disease is not justified.

VASCULAR COMPLICATIONS OF "RELATIVE POLYCYTHEMIA"

The term "relative polycythemia" refers to a condition in which the status of the blood is similar to that in polycythemia vera, except that the blood volume is within normal limits. This condition has been noted in some cases of Raynaud's disease and thromboangiitis obliterans by Brown and Giffin,[5] Horton and Brown,[16] and Rowntree, Brown, and Roth.[29] Harrop[15] cited two cases reported by Wright in which cerebrovascular hemorrhage or thrombosis affected patients who had relative polycythemia: a child, aged twelve years, had spastic hemiplegia which had followed convulsions when she had had measles at the age of four years. Cyanosis, clubbing of the fingers, and evidence of incomplete aeration of blood in the lungs were present. An infant, aged twenty months, had a paralyzed right arm and evidence of congenital stenosis of the pulmonary arteries.

Relative polycythemia was diagnosed thirty-five times at the clinic during a period of seven years (from Jan. 1, 1929, to Jan. 1, 1936). Doubtless many more cases were observed, but ordinarily such a diagnosis is made only when the condition is of primary interest. In many conditions, such as emphysema, studies for polycythemia such as determination of blood volume are not made because the presence of polycythemia is of little practical importance in the condition.

In twelve of the cases in which relative polycythemia was determined, there was evidence of vascular lesions. In none of these cases was polycythemia marked (Table VI). The highest erythrocyte count was 5.7 millions in each cubic millimeter of blood, and the most abnormal volume percentage of cells in the blood was 63. In several cases the increase in the number of erythrocytes, in the hematocrit readings, and in the viscosity of the blood was only minimal, exceeding normal by very little. The results probably represent phenomena attributable to simple concentration of the blood from a variety of causes. However, we feel there is justification for referring to these cases since polycythemia of some degree was present in all. There were five cases of thromboangiitis obliterans, two cases of arteriosclerosis obliterans, and one case each of erythromelalgia, cerebral hemorrhage or thrombosis, vasospastic neurosis, thrombophlebitis, and thrombosis of the inferior epigastric and portal veins.

COMMENT

Inquiry is pertinent as to whether the coexistence of polycythemia vera and vascular complications is incidental or is representative of a cause-and-effect relationship. Since both polycythemia vera and the

TABLE VI

VASCULAR COMPLICATIONS OF RELATIVE POLYCYTHEMIA

CASE	AGE (YR.) AND SEX	SYMPTOMS OF VASCULAR DISEASE	DIAGNOSIS	STUDIES OF THE BLOOD				
				HEMOGLOBIN, GM. PER 100 C.C. OF BLOOD	ERYTHROCYTES, MILLIONS, IN EACH C.MM. OF BLOOD	HEMACRIT READING	VISCOSITY OF WHOLE BLOOD	VOLUME OF BLOOD IN C.C. FOR EACH KG. OF BODY WEIGHT
34	M 49	Intermittent claudication; superficial phlebitis*	Thromboangiitis obliterans	15.9	5.29	51	6.8	
35	M 57	Superficial phlebitis; stasis dermatitis*	Thromboangiitis obliterans	18.2	4.54	51	5.3	63
36	M 46	Intermittent claudication; recurrent episodes of discoloration and pain involving right fifth toe and the heel*	Thromboangiitis obliterans	17.4	5.71	58	7.0	72
37	M 52	Intermittent claudication*	Thromboangiitis obliterans	17.8	4.32	57		73
38	M 53	Intermittent claudication; gangrene of toe, phlebitis*	Thromboangiitis obliterans	19.5	5.14	63	8.0	88
39	M 54	Burning sensation in both feet associated with increase in temperature of skin	Erythromelalgia	18.6	4.50	53		72

TABLE VI—CONT'D

40	F 51	Episodes of burning of soles of feet; right hemiplegia, apraxia and agnosia†	Left cerebral arterial hemorrhage or thrombosis; paresthesia of feet	19.2	5.11	58	5.8	88
41	M 61	Intermittent color changes of fingers and toes varying from cyanosis to pallor	Vasospastic neurosis simulating Raynaud's disease‡	16.9	5.00	50	6.7	
42	M 45	Edema of left leg and of right leg nine months later	Thrombophlebitis	16.9	5.20	60		
43	F 62	Gangrene of toes	Arteriosclerosis obliterans?; peripheral arteries pulsating normally	16.4	5.70	49	6.7	
44	M 59	Intermittent claudication in right calf; severe prolonged attack of pain in the thorax	Arteriosclerosis obliterans; coronary sclerosis with myocardial infarction	15.2	5.09	50	7.4	92
45	F 19	Ascites, enlarged liver and spleen and numerous gastric hemorrhages	Cirrhosis of liver, thrombosis of portal and inferior epigastric veins observed at necropsy§	13.8	5.30	55		108

*Occlusion of some arteries in legs.
†Patient underwent venesection and roentgen ray therapy elsewhere; she may have had polycythemia vera.
‡Some evidence of myelogenous leucemia.
§Diagnosis not absolute; polycythemia vera with secondary venous thrombosis or cirrhosis of the liver with secondary polycythemia.

vascular diseases considered usually affect elderly individuals, it might be assumed that mere chance was responsible for two conditions affecting the same person. However, approximately one-third of all of our patients who had polycythemia vera had vascular diseases, which fact indicates that polycythemia was responsible for the vascular diseases in most instances since the latter affect a much smaller proportion than one-third of all our patients of similar ages and sex. Moreover, this hypothesis is logical, as the conditions in the blood are those which produce an increased tendency to thrombosis. The situation is not so clear in relative polycythemia, in which the disturbances in the blood are frequently minimal. If the records of all cases in which the changes in the blood were no more marked than they were in the present series of cases were available for study, it would doubtless be found that the percentage of cases with vascular complications would be small when compared with that in cases of polycythemia vera. It is probable, but by no means certain, that the changed status of the blood is not responsible for the vascular lesions in the majority of cases of relative polycythemia. For example, polycythemia is rare in thromboangiitis obliterans, and we view the relationship as one of coincidence rather than one of cause and effect. Naturally, the fundamental disturbance may, in some obscure manner, produce thromboangiitis obliterans and relative polycythemia. The observations just made regarding thromboangiitis obliterans apply to arteriosclerosis obliterans, and with less certainty to erythromelalgia and vasospastic neurosis. Phlebitis and cerebrovascular hemorrhage or thrombosis may have resulted directly from polycythemia, but we have no evidence that this is so. As indicated in Table VI, the diagnosis was not absolute in the case of thrombosis of the inferior epigastric and portal vessels.

Our study emphasizes two important points. It is advisable to treat polycythemia vera if for no other reason than to prevent vascular complications. If the many vascular diseases noted in our study are viewed with the suspicion that polycythemia vera exists, it will be found in at least a small percentage of cases. This is particularly true with regard to erythromelalgia, which is frequently a sign of polycythemia, as we have observed on numerous occasions. Furthermore, it appears that arteriosclerosis obliterans and thromboangiitis obliterans respond in a better manner to treatment if polycythemia which may be present is treated actively.

SUMMARY

Study of ninety-eight cases of polycythemia vera and thirty-five cases of relative polycythemia reveals that erythromelalgia, myocardial infarction, angina pectoris, occlusive disease of the peripheral arteries, cerebral hemorrhage of thrombosis, intraabdominal vascular thrombosis,

phlebitis, and vasomotor neurosis occur in about a third of the cases. Recognition of the relationships is important diagnostically and therapeutically.

REFERENCES

1. Adams, L. J.: Polycythaemia Vera, With Special Reference to the Nervous Manifestations: An Analysis of Nine Cases, Canadian M. A. J. 32: 128, 1935.
2. Blumgart, H. L., Gargill, S. L., and Gilligan, Dorothy R.: Studies on the Velocity of Blood Flow: XV. The Velocity of Blood Flow and Other Aspects of the Circulation in Patients With "Primary" and Secondary Anemia and in Two Patients With Polycythemia Vera, J. Clin. Investigation 9: 679, 1931.
3. Brown, G. E.: Erythromelalgia and Other Disturbances of the Extremities Accompanied by Vasodilatation and Burning, Am. J. M. Sc. 183: 468, 1932.
4. Brown, G. E., and Giffin, H. Z.: Studies of the Vascular Changes in Cases of Polycythemia Vera, Am. J. M. Sc. 171: 156, 1926.
5. Brown, G. E., and Giffin, H. Z.: Peripheral Arterial Disease in Polycythemia Vera, Arch. Int. Med. 46: 705, 1930.
6. Brown, G. E., and Roth, Grace M.: The Reduction of Hypercalcemia in Cases of Polycythemia Vera by Phenylhydrazine, J. Clin. Investigation 6: 159, 1928.
7. Christian, H. A.: The Nervous Symptoms of Polycythemia Vera, Am. J. Med. Sc. 154: 547, 1917.
8. Cole, N. B.: Comments on a Case of Polycythemia Rubra Vera With Autopsy, M. Clin. North America 16: 1255, 1933.
9. Cory, R. F. P.: Case of Polycythaemia and Embolic Ulceration of Stomach and Intestines, J. Roy. Nav. M. Serv. 19: 122, 1933.
10. Elschnig, A., and Nonnenbruch, W.: Polycythämie und Embolie der Arteria centralis retinae, Klin. Monatsbl. f. Augenh. 88: 433, 1932.
11. Ernst, Curt: Beitrag zur Frage des Kreislaufes bei der Polycythaemia vera, Ztschr. f. klin. Med. 114: 757, 1930.
12. Giffin, H. Z.: Treatment in a Case of Polycythemia Vera, M. Clin. North America 12: 1497, 1929.
13. Gregg, D. E., and Wiggers, C. J.: The Circulatory Effects of Acute Experimental Hypervolemia, Am. J. Physiol. 104: 423, 1933.
14. Griffith, R. S.: Erythremia (Polycythemia Vera or Vaquez-Osler Disease), M. Clin. North. America 16: 199, 1932.
15. Harrop, G. A., Jr.: Polycythemia, Medicine 7: 291, 1928.
16. Horton, B. T., and Brown, G. E.: Unusual Cases of Thromboangiitis Obliterans: Their Association With Polycythemia Vera, M. Clin. North America 12: 1617, 1929.
17. Jacobi, A.: Polycythämie und Mesenterialvenenthrombose; ihre Beziehungen zu Unfällverletzungen, Mitt. a. d. Grenzgeb. d. Med. u. Chir: 41: 555, 1929.
18. Jacobi, H. G.: Symptomatic Response of Peripheral Arterial Disease in Polycythemia Vera to Intravenous Use of Physiologic Solution of Sodium Chloride, J. A. M. A. 96: 1138, 1931.
19. Lommel, F.: Quoted by Harrop.[15]
20. Lüdeke, Heinrich: Thrombophilie und Polycythämie. Virchows Arch. f. path. Anat. u. Physiol. 293: 218, 1934.
21. Oppenheimer, B. S.: Vascular Occlusion in Polycythemia Vera, Tr. A. Am. Physicians 44: 338, 1929.
22. Osler, William: Chronic Cyanosis, With Polycythaemia and Enlarged Spleen: A New Clinical Entity, Am. J. M. Sc. 126: 187, 1903.
23. Osler, William: A Clinical Lecture on Erythraemia (Polycythaemia With Cyanosis, Maladie de Vaquez), Lancet 1: 143, 1908.
24. Parkes-Weber, F.: Polycythaemia Erythrocytes and Erythraemia (Vaquez-Osler Disease), New York, 1922, Paul B. Hoeber, Inc.
25. Parkes-Weber, F.: Erythraemia With Migraine, Gout, and Intracardiac Thrombosis, Lancet 2: 808, 1934.
26. Peacock, H. A.: Blood Pressure and Blood Volume in Cases of Polycythemia Vera, Proc. Staff Meet., Mayo Clinic 4: 286, 1929.
27. Poll, Daniel: Thrombosis of Pulmonary Vessels in Polycythaemia Vera, J Mount Sinai Hosp. 1: 254, 1935.
28. Roch, M., and Epstein, A.: Erythémie Essentielle; Thrombophlébite Gastro-épiploïque ayant simulé une perforation d'estomac, Rev. méd. de la Suisse 49: 707, 1929.

29. Rowntree, L. G., Brown, G. E., and Roth, Grace M.: The Volume of the Blood and Plasma in Health and Disease, Philadelphia, 1929, W. B. Saunders Company.
30. Singer, Karl: Polycythämie und Milzgefässzirkulationsstörungen, Beiträge zur Pathogenese der Erythrämie, Deutsches Arch. f. klin. Med. 175: 355, 1933.
31. Sloan, L. H.: Polycythemia Rubra Vera: Neurological Complications: Report of Four Cases, Arch. Neurol. & Psychiat. 30: 154, 1933.
32. Sloan, L. H.: Polycythemia: Consideration of the Types, Symptoms and Findings in Polycythemia Rubra (Vera); Presentation of Patients, Med. Clin. North America 17: 369, 1933.
33. Tumen, H. J.: The Association of Polycythemia With Occlusion of the Inferior Vena Cava: Report of a Case, Am. J. Obst. & Gynec. 20: 417, 1930.
34. Vaquez, M. H.: Sur une forme spéciale de cyanose s'accompagnant d'hyperglobulie excessive et persistante, Compt. rend. Soc. d. biol. 44: 384, 1892.
35. Wright: Quoted by Harrop.[15]

SIGNIFICANCE OF BLOOD VESSELS IN HUMAN HEART VALVES*

LOUIS GROSS, M.D.
NEW YORK, N. Y.

DURING most of the eighty-four years in which reports have appeared on the problem as to whether blood vessels exist in normal human heart valves, a number of obstacles have interfered with its elucidation. As pointed out by Gross and Kugel,[1] one of the major difficulties lay in the fact that until recently no precise definition existed as to what constitutes the proximal limits of the several cardiac leaflets. As a consequence, when auricular myocardium was included as part of the auriculoventricular leaflets, these could be considered as possessing vasculature, since myocardium always contains blood vessels (Langer,[2] Dow and Harper[3]). On the other hand, when the leaflet (and ring) were considered as the purely fibroelastic structure distal to the myocardium, the existence of blood vessels in this site assumed an entirely different significance. This latter point, which has been the subject of an extensive controversy, will form the basis of this report. The topographical relations and limits of human heart valves, as defined by Gross and Kugel,[1] will be employed.

Another major obstacle in the problem has been the statement by Langer[2] that human embryonic heart valves contain myocardium and blood vessels and that these regress before birth. This assumption, which the present author has been unable to confirm, has offered the tempting explanation that blood vessels may exist in normal human valves as vestiges of the embryonic state.

A somewhat similar pitfall is the fact that several species of animals, e.g., ox, sheep, swine, dog, horse, etc., have blood vessels in normal valves. This suggests an all-too-facile analogy with the vessels at times found in human heart valves, an analogy which, as will be seen, is totally unjustified.

The most perplexing difficulty, however, lay in the fact that until recent years there were no means available for differentiating normal valves possessing certain involutionary changes (so-called tension changes), from the end-results of mild inflammatory lesions. As a consequence, most of the published reports have concerned themselves with improvements on injection methods, and scant attention was paid to careful histological examination of the tissues for the purpose of determining accurately their normality.

*From the Laboratories of the Mount Sinai Hospital, New York, N. Y.
Aided by grants from the Lucius N. Littauer and Walter W. Naumburg Funds.

The schools of thought in this field can be roughly divided into two groups. The first (Gerlach,[4] Luschka,[5] Kölliker,[6] Forster,[7] Henle,[8] Frey,[9] Rosenstein,[10] Sappey,[11] Krause,[12] Cruveilhier,[13] Cöen,[14] Bayne-Jones,[15] Kerr and Mettier,[16] Kerr, Mettier, and McCalla,[17] Wearn and his coworkers[18]) holds to the belief that blood vessels may exist in normal human heart valves, some authors considering these vessels to occur in the auriculoventricular as well as the semilunar valves, and others only in the former. The second group (Rokitansky,[19] Joseph,[20] Virchow,[21] Cadiat.[22] Langer,[2] Darier,[23] Königer,[24] Odinzow,[25] Nussbaum,[26] Tandler,[27] Dow and Harper[3]) considers that valves are normally nonvascularized and that, if blood vessels are found in them, they are due to an inflammatory process in the leaflets.

In previous publications, the author[28] with collaborators[29, 30] has adduced evidence which seemed to favor the belief that blood vessels may exist in a small percentage of normal human heart valves. In a report on 700 injected human hearts, Ritter, Gross, and Kugel[30] found blood vessels in 2 per cent of, what were considered at the time, intact valves. Although blood vessels were found in a considerable number of specimens (representing 18 per cent of this relatively large material), definite evidences of inflammation were found in a great majority of these. In later reports the author with collaborators[1, 31, 32,] has expressed doubt as to the normality of any human heart valve possessing blood vessels.

The following observations summarize the evidence at present available in favor of the concept that blood vessels may exist in the fibroelastic portion of normal human heart valves:

1. Langer's claim[2] that human fetal valves possess myocardium and blood vessels.

2. The regular and sometimes constant occurrence of blood vessels in the normal heart valves of some animal species and the alleged similarity of these vessels to those found in human heart valves.

3. The demonstration of blood vessels in apparently normal human heart valves ranging from 2 per cent[30] to 74 per cent.[18] The increased incidence of blood vessels as demonstrated by more recent workers has been attributed to improvements in injection technic.

4. The apparent absence of clinical or pathological evidence indicating present or past inflammatory disease in these hearts.

5. The histological structure of the valvular vessels, i.e., the occurrence of muscular wall arteries and veins.[29]

6. The apparent topographical regularity of blood vessels found in human heart valves.[29, 30, 33]

7. The apparent nondependence of these vessels on valvulitis, inasmuch as the incidence of vascularization of the several valves does not parallel the incidence of inflammation in them (Wearn and his collaborators[18]).

As against the concept of the existence of vessels in the fibroelastic portion of normal human heart valves are:

1. The existence of normal hearts without evidence of blood vessels in the valves. The incidence of such normal hearts ranges, according to various authors, from 98 per cent to 26 per cent.

2. The extraordinarily frequent coexistence of valve inflammation (chiefly of the rheumatic variety) in the great majority of specimens showing valve vasculature.

3. The histological similarity of the vessels occurring in inflamed valves (and obviously resulting from the inflammation) with those found in supposedly normal valves.

4. The coexistence of myocardial fibers with blood vessels which seem to extend into the fibroelastic portion of the leaflets (Langer,[2] Dow and Harper[3]).

In a series of studies carried out by the author with collaborators, the life cycles of a large number of characteristic cardiac lesions occurring in rheumatic fever have been studied. These lesions are found in the left auricle,[34] valve rings,[31] valve leaflets,[32] intervalvular fibrosa,[31, 35] conduction system,[36] aortic and pulmonic roots,[37] myocardium,[38] blood vessels,[39] and pericardium.[40] It was shown that the majority of these lesions may heal with such complete restitution to integrity that it requires the closest scrutiny to reveal stigmas of their past occurrence. Nevertheless, these stigmas occur with remarkable consistency and are very widespread, even when healing has gone on to completion. Using these stigmas as evidences of past rheumatic disease, Sohval and Gross[35] have recently shown that calcific aortic valve sclerosis (Mönckeberg type) is a distinct pathological entity (sui generis) and can exist quite apart from an underlying rheumatic basis. This conclusion was based on the histological findings in a series of hearts presenting the Mönckeberg process in which it was seen that the lesion frequently exists without appreciable evidence of any of the rheumatic stigmas otherwise found in very high incidence in completely extinct but definite ancient rheumatic fever.

It seemed then quite logical to apply the same criteria to those human hearts which contained blood vessels in the valves but appeared otherwise normal. Since it was of prime importance to establish the possibility of the existence of blood vessels in such otherwise seemingly intact hearts, it appeared advisable to first carry out these studies in a highly selected group of specimens least subject to criticism as to whether or not the valves had been the seat of a mild inflammatory process. If it could be shown that such carefully selected specimens possess blood vessels in the absence of inflammatory stigmas, one could then enter into the statistical question on the incidence of blood vessels in normal valves. On the other hand, if it could be shown that there exists overwhelming evidence against the acceptance of vascularized human heart valves as normal, such statistical observations would be

of value only in that they indicate the existence of mild valvular lesions in perhaps an hitherto unsuspected proportion of the population.

Accordingly, 44 hearts were selected from the last 4,000 autopsies performed in the laboratories of the Mount Sinai Hospital. Among these 4,000 autopsies, 700 hearts were subjected to injection by the author's method.[28] It may be mentioned parenthetically that these injected specimens did not show as high an incidence of vasculature in the supposedly normal hearts as did the noninjected specimens. The reason for this will become clear in the discussion.

To recapitulate, these 44 specimens presented no evidence clinically and, by currently acceptable standards, no evidence grossly that the heart had been subject to previous inflammatory disturbance. Syphilis was carefully ruled out by the history and Wassermann test. In the light of the microscopic findings present in these specimens, it must be mentioned that a careful review of the gross material revealed inconspicuous macroscopic changes in the leaflets or chordae tendineae attachments (such as small isolated thickenings of the leaflet edges, minor straightening of the scalloped borders, occasional abrupt insertions of the chordae tendineae into the cusps, etc.) which in retrospect undoubtedly represent minimal gross abnormalities. These were, however, of so mild an extent and simulated so closely the wear and tear tension changes commonly found in these leaflets that they could not be interpreted as evidences of disease without corroboration of the microscopic findings.

These specimens were fixed in 10 per cent neutral formalin saline* and sectioned by the standardized technic of Gross, Antopol, and Sacks.[41] The sections were stained according to the methods previously described by Gross and Ehrlich.[38] In the microscopic examination of these hearts, particular attention was paid to the following seventeen sites, viz., endocardium, myocardium and pericardium of the left auricle, rings† and leaflets of the mitral (anterior and posterior), aortic, tricuspid and pulmonic valves, intravalvular fibrosa of the anterior mitral leaflet, roots of the aorta and pulmonary artery, and pericardium as a whole.

In order to compare the incidence of lesions in these sites with those possibly occurring in hearts from individuals who had no history indicating cardiac affection and whose valves were normal microscopically and possessed no blood vessels—in other words, normal control hearts—a series of 100 specimens were studied by the same methods and charted statistically under the seventeen sites mentioned above. In addition, there were also examined hearts from 13 cases

*Solution of formaldehyde, U. S. P., 10 parts; 1 per cent sodium chloride solution, 90 parts. This solution is rendered neutral with a weak alkali.

†For definitions of these sites see reference 1.

of grossly monovalvular extinct rheumatic disease, 50 human hearts injected by Wearn's technic,[18] 50 calf hearts similarly injected, 50 uninjected calf hearts, uninjected and injected swine, sheep, rabbit and guinea pig hearts, and serial sections from numerous human, ox, and swine embryos.

MICROSCOPIC FINDINGS IN 100 CONTROL HEARTS WITH NORMAL NONVASCULARIZED VALVES

Reference to Table I discloses the fact that lesions in the left auricle (endocardium, myocardium, and pericardium) were represented in these control specimens by reduplications of the endocardium in 20 per cent of the cases. These were delicate, flat and collagenous, invariably occurred in the older age periods (generally from the sixth decade on), and have already been described by the author[34] as probably representing a sclerotic proliferative process which can be generally differentiated from the reduplications found in rheumatic disease. In 15 per cent of the cases very mild scatterings of lymphocytes and occasional dilated capillaries were found in the pericardium of the left auricle. These mild infiltrations are undoubtedly attributable to the fact that in a number of these cases there were present inflammatory lesions of the lungs with, possibly, some continguity process to the pericardium. No inflammatory lesions were found in the left auricular myocardium, and, more significantly, in no instance were lesions found in two or three of these sites in the same left auricle.

It has already been shown by Gross and Kugel[1] that capillaries only were found in the valve rings of 100 normal hearts with the following frequency:

Anterior mitral valve ring	1%
Posterior mitral valve ring	2%
Aortic valve ring	0%
Tricuspid valve ring	14%
Pulmonary valve ring	7%

These capillaries are very delicate, generally circular on cross-section (except in the tricuspid ring where they frequently appear as large sinusoidal spaces), in no way resemble granulation tissue, and are not surrounded by inflammatory cells. The fibroelastic leaflets distal to these rings presented no vasculature whatsoever. This absence of blood vessels was confirmed in many instances by injection and by serial sections.

Of great importance is the fact that the valve leaflets showed no appreciable thickening or reduplication of the proximal layers (auricularis layer of the auriculoventricular valves and ventricularis layer of the semilunar valves) and, except in the oldest age periods, no evidence of absorption of the chordae tendineae. The closure line of the leaflets occasionally showed mild fibroelastic thickenings.

The intervalvular fibrosa was completely devoid of capillaries or inflammatory cells both in the main body of this structure (annulus extension) as well as in the boundary between the left auricular myocardial wedge and the annulus extension. Inasmuch as repeated reference will be made to this boundary, which extends from the region of the aortic ring to the tip of the left auricular myocardial wedge, this site will be termed "myocardial fibrous boundary of the intervalvular fibrosa."

It has already been shown by the author[37] that capillaries are occasionally present between the fibroelastic and muscular strands of the pulmonic root media in approximately 24 per cent of normal hearts. These capillaries are extremely inconspicuous, arise from the blood vessels in the adventitial layer, and rarely penetrate beyond the inner third of the media. Rare capillaries confined to the medial-adventitial zone were observed in 25 per cent of normal aortic roots. Scars were rare and inconspicuous.

In 10 per cent of these control hearts mild scatterings of lymphocytes were noted in the pericardium of several of the standardized blocks. As mentioned before, however, these lymphocytes showed no particular concentrations, nor were there present increased numbers of capillaries or other findings suggestive of a previous rheumatic pericardial lesion.[40]

Of great importance is the fact that of the seventeen sites under which these statistics were listed, lesions were never found in more than three of these sites in any of the hearts of the normal non-vascularized control series. In the vast majority of cases, only one lesion was present. This consisted either of a flat reduplication of the left auricular endocardium or of capillarization of one of the rings, chiefly the tricuspid.

MICROSCOPIC FINDINGS IN THIRTEEN HEARTS WITH GROSSLY MONOVALVULAR EXTINCT RHEUMATIC DISEASE

In contrast to the paucity of the above mentioned findings are the extraordinarily high incidence and consistent occurrence of stigmas in extinct rheumatic disease recognizable grossly and microscopically as such. The lesions present in these hearts have already been reported by Sohval and Gross[35] in their studies on aortic calcific sclerosis of the Mönckeberg type. The statistical data in this group, rather than in a group of extinct grossly polyvalvular rheumatic disease, have been selected to be presented in this report, inasmuch as it appears of value to compare the incidence of lesions in the 44 supposedly normal vascularized valve hearts with a series which could be considered definitely rheumatic in which, however, the gross lesions showed minimal deviation from the normal.

TABLE I

COMPARISON OF PERCENTAGE INCIDENCE OF MICROSCOPIC LESIONS IN THE HEARTS OF THE NORMAL NONVASCULARIZED VALVE SERIES, GROSSLY MONOVALVULAR EXTINCT RHEUMATIC SERIES, AND THE SUPPOSEDLY NORMAL VASCULARIZED VALVE SERIES

	LEFT AURICLE				ANTERIOR MITRAL VALVE		POSTERIOR MITRAL VALVE		AORTIC VALVE		TRICUSPID VALVE		PULMONIC VALVE		INTERVALVULAR FIBROSA		GREAT VESSEL ROOTS		PERICARDIUM
	ENDOCARDIUM	MYOCARDIUM	PERICARDIUM	2 OR MORE SITES	RING	LEAFLET	RING	LEAFLET	RING	LEAFLET	RING	LEAFLET	RING	LEAFLET	ANNULUS EXTENSION	MYOCARDIAL-FIBROUS BOUNDARY	PULMONIC	AORTIC	(SEVERAL SITES)
Normal nonvascularized valves (100 cases)	20	0	15	0	0	0	0	0	0	0	0	0	0	0	0	0	24	25	10
Grossly monovalvular extinct rheumatic disease (13 cases)	63	37	74	74	53	95	47	74	58	21	32	26	26	5	5	85	37	68	80
Supposedly normal vascularized valves (44 cases)	69	32	92	69	35	62	56	41	41	12	35	14	28	14	21	71	74	64	74
Supposedly normal vascularized valves with 4 Aschoff body cases eliminated (40 cases)	68	30	95	68	33	60	58	40	40	12	33	10	28	10	18	73	78	68	70
Supposedly normal vascularized valves with Aschoff bodies in myocardium (4 cases)	75	50	75	75	50	75	75	50	50	50	75	50	75	50	50	50	75	75	100

As will be seen from Table I, the lesions in this group were extraordinarily common and widespread in the seventeen sites referred to in this report. Particular attention should be directed to the incidence of lesions in the left auricle, in the various rings and valve leaflets, in the fibrous boundary of the intervalvular fibrosa, in the great vessel roots, as well as in several pericardial sites. It appears then from these findings that rheumatic fever leaves a very high incidence of inconspicuous but widespread stigmas in certain sites of the heart, even when the inflammatory process has become completely extinct and when the disease was, so far as one could discern, relatively mild.

MICROSCOPIC FINDINGS IN FORTY-FOUR SUPPOSEDLY NORMAL HEARTS POSSESSING BLOOD VESSELS IN THE VALVES

The not infrequent discovery of rheumatic lesions in hearts at the autopsy table, from patients in whom there is no history of rheumatic fever and in whom this disease has never been suspected during life, is well known to pathologists. Hawking[42] has recently reported that in addition to those in whom the condition was diagnosed clinically as rheumatic fever, 1.2 per cent of 1,380 necropsies on other patients dying at the Presbyterian Hospital revealed evidence of clinically unsuspected rheumatic heart disease. Careful search through the standardized sections of the 44 hearts comprising the group under discussion revealed the surprising fact that four of them presented myocardial Aschoff bodies (Fig. 1). Inasmuch as these hearts were carefully selected to rule out all clinical and gross anatomical evidence of abnormality, this observation becomes extremely important to the problem under discussion. First, it indicates that apart from the autopsy findings of "silent" rheumatic hearts, this disease may exist in an active state (Rothschild, Gross, and Kugel[43]) with, however, such subdued virulence that the only other suggestive evidence of its existence is the presence of blood vessels in the valves which otherwise appear to be grossly intact. Second, the incidence of rheumatic stigmas in these four hearts is not significantly different from the other supposedly normal hearts with vascularized valves so that, were it not for the discovery of the Aschoff bodies, they would properly fall into this group.

In order to avoid confusion of the issue, the incidence of the rheumatic stigmas in the seventeen selected sites are listed in Table I under the following headings: 44 cases with supposedly normal vascularized valves, four of which, however, revealed Aschoff bodies in the myocardium; 40 cases with supposedly normal vascularized valves in which the four cases with Aschoff bodies are eliminated; four cases with supposedly normal vascularized valves which revealed Aschoff bodies in the myocardium.

It will be noted that in the three subdivisions of this group, the incidence and distribution of lesions bear a striking similarity to those found in the extinct rheumatic cases. Of considerable importance and interest are the findings in the left auricle. As will be observed, lesions were found in the endocardium and myocardium and, particularly in

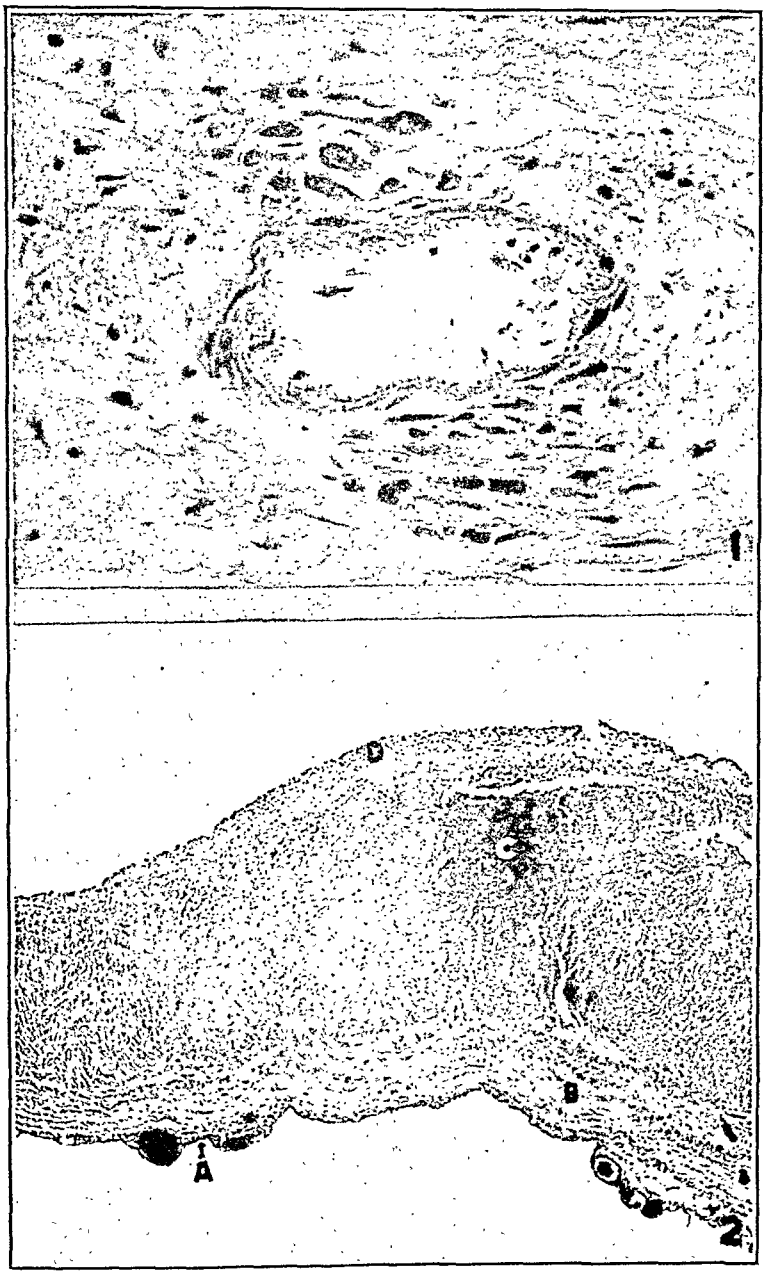

Fig. 1.—Case from supposedly normal vascularized valve series. Patient aged fifty-nine years. Hematoxylin and eosin stain. Medium power.

Typical Aschoff body in interventricular septum.

Fig. 2.—Case from supposedly normal vascularized valve series. Patient aged twenty-nine years. Hematoxylin and eosin stain. Medium power.

Cross-section through anterior mitral leaflet showing injected blood vessels situated within the auricularis layer. *A*, auricularis layer containing blood vessels surrounded by lymphocytes; *B*, spongiosa layer. Note several injected vessels near basal portion; *C*, fibrosa layer; *D*, ventricularis layer.

the pericardium, with a frequency considerably above that found in the control nonvascularized valve series, and, moreover, the incidence

of these lesions is approximately the same as that noted in the extinct monovalvular rheumatic series. Furthermore, in 69 per cent of this series lesions were found in two or more of the three auricular sites examined. This is in sharp contrast to the findings in the nonvascularized control series.

The incidence of capillaries together with scatterings of lymphocytes in the various valve rings again approach very closely that found in the extinct rheumatic series. This, therefore, is another distinct difference from the normal nonvascularized controls. In most instances, these capillaries were thicker than those occasionally found in normal rings. They were sometimes surrounded by scatterings of lymphocytes. Not infrequently, these lesions were distributed within scarred ring spongiosa and annulus.

The findings in the valve leaflets will be discussed in the following section. Suffice it to say here that many of the leaflets showed reduplications of the proximal layers and that blood vessels frequently occurred in these same layers and were generally surrounded by mild lymphocytic infiltration (Fig. 2).

During the first three or four decades of life, the normal myocardial-fibrous boundary of the intervalvular fibrosa consists of an inconspicuous connective tissue layer situated between the closely apposed left auricular myocardial wedge and the main collagenous annulus extension of the intervalvular fibrosa. Capillaries and inflammatory cells are not present either in the boundary or in the intervalvular fibrosa proper. In later age periods accumulations of fat tissue are deposited within this boundary zone. This tissue generally possesses delicate capillaries between the areolar septums. Of paramount interest was the observation that in 71 per cent of the hearts comprising the so-called normal vascularized valve series, a definite lesion existed within the myocardial fibrous boundary (Figs. 3, 4, 5) and in 21 per cent, within the annulus extension of the intervalvular fibrosa (Fig. 5). In the former the lesion consisted of a loose reticular tissue containing many stout and often distorted capillaries. Rare lymphocytes were occasionally present. These lesions could be easily differentiated from the normal fat accumulations. Moreover, they occurred with great regularity even in the earliest age periods. In the annulus extension of the intervalvular fibrosa, capillaries were observed penetrating for a variable distance toward the endocardium. These were occasionally surrounded by lymphocytes. These findings, therefore, by themselves sharply differentiate the so-called normal vascularized valve series from the normal nonvascularized controls.

Capillarization of the pulmonic root as well as lesions of the aortic root (capillaries and scars) occurred in very high incidence. Indeed, the incidence bore a striking resemblance to that found in the monovalvular extinct rheumatic series. In 74 per cent of the hearts several of

the standardized blocks from the same case showed pericardial lesions These consisted generally of scattered lymphocytes which often tended to concentrate in the neighborhood of the lamina propria layer (Fig. 6). Moreover, there was often a definite increase in the size and number of capillaries within the pericardium, and also a widening and thickening of the septums of the areolar tissue. These findings are in distinct



Fig. 3.—Case from supposedly normal vascularized valve series. Patient aged thirty-one years. Weigert's elastic and van Gieson's connective tissue stain. Low power.

Cross-section through basal portion of anterior mitral leaflet including left auricular myocardial wedge. *A*, auricularis layer containing an injected vessel; *B*, spongiosa layer; *C*, fibrosa layer; *D*, ventricularis layer; *E*, left auricular myocardial wedge; *F*, myocardial-fibrous boundary of intervalvular fibrosa containing numerous capillaries within a reticular framework; *G*, annulus extension of intervalvular fibrosa.

Fig. 4.—Case from supposedly normal vascularized valve series. Patient aged thirty-six years. Hematoxylin and eosin stain. Medium power.

Cross-section through annulus extension of intervalvular fibrosa including left auricular myocardial wedge. *A*, left auricular myocardial wedge; *B*, annulus extension of intervalvular fibrosa; *C*, myocardial-fibrous boundary of intervalvular fibrosa containing granulation tissue type vessels within a reticular framework.

contrast to the 10 per cent incidence of mild lymphocytic scatterings found in the normal nonvascularized valve control series.

Of greatest importance is the fact that every heart in this series showed lesions in at least six of the seventeen sites selected (not listed in Table I). The average heart showed lesions in ten or eleven sites, and several in sixteen or seventeen sites. A further significant differ-

Fig. 5.—Case from supposedly normal vascularized valve series. Patient aged nineteen years. Hematoxylin and eosin stain. Medium power.

Cross-section through annulus extension of intervalvular fibrosa including left auricular myocardial wedge. *A*, left auricular myocardial wedge; *B*, annulus extension of intervalvular fibrosa. Note penetrating capillaries (injected) surrounded by scattered lymphocytes. *C*, myocardial-fibrous boundary of intervalvular fibrosa containing granulation tissue type vessels within a reticular framework. Note penetration of these capillaries into annulus extension.

Fig. 6.—Case from supposedly normal vascularized valve series. Patient aged twenty-seven years. Hematoxylin and eosin stain. Medium power.

Cross-section through pericardial portion of left auricle. *A*, left auricular myocardium; *B*, pericardium infiltrated with lymphocytes. Note concentration of lymphocytes around *C*, lamina propria.

ence from the normal nonvascularized valve control series was the frequent presence of delicate reduplications of the proximal valve layers and the occasional early absorption of chordae tendineae insertions.[32]

It is obvious, therefore, that this series differs markedly from the normal nonvascularized controls in the high incidence of inflammatory stigmas; in their wide distribution; in the association of reduplications on the proximal valve layers, however mild; in the high incidence of ring capillarization; and in the almost invariable presence of stigmas in the left auricle, myocardial fibrous boundary of the intervalvular fibrosa, great vessel roots, and pericardium. The significance of these findings will be taken up in the discussion.

MICROSCOPIC FINDINGS IN FIFTY HUMAN HEARTS AND IN THE HEARTS OF SEVERAL SPECIES OF ANIMALS INJECTED BY WEARN'S TECHNIC

The following pertinent facts concerning the histological structure of the calf's heart should be borne in mind: the spongiosa of the auriculoventricular valves generally contains large quantities of fat tissue; both the ring and the spongiosa layer contain capillaries, arterioles, and arteries which extend for a variable distance toward the free edge of the leaflets; occasional vessels are present within the arterialis layer of these leaflets and capillaries may sometimes be seen within the ventricularis mantle of the intervalvular fibrosa; the collagenous layer (annulus extension) of the latter, however, rarely contains vessels; the aortic ring invariably contains numerous vessels confined to an extraordinarily large ring spongiosa; these vessels generally do not ascend for any appreciable distance toward the free edge of the aortic leaflets—when they do so, however, they lie within the spongiosa layer; reduplications of the proximal valve layers and inflammatory cells are not found in the normal calf's heart. In contrast to this, the blood vessels within the valve leaflets of the supposedly normal human heart valves generally lie within the proximal layers of the valve leaflets and are not infrequently surrounded by scatterings of lymphocytes.

Blood vessels could be seen macroscopically as well as microscopically within the valve leaflets of the uninjected calf hearts. These vessels were also seen in the injected specimens. Furthermore, it was observed that, when the injection technic was varied, this did not appreciably influence the incidence of successful injections. Thus, for example, when the pressure was dropped to as low as 80 mm. of mercury, successful injections were obtained. It is possible, however, that in these specimens there was less complete filling of the vascular network. Similar observations were made on a number of swine and sheep hearts. On the other hand, neither macroscopic nor microscopic studies of injected and uninjected rabbit or guinea pig hearts disclosed

capillaries within the fibroelastic portions of the leaflet, irrespective of the technic employed. It becomes obvious, therefore, that, if blood vessels are present in valve leaflets, no unusual injection technic appears to be necessary for their successful demonstration. Furthermore, however successful the injection technic may be, the results rarely equal the findings as disclosed by microscopic observation. For, even in the

Fig. 7.—Frontal section through 11 cm. (crown-rump) human embryo. Hematoxylin and eosin stain. Medium power.
A, interventricular septum; *B*, wall of left ventricle; *C*, anterior mitral leaflet. Note spongy structure and absence of blood vessels. *D*, left auricle.

Fig. 8.—Frontal section through 30 cm. (crown-rump) ox embryo. Hematoxylin and eosin stain. Medium power.
A, Interventricular septum; *B*, wall of left ventricle; *C*, anterior mitral leaflet. Note spongy structure containing numerous capillaries.

most successful injection, the injection mass does not penetrate every capillary within the valve leaflet or myocardium, whereas microscopic examination invariably reveals these uninjected vessels.

The results of injecting the human hearts were similar to the findings mentioned above. Thus, of the fifty hearts injected by this method, only four showed gross vascularization of the anterior mitral leaflet. All four hearts, however, had gross alterations of the valves, which, though not advanced, were nevertheless suggestive of a healed rheumatic process. This was confirmed by subsequent examination of the above mentioned seventeen cardiac sites. Incidentally, this examination revealed ring capillaries (normal) in several of the hearts, not disclosed by the injection technic. It seems, therefore, that, whenever the heart valves possessed blood vessels, they could be invariably demonstrated microscopically, and while a successful injection afforded a more spectacular display of the vessels, these methods in no way increased the incidence of the discovery of blood vessels; on the contrary, the incidence of valve vasculature as determined by microscopic study was greater than that disclosed by the injection technic.

MICROSCOPIC FINDINGS IN HUMAN EMBRYOS AND IN EMBRYOS OF SEVERAL ANIMAL SPECIES

Examination of serial sections from a large number of human embryos ranging from 4 mm. upward, kindly placed at the author's disposal by Professor George Streeter, of the Carnegie Institute of Embryology, as well as 20 human embryos serially sectioned in these laboratories, failed to disclose myocardium in the primitive valve cushions of the human embryo (Fig. 7). These consist of embryonal myxomatous tissue which is clearly delimited from the spongy myocardium. In the auriculoventricular valves, the apex of the auricular myocardial wedge not infrequently enters the base of the valve structure, but the limits of the portion destined to be the fibroelastic structure are sharp and distinct. Of greatest importance is the fact that, whereas careful search through these serial sections failed to disclose blood vessels within the valve cushions, blood vessels were readily demonstrated within the valve leaflets of ox and swine embryos (Fig. 8).

DISCUSSION

From the findings reported above, it is seen that even when the selection of the so-called normal human vascularized valve series was so carefully made that only 44 out of 4,000 specimens were used for the examination, these specimens showed a very dramatic difference from the normal nonvascularized ones. The latter were conspicuous for the paucity of stigmas in any way resembling those found in the vascularized series. On the other hand, in the so-called normal vascularized valve group, stigmas of previous inflammatory disease were consistently found and bore a more than casual resemblance to those observed in the extinct rheumatic control series. Moreover, in every instance a

number of stigmas were found together in the same heart. The chief sites as noted were the left auricle, the myocardial-fibrous boundary of the intervalvular fibrosa, great vessel roots, and the pericardium. The rather wide distribution of these sites suggests strongly that the lesions found therein were not related anatomically to the vascularization of the valves but bore a common genetic relationship to it. In other words, the same agent produced both the lesions in the various sites mentioned, as well as the vascularization of the valves.

To put it succinctly, these hearts differed completely from normal ones possessing no vessels within their valves. Moreover, statistically as well as anatomically the differences bore a striking resemblance to the findings in a definite rheumatic series. Of great interest is the fact that in four of these cases (9 per cent), Aschoff bodies were found after careful examination of many sites, yet these latter cases did not differ essentially from the so-called normal vascularized series in which no Aschoff bodies were found. As mentioned previously, were it not for the discovery of the Aschoff bodies, these four cases properly belonged in the supposedly normal vascularized valve series. These facts, therefore, together with the close resemblance in the quantity and distribution of the stigmas as well as the presence of delicate reduplications of the proximal layers of the valves, afford the strongest support to the view that the supposedly normal vascularized valve series owes the presence of blood vessels in the valves to a previous mild and, in most instances, completely healed rheumatic process. That activity may still persist in such cases, however, is shown by the finding of Aschoff bodies in 9 per cent of this group of cases. In further support of this contention is the fact that there exists a completely smooth graded series of specimens described by the author with collaborators[31, 32, 34, 36-40] in which the findings range from those demonstrated in indisputable rheumatic hearts (with Aschoff bodies and other typical macroscopic and microscopic lesions) to those described as occurring in this supposedly normal vascularized valve series. Moreover, the findings in the various groups merge imperceptibly from one group into the other.

If it be assumed that another inflammatory disease or diseases may be responsible for the eventual production of these lesions, one should find in an appreciable number of autopsies the acute stages of some hitherto unknown cardiac or other disease which might conceivably produce the same stigmas. Experience with a large material has demonstrated that to all intents and purposes this does not exist. The relatively rare diseases which also implicate the valves, such, for example, as syphilis, tuberculosis, and Libman-Sachs' disease, are associated with characteristic clinical and pathological findings and, moreover, occur statistically in so low a frequency that it is inconceivable that these could be responsible for more than an insignificant propor-

tion of valve vascularization. The conclusion, therefore, is inescapable —that either vascularization does not exist in normal valves leaflets or, if does exist, it must be extraordinarily rare.

In a report by Ritter, Gross, and Kugel[30] dealing with this subject, several possibilities were suggested to account for the existence of blood vessels occasionally found in supposedly normal hearts. Three questions were asked which it seems can now be answered quite definitely. The first one was whether it is possible that these valves had really been the seat of an endocarditis, that granulation tissue blood vessels had in this way been produced, and that all signs of inflammation in the valve had disappeared without leaving appreciable changes other than blood vessels. The answer to this is largely in the affirmative. It must be noted, however, that with more recent knowledge on the rather inconspicuous stigmas or telltale marks of ancient inflammation, appreciable traces are left in these hearts and can be found on careful microscopic examination. In this connection, one should employ the term "tension changes" with considerable reserve. When these take the form of definite reduplications and are associated with thickening of the smooth muscle of the valve leaflets, a careful search should be made for the stigmas referred to above.

The second question asked by Ritter, Gross, and Kugel was whether it is possible that even though many of the blood vessels found in these valves are distinctly of the arterial and venous type, they may have arisen none the less as granulation tissue vessels. The answer to this is also in the affirmative. In recent reports by Gross and Friedberg,[31, 32] it has been shown that, in rheumatic fever, muscular wall arterial vessels can be stimulated to formation in great numbers at various sites within the endocardium of valve leaflets (subaortic angle, arterialis layer, etc.) in which they are otherwise not normally present. Furthermore, during the active phases of rheumatic fever, various stages in the development of these vessels may be found.

The third question asked by the above mentioned authors was whether serial sections might have disclosed evidence of inflammatory lesions in those instances in which single section failed to disclose them. As already mentioned, the newer data on the end-results of inflammatory lesions furnish a means of discerning evidences of past inflammation even without serial sections. It cannot be denied, however, that before a valve can be considered normal, serial sections must be made.

The existence of vascularized valves normally in a number of species of animals has been a stumbling block to many of the investigators in this field, for it is a great temptation to assume that the blood vessels sometimes found in human heart valves are analogous to the former. That this is not the case, however, is clearly shown by the above mentioned findings. When vessels are present in a given species, they can

be found with the greatest ease, they occur consistently, they are not associated with any inflammatory stigmas and they can be found invariably on microscopic examination. On the other hand, injection technic does not demonstrate valve vascularization in those species in which this does not normally occur.

It has already been shown that animals normally possessing vascularized valves also show vessels in sections of the embryo heart valves. The human embryo, however, possesses neither myocardium nor blood vessels in the valves. It appears, therefore, that Langer's contention is no longer tenable and this observation removes any logical basis for the origin of such vessels in normal human heart valves.

There remains, therefore, to discuss the reason for the discrepancies between the findings herein recorded and those reported by other recent observers, particularly by Wearn and his coworkers. It is the contention of the latter authors that with improvement in injection technic, they were able to obtain an increasing incidence in vascularization of human heart valves until it reached 74 per cent. Nevertheless, they point out that in twelve valves from a series of eighty-eight supposedly normal hearts they were able to demonstrate blood vessels microscopically when injection failed to do so. This observation is similar to the one made by the present author in 1921[28] and is confirmed by the studies herein presented. In this connection, it is of interest to note that although the author's injection technic[28] was found superior to that employed by Wearn, apparently no injection technic thus far devised can as faithfully portray the incidence of vascularization or capillarization as can the microscope, particularly if serial sections are used. It appears, therefore, that one must search for another source for the vasculature demonstrated by Wearn and his coworkers.

It has been shown above that human heart valves which possess blood vessels in the fibroelastic portions are not normal. However, to assume that 74 per cent (Wearn's figures*) of hearts coming to autopsy could have been the seat of an inflammatory lesion of the valves is untenable. Although Wearn states that the most common distribution of vessels in the mitral leaflet is an extension of from 3 mm. to 7 mm. into the free leaflet and that in 40 per cent of the vascularized tricuspid valves the vessels extended to about one-half the distance to the free edge, it is suggested that in the majority of his cases (i.e., those not the seat of inflammatory stigmas) this extension below the base possibly represents a macroscopic appraisal of the injection and that a microscopic examination of this material would reveal that these vessels lie in the apex of the auricular myocardial wedges. In estimating the extent of these wedges, it must be borne in mind that

*Since this article was submitted, Wearn and his associates (AM. HEART J. 13: 7, 1937) reported that only 13 per cent of the auriculoventricular valves examined by them would be accepted by Gross and Kugel as being truly vascularized.

sclerotic changes not infrequently produce scarring to such an extent that the limits are not sharp. However, a careful examination of a van Gieson stained preparation will generally reveal isolated myocardial bundles from which the original extent of the wedge may be reconstructed. It is further suggested that the semilunar valves, which displayed vasculature in considerably lower incidence, either belonged to diseased hearts of the type herein described under the group of so-called normal hearts with vascularized valves, or possessed vessels confined to the ring region. A low incidence of vessels in the latter site is apparently normal.

Inasmuch as the thesis with which this report concerns itself deals with the existence of blood vessels situated within the fibroelastic portions of the valve leaflets as defined by Gross and Kugel[1] and employed in these studies, it does not appear to be of any further interest to describe the course of blood vessels which occur in myocardium or such portions of the root of the valve as still possess some extension of the auricular myocardial wedge. The original stimulus to investigate this problem has been to verify or deny Köster's claim[44] that the existence of blood vessels in normal valve leaflets affords an anatomical basis for the assumption that endocarditis is of embolic origin. Although such embolic origin is undoubtedly true, at least in some instances of the bacterial endocarditides, in the light of these studies it cannot serve as an explanation for the origin of rheumatic valvulitis. Furthermore, even if the vessels were conceded to extend for a short distance into the base of the valve, this would certainly not account for the formation of verrucae at the closure line, a considerable distance beyond the base of the valve.

Wearn and his collaborators have shown that according to their figures the incidence of valvulitis does not correspond to the incidence of vascularization of the valves. Thus, valve vascularization was noted by them in the following order of frequency: mitral, tricuspid, pulmonic, aortic. They, therefore, do not link up the incidence of vascularization with that of endocarditis. These findings, however, do not correspond to the observations made in these laboratories. In previous reports, Gross and Friedberg[31, 32] have demonstrated an extraordinarily high incidence of vascularization of the valves in rheumatic fever, this occurring almost invariably in the mitral, aortic and tricuspid valves and somewhat less frequently in the pulmonic. Moreover, approximately the same incidence of vascularization is found in the rings, even when vessels fail to extend into the fibroelastic portion of the leaflet distal to the ring. Thus, the existence of valvulitis parallels the presence of blood vessels provided the ring is considered part of the valve leaflet. As has been shown, however, overwhelming evidence at present available points to the fact that these blood vessels are secondary to the inflammation.

SUMMARY

There have been described in this report the findings in 100 non-vascularized normal human valves, 44 human hearts in which the valves were vascularized but appeared grossly normal, 13 hearts from extinct monovalvular rheumatic disease, 50 human hearts, 50 calf hearts, and a number of rabbit and guinea pig hearts injected by Wearn's technic, as well as a number of uninjected calf, swine, rabbit and guinea pig hearts, and swine, ox and human embryos serially sectioned. It is shown that the so-called normal vascularized human hearts present widespread stigmas which in incidence and distribution bear striking resemblance to the findings in undisputed, extinct rheumatic specimens. Reasons are given which indicate very strongly that rheumatic fever, which has gone on to complete healing, is responsible for the formation of these blood vessels. It is further shown that rheumatic fever can produce muscular vessels as one of the results of granulation tissue evolution. A description is given of the normally vascularized calf heart valves, and attention is drawn to the differences between these valves and their blood vessels, and those sometimes found in human hearts. It is further shown that while ox and swine embryos display blood vessels in their valves, these are not found in the heart valves of human embryos. As a consequence, there exists no rational embryogenetic basis on which to explain the occurrence of blood vessels found in human hearts.

A discussion of injection technic together with new observations reinforces the belief that such technic affords no information to the problem under discussion which cannot be better obtained by microscopic observations on serial sections. The conclusion is drawn that blood vessels do not exist in normal valves or, if they do, they must be very rare.

REFERENCES

1. Gross, Louis, and Kugel, M. A.: Topographic Anatomy and Histology of the Valves in the Human Heart. Am. J. Path. 7: 445, 1931.
2. Langer: Über die Blutgefässe der Herzklappen, Sitzungsb. d. k. Akad. d. Wissensch., Wien 82: 208, 1880.
   Idem: Über die Blutgefässe der Herzklappen bei Endocarditis Valvularis, Virchows Arch., Berl. 109: 465, 1887.
3. Dow, D. Rutherford, and Harper, W. F.: The Vascularity of the Valves of the Human Heart, J. Anat. 66: 610, 1932.
4. Gerlach, E.: Handbuch der allgemeinen und speciellen Gewebelehre, Mainz, 183, 1848.
5. Luschka, H.: Das Endocardium und die Endocarditis, Virchows Arch. 4: 171, 1852.
   Idem: Die Blutgefässe der Klappen des menschlichen Herzens, Sitzungsb. d. k. Akad. d. Wissensch., Wien. math.-nat. Kl. 36: 367, 1859.
   Idem: Die Blutergüsse im Gewebe der Herzklappen, Virchows Arch. 11: 144, 1857.
   Idem: Die Anatomie des Menschen, Tübingen 1: Part 2, 1862.
6. Kölliker, A.: Handbuch der Gewebelehre des Menschen, Leipzig, 539, 1852.
7. Förster: Quoted by Dow and Harper.[3]

8. Henle, J.: Handbuch der systematischen Anatomie des Menschen, Braunschweig 3: 17, 1868.
9. Frey, H.: Handbuch der Histologie und Histochemie, Leipzig, ed. 3, 402, 1870.
10. Rosenstein: Ziemssen's Handbuch, Leipzig 6: 11, 1876.
11. Sappey, P. C.: Anatomie descriptive, Paris, ed. 3, 2: 497, 1876.
12. Krause, W.: Handbuch der menschlichen Anatomie, Hanover 1: 302, 1876.
13. Cruveilhier, J.: Traité d'Anatomie descriptive, Paris, ed. 5, 3: 34, 1877.
14. Cöen, E.: Ueber die Blutgefässe der Herzklappen, Arch. f. mikr. Anat. 27: 397, 1886.
15. Bayne-Jones, S.: Blood Vessels of the Heart Valves, Am. J. Anat. 21: 449, 1917.
Idem: The Blood Vessels of the Heart Valves, Johns Hopkins Hosp. Rep. 18: 181, 1919.
16. Kerr, W. J., and Mettier, S. R.: Circulation of the Heart Valves, Am. Heart J. 1: 96, 1925-26.
17. Kerr, W. J., Mettier, S. R., and McCalla, R. L.: The Capillary Circulation of the Heart Valves in Relation to Rheumatic Fever, Tr. A. Am. Physicians 43: 213, 1928.
18. Wearn, J. T.: The Extent of the Capillary Bed of the Heart, J. Exper. Med. 47: 273, 1928.
Bromer, A. W., Zschiesche, L. J., and Wearn, J. T.: Blood Vessels of Non-Inflammatory Origin in Human Heart Valves, J. Clin. Investigation 7: 487, 1929.
Idem: The Significance of the Presence of Blood Vessels in Heart Valves, Tr. Am. Clinat & Clin. Assn. 47: 1, 1931.
Wearn, J. T., Bromer, A. W., and Zschiesche, L. J.: The Incidence of Blood Vessels in Human Heart Valves, Am. Heart J. 11: 22, 1936.
19. Rokitansky: Handbuch der speciellen pathol. Anatomie, 3 Auflage 2: 297, 1856.
20. Joseph, L.: Ueber die Ringe und Klappen des menschlichen Herzens, Virchows Arch. 14: 244, 1858.
21. Virchow, R.: Reizung und Reizbarkeit, Archiv. f. pathol. Anat. 14: 56, 1858.
22. Cadiat: Sur l'anatomie et la physiologie du coeur, Bull. Acad. de méd., Paris 8: 69, 1879.
23. Darier: Les vaisseaux des valvules du coeur chez l'homme à l'état normal et à l'état pathologique, Arch. de Physiol., Paris 5 and 6: 35 and 164, 1888.
24. Königer: Histologische Untersuchungen über Endokarditis, Arbeiten aus dem Pathologische Institut zu Leipzig, 1903-1908.
25. Odinzow: Vascularization der Herzklappen im Kindesalter, Inaug. Diss., München, 1904.
26. Nussbaum, A.: Über das Gefässsystem des Herzens, Arch. f. mikr. Anat., Bonn 80: 450, 1912.
27. Tandler, J.: Anatomie des Herzens. Bardeleben's Handbuch der Anatomie des Menschen, Jena 3: 1913.
28. Gross, Louis: The Blood Supply to the Heart, New York, 1921, P. B. Hoeber.
29. Kugel, M. A., and Gross, Louis: Gross and Microscopical Anatomy of the Blood Vessels in the Valves of the Human Heart, Am. Heart J. 1: 304, 1926.
30. Ritter, Saul A., Gross, Louis, and Kugel, M. A.: Blood Vessels in the Valves of Normal Human Hearts, Am. Heart J. 3: 433, 1928.
31. Gross, Louis, and Friedberg, Charles K.: Lesions of the Cardiac Valve Rings in Rheumatic Fever, Am. J. Path. 12: 469, 1936.
32. Gross, Louis, and Friedberg, Charles K.: Lesions of the Cardiac Valves in Rheumatic Fever, Am. J. Path. 12: 855, 1936.
33. Rappe: Über Gefässe in den Herzklappen, Diss., Göttingen, 1904.
34. Gross, Louis: Lesions of the Left Auricle in Rheumatic Fever, Am. J. Path. 11: 711, 1935.
35. Sohval, Arthur R., and Gross, Louis: Calcific Aortic Valve Sclerosis (Mönckeberg Type), Arch. Path. 22: 477, 1936.
36. Gross, Louis, and Fried, B. M.: Lesions in the Auriculoventricular Conduction System Occurring in Rheumatic Fever, Am. J. Path. 12: 31, 1936.
37. Gross, Louis: Lesions in the Roots of the Pulmonary Artery and Aorta in Rheumatic Fever, Am. J. Path. 11: 631, 1935.

38. Gross, Louis, and Ehrlich, J. C.: Studies on the Myocardial Aschoff Body: I. Descriptive Classification of Lesions, Am. J. Path. 10: 467, 1934.
Idem: Studies on the Myocardial Aschoff Body: II. Life Cycle, Sites of Predilection and Relation to Clinical Course of Rheumatic Fever, Am. J. Path. 10: 489, 1934.
39. Gross, Louis, Kugel, M. A., and Epstein, Emanuel Z.: Lesions of the Coronary Arteries and Their Branches in Rheumatic Fever, Am. J. Path. 11: 253, 1935.
40. Friedberg, Charles K., and Gross, Louis: Pericardial Lesions in Rheumatic Fever, Am. J. Path. 12: 183, 1936.
41. Gross, Louis, Antopol, William, and Sacks, Benjamin: A Standardized Procedure Suggested for Microscopic Studies on the Heart, Arch. Path. 10: 840, 1930.
42. Hawking, Frank: Latent Acute Rheumatic Carditis as Determined at Autopsy. Its Occurrence, Arch. Int. Med. 54: 799, 1934.
43. Rothschild, M. A., Kugel, M. A., and Gross, Louis: Incidence and Significance of Active Infection in Cases of Rheumatic Cardiovalvular Disease During the Various Age Periods, Am. Heart J. 9: 586, 1934.
44. Köster, K.: Die embolische Endocarditis, Virchows Arch. 72: 257, 1878.

STUDIES IN CARDIOVASCULAR SYPHILIS

I. Teleroentgenography in the Diagnosis of Early Syphilitic Aortitis: A Comparison of Findings in 1,000 Syphilitic and 600 Nonsyphilitic Individuals*

Jarold E. Kemp, M.D., and K. D. Cochems, M.D.
Chicago, Ill.

CURRENT interest in the diagnosis of cardiovascular syphilis centers in the effort to recognize early syphilitic aortitis uncomplicated by aortic insufficiency or saccular aneurysm. The prevention of these later and usually fatal complications depends in part on the adequacy of treatment of early syphilis, but much more largely, considering the relatively small number of recently infected persons who receive such adequate treatment, on the recognition of the aortic lesion before it has produced irreparable anatomical damage.

The failure to recognize early aortitis in the living patient is due in part to the often silent course of the lesion and in part to confusion arising from the fact that the symptoms and clinical signs which it produces may be closely duplicated by two common nonsyphilitic conditions—essential hypertension and arteriosclerosis. The great discrepancy which exists between the clinical and autopsy diagnosis of early syphilitic aortic disease has been pointed out by Moore, Danglade, and Reisinger,[1] who found that only 4, or 3.8 per cent, of 105 cases of syphilitic aortitis proved at autopsy had been diagnosed during life.

With added clinical experience, however, many observers have acquired increasing confidence in their ability to diagnose early aortitis correctly in a high proportion of cases. By the expedient of clinical restudy of living patients, Moore and Metildi,[2] for example, have shown that 19.1 per cent of 115 patients diagnosed as uncomplicated aortitis subsequently developed indubitable and graver forms of cardiovascular syphilis, thereby establishing the validity of the earlier and more difficult diagnosis. In an additional 35.6 per cent, there was presumptive evidence that the original diagnosis was correct. These workers feel, therefore, that in certain instances, the diagnosis of aortitis may be safely made even in the presence of essential hypertension and arteriosclerosis, or both. They list seven diagnostic criteria for uncomplicated syphilitic aortitis as follows: "(1) Teleradiographic and fluoroscopic evidence of aortic dilatation; (2) increased retromanubrial dullness; (3) a history of circulatory embarrassment; (4) a tympanitic bell-like, tambour accentuation of the aortic second

*From the Syphilis Division of the Public Health Institute, Chicago, Ill.

sound; (5) progressive cardiac failure; (6) substernal pain, and (7) paroxysmal dyspnea." They insist that to justify the diagnosis of uncomplicated aortitis, at least three of the above criteria must be present in a patient with known late syphilis but without mitral disease. Their point of view has not yet met with general acceptance.

Since aortic dilatation is a prominent feature of syphilitic aortitis at autopsy, it is not surprising that many roentgenological studies have been carried out in the effort to aid in its early diagnosis. As a result of these studies, most workers in this field are agreed that in syphilitic aortitis there is usually diffuse dilatation and loss of elasticity of the aorta, increased density of the root and sometimes of the knob, and, in particular, localized dilatation and excessive pulsation of the first portion of the ascending aorta (Steel,[3] Sproull,[4] Brown,[5] Kurtz and Eyster,[6] and Hampton, Bland, and Sprague[7]). Opinions concerning the value of roentgenological studies in the diagnosis of uncomplicated syphilitic aortitis are conflicting. However, a few observers, particularly Maynard and his associates,[8] believe that in certain instances the diagnosis of simple aortitis may be made by teleroentgenogram even in the absence of symptoms or clinical signs. Most roentgenologists feel that in order to obtain an accurate estimate of the aortic shadow, fluoroscopy must be combined with one of the more exact methods of accurate measurements of the outline of the heart and great vessels: orthodiagraphy, kymography, or teleroentgenography.

PROBLEM

Since teleroentgenography is the method most commonly used for mensuration of the aortic shadow, this study was undertaken to determine as accurately as possible its value in the diagnosis of early uncomplicated syphilitic aortitis. Having available data on a large number of unselected syphilitic and nonsyphilitic individuals with identical cardiac examinations, including teleroentgenographic studies, it occurred to us that a comparison of the two groups might provide a more accurate answer than previous studies of smaller groups of patients.

Material Studied

The material of this study is compiled from the records of patients admitted to the Public Health Institute during the past thirteen years. Prior to its reorganization in 1931, cardiovascular examinations, including a complete medical history and physical examination, at least two blood pressure observations, a teleroentgenogram, and an electrocardiogram, were required of the majority of patients whether or not they had venereal disease. While these procedures are evidently unnecessary except in patients with syphilis, and have since been discontinued, the material gathered in the application of this routine has

made available for analysis and comparison a large amount of information about both syphilitic and nonsyphilitic individuals of analogous age, sex, and occupational groups.*

The method of study in all patients was as follows: About 2,500 x-ray films of nonsyphilitic and syphilitic persons were examined. Of these, nearly a thousand were discarded because of technical imperfections in the roentgenogram: i.e., films blurred, not centered properly, stained by chemical deterioration, or unmeasurable as to aortic width because of other mediastinal shadows. When the roentgenogram was sufficiently satisfactory to permit accurate measurements of the Vaquez-Bordet[9] aortic arch width and of the size of the heart, the patient's history was withdrawn from the files and analyzed for the pertinent factors of race, sex, age, the presence or absence of nonsyphilitic heart disease, including the presence or absence of peripheral arteriosclerosis, blood pressure, cardiac, and Vaquez-Bordet aortic arch measurements, the presence or absence of syphilitic infection, the duration of syphilis when known, the type and amount of antisyphilitic treatment received by the patient before coming to this clinic or before the cardiac examination was made, the presence or absence of syphilitic heart disease, the results of fluoroscopic examination, and the presence of signs or symptoms of uncomplicated syphilitic aortitis. These data were transferred to punch cards through the courtesy of Dr. Herman N. Bundesen, Commissioner of Health of Chicago, and were subjected to statistical analysis. It is felt that the manner in which this material was selected guarantees against possible artificial selection and precludes the question of the unconscious selection of material by reference from a syphilis to a cardiac clinic. There were available 600 records of nonsyphilitic individuals and 1,000 of persons with syphilis.

The absence of syphilis in the group of 600 nonsyphilitic persons was determined by the absence of a history of infection and of symptoms or physical signs attributable to syphilis, and by the presence of a negative serological test in each member of the series. The existence of syphilis in the 1,000 syphilitic patients was established in every instance by indisputable anamnestic, clinical, or laboratory evidence. All stages of syphilitic infection are represented from the chancre to general paresis.

RESULTS

A summary and comparison of the syphilitic and nonsyphilitic material by age groups and by the presence or absence of cardiovascular abnormalities is presented in Tables I and II.† A tabulation by sex

*We wish to express our thanks to Dr. Joseph Earle Moore for his advice and help in the compilation of these data and to Miss Usilton, of the U. S. Public Health Service, for the preparation of the scatter charts published herewith.

†In the compilation of these data it was realized that the Vaquez-Bordet method of measuring the width of the supracardiac shadow is not a true estimate of the diameter of the aorta. It was adopted, however, because it is the method most commonly used in interpreting teleroentgenographic studies of the cardiovascular stripe.

is omitted, since the group of females is small and since there were no striking differences between the sexes. The 600 nonsyphilitic persons included 478 males and 122 females; the 1,000 syphilitic patients, 749 males and 251 females. An analysis by race is also omitted since of the 600 nonsyphilitics 96.5 per cent were white, and only 3.5 per cent were colored; and of the 1,000 syphilitics 92.6 per cent were white, and 7.4 per cent were colored. The age groups selected are 0 to 19 years, and thence by decades until the age of 50 years, after which all decades are grouped together because of the small number of patients available in each of the separate later decades. As shown in Table I, 29.8 per cent of the 600 nonsyphilitic individuals had some

TABLE I

NONSYPHILITIC PATIENTS ACCORDING TO AGE GROUPS AND TYPE OF CARDIOVASCULAR ABNORMALITY

AGE	TOTAL CASES	NO CARDIOVASCULAR ABNORMALITY	TOTAL WITH SOME FORM OF CARDIOVASCULAR ABNORMALITY	TYPE OF CARDIOVASCULAR ABNORMALITY			
				RHEUMATIC HEART DISEASE	THYROID HEART DISEASE	ESSENTIAL HYPERTENSION	ARTERIOSCLEROSIS WITH AND WITHOUT HYPERTENSION
0-19	17	14	3 (11.7%)	2	-	1	-
20-29	225	208	17 (7.5%)	11	2	4	-
30-39	135	112	23 (17.0%)	10	1	6	6
40-49	111	68	43 (38.7%)	5	-	4	34
50+	112	19	93 (83.0%)	3	-	1	89
Total	600	421	179 (29.8%)	31	3	16	129

demonstrable abnormality of the cardiovascular apparatus. This was practically the same as the incidence of nonsyphilitic heart disease (30.6 per cent) occurring either alone or in combination with syphilitic heart disease among the 1,000 syphilitic patients (Table II). In both

TABLE II

SYPHILITIC PATIENTS CLASSIFIED ACCORDING TO AGE GROUPS AND TYPE OF CARDIOVASCULAR ABNORMALITY

AGE	TOTAL CASES	NO CARDIOVASCULAR ABNORMALITY	NO. WITH UNCOMPLICATED CARDIOVASCULAR SYPHILIS	NO. WITH NONSYPHILITIC CARDIOV. ABNOR.			TYPE OF NONSYPHILITIC CARDIOVAS. ABNORMALITY			
				AND SYPHILITIC CARDIOVASCULAR DISEASE	WITHOUT SYPHILITIC CARDIOVASCULAR DISEASE	TOTAL	RHEUMATIC HEART DISEASE	THYROID HEART DISEASE	ESSENTIAL HYPERTENSION	ARTERIOSCLEROSIS WITH AND WITHOUT HYPERTENSION
0-19	10	8	1	-	1	1	-	-	1	-
20-29	184	161	2	-	21	21	10	1	10	-
30-39	304	263	10	1	30	31	10	-	13	8
40-49	272	131	33	10	98	108	7	-	34	67
50+	230	58	27	43	102	145	3	-	3	139
Total	1000	621	73	54	252	306	30	1	61	214

groups of individuals and in both sexes, the incidence of some form of nonsyphilitic cardiovascular abnormality rises steadily with each decade and is apparently due to the rising incidence of hypertension and arteriosclerosis.

The patients with cardiovascular syphilis have been divided into four groups, based on the usually accepted standards of diagnosis: i.e., (1) aortic insufficiency occurring in the absence of a history of rheumatic fever and uncomplicated by mitral disease; (2) saccular aneurysm, in this series always of the thoracic aorta; (3) aortic insufficiency and aneurysm occurring together; and (4) simple or uncomplicated syphilitic aortitis. In all instances the last diagnosis was

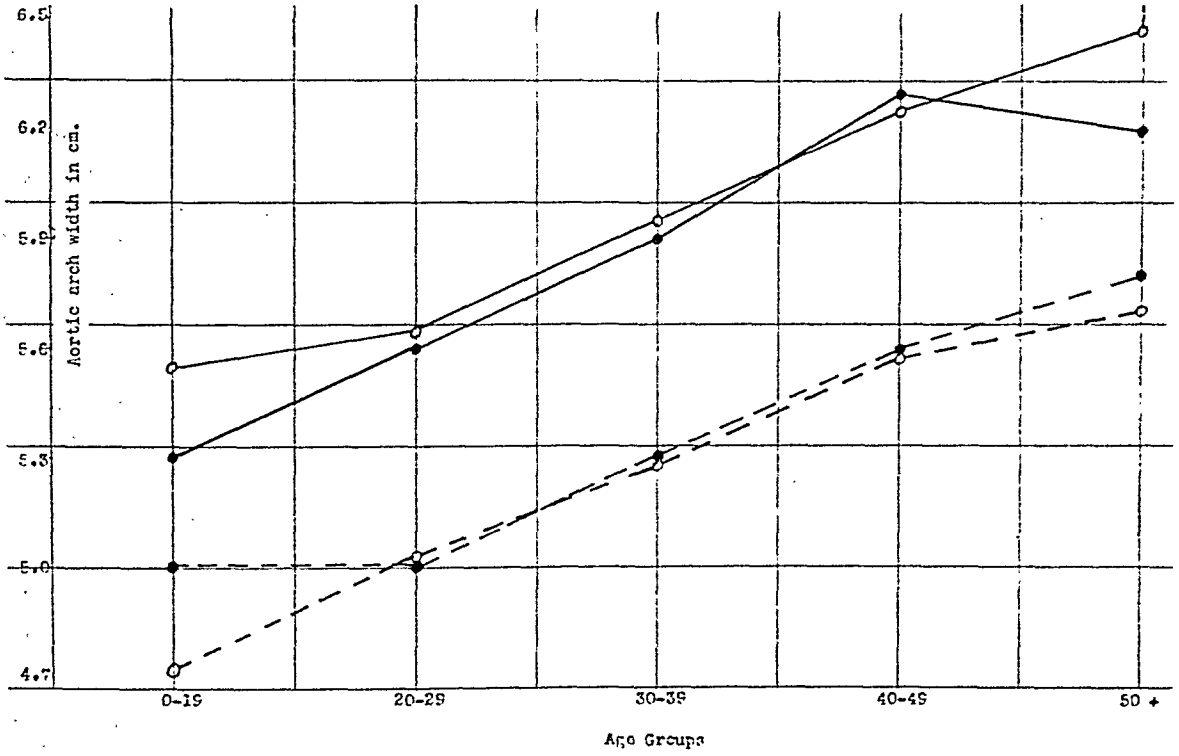

Fig. 1.— .—. Nonsyphilitic males without heart disease of any type; .---. nonsyphilitic females without heart disease of any type; o—o syphilitic males, excluding nonsyphilitic heart disease and cardiovascular syphilis; o---o syphilitic females, excluding nonsyphilitic heart disease and cardiovascular syphilis.

made on the basis of the presence of at least three of the criteria suggested by Moore and Metildi,[2] and in none does the diagnosis rest on roentgenological evidence alone. These results are shown in Table III. As is to be expected, the incidence of cardiovascular syphilis in any form, and particularly in the more serious forms, increases with advancing age.

The relationship of age to aortic dilatation demonstrable by teleroentgenogram has been approached in two ways. In Fig. 1 is shown the arithmetical average of the Vaquez-Bordet measurement by sex and age groups for (1) all nonsyphilitic patients with no evidence of cardiovascular abnormality of any type and (2) all syphilitic patients,

TABLE III

TYPE OF SYPHILITIC HEART DISEASE ENCOUNTERED IN 1,000 SYPHILITIC PERSONS

AGE GROUPS	TOTAL CASES	SYPHILITIC HEART DISEASE—COMPLICATED OR UNCOMPLICATED	TYPE OF SYPHILITIC HEART DISEASE—COMPLICATED AND UNCOMPLICATED			
			AORTITIS	AORTIC INSUFFICIENCY	ANEURYSM	AORTIC INSUFFICIENCY AND ANEURYSM
0-19	10	1 (10.0%)	1	-	-	-
20-29	184	2 (1.0%)	2	-	-	-
30-39	304	11 (3.6%)	8	3	-	-
40-49	272	43 (15.8%)	22	7	8	6
50+	230	70 (30.4%)	9	10	39	12
Total	1000	127 (12.7%)	42	20	47	18

excluding those with both nonsyphilitic and syphilitic heart disease but including those in whom the only evidence of aortitis was an increase in the width of the aortic arch shadow. Considering, therefore, only those nonsyphilitic and syphilitic patients with clinically normal cardiovascular systems, there is no apparent tendency of syphilis per se to produce aortic dilatation over and above the degree to be expected with the passage of years.

Since averages do not correctly represent the entire story, the maximal and minimal aortic arch widths observed are presented by age and sex in Table IV. Both in nonsyphilitic and syphilitic patients with no clinical evidence of any form of heart disease, the maximum aortic arch width observed was 7.6 cm. in males (age group 40 to 49

TABLE IV

EXTREME VARIATIONS OF AORTIC ARCH WIDTH IN NONSYPHILITIC AND SYPHILITIC PATIENTS OF VARIOUS AGE GROUPS WITH AND WITHOUT HEART DISEASE (NONSYPHILITIC IN ROMAN TYPE, SYPHILITIC IN ITALICS)

SEX	AGE GROUP	EXTREME VARIATIONS OF AORTIC ARCH WIDTH, CM.		
		NO HEART DISEASE	HEART DISEASE NONSYPHILITIC	SYPHILITIC HEART DISEASE COMPLICATED OR UNCOMP.
M	0-19	4.7 - 5.8	5.5 - 5.5	-
		4.1 - 6.2	*5.4 - 5.4*	-
	20-29	4.1 - 7.3	5.2 - 7.2	-
		4.5 - 7.5	*4.8 - 6.3*	*5.7 - 7.5*
	30-39	4.5 - 7.0	6.2 - 7.6	-
		4.5 - 7.1	*5.5 - 7.2*	*6.0 - 8.6*
	40-49	5.2 - 7.6	6.3 - 9.8	-
		4.8 - 7.6	*5.3 - 7.9*	*5.5 - 13.0*
	50+	5.5 - 6.8	6.2 - 9.7	-
		5.2 - 7.0	*5.3 - 9.4*	*5.5 - 13.0*
F	0-19	4.2 - 5.8	4.5 - 5.0	-
		4.7 - 5.1	- -	-
	20-29	4.2 - 5.9	4.4 - 4.5	-
		3.9 - 6.0	*3.9 - 7.6*	-
	30-39	3.9 - 7.0	5.0 - 8.0	-
		4.3 - 6.6	*5.0 - 6.9*	*6.2 - 7.5*
	40-49	5.2 - 6.4	5.6 - 7.5	-
		4.8 - 6.6	*5.6 - 7.9*	*5.9 - 8.3*
	50+	5.5 - 6.1	5.8 - 8.0	-
		5.2 - 6.2	*6.0 - 7.1*	*6.0 - 8.8*

years), and 7 cm. in females (age group 30 to 39 years). In both sexes, however, in patients over the age of 50 years, and in the presence of nonsyphilitic heart disease (usually hypertension plus arteriosclerosis), the maximum width for males was 9.7 cm. and for females 8.0 cm. These measurements are far in excess of those of many individuals with outspoken cardiovascular syphilis. The extreme limits of 13 cm. in patients with syphilitic heart disease are, of course, accounted for by saccular aneurysms.

In order to give a somewhat clearer comparison of a nonsyphilitic with a syphilitic population, a scatter chart has been prepared (Fig. 2), showing the distribution of all nonsyphilitic patients with and without cardiovascular abnormalities by age groups compared with aortic arch width, and a regression or trend line is indicated. The

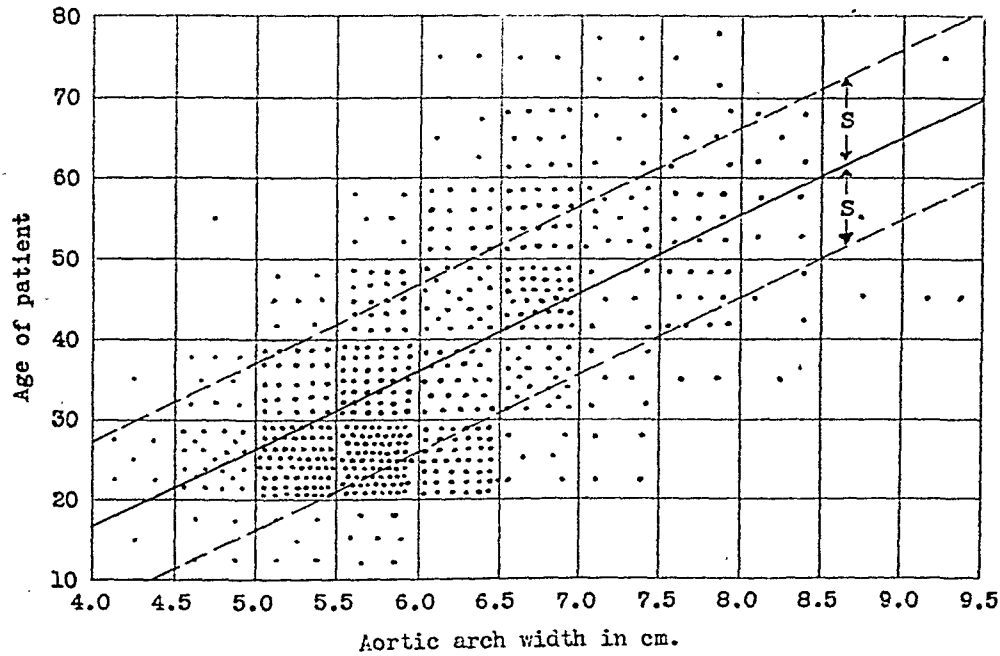

Fig. 2.—Six hundred nonsyphilitic patients.

"S" area is the standard error of estimate, showing how nearly the estimated values agree with the values actually observed. In this figure the area included between the two broken lines contains approximately 71 per cent* of all observed values. In this group the standard error of estimate is quite high, and the trend line permits an estimate of the aortic width of a patient of a given age group only within ten years. For example, the regression line shows that patients 50 years of age have an average aortic arch width of 7.5 cm., but the same value can be expected in patients aged 40 to 60 years.

Figure 3† shows regression lines based on the coefficient of correlation between age and aortic arch width in three groups of patients:

*$\frac{100 \times Sy}{Oy}$

†Thanks are due Dr. Paul D. Rosahn for his aid in the statistical interpretation of these data.

(1) 600 nonsyphilitics; (2) 915 syphilitic patients, excluding those with aortic insufficiency and saccular aneurysm, but including those with uncomplicated aortitis; (3) 85 syphilitic patients with advanced cardiovascular syphilis, aortic insufficiency and aneurysm. The coefficients of correlation between age and aortic width for these three groups were as follows:

$$(1)\ r = +0.6281 \pm 0.0247;\ r^2 = 0.39$$
$$(2)\ r = +0.5897 \pm 0.0216;\ r^2 = 0.35$$
$$(3)\ r = +0.3205 \pm 0.0997;\ r^2 = 0.10$$

In each case the correlation coefficient is more than two and a half times its standard error, and they are all, therefore, statistically significant. The appended value of r^2, which is termed the coefficient of determination, shows what percentage of the variation in the depend-

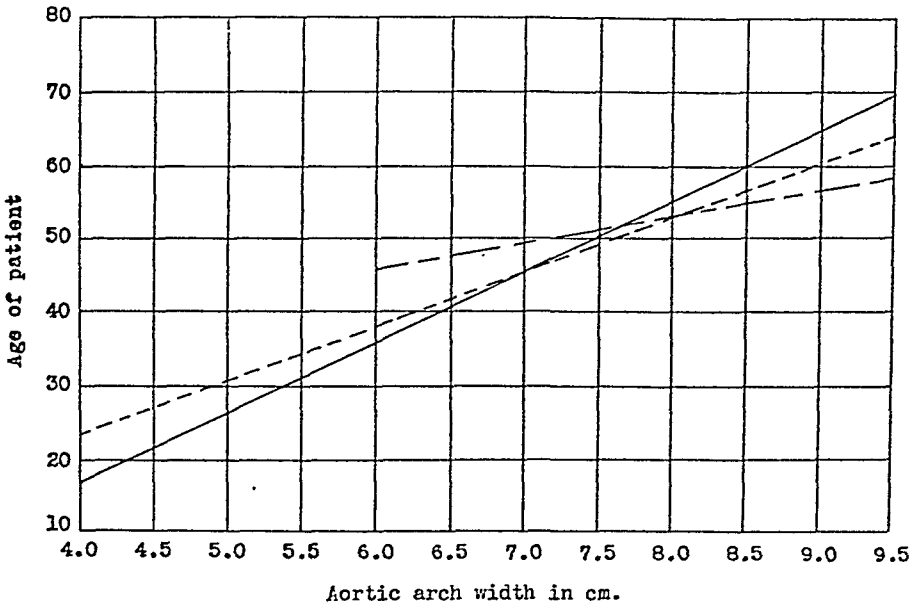

Fig. 3.—Comparison of aortic arch widths in centimeters in syphilitic and nonsyphilitic individuals according to age of patient.

—— Nonsyphilitic patients (600 cases); ---- syphilitic patients (excluding aortic insufficiency and saccular aneurysm, but including uncomplicated aortitis) (915 cases); — — — patients with cardiovascular syphilis (excepting uncomplicated aortitis) (85 cases).

ent variable is explained by the independent variable. In the nonsyphilitic group only 39 per cent of the increasing aortic arch width was due to increasing age, the rest having been caused by other factors such as arteriosclerosis, hypertension, etc. Similarly, in the syphilitic patients without syphilitic heart disease, except uncomplicated aortitis, only 35 per cent of the increasing aortic arch width with increasing age can be explained by the increasing age of the patient. In the 85 cases of aortic regurgitation and aneurysm, however, only 10 per cent of the widening of the arch shadow is due to the increasing age of the patient, the remaining 90 per cent being presumably due to syphilis plus the other factors operative in nonsyphilitic persons.

In Table V is shown in somewhat simplified form the incidence of aortic dilatation in nonsyphilitic patients as affected by the existence of various forms of nonsyphilitic cardiovascular abnormalities. The aortic widths are here classified in three categories, corresponding with the classification used by Maynard, i.e., normal, aortic arch widths up to 6.7 cm. in males, and to 6.2 cm. in females; borderline dilatation, from 6.7 cm. to 7.0 cm. in males, and from 6.2 cm. to 6.5 cm. in females; and definite aortic dilatation, 7.1 cm. or more in males, and 6.6 cm. or more in females. According to this classification, borderline or definite aortic dilatation occurs in 7.4 per cent of normal individuals. Rheumatic heart disease and hypertension alone account for an unexpectedly small increase in aortic width in this series of cases. Arteriosclerosis, with and without hypertension, is obviously the factor which produces aortic dilatation in nonsyphilitic patients in the majority of instances.

TABLE V

COMPARISON OF AORTIC ARCH WIDTHS (MAYNARD'S CLASSIFICATION) IN 600 NONSYPHILITIC INDIVIDUALS ACCORDING TO PRESENCE OR ABSENCE AND TYPE OF NONSYPHILITIC HEART DISEASE

AORTIC WIDTH	PER CENT OF PATIENTS WITH*				
	NO HEART DISEASE	RHEUMATIC HEART DISEASE	HYPERTENSION	ARTERIOSCLEROSIS	ARTERIOSCLEROSIS AND HYPERTENSION
Normal†	92.4	78.6	75.0	18.6	36.6
Borderline‡	5.4	7.1	6.2	16.2	12.6
Dilated§	2.0	14.2	18.7	65.1	50.7

*Omitting 3 patients with thyroid heart disease.
†Males, aortic width up to 6.7 cm.; females, aortic width up to 6.2 cm.
‡Males, aortic width from 6.8 to 7.0 cm.; females, aortic width 6.3 to 6.5 cm.
§Males, aortic width 7.1 cm. or over; females, aortic width 6.6 cm. or over.

TABLE VI

COMPARISON OF AORTIC ARCH WIDTHS (MAYNARD'S CLASSIFICATION) IN 1,000 SYPHILITIC INDIVIDUALS WITH AND WITHOUT HEART DISEASE

AORTIC WIDTH	NO HEART DISEASE	SYPHILITIC AORTITIS, COMPLICATED AND UNCOMP.	AORTIC INSUFFICIENCY AND ANEURYSM, COMPLICATED AND UNCOMPLICATED	NONSYPHILITIC HEART DISEASE ONLY*			
				RHEUMATIC	ESSENTIAL HYPERTENSION	ARTERIOSCLEROSIS	ARTERIOSCLEROSIS AND HYPERTENSION
	PER CENT	PER CENT	PER CENT	PER CENT	PER CENT	PER CENT	PER CENT
Normal†	92.1	22.5	3.7	83.3	89.2	51.4	49.2
Borderline‡	2.9	17.8	3.7	12.5	5.4	21.6	18.0
Dilated§	5.0	59.7	92.6	4.2	5.4	27.0	32.8

*Omitting one patient with thyroid heart disease.
†Males, aortic width up to 6.7 cm.; females, aortic width up to 6.2 cm.
‡Males, aortic width from 6.8 to 7.0 cm.; females, aortic width 6.3 to 6.5 cm.
§Males, aortic width 7.1 cm. or over; females, aortic width 6.6 cm. or over.

A similar classification of the syphilitic patients is provided in Table VI. As shown by this table, borderline and definite aortic dilatation occurred with the same frequency (7.9 per cent) in the 593 syphilitic individuals without demonstrable heart disease of any type as in the 422 nonsyphilitics without heart disease (7.2 per cent). The inclusion among the group of syphilitics without heart disease of patients with aortic dilatation but no other evidence of early aortitis, adds to the significance of this observation. It is of interest to note also that 22.5 per cent of the patients with aortitis had no teleroentgenographic evidence of aortic widening and that unquestionable aortic dilatation was present in only 59.7 per cent of the group.

SUMMARY AND CONCLUSIONS

In an attempt to evaluate aortic mensuration by teleroentgenography in the diagnosis of uncomplicated early syphilitic aortitis, we have compared 1,000 unselected syphilitics with 600 unselected nonsyphilitic individuals of the same occupational, sex, and age groups. The Vaquez-Bordet measurement of the supracardiac shadow was used in comparing the width of the aortic arch. In every instance the presence or absence of syphilis was established without question, and all patients were subjected to identical cardiovascular studies. A compilation of these data showed that:

1. The incidence of cardiovascular syphilis among the group of 1,000 syphilitic patients was essentially the same as that noted by others who had also studied large groups of patients.
2. The increased widening of the supracardiac shadow resulting from essential hypertension and arteriosclerosis with or without hypertension was the same in nonsyphilitic as in syphilitic individuals without syphilitic heart disease.
3. The increase in the width of the aortic arch shadow as a result of advancing age was the same in both syphilitic and nonsyphilitic individuals without heart disease.
4. Only 59 per cent of the patients with clinically recognizable syphilitic aortitis showed teleroentgenographic evidence of aortic dilatation.
5. There is no evidence that the diagnosis of uncomplicated syphilitic aortitis can be made by teleroentgenography alone. Fluoroscopy and careful clinical evaluation of symptoms and physical signs are essential.

REFERENCES

1. Moore, J. E., Danglade, J. H., and Reisinger, J. D.: Diagnosis of Syphilitic Aortitis Uncomplicated by Aortic Regurgitation or Aneurysm, Arch. Int. Med. 49: 766, 1932.
2. Moore, J. E., and Metildi, P. F.: Uncomplicated Syphilitic Aortitis: Diagnosis, Prognosis and Treatment, Arch. Int. Med. 52: 978, 1933.
3. Steel, D.: The Roentgenological Diagnosis of Syphilitic Aortitis—A Review of Forty Proved Cases, Am. Heart J. 6: 59, 1930.

4. Sproull, J.: Roentgen Study of Thoracic Aorta—A Summary, New England J. Med. 205: 83, 1931; Status and Clinical Application of Roentgenology of the Thoracic Aorta, Am. J. Roentgenol. 28: 37, 1932.
5. Brown, S.: The Roentgenologic Study of the Thoracic Aorta, Radiology 20: 343, 1933.
6. Kurtz, C. M., and Eyster, J. A. E.: Fluoroscopic Studies of the Heart and Aorta in Acquired and Congenital Syphilis, Am. Heart J. 6: 67, 1930.
7. Hampton, A. O., Bland, E. F., and Sprague, H. B.: Further Studies of the Aorta With Special Reference to Luetic Aortitis, Am. Heart J. 6: 77, 1930.
8. Maynard, E. P., Jr., Curran, J. A., Rosen, I. T., Williamson, C. G, and Lingg, Claire: Cardiovascular Syphilis: Early Diagnosis and Clinical Course of Aortitis in Three Hundred and Forty-Six Cases of Syphilis, Arch. Int. Med. 55: 873, 1935.
9. Vaquez, H., and Bordet, E.: The Heart and the Aorta, New Haven, Conn., 1920, Yale University Press.

THE ELECTROCARDIOGRAM IN HYPERTENSION WITH ESPECIAL REFERENCE TO LEAD IV*

C. L. C. van Nieuwenhuizen, M.D., and H. A. Ph. Hartog, M.D.
Utrecht, Netherlands

INTRODUCTION

THE conception of the significance of the electrocardiogram in cases of hypertension has been influenced by the efforts to make a special use of electrocardiography in studying the condition of the heart muscle and the coronary arteries. Although of theoretical interest, its knowledge at first seemed to be of little or no clinical importance; however others, as well as we, have lately gathered adequate evidence to the contrary. Experiments as well as clinical observations proved means to increase the knowledge concerning the myocardium in the different forms of hypertension. Nevertheless, important problems remained unsolved. Using thoracic leads as a routine method† combined with the standard leads, it appears to us that we have gained fresh insight into the origin and also into the cause of absence of a number of characteristic changes in the electrocardiogram.

In a total of 2,000 curves, we found 228 cases of hypertension with which we tried to answer the following questions:

1. To what degree do hypertension and left axis deviation coincide? What is the cause of absence of left axis deviation in cases of distinct hypertension?

2. What is the significance of the negative T-wave in Lead I and of the positive T-wave in Lead III in cases of left axis deviation?

3. Are the convexity of the S-T line in Lead I and the concavity of the S-T line in Lead III in electrocardiograms with left axis deviation of any clinical interest?

4. What are the electrocardiographic differences between the curves found in cases of pronounced left axis deviation and those brought about by coronary thrombosis or those occurring in bundle or bundle-branch block?

5. Is it justifiable to attach clinical importance to the occurrence of an S-wave in Lead IV followed by an extreme convexity of the S-T line?

I. HYPERTENSION AND LEFT AXIS DEVIATION

A. Data.—Hypertension and so-called left axis deviation (R_1 being higher than 12 mm. and S_3 lower than –5 mm.) do not always coincide; neither is the height of the blood pressure directly proportional to the

*From the Medical Clinic of the State-University at Utrecht, Prof. Dr. A. A. Hijmans van den Bergh, director.

†For technical details see Nederl. Tijdschr. v. Geneesk. 80: 225, 1936.

degree of left axis deviation. Although in cases of a pronounced increase of the systolic blood pressure R_1 is usually found higher and S_3 lower than normal, exceptions are not rare. Conversely, left axis deviation is found sometimes in cases of normal systolic blood pressure; for instance, in aortic valve defects and mitral insufficiency, and in one case, in spite of hypertension, we found right axis deviation in mitral stenosis (S_1 low in regard to R_1 and R_1 low and R_3 too high in regard to R_2 and R_1). Among 100 patients with a systolic blood pressure over 150 mm. Ziskin[1] found only 44 cases of left axis deviation, Nuzum and Elliot[2] found 60 per cent; and other investigators[3] also have drawn attention to the frequent absence of left axis deviation in cases of hypertension. According to Ziskin[1] moreover, left axis deviation occurs less often when the blood pressure is over 200 mm. mercury than when the tension is from 150 to 200 mm. These figures apply to standard leads only. When the changes in the thoracic leads are taken into consideration, altogether different figures are obtained. In the thoracic lead as we record it (right arm electrode in fourth left intercostal space near the sternum—left leg electrode) the R-wave never exceeds +17 mm. (1 mm. volt corresponding to 1 cm. string deviation), and Q is never under −2 mm. In the thoracic lead left axis deviation manifests itself by an increase in height of the R-wave and a decrease in depth, and sometimes disappearance, of the Q-wave. The relation R:Q, normally averaging about 2 and showing extremes of 8 and about 1, now amounts to 10 and more. Cases of coronary thrombosis with anterior infarction in which the so-called C_2-type occurs[4] and curves resulting from bundle-branch or arborization block should be excluded.

In 228 cases of hypertension we found:

Left axis deviation in standard leads only	20 per cent
Left axis deviation in standard and thoracic leads	44 per cent
Left axis deviation in thoracic leads only	19 per cent
Left axis deviation completely absent	17 per cent

In other words, 64 per cent showed left axis deviation in standard leads, a result which very nearly approaches that of Nuzum and Elliot; the thoracic lead being used in addition, a left axis deviation was found in 83 per cent of the cases. Ziskin is of the opinion that the frequency of left axis deviation decreases with tensions over 200 mm. We found a frequency as given in Table I. The frequency of the left axis devia-

TABLE I

SYST. BL. PRESS., LEFT AXIS DEV.	IN I-IV*	IN I-III	IN IV ONLY	ABSENT
150-200 mm. (94 cases)	38%	20%	20%	22%
200-250 mm. (75 cases)	47%	12%	21%	20%

*Lead IV, thoracic lead (fourth left intercostal space—left leg electrode).

tion, manifesting itself in standard leads only, decreases slightly with an increase in tension; on the other hand, the left axis deviation occurring in all leads increases, thereby causing a slight increase in the total left axis deviation in cases with a tension of over 200 mm. mercury.

We have studied this same relation for the diastolic blood pressure and have arranged the results in Table II. The increase in left axis

TABLE II

DIAST. BL. PRESS., LEFT AXIS DEV.	IN I-IV	IN I-III	IN IV ONLY	ABSENT
0-100 mm. (96 cases)	40%	31%	16%	13%
100-150 mm. (116 cases)	41%	13%	24%	22%

deviation recorded in Lead IV is smaller than its decrease in the standard leads, thus resulting in a decrease of nearly 10 per cent of the total left axis deviation when the diastolic blood pressure exceeds 100 mm. mercury.

Our figures for the pulse pressure are as given in Table III. This shows that the left axis deviation is influenced little or not at all by the pulse pressure.

TABLE III

PULSE PRESSURE, LEFT AXIS DEV.	IN I-IV	IN I-III	IN IV ONLY	ABSENT
25- 75 mm. (98 cases)	43%	23%	18%	16%
75-125 mm. (121 cases)	41%	21%	19%	19%

In summary, we have found that left axis deviation does not occur much more often when the systolic blood pressure is 200-250 mm. than when it is 150-200 mm. but that its frequency certainly does not decrease either. In case the diastolic blood pressure increases, the left axis deviation decreases, in standard leads, but at the same time it increases in the thoracic leads, resulting in a slight decrease of the total left axis deviation when the diastolic blood pressure exceeds 100 mm. Hg. The amount of pulse pressure has little or no influence on the frequency or the degree of left axis deviation, no distinct connection being found between the amount of blood pressure and left axis deviation. We considered the possibility of a relationship between left axis deviation and dilatation of the heart. As in most cases an x-ray picture had been taken (at a distance of 2 m.); we were able to determine the heart measurements. We used the measure Dl + Dr according to Dietlen and Moritz,[5] because the results of more accurate methods, while more exact (Danzer's cardiothoracic ratio,[6] the prediction figures of Hodges and Eyster[7]) and other methods[8] are not more reliable.

The best results seem to be obtained by examining the heart *in vivo* before the screen and the x-ray picture before the light box. We determined the distance from a vertical line through the center of the

sternum to the left vertical tangent of the heart (Dl) and found the incidence as given in Table IV. The above figures show that, generally speaking, the left axis deviation increases distinctly with the dilatation of the left ventricle; only in Lead IV did the occurrence of left axis deviation decrease distinctly. So far as our figures allow any conclusion, it seems remarkable that the frequency of left axis deviation decreases slightly at a dilatation of Dl = 10.5 – 12.5 cm. (especially in the arteriosclerotic hypertension group). In determining the total width of the heart, the relation is found as given in Table V. Here, too, we

TABLE IV

LEFT AXIS DEVIATION	IN I-IV	IN I-III	IN IV ONLY	ABSENT
Dl up to 9.5 cm. (62 cases)	31%	14%	23%	32%
Dl 9.5-10.5 cm. (54 cases)	60%	13%	15%	12%
Dl 10.5-12.5 cm. (65 cases)	43%	23%	12%	22%
Dl 12.5-15.5 cm. (26 cases)	69%	20%	7%	4%

find that an increase in heart size shows a marked increase in left axis deviation and a decrease of the occurrence of left axis deviation in Lead IV only. Furthermore, left axis deviation appeared to occur more frequently in old age than in middle age. Whether this is a physiological phenomenon, as Schlomka[9] supposes, we do not know. In our cases, however, we found that the groups of older patients as a rule had markedly dilated hearts when the electrocardiogram showed left axis

TABLE V

LEFT AXIS DEVIATION	IN I-IV	IN I-III	IN IV ONLY	ABSENT
Dl + Dr up to 12 cm. (14 cases)	43%	14%	14%	29%
12-14 cm. (66 cases)	38%	20%	23%	19%
14-16 cm. (58 cases)	48%	27%	13%	12%
16 cm. and up (37 cases)	65%	22%	3%	10%

TABLE VI

AGE	DL + DR	UP TO 12 CM.	12-14 CM.	14-16 CM.	16 CM. AND UP
0-50	(78 cases)	15%	33%	32%	52%
50-60	(65 cases)	9%	30%	43%	62%
60-70	(47 cases)	2%	40%	29%	58%

deviation. Therefore, in our opinion the increased frequency of left axis deviation in old age is caused, at least in part, by an increase in dilatation of the heart.

Regarding the cause of hypertension, it can be said that especially defects of the aortic valves are accompanied by left axis deviation; in those cases a marked dilatation of the left ventricle exists. The same applies to hypertension in mitral insufficiency. Also in chronic nephritis left axis deviation is usually found, but here too, in our cases, the heart

usually showed a pronounced increase in width. In arteriosclerotic hypertension left axis deviation occurs less frequently than, for example, in aortic insufficiency, but then the heart dilatation usually was not very marked.

To summarize, we found:

1. Eighty-three per cent of the cases of hypertension show left axis deviation when Lead IV is used also.

2. The left axis deviation shows itself more clearly in cases of higher systolic and diastolic tension but does not increase in frequency.

3. When the systolic blood pressure exceeds 200 mm. and the diastolic blood pressure 100 mm.Hg, left axis deviation (in standard leads only) decreases in frequency (in accordance with the figures of Ziskin); while in thoracic leads it increases in frequency. In the first case the total percentage of left axis deviation increases slightly; in the second it decreases distinctly.

4. There is a general relationship between left axis deviation and dilatation of the heart as Dl + Dr exceeds 14 cm., the left axis deviation increases distinctly in frequency. However, there are certain exceptions to this rule (see "Interpretation"). A higher degree of dilatation shows a decrease in the *exclusive* occurrence of left axis deviation in the thoracic leads, while in thoracic and standard leads evidence of the left axis deviation increases.

5. Hypertension in old age usually shows a more pronounced left axis deviation; in our cases, however, the heart was also more dilated.

6. Defects of the aortic valve and chronic nephritis especially are associated with left axis deviation, more so than arteriosclerotic hypertension. However, in our cases the first mentioned diseases coincided with higher degrees of heart dilatation than did the arteriosclerotic.

In our opinion the principal causes of the occurrence of left axis deviation in the electrocardiogram in hypertension are a clockwise rotation of the heart in its longitudinal axis and a dilatation of the left ventricle.

B. Interpretation.—Einthoven himself noticed the left axis deviation in hypertension[10]; Lewis,[11] among others, later confirmed this observation. However, both investigators saw cases of distinct hypertension in which left axis deviation was absent and realized that not only the problem of the origin, but also of the cause of the absence of left axis deviation, had to be solved. Lewis based his explanation on two assumptions: the first, that the normal electrocardiogram is a bicardiogram, composed of dextro- and levogram; the second, that the degree of deviation of the electrocardiogram is proportional to the quantity of muscle in action. Hypertrophy and dilatation of the left half of the heart will cause this to dominate and result in a left axis deviation (Lewis' "left preponderance"). When the right half of the heart shows hypertrophy (and dilatation) a "right preponderance" as a rule will be the result.

When, however, not only the left but also the right ventricle hypertrophies, the resulting relation of the muscles may be such that, for instance, in case of hypertension, not only an absence of preponderance but even a "right preponderance" may be the result. As yet neither of these assumptions of Lewis has been proved. We are still in doubt as to whether or not the electrocardiogram really is a bigram; the second assumption obviously cannot possibly be right: the electrocardiogram of children usually shows a much larger voltage than that of adults and in large animals it is often smaller than in human beings.

Herrmann and Wilson[12] and Burger[13] could therefore not share this opinion. Determining the exact weight of left and right ventricles Herrmann and Wilson found left axis deviation only at differences in weight of over 250 gm. Burger proved that normal, sometimes considerable, variations in the height of R- and S-waves are not proportional to differences in weight between the ventricles or of the ventricles separately. Another theory sees the cause of preponderance curves in a shifting of the anatomical or of the electrical heart axis (the sum total of all action currents generated in the systole). A dilatation usually implies a change in the position of the heart. Conversely, the form of the electrocardiogram is influenced by a shifting of the heart's position in respect to the electrodes, as Einthoven, Fahr and de Waart[14] and, more extensively, Cohn[15] were able to prove. Finally, by changing the position of the electrodes in regard to the heart (for instance, by applying the right arm electrode to the left arm, the left arm electrode to the left leg, etc.) a left axis deviation or a right axis deviation can be produced at will. One may rightly object that a shifting of the position of the heart to a degree as required in the experiments of Cohn, is never seen in hypertension. Moreover, this is accompanied by a change of position of P and T in the same direction as R, while in hypertension curves the T-wave is often found opposite to the main deviation of the ventricular complex.

Even if one believes an altered position of the heart by a rotation in its sagittal axis to influence the form of the electrocardiogram, this influence cannot possibly be very great. Boden and Neukirch[16] and later Burger[17] are of the opinion that hypertrophy curves are caused by a rotation of the heart in its longitudinal axis. Normally the right ventricle lies more in the frontal plane (the plane of the standard leads), the left ventricle more in the sagittal plane. According to Burger, this is why in normal cases the right ventricle has a larger electric effect than the left. Hypertrophy of the left ventricle causes the heart to rotate clockwise on its longitudinal axis, bringing the left ventricle more in the frontal plane. However, the degree of shifting is not necessarily proportional to the change in relation between the mass of muscle of the right and left ventricles.

Nuzum and Elliot[18] attribute the preponderance curves to coronary changes. They have come to this conclusion finding the left axis deviation far from constant in hypertension and often absent when the heart is markedly dilated; moreover they found left axis deviation to occur more frequently in angina pectoris without hypertension than in hypertension without angina pectoris. They suppose the left axis deviation to be brought about by intraventricular conduction disturbances caused by an insufficient blood supply of the conduction system and the myocardium resulting from coronary changes.

This conclusion is highly disputable. In the first place, the ventricular complex in hypertension hardly ever shows an increase in width, as it does as a rule in cases of intraventricular conduction disturbances. Besides, it does not seem justifiable to attribute left axis deviation of the electrocardiogram, as may be found in young people (e. q., with chronic nephritis), always to coronary changes. And finally the figures these authors give do not cover our data.* Ziskin,[1] who found left axis deviation in only 44 per cent of his cases, was of the opinion that as yet it seemed impossible to discover its cause or to estimate its significance.

The investigators, mentioned above, always took as a starting point the percentage of left axis deviation existing in hypertension and found

---

PLATE A

I. Left Axis Deviation in All Leads

Fig. 1.—Man, aged forty-nine years, mitral insufficiency. Dyspnea on exertion, palpitation. Heart diameter 13.7 cm. Electrocardiogram: low P-waves in all leads. S_3, relatively low, corresponding small Q_4 (–1 mm.), and high R_4 (20 mm). S-T runs in the isoelectric level (normally aniso-electric). T_4, shallow, slightly diphasic. Conclusion: left axis deviation in all leads, T_4 indicates a not too favorable condition of the myocardium.

Fig. 2.—Woman, aged sixty-seven years, hypertension (220/115). Cardiac failure (dyspnea, edema, nocturia, palpitation). Heart diameter, 13.5 cm. Electrocardiogram: in Lead I low, diphasic T-waves, R_1, 14 mm. In Lead II: deep S-waves. A-V conduction time 0.20 sec. Lead III: deep S-waves (–23 mm.), T positive. Lead IV: relatively small Q-Wave, S-T isoelectric. Conclusion: left axis deviation in all leads. T_1 corresponding with cardiac failure.

II. Left Axis Deviation in Lead IV Only

Fig. 3.—Woman, aged forty-one years, palpitation, pain in chest and back on exertion, dyspnea. Tension, 120/85. Diameter of the heart, 13.5 cm. Electrocardiogram: Lead I no deviations. In Lead II S-T interval is somewhat anisoelectric. No S-wave. Lead III: Pardee-Q, negative T. Lead IV: diphasic P, shallow Q and high R summit (23 mm.). Conclusion: coronary sclerosis, beginning left dilatation; Pardee-Q masks left axis deviation in Lead III.

Fig. 4.—Man, tension 200/120. In Lead I a notch at the bottom of RS, prolongated S-T segment (0.36 sec.), high T-wave. Lead II: low T-wave. Lead III: *W*-shaped complexes, flat T-waves. Lead IV: small Q, high R, broad, blunt T-wave. Conclusion: *W*-shaped complexes, probably caused by coronary sclerosis, are masking left axis deviation in the standard leads; however, it is manifest in the chest lead.

Fig. 5.—Woman, aged forty-seven years, hypertension (200/90). Vague anginal complaints, palpitation, slight dyspnea on exertion, headaches. Heart of normal width (11.4 cm.). Urine normal. Electrocardiogram: in Lead I, no deviation. Lead II: high T-wave. Lead III: S perhaps a little too deep. Lead IV: pronounced left axis deviation (small Q-wave, high R-wave), T shallow. Conclusion: the elevated blood pressure has not as yet caused a marked dilatation of the heart. However, Lead IV shows already a left axis deviation; very probably the dilatation is already manifest in an anteroposterior plane.

Fig. 6.—Woman, aged forty-eight years, angina pectoris, hypertension (255/110). Heart slightly enlarged (14.5 cm.). Electrocardiogram: in Lead I no deviation. Lead II: low T-waves. Lead III: S-T takes off a little too high, is of convex shape, and proceeds into a negative T-wave. Left axis deviation is manifesting itself in Lead IV: shallow Q, high R-wave. The shallow T_4, negative T_3, and low T_2 point to a less favorable condition of the myocardium.

---

*We will revert to this subject in a following paper.

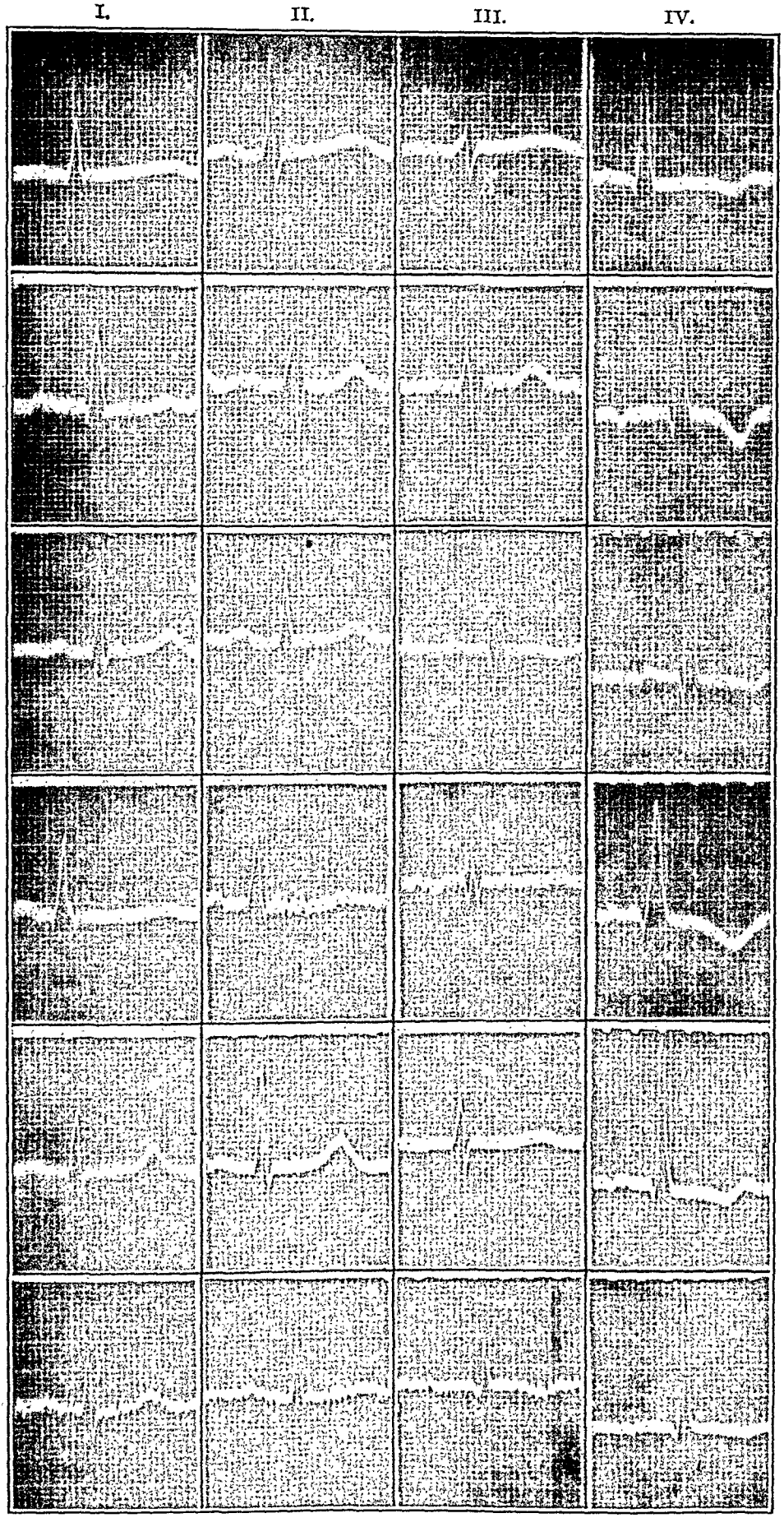

PLATE A. *(See legends on opposite page.)*

this to be either higher or lower. However, it is possible to approach the subject from another angle, the problem being: Why and when is left axis deviation absent in hypertension? In our opinion it is possible to understand in most cases the absence of left axis deviation in extremity leads by comparing the curves of the standard leads with those of the thoracic lead, which is taken in an altogether different plane (sagittally); conversely, the same holds for cases in which left axis deviation is absent in the thoracic lead, while it is present in the leads from the extremities; finally it is possible with the data from these groups to investigate the absence of left axis deviation in all leads in cases of hypertension.

Left Axis Deviation Only in Thoracic Leads (36 Cases, Figs. 3-10)

In case left axis deviation occurs only in thoracic leads (shallow Q or absence of Q, high R), the ventricular complexes in the standard leads appear to be:

1. Deformed by deep, sharp notches (Case 9, Fig. 9). This then is a plausible reason for the nonmanifestation of left axis deviation in cases of distinct hypertension.

2. Normal. In these cases the heart did not appear dilated in the roentgenogram, However, an incipient dilatation often takes place in

---

PLATE B

II. Left Axis Deviation in Lead IV Only

Fig. 7.—Woman, aged fifty-two years, hypertension (160/115), dyspnea on exertion, swollen ankles in the evening, palpitation. X-ray examination of the heart: curved arch of left ventricle; however, no enlargement (12.5 cm.). Electrocardiogram: prolongated S-T segment (0.40 sec.). Lead III: small, notched complexes, T positive. Lead IV: left axis deviation (small Q, high R-wave). S-T isoelectric. T shallow in relation to R. Conclusion: the hypertension causes left axis deviation in Lead IV only, early dilatation of the heart. Prolongated S-T segment and shallow T_4 show that the myocardium is not in optimal condition.

Fig. 8.—Man, aged forty years, verrucous endocarditis of the aortic valves. Aortic regurgitation. Tension 150-0. Diameter of the heart, 15.6 cm. Electrocardiogram: low T-wave in Lead I. Lead II: anisoelectric S-T notch at the foot of RS. Lead III: notched complexes. Lead IV: left axis deviation (small Q, high R-wave). The negative P-wave is clearly visible in the positive T-wave. A-V conduction time 0.26 sec. Conclusion: multiple signs of myocardial damage. Left axis deviation in Lead IV only.

Fig. 9.—Woman, aged forty-four years, thyrotoxicosis. Tension 160/95. Heart, 12.9 cm. Electrocardiogram: in Leads I and II, split P-waves; in Lead III notched complexes; in Lead IV left axis deviation (shallow Q, high R-wave). Further on, auricular extrasystoles.

Fig. 10.—Woman, aged twenty-one years, hypertension (150/110). Vagovasal attacks. Bronchial asthma. Heart not enlarged (13 cm.). Electrocardiogram: in standard leads rather right than left axis deviation. In Lead IV, according to hypertension, left axis deviation. S-T segment at first horizontal. Conclusion: left axis deviation, no evidence of myocardial damage.

III. Left Axis Deviation in Standard Leads Only

Fig. 11.—Man, aged fifty-three years, seizures of unconsciousness, complains of palpitation, tingling in arms and legs. Marked peripheral arteriosclerosis. Blood pressure 145/80. Heart enlarged to the left (diameter, 15.5 cm.), broad aorta. Electrocardiogram: in standard leads left axis deviation. T_3 negative. In Lead IV typical shape of coronary sclerosis, deep Q-wave (-20 mm.), low R-summit (5 mm.), deep and somewhat broad T-wave (-11 mm.). Coronary sclerosis masks, according to our conception, left axis deviation in Lead IV.

Fig. 12.—Man, aged sixty-eight years, diabetes, sclerosis of aorta, and peripheral sclerosis. Wassermann reaction negative. Tension 145/70. Heart enlarged to the left. Electrocardiogram: auricular extrasystoles (bigeminy). No left axis deviation in Lead IV: deep Q-wave (-19 mm.), low R-wave (12 mm.), deep negative T-wave, in which the P-wave of the next auricular extrasystole is just visible.

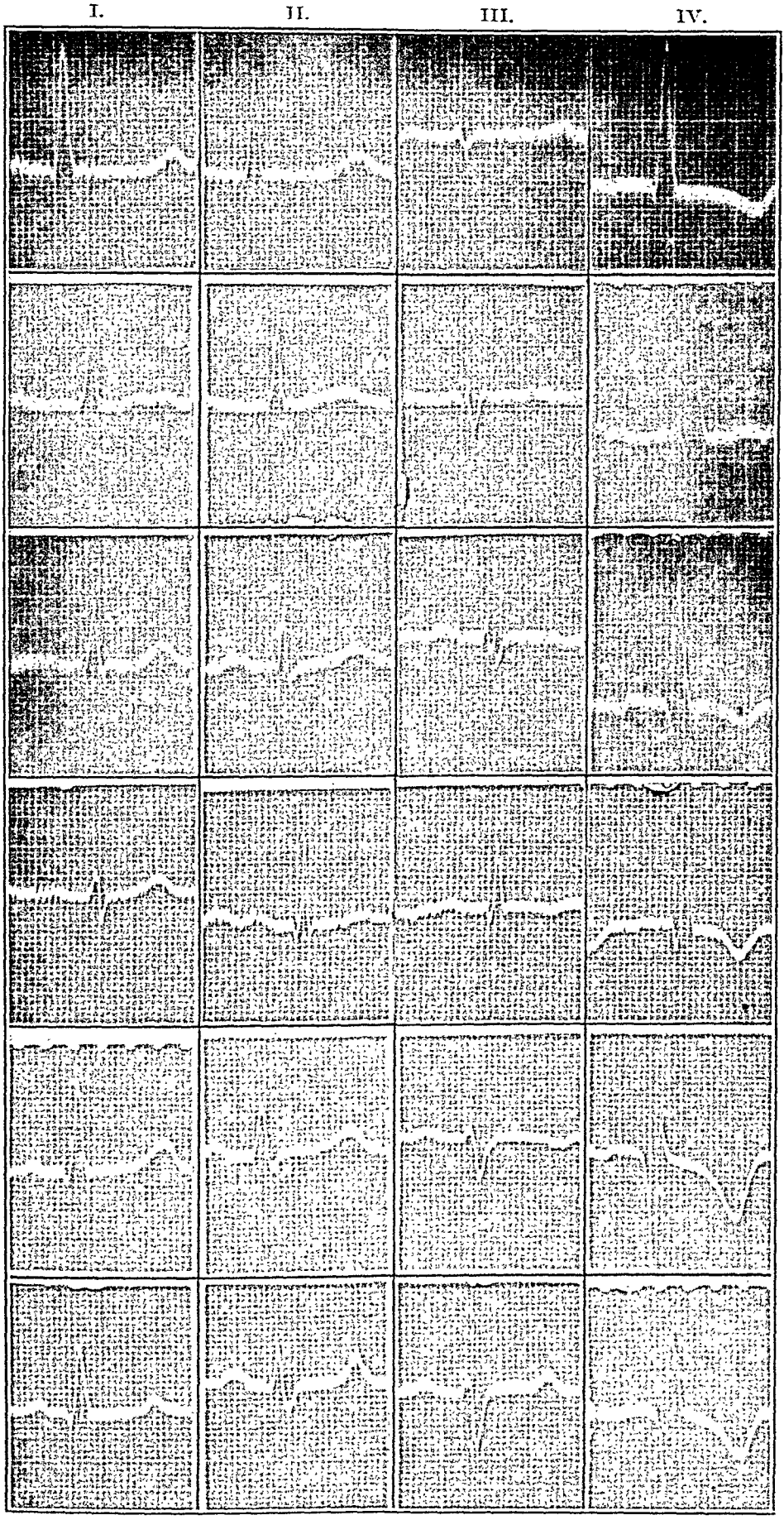

PLATE B. *(See legends on opposite page.)*

the sagittal plane, in other words, in the plane of the thoracic lead; only in more pronounced stages of dilatation it is accompanied by a rotation, which places the left ventricle more and more in the frontal plane; for this reason the left axis deviation in the beginning manifests itself only in the thoracic lead. In radioscoping these cases, attention should be paid to a posterior enlargement of the left ventricle by observing the patient in the second oblique position (Case 5, Fig. 5).

3. Changed as a result of abnormal conditions of the coronary arteries. These occurred very often in this group. Eleven times we found a so-called Pardee-Q in Lead III and eight times an *M*- or a *W*-shaped ventricular complex. The extensive investigations of Pardee, Edeiken, and Wolferth[19] and Wallace[20] have proved beyond doubt that a deep Q in Lead III, complying with Pardee's[21] criteria, is characteristic of coronary sclerosis (and when it is seen to establish itself in successive electrocardiograms, for coronary thrombosis[22]). We as well as others are of the opinion that the *M*- and *W*-shaped ventricular complexes are often due to coronary sclerosis. Although this type of change in Lead II is practically sure to have a definite significance (Edeiken and Wolferth[23]), its occurrence in Lead III, especially in advanced age, points to the diagnosis of coronary sclerosis. In addition to the pathological data on which the above mentioned research is based, we have further support in the anamnesis of these patients in whom angina pectoris is often found. In this group of thirty-six patients we found eight with angina pectoris.

Peripheral arteriosclerosis could be demonstrated in fourteen out of the nineteen cases in which a Pardee-Q or *M*- or *W*-shaped ventricular complex was found. Furthermore, a saddle-shaped S-T curve occurred fifteen times in Lead I or II separately, an abnormality which in its pure form* is almost exclusively found in cases of coronary sclerosis.

Summarizing.—Left axis deviation is absent in the standard leads and present in the thoracic leads (1) because notches resulting from injury of the myocardium conceal the left axis deviation in standard leads (Case 2, Fig. 2), or (2) because of the dilatation of the left ventricle still taking place in the sagittal plane only (Case 3, Fig. 3), or (3) because coronary sclerosis alters the ventricular complexes in Leads I, II and III, thus covering up the left axis deviation (Cases 4 and 5, Figs. 4 and 5).

Left Axis Deviation in Standard Leads Only (Figs. 11-15)

In 25 cases we found a marked left axis deviation in the Leads I-III, while in Lead IV the Q-wave was not shallow or absent, but distinctly too deep (from –7 to –18 mm.). Of the patients showing these cardiograms, 25 were over fifty and 12 over sixty years old; 8 suffered from angina pectoris, and in 14 other cases arteriosclerosis could be diagnosed (pulse, aorta, retina). Thus 17 out of 25 patients had arteriosclerosis.

*We intend to revert to this subject in another paper (on coronary sclerosis).

Eleven of these showed a saddle-shaped S-T curve in Lead I or II; seven, a remarkable, steep S-T curve beginning below the isoelectric level; two patients suffering from an after-effect of acute nephritis were fifteen and seventeen years old respectively; in these cases a deep Q_4 can be attributed to a vertical position of the heart, which existed in both patients (in a preceding paper we have shown that a shallow or positive T and a low Q are normal in children and asthenic subjects[24]). When x-ray pictures were taken, they showed a distinct dilatation of the heart in all but two cases. The heart was normal in size in one patient with angina pectoris (blood pressure 135/70) and in one of the patients who had had acute nephritis (blood pressure 165/60). Finally in a patient with bronchiectasis the heart was markedly displaced toward the right (the man was thirty-one years old, blood pressure 115/70).

Thus the absence of left axis deviation in the thoracic lead, although plainly evident in the standard leads, may be accounted for by:

1. The age of the patient, because in youth a low Q_4 can be normal (Case 13, Fig. 13).
2. A distortion or displacement of the heart toward the right.
3. Arteriosclerotic changes in the coronary vessels and their results (Cases 11 and 12, Figs. 11 and 12).
4. A mitral insufficiency coinciding with the hypertension (Case 10, Fig. 10) and a deep Q_4 regularly occurring in mitral stenosis and insufficiency.

Hypertension Without Left Axis Deviation in Standard and Thoracic Leads (Figs. 14-17)

This we saw in thirty-two of the cases studied. The abnormal conditions, as described for the above groups, can also be found in this group. An *M*- or a *W*-shaped ventricular complex in five cases, a Pardee-Q in seven cases, and a notched ventricular complex in ten cases concealed the left axis deviation in the standard leads; the Q in the thoracic lead was usually deep, sometimes normal, but never shallow in these cases. In four cases the standard leads were normal and the Q deep (–8 to –10 mm.). In four of the other six cases of distinct hypertension a marked dilatation could not be demonstrated by radioscopy (Dl ÷ Dr not exceeding 12.5 cm.); a mitral stenosis accompanied by hypertension occurred once (155/75). In the other case we found a hypertension of 195/80 with a normal electrocardiogram, while the heart appeared to be slightly dilated toward the left.

As a result of these observations we can say that absence of left axis deviation in the standard and thoracic leads in cases of marked hypertension is usually caused by (1) abnormal conditions in the coronary system concealing the left axis deviation; (2) notches distorting the ventricular complexes; and (3) a normal shape of the heart notwith-

standing the hypertension; in these cases it seems only reasonable to assume that the hypertension has not existed very long or is not constantly present.

Up to this time a direct relation between left axis deviation and hypertension has been considered to be doubtful. The results of statistics on 238 patients formed the basis of our hypothesis—that left axis deviation depends on a dilatation of the left half of the heart, beginning in a sagittal plane (in which stage a left axis deviation can be recorded in the thoracic leads only) and later on also in the frontal plane, the heart rotating clockwise on its longitudinal axis; in those cases left axis deviation is usually recorded in the standard leads too. Left axis deviation is generally not seen when no dilatation exists.

Absence of left axis deviation in hypertension which has brought about a heart dilatation is in our opinion caused by other factors which conceal the left axis deviation in these cases; thus the electrocardiogram is influenced by coronary defects (Pardee-Q, *M*- or *W*-shaped ventricular complexes, saddle-shaped S-T curve and, in the thoracic lead, a deep Q, with a low R and the S-T curve horizontal at first, instead of the normally existing absence of an isoelectric S-T curve in this lead), or by a change of position of the heart, by notches distorting the ventricular complexes, by the tendency to right axis deviation in mitral defects, and by age (a deep Q_4 is normal in youth). The absence of left axis deviation on the electrocardiograms of patients with hypertension calls for a search of the interfering factors mentioned above.

PLATE C

III. Left Axis Deviation in Standard Leads Only

Fig. 13.—Boy, aged seventeen years, postanginous nephritis. Tension 155/85. Electrocardiogram: left axis deviation in standard leads. In Lead IV deep Q-wave, such as is commonly seen in adolescence and as a rule in childhood. Heart diameter, 11 cm. An example of the remaining of a deep Q-wave in youthful patients in spite of hypertension.

IV. Left Axis Deviation Fails in All Leads

Fig. 14.—Woman, aged forty years, precordial pain and dyspnea on exertion. Tension 160/85. Wassermann reaction, negative. Heart slightly enlarged to the left, hypertension type. Electrocardiogram: in Lead I diphasic T, S-T segment runs below the isoelectric level. Lead II: somewhat saddle-shaped S-T segment. In Lead III a Pardee-Q. Lead IV: small, notched complexes. T positive: the shape remin ls one of the C_1 type and originates here probably from arteriosclerotic changes of the right coronary artery. These are masking left axis deviation in all leads.

Fig. 15.—Woman, aged forty-four years, mitral stenosis. Tension 155/75. Heart enlarged to the left (13.4 cm.). In spite of hypertension and left dilatation, no left axis deviation. (Deep Q_4, normal S and R summits in standard leads.)

Fig. 16.—Woman, aged forty-eight years, chronic Bright's disease. Tension 210/160. Heart of normal shape, not enlarged to the left (12.5 cm.). The electrocardiogram shows no typical changes. Notwithstanding the hypertension the failure of left axis deviation conforms to the normal heart diameter.

Fig. 17.—Woman, aged sixty-six years, hypertension 225/110. Peripheral arteriosclerosis, arteriosclerotic retinitis. Heart enlarged to the left (Dr 4, Dl 10 cm.), transverse type, aortic knob prominent. Urine: no abnormalities. Electrocardiograms: saddle-shaped S-T segment in all leads. In chest lead S-T almost horizontal. In Lead III notched *M*-shaped complexes; Lead IV: coronary sclerosis type (deep Q-wave, relatively low R summit, almost horizontal S-T line). Conclusion: notwithstanding hypertension and dilatation of the heart, no left axis deviation as a consequence of coronary sclerosis.

V. Left Axis Deviation in All Leads; T_1 Negative, T_2 Positive, No Convexity of S-T Segment in Lead I

Fig. 18.—Woman, aged fifty-one years, hypertension (275/170). Apoplexy, cardiac failure. Electrocardiogram: pronounced left axis deviation, S-T segment not evidently convex in Lead I, in Lead III slightly concave.

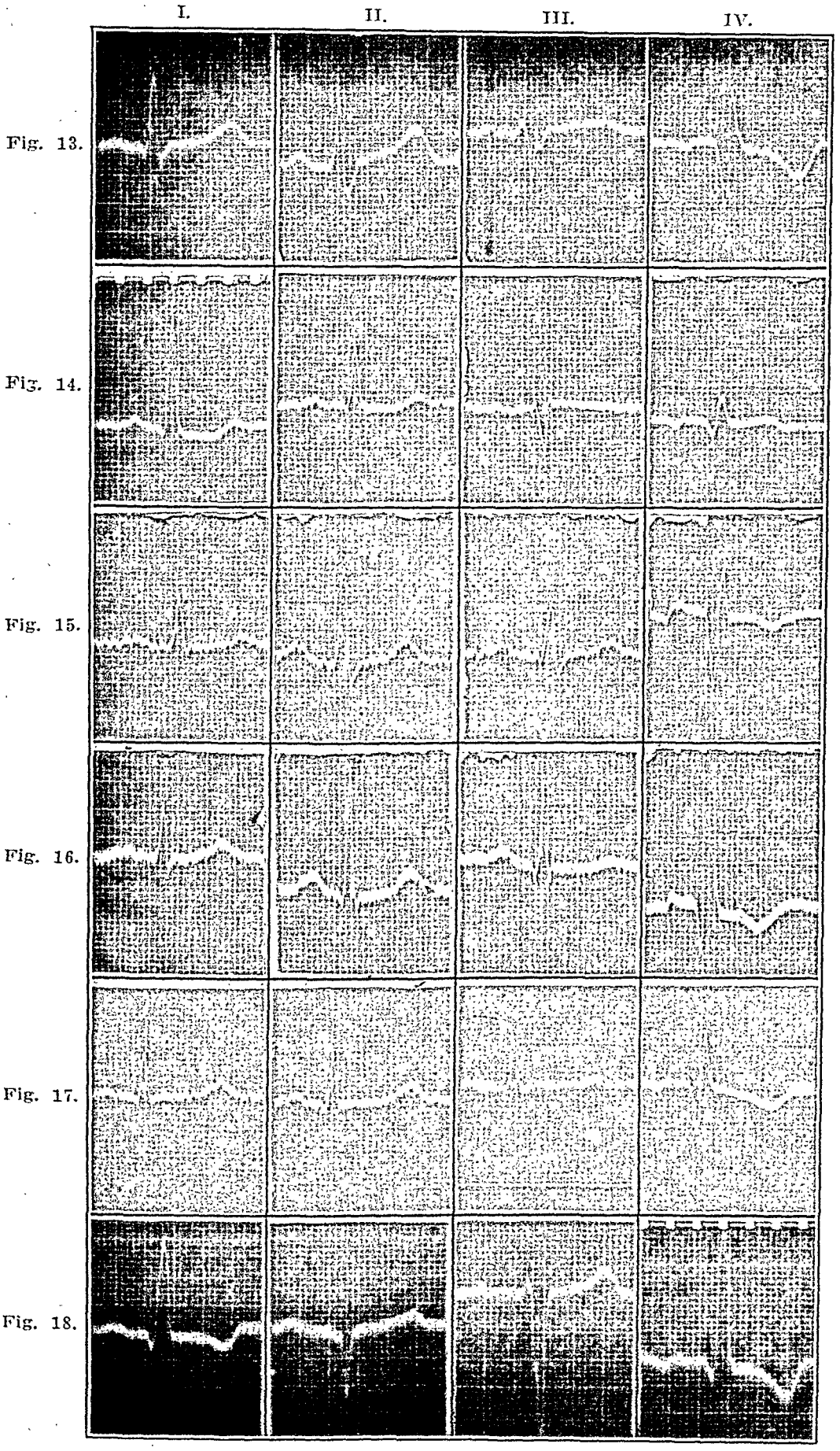

PLATE C. *(See legends on opposite page.)*

II. THE SIGNIFICANCE OF THE NEGATIVE T-WAVE IN LEAD I AND OF THE POSITIVE T-WAVE IN LEAD III IN CASES OF LEFT AXIS DEVIATION ON THE ELECTROCARDIOGRAM (FIG. 18)

A divergence of opinion has long existed about this phenomenon. Are these T-waves, opposite to the main deviation of the electrocardiogram, caused by the left axis deviation as such, that is, by a change of position of the anatomical or of the electrical axis of the heart, or are the negative T_1 and the positive T_3 an indication of an imperfect condition of the myocardium? This is a problem of clinical importance. The same problem applies to the positive T_1 and the negative T_3 in electrocardiograms with right axis deviation.[25] Barnes and Whitten[26] as well as Wilson and Herrmann[27] support the first theory; Freundlich[28] and Proger and Minnich,[29] the second one. We agree with the opinion that in hypertension a negative T-wave in Lead I indicates an imperfect condition of the myocardium. This is what experience teaches us. But also it is hard to explain how a negative T_1 could be brought about by a left axis deviation. As we have set forth already, one would sooner expect an altered position of the electrical or anatomical axis to cause a total inversion of the ventricular complex[30] (the T-wave moving in the same direction as the main deviation of the ventricular complex). In considering the similar diphasic character of the waves in the bundle-branch and arborization block, a possible explanation was sought in intraventricular conduction disturbances. We have mentioned already that an extended QRS complex is hardly ever found in hypertension curves.

The results of our comparison of patients with a positive T_1 in the electrocardiogram and patients with a negative T_1 are given in Table VII.

TABLE VII

	T_1 POSITIVE	T_1 NEGATIVE
Number of cases	91	62
Symptoms of cardiac failure	26%	70%
Anginal complaints	20%	26%

Although patients with a positive T_1-wave often show a more markedly dilated heart than patients with a negative T_1, in our cases we often found a mild hypertension coinciding with a negative T_1 and a higher tension still showing a positive T_1.

Whatever the explanation may be, the experience from our cases has taught us that symptoms of decompensation occur more often when hypertension coincides with a negative T_1 and a positive T_3 than with a positive T_1. This fact alone is of clinical interest.

(For the significance of the T-wave in Lead IV, see "V. Electrocardiographic Differential Diagnosis.")

III. THE CONVEXITY OF THE S-T CURVE IN LEAD I AND THE CONCAVITY OF THE S-T CURVE IN LEAD III IN HYPERTENSION (FIGS. 19-21).

In studying the curves of patients with hypertension, we repeatedly found these remarkable abnormalities: The convex S-T curve in Lead I as a rule continued into a negative T-wave, and the concave S-T curve into a positive T. In most of these cases we noticed serious heart trouble. The phenomenon occurred twice as often in subjects over fifty years of age as in those under fifty years; it was seldom seen in subjects with tensions under 150 mm. but was seen frequently in subjects with tensions over 200 mm. Hg. In practically all cases the heart was dilated toward the left, Dl amounting to more than 11 cm. in 75 per cent of the cases. In more than half of the cases distinct cardiac failure was found, and in one-third of all cases the anamnesis included anginal complaints. In patients with tension above 200 mm. the convexity of the S-T line occurred twice as frequently as left axis deviation without this abnormality. Furthermore, the group with the convex S-T curve usually showed a greater dilatation of the heart toward the left than the other group and, finally, a slightly higher incidence of cardiac failure was seen than in the other group.

Here too the question arises whether the convexity of the S-T curve in Lead I is a result of the cardiac dilatation as such, or of the poor condition of the heart muscle. Finding a distinct enlargement of the heart toward the left far more often than in the group without a convex S-T curve while the incidence of heart decompensation increased in a lesser degree, we are inclined to interpret the convex S-T curve as a manifestation of the heart enlargement itself. Those patients showing a convex S-T curve in Lead I and a tension under 150 mm. Hg nearly always suffered from aortic regurgitation, in which the heart was greatly dilated, although real symptoms of cardiac failure were usually absent.

TABLE VIII

	LEFT AXIS DEV. WITH CONVEX S-T CURVE	LEFT AXIS DEV. WITHOUT CONVEX S-T CURVE
Number of cases	76	98
Men	45%	45%
Women	55%	55%
Over 50 years of age	63%	67%
Systolic tension 145/200 mm. Hg	30%	44%
Systolic tension 200/250 mm. Hg	50%	23%
Systolic tension 250/300	11%	3%
Heart distinctly dilated toward the left (Dl + Dr 16 cm.)	75%	28%
Symptoms of cardiac failure	55%	40%
Anginal symptoms	30%	22%

Comparing a group of cases of left axis deviation with a convex S-T curve to a group without a convex S-T curve, both groups, however,

showing a negative or diphasic T_1, practically the same percentage of cases of failure is found, as is shown in Table IX.

TABLE IX

	CARDIAC FAILURE	ANGINA PECTORIS
S-T convex, T_1 diphasic or negative	64%	31%
S-T not convex, T_1 diphasic or negative	68%	26%

Rijkert and Hepburn published a paper on the convexity of the S-T curve[31] some time after we had started our studies on this subject. These authors also found the convex S-T curve practically always present in arterial hypertension, while the cases showing no hypertension had aortic regurgitation or aortic stenosis. They found failure in 57 per cent of the cases, a figure remarkably close to our result (55 per cent). On these grounds, they point out the clinical importance of this defect, but they omitted to compare their cases with a group of cases of left axis deviation without a convex S-T curve. Such a comparison shows the percentage of patients with failure to be not much higher than in the group without a convex S-T curve. In 14 out of 20 patients examined after death, they found coronary lesions (sclerosis, atheromatosis and, in one case, thrombosis). This percentage is not surprising in this group considering the fact that hypertension so often coin-

PLATE D

VI. Convexity of S-T Segment in Lead I, Concavity in Lead III, Convexity in Lead IV

Fig. 19.—Man, aged sixty-seven years, tension 220/110. Angina pectoris. Heart of transverse type. Urine, normal. Electrocardiogram: low T_1, left axis deviation in all leads. Marked convexity of S-T line in Lead IV.

Fig. 20.—Man, aged forty-one years, chronic Bright's disease. Tension 230/165. Heart strongly enlarged to the left. Electrocardiogram: marked left axis deviation. Obvious convexity of S-T in Lead I, concavity in Lead III. S-T runs in Lead I below, in Lead II above isoelectric level. In addition, negative T_1, and positive T_2.

Fig. 21.—Man, aged forty-two years, syphilitic aortic regurgitation. Cardiac failure. Heart strongly enlarged to the left. Electrocardiogram: pronounced left axis deviation in all leads. Convexity of S-T interval in Leads I, II, and IV. $S\text{-}T_3$ straight, ascending.

VII. Pronounced Convexity of S-T Line in Lead IV, With S-Wave, in Extensive Injury of the Kidney (Nephrosclerosis)

Fig. 22.—Woman, aged sixty-six years, diabetes mellitus, severe angina pectoris, gangrene of toes. Tension 220/115. Heart enlarged to the left. Electrocardiogram: in Lead I, S-T runs below the isoelectric level and in convex. T_1 is diphasic. In Lead II notches in QR, T-wave diphasic. A-V time 0.18 sec. Lead III: distinct Pardee-Q. S-T runs above isoelectric level. Lead IV: pointed convex S-T line. T negative. On this score a diagnosis of coronary sclerosis and extensive damage to the kidneys was made. Sudden death. Post-mortem examination: severe coronary sclerosis. Thrombosis of a branch of the left descendent coronary artery, arteriosclerotic nephrosclerosis.

Fig. 23.—Man, aged forty-five years, entered hospital with symptoms of acute myocardial infarction. Was known to be suffering from kidney disease. Tension, on entering the ward (when cardiac failure already existed), 125/65. Urine, albumin 0.3 per cent, numerous hyaline and granular casts. No x-ray examination. Electrocardiogram: in Lead I small, notched complexes, S-T runs a little above the isoelectric level and is slightly convex, indication of Pardee RS-T segment. Lead II: S-T segment lies below isoelectric level, diphasic T-wave. Lead III: deep S-wave, S-T below isoelectric level, diphasic T-wave. Lead IV: C_2 type; in addition a convexity of the S-T line is to be noted. A distinct S-wave exists in this lead. Diagnosis: anterior infarction, nephrosclerosis (?).

Fig. 24.—The patient declined rapidly, cardiac failure increased, auricular fibrillation occurred, at first in paroxysms, later on continuously. The patient died with the symptoms of severe failure. Post-mortem examination: dissecting aneurysm of the whole aorta, anterior infarction, genuine nephrosclerosis.

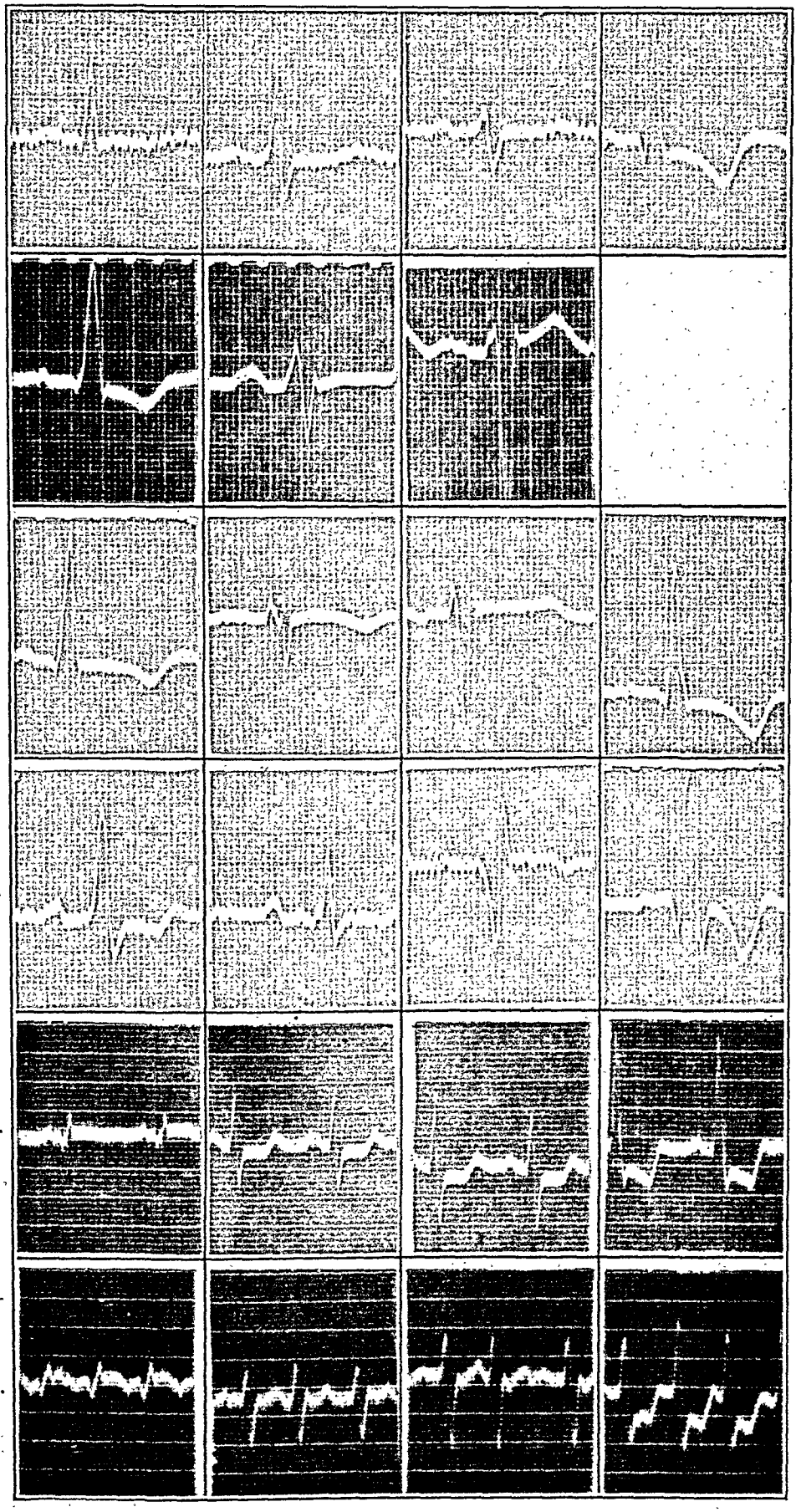

PLATE D. (*See legends on opposite page.*)

cides with arteriosclerosis and that coronary sclerosis is found so often at post-mortem examination of patients who have suffered from hypertension (90 per cent, Nuzum, Elliot and Evans;[32] 50 per cent, Rössle; 40 per cent, Bell and Clawson[33]).

Necropsy also showed coronary lesions in some of our cases; in some other cases, however (e.g., with chronic nephritis), these could not always be demonstrated. We came to the conclusion that coronary changes could not always be considered to be the cause.

To summarize, then, we have found that:

1. The convex S-T curve in Lead I and the concave S-T curve in Lead III usually occur in cases of hypertension; in the absence of hypertension these electrocardiographic deviations are usually manifestations of aortic defects; often they are very clearly seen in cases of chronic nephritis (see also V).

2. The cause of these changes is to be found in the marked dilatation of the heart; coronary troubles may have an influence.

3. Since a convex S-T curve usually occurs in cases of pronounced dilatation, the symptoms of failure are naturally frequent; however they may be absent (compensated defects of the aortic valves).

IV. THE OCCURRENCE OF AN S-WAVE, FOLLOWED BY AN EXTREME CONVEXITY OF THE S-T CURVE IN LEAD IV (FIGS. 22-24)

Normally an S-wave is not found in Lead IV and the S-T curve starts at, or at most, 2-2.5 mm. below the isoelectric level, proceeding continuously into the negative T-wave without a horizontal stretch.

A few of the curves, however (we have seen four tracings up to this time), showed a marked S-wave and a distinct convexity of the S-T curve. All patients showing this phenomenon were very ill, the clinical diagnosis being uremia in two, coronary thrombosis and coronary sclerosis in one each. In three cases a post-mortem examination was made. In the patient with coronary thrombosis (Case 23, Fig. 23), in addition to the heart infarction which had caused the C_2 type (the other leads did not point positively to the diagnosis of coronary thrombosis), a pronounced nephrosclerosis was found. We had anticipated this, as the descending part of the S-T line was unusually convex for a C_2 type. A post-mortem examination of the patient with coronary sclerosis revealed a thrombosis adherent to the arterial wall. The blood could still pass the ramus descendens of the arteria coronaria sinistra, for which reason an infarct had not developed. In addition, a serious nephrosclerosis was found. In a third case of uremia we also found extensive alterations in the kidneys. We are not able as yet to explain the origin of this type. Hypertension was found in three cases; the heart was dilated in all cases, although not always considerably. Whatever the cause may be, this type, which is rather rare (4 out of 2,000 electrocardiograms), is probably an indication of extensive alterations in the kidneys.

V. ELECTROCARDIOGRAPHIC DIFFERENTIAL DIAGNOSIS

On first view the electrocardiogram in hypertension, especially when the T-wave in Lead I is negative, may be mistaken for the electrocardiogram of coronary thrombosis; in this case it also looks similar to the electrocardiogram of arborization and bundle-branch block. As for the bundle-branch block, diphasic ventricular complexes, usually of a high voltage, occur in both types. On the other hand, notches in the ventricular complexes and an increased Q-S interval are obligatory signs of the bundle-branch and arborization block, while notches are hardly ever, a prolonged ventricular complex practically never, found in the electrocardiogram in cases of left axis deviation. Moreover, these two electrocardiograms differ in the thoracic lead, in which arborization block, in addition to the prolonged and notched ventricular complex, shows a deep, pointed T-wave, and the bundle-branch block, a deep obtuse T-wave; while the T-wave is usually normal or slightly too low in cases of hypertension. Exceptionally these latter cases too show a deep T-wave which, however, is associated with a deep, and not a shallow or absent, Q-wave in the ventricular complex.

The electrocardiogram in thrombosis of the left coronary artery followed by an anterior infarct, which in Lead I sometimes causes a convex, high take-off of the S-T segment with the T-wave creeping into it (Smith, Pardee), changes in the course of time (two to four weeks) into a type in which S-T starts at the isoelectric level and continues after a rather long isoelectric course into a negative T-wave, which is comparatively narrow and shallow itself. On first view this electrocardiogram resembles that of a case of hypertension with a negative T_1. However, the types with the convex S-T line do not present any differential diagnostic difficulties; in the first place because in hypertension R_1, after T_1 has become negative, is usually high (exceeding 12 mm.), while in the electrocardiogram of coronary thrombosis R_1 is low. Furthermore, in Lead IV the tracings are totally different. In cases of anterior infarction the C_2 type (a long descending S-T limb, continuing into a short ascending limb, forming an angle of about 125° between them) usually occurs, which S-T segment differs altogether from the blunt, low or pointed T-wave in the bundle-branch and arborization block. In aortic regurgitation, however, it is quite possible that the electrocardiogram in the chest lead may resemble the C_2 type. In both cases the Q-wave is small or absent, the R-wave high. However, in coronary thrombosis the S-T line as a rule (not always) has its starting point far below the isoelectric level, and a positive T-wave, such as usually appears in the C_2 type of coronary thrombosis, never occurs in aortic regurgitation. In addition, the C_2 type usually shows a notch (the size of which depends on the location of the electrode), while in regurgitation this is often absent. The descending S-T segment is practically always straight in coronary thrombosis, and invariably convex

in aortic regurgitation. However, in view of the marked similarity between the tracings as obtained in the thoracic lead, especially in luetic aortic regurgitation and those in anterior infarction, the question presents itself whether in aortic regurgitation, too, the coronary circulation has not decreased (by luetic changes of the intima or coronary stenosis). The anginal complaints in aortic regurgitation point in the same direction.

SUMMARY

In hypertension the *extremity leads* may show:

1. Left axis deviation alone;

2. Left axis deviation, with a negative T_1 and a positive T_3—usually in cases with myocardial damage;

3. Left axis deviation, with a negative T_1, a positive T_3, a convex S-T_1 interval and a concave S-T_3 interval. In such cases the heart usually shows pronounced dilatation;

4. Absence of left axis deviation, as a consequence of factors mentioned below.

Lead IV shows usually the following characteristics: P-wave diphasic; Q, shallow or absent; a normally wide ventricular complex; R-wave, high; T-wave, rather low, negative and of normal shape; no notches usually. When, however, the hypertension is due to aortic insufficiency, the S-T segment has a long, convex descending limb and a short ascending one. When the hypertension is complicated by coronary sclerosis, then instead of a small or an absent Q-wave, this wave is usually deep; the R-wave, low; the S-T interval, isoelectric in its first portion; and the T-wave, negative and deep. However, many variable forms are seen. In a few cases of hypertension associated with nephrosclerosis we found a deep S-wave (–5 to –7 mm.) continuing into a distinctly convex S-T interval which, after returning to the isoelectric level, ended in a deep, negative T.

Ziskin concludes his paper, published in 1928, with the words: "Other factors, besides those enumerated, and at present unknown, are involved in the production of left ventricle preponderance." Since then eight years have passed in which extensive research work has been done to investigate the condition of the myocardium and the coronary vessels by means of the electrocardiogram.

Using as routine a thoracic lead in addition to the standard leads, we were able to draw conclusions not only from the similarities, but especially from the differences between them. This brought out the fact that in hypertension left axis deviation is present in 83 per cent of the cases in standard or chest leads, for which in our opinion not only the clockwise rotation in the longitudinal axis, but especially the enlargement of the heart must be held responsible. We based our experiments on the assumption that left axis deviation, when absent in

marked cardiac dilatation, is obscured by interfering factors. Certain factors were found to cause this absence; e.g., in youth, the longitudinal position of the heart, notwithstanding dilatation; the enlargement in a sagittal plane only, in incipient cases; and finally, in advanced age, coronary sclerosis. Therefore the absence of left axis deviation in a case of marked enlargement of the heart should lead one to suspect some of the above mentioned conditions.

A negative T_1 and a positive T_3 were found to imply an involvement of the myocardium. The convex S-T_1 interval and concave S-T_3 interval, which in our opinion are caused by the pronounced cardiac dilatation accompanying these cases, should therefore suggest, usually, a doubtful prognosis.

We have drawn attention to a special type of the ventricular complex in Lead IV, in which an S-wave and an extremely convex S-T interval are conspicuous; in these cases serious kidney damage was found (nephrosclerosis, chronic nephritis).

Finally, we have described in detail the electrocardiogram in cases of hypertension and its differential diagnostic difficulties, giving the chest lead especial attention.

REFERENCES

1. Ziskin: Arch. Int. Med. 42: 512, 1928.
2. Nuzum and Elliot: Arch. Int. Med. 55: 293, 1935.
3. Wenckebach: Die unregelmässige Herztätigkeit, 1929, p. 103.
Lewis: Clinical Electrocardiography, 1931, p. 111.
4. Nederl. Tijdschr. v. Geneesk. 80: 225, 1936.
5. Dietlen and Moritz: Klin. Wchnschr. 2: 2097, 1922.
6. Danzer: Am. J. M. Sc. 153: 513, 1919.
7. Hodges and Eyster: Arch. Int. Med. 37: 707, 1926; and 41: 667, 1928.
8. Nuzum and Elliot: Arch. Int. Med. 55: 293, 1935.
9. Schlomka, G.: Klin. Wchnschr. 15: 564, 1936.
10. Einthoven: Arch. Int. de Physiol. 4: 132, 1906; Pflügers Arch. 122: 517, 1908.
11. Lewis: Heart 5: 367, 1913-14; Phil. Trans. Roy. Soc. 207: 247, 1916.
12. Herrmann and Wilson: Heart 9: 91, 1921-22.
13. Burger: Ztschr. f. klin. Med. 102: 603, 1926.
14. Einthoven, Fahr, and de Waart: Pflügers Arch. 150: 275, 1913.
15. Cohn: Heart 9: 311, 1921-1922.
16. Boden and Neukirch: Pflügers Arch. 171: 146, 1918.
17. Burger: Ztschr. f. klin. Med. 102: 603, 1926.
18. Nuzum and Elliot: Arch. Int. Med. 55: 293, 1935.
19. Pardee, Edeiken, and Wolferth: Am. Heart J. 7: 1965, 1932.
20. Wallace: Am. J. M. Sc. 188: 498, 1934.
21. Pardee: Arch. Int. Med. 46: 470, 1930.
22. Nederl. Tijdschr. v. Geneesk. 79: 565, 1935.
23. Edeiken and Wolferth: Am. J. M. Sc. 188: 892, 1934.
24. Arch. Int. Med. (in press).
25. Master: Am. Heart J. 5: 291, 1930.
26. Barnes and Whitten: Am. Heart J. 5: 14, 1929.
27. Wilson and Herrmann: Heart 8: 229, 1921-22; and 9: 91, 1921-22.
28. Freundlich: Deutsches Arch. f. klin. Med. 177: 449, 1934.
29. Proger and Minnich: Am. J. M. Sc. 189: 674, 1935.
30. Proger and Korth: Deutsches Arch. f. klin. Med. 170: 516, 1931.
31. Rijkert and Hepburn: Am. Heart J. 10: 942, 1935.
32. Nuzum, Elliot, and Evans: Am. Heart J. 10: 367, 1935.
33. Bell and Clawson: Arch. Path. 5: 939, 1928.

CORONARY THROMBOSIS: AN INVESTIGATION OF HEART FAILURE AND OTHER FACTORS IN ITS COURSE AND PROGNOSIS*†

A. M. MASTER, M.D., S. DACK, M.D., AND H. L. JAFFE, M.D.
NEW YORK, N. Y.

THE more recent studies of coronary artery thrombosis have brought out the importance of the rôle of cardiac insufficiency in determining the course of this disease.[1, 2, 3] Early writers[4, 5] attributed many of the symptoms of coronary thrombosis other than precordial pain and shock to passive congestion secondary to ventricular damage. Levine[6] found that in a large group of his patients the temporary improvement following the immediate effects of the thrombosis was succeeded by symptoms of progressive congestive heart failure, which, when they persisted for weeks, assumed an ominous significance. In our series we found a high incidence of congestive failure, particularly in the fatal cases, and in a number of our patients the sudden appearance of congestive failure or the sudden aggravation of preexisting failure was the only indication of coronary artery occlusion. Similar cases of coronary occlusion have probably been unrecognized in the past, although some have been reported.[2, 6, 7]

We have tried to determine the factors that predispose to cardiac insufficiency in acute coronary artery thrombosis and to evaluate the prognostic significance of the various signs and symptoms related to such insufficiency.

Since coronary thrombosis is predominantly a lesion of the left ventricle, it seemed desirable to utilize the concept of left versus right heart failure. That is, when the strain on the left ventricle induced by infarction is sufficiently severe, this chamber fails, resulting in back pressure in the pulmonary circuit and stasis in the lungs. The clinical picture of left ventricular failure thus presented was described first by Hope[8] and later by other authors in Europe.[9-13] In this country the principle has been discussed more recently by Hirschfelder,[14] Robb and Weiss,[15] White and McGinn[16] and Fishberg;[17] lately, Fishberg, Hitzig and King[2] have applied it to coronary thrombosis. Failure of the left ventricle alone is characterized by dyspnea, orthopnea, ashen gray cyanosis, cough, bloody expectoration, cardiac asthma, pulmonary râles or edema, diastolic gallop rhythm, accentuation of the second pulmonic sound, diminished vital capacity, and prolonged arm-to-

*From the Medical Services and the Cardiographic Laboratory, the Mount Sinai Hospital.

†Read at the meeting of the American Heart Association, Kansas City, Mo., May 12, 1936.

tongue circulation time. When the strain further involves the right ventricle or often initially, if infarction of the interventricular septum occurs, evidence of failure of the right ventricle appears in the form of bluish cyanosis, distended cervical veins, hydrothorax, enlargement of the liver, ascites, edema, increased venous pressure and prolonged arm-to-lung circulation time. A combination of both types of failure usually occurs in coronary thrombosis. White and McGinn[16] have emphasized the fact that initial strain of the left ventricle is responsible not only for the majority of cases of failure of this ventricle alone but of both ventricles combined. In coronary thrombosis, the primary strain is, of course, almost always on the left ventricle.

INCIDENCE AND MORTALITY RATE

This study is based on 140 consecutive ward cases of coronary artery thrombosis (Table I). Cardiac insufficiency was present in two-thirds of the patients; 18 per cent had evidence of left ventricular failure alone and 48 per cent of left and right combined. Isolated heart failure of the right ventricle did not occur. It has been observed that when the heart fails following coronary occlusion, the right ventricle, in addition to the left, usually becomes insufficient. In a previous series studied by Master[1] nearly all the cases showed definite heart failure, usually both left and right. Analysis of the circulatory measurements in coronary thrombosis published by Fishberg and his coworkers[2] indicates similar findings, particularly in the severe and fatal cases. It is interesting to note that while the infarction nearly always involves the left ventricle alone, the cardiac failure which results is usually failure of both left and right ventricles.

TABLE I

INCIDENCE OF HEART FAILURE IN 140 ATTACKS

	FIRST ATTACK	SECOND	THIRD	FOURTH	ALL ATTACKS
No. of cases	74	48	16	2	140
Cardiac failure	39 (53%)	38 (79%)	14 (88%)	2	93 (66%)
Left only*	11 (15%)	12 (25%)	3 (19%)	0	26 (18%)
Left and right†	28 (38%)	26 (54%)	11 (69%)	2	67 (48%)
Mortality rate	8 (11%)	14 (29%)	8 (50%)	0	30 (21%)

*Left ventricular failure.
†Combined left and right ventricular failure.

Cardiac insufficiency occurred in 93 of our 140 cases. It appeared with equal frequency in men and women (Table II) although in this series there were four times as many men as women. The type of failure and the mortality rate were similar for both. The average age of patients with cardiac insufficiency was fifty-seven years, which exceeds by eight years those without failure (Table II). This difference is probably the result of the more advanced involvement of the coronary arteries in the older patients. However, even young patients

developed severe heart failure if the infarction was extensive. The average age of the patients with left heart failure alone was practically the same as that of the patients with combined left and right heart failure.

TABLE II

SEX AND AGE IN HEART FAILURE

	MALES	FEMALES	TOTAL	AVERAGE AGE
No. of cases	111	29	140	54 yr.
Cardiac failure	75 (68%)	18 (62%)	93 (66%)	57 yr.
No cardiac failure	36 (32%)	11 (38%)	47 (34%)	49 yr.
Mortality rate	23 (21%)	7 (24%)	30 (21%)	

The presence of cardiac insufficiency was of great significance in the outcome of an attack of coronary thrombosis. The mortality rate in the group with heart failure was 30 per cent and in that without it only 4 per cent (Table III), a difference to be attributed almost entirely to the cases with combined left and right ventricular failure; the mortality rate in left ventricular failure alone was the same as that in cases without cardiac insufficiency. Furthermore, failure of both ventricles was present in all but three of our fatal cases.

TABLE III

HEART FAILURE AND MORTALITY RATE

	CASES	DEATHS	MORTALITY RATE
Cardiac failure	93	28	30%
Left only	26	1	4%
Left and right	67	27	40%
No cardiac failure	47	2	4%
Total	140	30	21%

EXACT MEASUREMENTS OF THE CIRCULATION

In studying the dynamics of the circulation several quantitative methods have been evolved. The vital capacity of the lungs was determined almost a century ago by Hutchinson.[18] In our experience it has been very useful, and we are in full accord with White and McGinn[16] when they say that it has too long been neglected. This test consists of measuring the volume of air expelled by a forced expiration following a deep inspiration. The normal for the male averages 4,000 c.c. and for the female 3,500 c.c., varying with the surface area. In the absence of pulmonary disease a reduction in vital capacity is an accurate measure of left ventricular failure, particularly when it is below 60 per cent of normal, as Peabody and his associates[19] and Pratt[20] have demonstrated. In heart disease a diminished vital capacity results from congestion of the lung secondary to insufficiency of the left ventricle. The dilated alveolar capillaries and the transudate in the alveoli encroach upon the alveolar spaces and reduce the capacity and elasticity of the lungs.

The function of the left ventricle may also be tested by the time consumed in the passage of a substance from an antecubital vein through the lungs to the peripheral arteries. Numerous substances have been employed[15, 21, 22] to determine this circulation time. As advocated by Fishberg, Hitzig and King,[23] we have used saccharin, the end point being a sweet taste. The normal time consumed is from 12 to 16 seconds and therefore we have considered 18 seconds or more as indicative of a significant slowing of the circulation through the lungs.

Similarly, insufficiency of the right ventricle can be determined by measuring the arm-to-lung circulation time. Blumgart[21] used radium seed emanation, and Hitzig[24] and Miller[25] suggested ether for this purpose. The normal circulation time is from 4 to 8 seconds and this is prolonged when there is slowing of the peripheral venous return through the right ventricle to the lungs.

Elevation of the venous pressure as evidenced by distended neck veins has been recognized for many years as a sign of cardiac insufficiency. Direct measurement of the venous pressure in an antecubital vein has now become a common procedure in heart failure,[26, 27] but only recently has its importance as an indication of failure primarily of the right ventricle been appreciated. Fishberg and his coworkers[2] stressed the value of this test in the study of heart failure in coronary thrombosis. We have used the direct method of Taylor, Thomas, and Schleiter[28] and have considered a pressure of 9 cm. or higher abnormal.

The arm-to-tongue circulation time was determined in 65 cases (Table IV). In 60 cases it was an accurate index of the severity of failure of the left ventricle, and consequently of pulmonary engorgement. In 5 cases with evidence of left or combined failure, such as râles, enlarged liver, low vital capacity, it was normal. This has been noted also in occasional cases by Robb and Weiss,[15] and Hitzig, King and Fishberg.[29]

TABLE IV

ARM-TO-TONGUE CIRCULATION TIME IN 65 ATTACKS

	NORMAL (12-17 SEC.)	SLIGHTLY PROLONGED (12-20 SEC.)	DEFINITELY PROLONGED (21-30 SEC.)	MARKEDLY PROLONGED (31-60 SEC.)
No. of cases	16	12	26	11
Cardiac failure	5 (31%)	8 (67%)	25 (96%)	11 (100%)
Left only	1 (6%)	3 (25%)	8 (31%)	2 (18%)
Left and right	4 (25%)	5 (42%)	17 (65%)	9 (82%)
Vital capacity—				
Average	2,350	2,600	1,900	1,600
50% of normal or less	25%	16%	54%	73%
Orthopnea	0	2 (16%)	16 (61%)	9 (82%)
Mortality rate	0	1 (8%)	6 (23%)	2 (18%)

The circulation time was definitely prolonged, that is, 21 seconds or more, in 57 per cent of the cases. Clinical signs of cardiac insufficiency, usually of both ventricles, were present in all but one of these cases

and a significantly reduced vital capacity (50 per cent of normal or less) and orthopnea were observed in the great majority. The seriousness of a prolonged circulation time was further reflected in an elevated mortality rate.

The arm-to-lung circulation time measured 9 seconds or more in one-third of the cases studied (Table V). In most of these there were clinical signs of failure of both ventricles, including elevated venous pressure. Two cases in which the ether time was slightly prolonged (9 to 10 seconds) offered no other evidence of cardiac insufficiency, and in the absence of other clinical signs it cannot be stated definitely that this prolongation was a manifestation of heart failure.

TABLE V

ARM-TO-LUNG CIRCULATION TIME IN 40 ATTACKS

	8 SEC. OR LESS	9 SEC. OR MORE
No. of cases	27	13
Cardiac failure	15 (56%)	11 (85%)
Left only	9 (33%)	1 (8%)
Left and right	6 (23%)	10 (77%)
Vital capacity		
50% of normal or less	60%	50%
Venous pressure 9 cm. or more	8%	67%
Arm-to-tongue time 21 sec. or more	37%	85%
Mortality rate	1 (3.5%)	2 (15%)

In most of the cases of isolated failure of the left ventricle the arm-to-lung time was normal. Of 27 patients in whom this measurement was normal, nine were suffering from isolated left ventricular failure accompanied by low vital capacity and prolonged arm-to-tongue time. However, although the prolongation of the arm-to-lung time depends solely on insufficiency of the right ventricle, it was found to be normal in 6 cases with definite right ventricular failure. In two of these the venous pressure was elevated. It seems, therefore, that right heart failure is late in affecting the arm-to-lung circulation time, and, when prolongation does appear, other evidence of failure is already present.

The venous pressure was measured in 84 cases (Table VI). Of the 39 patients in whom it was 9 cm. or higher, only one failed to show

TABLE VI

VENOUS PRESSURE IN 84 ATTACKS

	8 CM. OR LESS	9 CM. OR MORE
No. of cases	45	39
Cardiac failure	31 (69%)	37 (95%)
Left only	19 (43%)	1 (2.5%)
Left and right	12 (26%)	36 (92%)
Vital capacity		
50% of normal or less	32%	59%
Arm-to-tongue time 21 sec. or more	45%	73%
Arm-to-lung time 9 sec. or more	17%	77%
Mortality rate	4 (9%)	12 (31%)

evidence of right as well as left ventricular failure. The arm-to-tongue and arm-to-lung circulation times were prolonged, and the vital capacity was significantly reduced in most of this group. When the venous pressure was found to be elevated, congestion in the lungs and enlargement of the liver had already occurred. Hence an elevated venous pressure appeared only when failure of the right ventricle followed that of the left; it was practically always normal in the presence of isolated left ventricular failure. Blumgart and Weiss[30] also found that elevation of the venous pressure was usually preceded by a decrease in vital capacity and slowing of the pulmonary circulation.

Like the arm-to-lung time, the venous pressure was normal in one-quarter of the patients with clinical signs of combined left and right ventricular failure. Thus in early combined failure the venous pressure may be normal despite a diminished vital capacity, prolonged arm-to-tongue, and in some cases prolonged arm-to-lung circulation times. On the other hand, the presence of a normal venous pressure in some of these cases of left and right failure may be explained by the concomitant presence of shock in which the venous pressure tends to be low.[2]

In this connection the relation of venous pressure to shock was studied. It was lowered to 3 cm. or less in 15 cases, yet clinical signs of shock existed in only half of these. Conversely, the venous pressure was elevated to 9 cm. or more in almost half the patients who were in shock and occasionally to 20 cm. or more. Since congestive heart failure was present in many of the latter group, it appears that the height of venous pressure is determined by the predominance of either shock or congestive failure. No such clear-cut correlation between venous pressure and shock as was reported by Fishberg and his coworkers[2] was found in our series, nor could we confirm their impression of a definite relationship between venous pressure and infarction of the interventricular septum. In necropsy examination of 16 cases, most of them with gross infarction of the septum, the venous pressure measured 12 cm. or above in only five, the highest being 18 cm. In general, there was no correlation between the degree of septal involvement and the height of the venous pressure; in one case with practically complete infarction of the septum and almost no signs of shock the venous pressure was only 8 cm.

The vital capacity proved to be the most accurate measure of the degree of cardiac insufficiency (Table VII). It proved to be accurate not only as a diagnostic sign, but as a prognostic one as well, as Ernstene has reported.[31] Only twelve patients had a vital capacity of 75 per cent of normal or higher; none of these died; and only one had evidence of slight failure of the left ventricle. Almost all the patients with a vital capacity of from 25 to 50 per cent of normal had cardiac insufficiency, and the majority were orthopneic. Of eight patients with a vital capacity of from 15 to 25 per cent of normal,

all had severe left and right failure, six had orthopnea, and two died. In more than two-fifths of the patients the vital capacity measured between 50 and 75 per cent of normal (average 2,500 c.c.). Nearly three-fourths of these had signs of congestive failure, and one-third were orthopneic. It seems, therefore, that even this moderate reduction in vital capacity may be an indication of heart failure.[19] As a rule, the vital capacity increased as the clinical condition grew better and therefore was useful in following the improvement of the patient, particularly when frank clinical signs of passive congestion were absent.

TABLE VII

VITAL CAPACITY IN 80 ATTACKS

	VITAL CAPACITY—PER CENT OF NORMAL			
	76 TO 90%	51 TO 75%	26 TO 50%	15 TO 25%
Vital capacity—				
Average	3,500 c.c.	2,500 c.c.	1,650 c.c.	775 c.c.
Range	2,800 to 4,200	1,600 to 3,100	1,200 to 2,000	400 to 1,100
Incidence in 80 attacks	12 (15%)	35 (44%)	25 (31%)	8 (10%)
Cardiac failure	1 (8%)	26 (73%)	21 (84%)	8 (100%)
Left only	0	11 (31%)	6 (24%)	2 (25%)
Left and right	1 (8%)	15 (42%)	15 (60%)	6 (75%)
Orthopnea	1 (8%)	11 (31%)	16 (62%)	6 (75%)
Circulation time				
Prolonged 21 sec. or more	1 (11%)	10 (38%)	15 (75%)	6 (86%)
Slightly prolonged 18-20 sec.	3 (33%)	6 (23%)	2 (10%)	0
Normal 12-17 sec.	5 (55%)	10 (38%)	3 (15%)	1 (14%)
Mortality rate	0	4 (11%)	3 (12%)	2 (25%)

In general, there was a definite correlation between vital capacity and arm-to-tongue circulation time. The latter was prolonged to 21 seconds or more in the majority of cases with a vital capacity less than 50 per cent of normal and in only one case with a normal vital capacity. On the other hand, a normal circulation time occurred in four patients with definite cardiac insufficiency and very low vital capacity. Hence, as Robb and Weiss[15] also found, the vital capacity is usually lowered before slowing of the blood flow and is therefore the first sign of left heart failure. As pulmonary congestion increases, the pulmonary blood flow is slowed and the arm-to-tongue circulation is prolonged. As the strain falls on the right ventricle, the venous pressure is elevated and finally as the peripheral flow is slowed the arm-to-lung time is increased.

PULSE RATE IN CARDIAC INSUFFICIENCY

Clinicians early realized the importance of the pulse rate in estimating the degree of heart failure; a fast rate was associated with cardiac strain and a normal or only slightly elevated rate was a good prognostic sign. Physiologists showed that the rapid rate of heartbeat indicated a mechanically inefficient heart muscle, with increased oxygen

consumption for the work performed.[32-34] When the rate is slow, diastole is long enough for the myocardium to receive sufficient oxygen, and the oxygen consumption per unit of time is the most economical. The mechanism for the increased heart rate in severe heart failure may be explained by the Bainbridge reflex,[35] that is, an increased venous pressure such as occurs in heart failure distends the right auricle and reflexly produces an acceleration in heart rate. Fishberg[17] reasoned that in coronary artery thrombosis reflexes initiated in the carotid sinus and aorta by the drop in blood pressure gave rise to tachycardia.

We also found that the incidence of cardiac insufficiency rose with an increasing heart rate (Table VIII). If at any time in the course of the attack, the rate rose to 120 beats per minute or more, cardiac insufficiency was usually present (85 per cent). When the rate was 100 to 120, cardiac insufficiency was present in three-quarters of the cases. In both these groups the cardiac insufficiency in the majority of the cases was combined left and right ventricular failure. When the heart rate was below 100, heart failure was present in only one-half of the cases. These findings were consistent in heart rates occurring at any time during the attack. Even in the presence of shock a heart rate above 100 usually indicated that there was also cardiac insufficiency.

TABLE VIII

PULSE RATE AND HEART FAILURE (135 ATTACKS)

	60-80	80-100	100-120	120/MIN. OR OVER
No. of cases	16	43	42	34
Cardiac failure	7 (44%)	26 (60%)	30 (71%)	29 (85%)
Left only	3 (19%)	11 (26%)	6 (14%)	6 (17%)
Left and right	4 (25%)	15 (34%)	24 (57%)	23 (68%)
Gallop rhythm	2 (12%)	13 (30%)	16 (38%)	23 (68%)
Mortality rate	1 (6%)	5 (12%)	9 (21%)	15 (44%)

The vital capacity was decreased to 50 per cent of the normal in more than one-half of the cases with tachycardia but in only one-third of the cases with a pulse rate below 100. Gallop rhythm frequently accompanied tachycardia, occurring in almost three-quarters of the patients with a rate of 120 or more, in one-third when the rate was from 100 to 120, and in one-fifth when it was below 100. As Levine[6] and Bramwell[36] have already found, it is uncommon with a slow pulse rate.

The mortality rate was highest in the group with the most rapid pulse rate. When the rate was 120 or more, death occurred in 44 per cent, but in only 10 per cent when it was below 100. In 16 patients the pulse rate never rose above 80, and only one of these died. Therefore, in coronary artery thrombosis tachycardia indicates severe heart failure.

PULSE PRESSURE AND CARDIAC INSUFFICIENCY

A drop in both systolic and diastolic blood pressure usually succeeded coronary occlusion. In many of the cases the drop in the systolic pressure was much greater than that in the diastolic so that the pulse pressure became small. This decrease in pulse pressure has been attributed to the lowered cardiac output resulting from shock. Although it is commonly considered that a pulse pressure of less than 40 mm. is abnormal, it must be remembered that a "normal" pulse pressure depends on the absolute values of the systolic and diastolic pressures. Thus a low pulse pressure is probably more significant when the diastolic pressure is high than when it is normal. Actually we have found that in patients suffering from coronary thrombosis the pulse pressure change was significant only when it fell to 20 mm. or less (Table IX). This occurred in 12 patients, 10 of whom developed cardiac insufficiency, all but one having both left and right ventricular failure. Seven of the twelve patients died, making the high mortality rate of 58 per cent. On the other hand, the incidence of cardiac insufficiency and the mortality rate in the patients with a pulse pressure above 20 mm. corresponded with those for the entire series. It is apparent, therefore, that the incidence of cardiac insufficiency and the mortality rate were increased only when the pulse pressure fell to 20 mm. or less. Coombs[37] reported similar results with a pulse pressure of 25 mm. or less.

TABLE IX

PULSE PRESSURE IN HEART FAILURE (136 ATTACKS)

	31 MM. OR MORE	21 TO 30 MM.	20 MM. OR LESS
No. of cases	73	51	12
Cardiac failure	47 (64%)	34 (67%)	10 (83%)
Left only	17 (23%)	8 (16%)	2 (16%)
Left and right	30 (41%)	26 (51%)	8 (67%)
Shock	25 (34%)	23 (45%)	9 (75%)
Mortality rate	10 (14%)	9 (18%)	7 (58%)

The effect of shock or peripheral circulatory failure on pulse pressure is shown by the presence of this condition in three-fourths of the patients with a pulse pressure of 20 mm. or less and in only one-third of the patients with pulse pressure above 30 mm. The high mortality in the former group is probably the result of a combination of severe peripheral and congestive heart failure.

HEART SOUNDS

A change in the intensity and quality of the heart sounds following coronary occlusion has long been noted and is of great diagnostic value. The first sound becomes muffled or faint, and therefore the second seems relatively louder. The two sounds may be of equal intensity (tic-tac),

and if the rate is rapid, embryocardia results. A definite decrease in intensity occurs usually within two or three days following the attack but occasionally may not be observed for two weeks.

Although the classification of heart sounds according to quality is a subjective one, pertinent observations have resulted from a study of this type (Table X). In ninety-one patients considered to have faint or poor heart sounds, cardiac failure was present in four-fifths, and the mortality rate was 29 per cent. This contrasted with a death rate of only 9 per cent in those with fair heart sounds. An embryocardia was present in fifteen instances and was practically always associated with shock and tachycardia.

TABLE X

HEART SOUNDS IN 140 ATTACKS

	FAIR SOUNDS	POOR SOUNDS	EMBRYO-CARDIA	NO GALLOP	GALLOP RHYTHM
No. of cases	45	91	15	96	54
Cardiac failure	21 (47%)	71 (78%)	9 (60%)	47 (49%)	46 (85%)
Left only	8 (18%)	17 (19%)	2 (13%)	12 (13%)	14 (26%)
Left and right	13 (29%)	54 (59%)	7 (47%)	35 (36%)	32 (59%)
Tachycardia 100 or more	20 (44%)	56 (62%)	13 (87%)	37 (38%)	39 (72%)
Shock	12 (26%)	37 (41%)	13 (87%)	31 (32%)	30 (55%)
Mortality rate	4 (9%)	26 (29%)	2 (13%)	12 (13%)	18 (33%)

Parsonnet and Hyman,[38] recording the heart sounds in fourteen cases of coronary thrombosis with poor heart sounds, found that the first sound had lost its larger amplitude and that the second sound had assumed the usual characteristics of the first. We have recently taken heart-sound records of five patients with coronary thrombosis and have found that in four of these the muffling of the first sound was caused by a loss of high frequency vibrations. Apparently injury to the heart muscle lessens the ability to produce this high frequency vibration because of either a loss of muscle tone or change in intraventricular pressure.

An overacting type of heart sound was occasionally observed; when this was present, another thrombosis or heart failure was found to be imminent. If either of these occurred, the heart sounds became poor.

GALLOP RHYTHM

Diastolic gallop rhythm is an adventitious sound which is heard during diastole of the heart and together with the normal physiological heart sounds gives a definite rhythm like the gallop of a horse.[36, 39] The rhythm usually consists of three distinct sounds, occasionally of four. For years numerous authors have emphasized the significance of this rhythm as a sign of cardiac weakness and failure especially of the left ventricle.[36, 40, 41] Thompson and Levine[42] have recently shown it to be a serious prognostic sign in coronary thrombosis.

In our series diastolic gallop rhythm was present in 54 cases (32 per cent) (Tables X and XI). It was most common when the heart rate was rapid and rarely occurred when the rate was below 80 per minute. White and McGinn[16] reported a similar incidence in heart failure following long-standing hypertension or coronary thrombosis. In our patients gallop rhythm was probably associated with insufficiency of the left ventricle since it was as frequent in those with isolated left ventricular failure as in those with combined left and right ventricular failure. About one-half of the patients in each group developed this sign. The serious prognostic import was borne out by the higher mortality rate (38 per cent) in those patients who presented this finding than in those who did not (13 per cent). Furthermore it was present in the great majority of fatal cases.

TABLE XI

SIGNIFICANCE OF GALLOP RHYTHM IN HEART FAILURE

	CASES	GALLOP RHYTHM	NO. MORTALITY	NO GALLOP RHYTHM	NO. MORTALITY
Cardiac failure	93	47 (51%)	18 (38%)	46 (49%)	12 (26%)
Left only	26	14 (54%)	1 (7%)	12 (46%)	0
Left and right	67	33 (49%)	17 (52%)	34 (51%)	10 (29%)
No cardiac failure	47	7 (15%)	0	40 (85%)	2 (5%)

It is interesting to note that seven of the 54 patients with diastolic gallop rhythm developed no other sign of congestive heart failure and, in fact, had a normal venous pressure, circulation time and relatively high vital capacity. A gallop rhythm may thus be the only sign of myocardial strain following coronary occlusion.

ARRHYTHMIAS

The frequent occurrence of arrhythmias in coronary artery thrombosis has often been commented upon. Not uncommonly they are the first indication of trouble. In our series 19 patients, or one in seven, developed a cardiac irregularity other than extrasystoles. In each of three cases several types of arrhythmia occurred at different periods. Nearly every variety of irregularity was encountered. Excluding premature beats the most common was auricular fibrillation, which was present nine times; auricular tachycardia and heart-block were each present three times, nodal rhythm twice, and auricular flutter once. Finally, ventricular tachycardia, emphasized by most authors, occurred only once and lasted but a short time. Premature beats were observed in 25 patients. It is interesting that they were ventricular in origin in three-fourths of the cases, presumably because the infarction affects the ventricle primarily.

In most cases the arrhythmias appeared soon after the thrombosis had taken place, but occasionally auricular tachycardia and fibrillation set in after two or three weeks. The onset was often accompanied

by collapse, especially in cases with sudden marked increase in heart rate as in auricular fibrillation or tachycardia. The outstanding feature of these arrhythmias was the fact that they usually disappeared spontaneously after a short period and in some instances were only fleeting. This was particularly true in auricular fibrillation, as previously reported.[43] Only twice did an arrhythmia become permanent, in one patient with auricular fibrillation who received digitalis and in another with incomplete heart-block.

The transitory nature of the arrhythmias may be explained in several ways. The majority seem to arise either reflexly from the functional derangement attendant on the acute injury to the heart or directly from an irritable focus in the damaged area. Second, in coronary thrombosis a strain is placed on the auricles[1] which may account for the initiation of auricular flutter or fibrillation. The right auricle may be the site of damage in thrombosis of the right coronary artery, and this may initiate auricular fibrillation, flutter, tachycardia, or nodal rhythm. However, there were cases with left coronary occlusion which developed these arrhythmias too. Finally, the conduction system may be the site of injury, particularly in thrombosis of the right coronary artery which supplies the S-A and A-V nodes and the posterior part of the intraventricular septum. Campbell[44] has reported two cases in which stenosis of the specific artery to the A-V node or bundle produced no change in rhythm during life. Usually normal rhythm is reestablished as soon as the initial shock has disappeared and the heart has adjusted itself, but even when there is actual damage of the conduction system as in heart-block, the arrhythmia is likely to be transitory because of the profuse anastomosis between the vessels supplying this area.[45] In this case the duration is usually longer.

In our series the arrhythmias did not play an important rôle in the outcome of the attack. Only four of the nineteen patients, three with auricular fibrillation and one with complete heart-block, died during the period of irregularity. Collapse and heart failure which were also present probably were aggravated or induced by the arrhythmia. Most of the remaining fifteen cases presented some degree of heart failure. This was severe and associated with collapse only when the cardiac rate was either very rapid as in paroxysmal tachycardia, or very slow as in complete heart-block. The importance of the heart rate is illustrated in another way by two cases. Each of these patients had suffered a coronary occlusion a short time previously. Both were suddenly seized with severe precordial pain and went into collapse; auricular fibrillation with a rapid ventricular rate was present in one case and auricular tachycardia in the other; in both the electrocardiogram showed changes characteristic of coronary thrombosis. They were, therefore, considered to have suffered a second occlusion. However, when the symptoms and the electrocardiographic abnormalities disappeared completely within twenty-four hours of the cessation of

the arrhythmia, it was evident that the entire episode could be accounted for by the effect of a sudden increase in cardiac rate on a heart already damaged by a previous thrombosis.

RESPIRATORY RATE

Peabody, Wentworth, and Barker[19] suggested that in the absence of pulmonary disease the respiratory rate, like the pulse rate, is a useful and simple index of heart failure. These authors have shown that heart failure, by reducing the vital capacity of the lungs, necessitates an increase in pulmonary ventilation to supply the patient with adequate oxygen. With a lowered vital capacity and increased minute volume of respiration, the respiratory rate must be increased. These three factors are chiefly responsible for the dyspnea of heart failure. The diminished vital capacity may not alone be responsible for the increase in number of respirations per minute; pulmonary congestion may cause a reflex acceleration of breathing through the vagus nerve and the respiratory center.[46]

In our cases of coronary thrombosis the respiratory rate remained normal unless cardiac insufficiency or a pulmonary complication, such as pneumonia or infarction, developed (Table XII). In the absence of these complications the rapidity of the respiratory rate indicated, not only the presence, but also the degree of cardiac insufficiency. A rapid respiratory rate was usually found in the first week of the illness. When it was 20 per minute or less, cardiac insufficiency was present in only a small group of cases and was of the left ventricle alone. Orthopnea was absent; the vital capacity was relatively high; and none of the attacks was fatal. As the respiratory rate reached 28, the incidence of combined cardiac insufficiency, orthopnea, and fatal attacks rose, and the vital capacity was diminished. Only four of 35 patients with a respiratory rate over 28 had no cardiac insufficiency, and in these the tachypnea was due to a pulmonary complication.

TABLE XII

RESPIRATORY RATE AND HEART FAILURE (132 ATTACKS)

	20/MIN. OR LESS	21 TO 24	25 TO 28	29 OR MORE
No. of cases	22	44	31	35
Cardiac failure	8 (36%)	27 (61%)	25 (81%)	31 (87%)*
Left only	6 (27%)	7 (16%)	9 (30%)	3 (9%)
Left and right	2 (9%)	20 (45%)	16 (51%)	28 (80%)
Orthopnea	0	15 (34%)	19 (61%)	27 (77%)
Vital capacity				
Per cent of normal	66%	57%	56%	16 (40%)
50% of normal or less	12%	44%	47%	42%
				60%
Mortality rate	0	5 (11%)	7 (23%)	

*The other four patients without cardiac insufficiency suffered from bronchial asthma or pneumonia.

DYSPNEA AND ORTHOPNEA

Dyspnea has been described as the initial and cardinal symptom of heart failure[47] and, as we now know, specifically of left ventricular failure. Orthopnea is, of course, an advanced type of dyspnea. Its mechanism is probably due to a reduction in vital capacity and reflex stimulation of the respiratory rate which results in increased pulmonary ventilation, factors that are present in congestion of the lungs. Since a sitting or semirecumbent position relieves the patient, it may be assumed that the orthopnea can be attributed to the increased vital capacity[48, 49] and diminished pulmonary ventilation[19, 46] which occur in this position.

Orthopnea was a frequent symptom in our series, occurring in 44 per cent of the cases (Table XIII). Frequently it was present in the absence of pain. Nearly always present in the more seriously ill patients, it was an implication of severe combined left and right failure. The mortality rate was 43.5 per cent in this group and was only 3 per cent in those without orthopnea. The vital capacity was usually lowered to 50 per cent of normal or less, the average being 1,800 c.c.

TABLE XIII

ORTHOPNEA AND VITAL CAPACITY

	NO.	AVERAGE VITAL CAPACITY		MORTALITY RATE
		C.C.	% OF NORMAL	
Cardiac failure with orthopnea	62 (44%)	1,800	44	27 (43.5%)
Left only	9	1,700	43	1 (11%)
Left and right	53	1,800	44	26 (49%)
Cardiac failure without orthopnea	31 (22%)	2,100	55	1 (3%)
Left only	17	2,000	52	0
Left and right	14	2,300	57	1 (7%)
No cardiac failure or orthopnea	47 (34%)	2,700	66	2 (4%)

On the other hand cardiac insufficiency may occur without orthopnea. Thirty-one patients with evidence of failure of both left and right ventricles were not orthopneic. It is noteworthy that in this group the vital capacity was somewhat higher, averaging 2,100 c.c. and the mortality rate was only 3 per cent. As the patients without signs of cardiac insufficiency had a vital capacity averaging 2,700 c.c., it is evident that orthopnea is associated with a lowered vital capacity secondary to pulmonary congestion and is of serious prognostic import.

PULMONARY EDEMA

As far back as 1878 Welch[9] produced pulmonary edema in rabbits by injuring the left ventricle. Since then, clinical observations have emphasized the relation between pulmonary edema and insufficiency of the left ventricle secondary to acute myocardial infarction.[13, 16, 17, 50, 51] When the ventricle fails, congestion of the lungs appears; if it is severe

or sudden in occurrence, the patients become very dyspneic and develop cardiac asthma. A further increase in congestion results in a sufficiently high pressure in the pulmonary capillaries to bring on actual edema of the lungs. Libman,[52] Levine[6] and Herrick[53] pointed out that pulmonary edema may be the first or only indication of a coronary occlusion and unless characteristic electrocardiographic evidence of myocardial infarction is obtained, such an attack may go unrecognized. Nine of our patients who developed pulmonary edema had little or no precordial pain. Massive pulmonary edema was not infrequent, occurring in twenty patients, or over one-fifth of those with congestive failure (Table XIV). It was more common in women than in men, perhaps because of the higher incidence of previous hypertension in the former.

TABLE XIV

PULMONARY EDEMA IN 140 ATTACKS

	NUMBER
Incidence	20 (14%)
Sex—	
Male	14 (70%)
Female	6 (30%)
Previous occlusion	14 (70%)
Previous hypertension	17 (85%)
Enlarged heart	19 (95%)
Minimal pain	9 (45%)
Left and right heart failure	18 (90%)
Mortality	10 (50%)

An initial attack of coronary thrombosis was seldom complicated by pulmonary edema except in patients with long-standing hypertension. The great majority of these patients gave a history of a previous occlusion as well as hypertension, and all but one had definite cardiac enlargement. In other words, pulmonary edema following coronary occlusion usually occurred in those whose hearts had been subjected to long-standing left ventricular strain. Practically all the patients with pulmonary edema also showed such evidence of failure of the right ventricle as enlarged liver, distended peripheral veins and elevated venous pressure. The mortality rate of 50 per cent, a rate considerably higher than in other patients with congestive failure, was further evidence of the severity of the cardiac failure.

SHOCK

Heart failure following coronary thrombosis differs from ordinary congestive failure in that it is frequently associated with peripheral circulatory collapse. The latter is probably a nervous phenomenon initiated by the acute myocardial injury and results in a low peripheral venous pressure, reduced venous return to the heart, and diminished cardiac output. In congestive heart failure, on the contrary, there is

an increase in venous pressure. The clinical picture of the attack depends therefore on which of the two elements predominates.

In their recent study of myocardial infarction Fishberg and his associates[2] found that in patients with previously normal hearts shock might dominate the picture completely, particularly early in the attack, and that in patients with previous heart failure the signs of either shock or failure might be foremost. The frequent absence of cardiac insufficiency during shock, even when extensive infarction existed, they attributed to the diminished venous return which lessens the work of the heart and prevents passive congestion of the veins. This conclusion is borne out by the low venous pressure and normal circulation time present during the stage of shock. Shock immediately after the attack, followed gradually by signs of passive congestion as the shock diminished, was a sequence frequently found in their patients. We have been less successful in dividing our cases into those with shock and those with heart failure. In most instances we found that the two were present simultaneously, particularly when the patients were observed for several days following the onset of the attack. Harrison,[3] too, points out the frequent association of these conditions following coronary thrombosis.

Manifestations of shock, such as grayish pallor, moist clammy skin, cold extremities, collapse or marked weakness, and rapid fall in blood pressure, appeared in almost one-half our patients (Table XV). Four-fifths of these developed, in addition, passive congestion, either simultaneously or subsequent to recovery from the effects of shock. On the other hand, only three-fifths of those without shock developed cardiac insufficiency. It may be assumed then that both shock and cardiac insufficiency usually occur together and in the more seriously ill patients with large infarctions—a conclusion borne out by the fact that two-fifths of the patients in shock died. As practically all the fatal cases also suffered from a severe degree of congestive failure, it is obvious that both peripheral circulatory and cardiac failure are important factors in determining the outcome of an attack of thrombosis. In the fatal cases, however, the picture of congestive failure usually predominated over that of shock, except when death occurred very early in the attack.

TABLE XV

SHOCK AND HEART FAILURE IN 135 ATTACKS

	NO SHOCK	SHOCK
No. of cases	74	61
Cardiac failure	45 (61%)	50 (81%)
Left only	16 (22%)	10 (17%)
Left and right	29 (39%)	40 (64%)
Cyanosis	37 (62%)	53 (83%)
Mortality rate	5 (7%)	25 (42%)

CYANOSIS

Excluding patients with pulmonary complications, three types of cyanosis were observed. In the stage of shock there was usually a grayish pallor rather than cyanosis. In the majority, the addition of left ventricular failure produced an ashy gray cyanosis due to the admixture of bluish cyanosis and pallor. Many clinicians have noted the characteristic facies which this ashy gray hue imparts to coronary thrombosis. Second, when severe right heart insufficiency was present, the stasis in the peripheral vessels produced the typical dark bluish purple cyanosis seen in ordinary congestive heart failure. Finally, we have recently observed four cases in which an intense, blue, symmetrical acrocyanosis was present in all extremities. These patients were extremely sick and suffered from a combination of severe shock and cardiac failure, with marked slowing of the peripheral blood flow.

Definite cyanosis occurred in 65 per cent of our patients (Table XVI). The incidence of cardiac insufficiency was definitely higher in these than in the noncyanotic patients and furthermore, the incidence of combined left and right heart failure was twice as frequent.

TABLE XVI

CYANOSIS IN 135 ATTACKS

	NO CYANOSIS	CYANOSIS
No. of cases	44	91
Cardiac failure	23 (52%)	68 (75%)
Left only	9 (20%)	14 (15%)
Left and right	14 (32%)	54 (60%)
No cardiac failure	21 (48%)	23 (25%)*
Shock	11 (25%)	53 (58%)
Mortality rate	4 (9%)	26 (29%)

*Nine patients had a pulmonary complication.

Shock developed in more than half of the cyanotic patients, a frequency double that in the noncyanotic patients. The mortality rate was also considerably higher with cyanosis, and conversely nearly all the fatal cases showed a moderate or severe degree of cyanosis. It seems therefore that the type of cyanosis seen in coronary thrombosis is usually a sign of both cardiac insufficiency and shock.

In eleven patients cyanosis of varying degree was observed in the absence of shock, any other sign of cardiac insufficiency, and any pulmonary complication such as pneumonia, pulmonary infarction, or emphysema. It may be that mild temporary shock or cardiac insufficiency occurred very early in the attack before the patients came under observation and that the cyanosis persisted long after these conditions disappeared. Hamman[4] has pointed out that cyanosis may persist throughout convalescence of the attack even after other signs of heart failure have disappeared.

FEVER

Fever is one of the cardinal signs of coronary thrombosis. Although congestive heart failure has been shown to cause fever,[54] it is probable that in coronary thrombosis the fever results from the necrosis of the heart muscle alone. In the absence of infection a rise to 101° F. or more has been taken to indicate the presence of a large area of infarction. Among our 68 patients with such a rise in temperature the incidence of cardiac insufficiency and the mortality rate were considerably higher than in those without fever (Table XVII). Uncomplicated by infection the temperature not infrequently reached 103° F.; it rose to 104° in only seven patients, six of whom were suffering from pneumonia in addition to the cardiac infarction. In the majority of cases fever was highest several days after the onset of the infarction and gradually subsided within the first week. Three-fourths of this group developed cardiac insufficiency. Of nineteen cases with fever for from eight to fourteen days, cardiac insufficiency was present in all but two. Only a minority of patients without fever developed cardiac insufficiency. These observations lead to the conclusion that fever is a reliable guide to the degree of infarction.

TABLE XVII

FEVER AND HEART FAILURE (138 ATTACKS)

	LESS THAN 101° F.	101° F. OR HIGHER
No. of cases	68	70
Cardiac failure	32 (47%)	51 (73%)
Left only	9 (14%)	12 (17%)
Left and right	23 (33%)	39 (56%)
Leucocytosis 15,000 or more	9 (13%)	21 (30%)
Mortality rate	12 (18%)	18 (26%)

Fever of two or three weeks' duration occurred in only three uncomplicated cases; all were in cardiac failure. Three of four patients with fever persisting longer than three weeks developed cardiac insufficiency. However, since all four had a complication other than cardiac infarction to account for the fever, the latter cannot be correlated with the presence of cardiac failure. In ten patients the various complications responsible for prolonged fever were pneumonia, embolic accidents, and renal infection. When fever in coronary thrombosis lasts for more than two weeks, one must search for one of the above or similar conditions, since we have seen that, even when congestive failure is present, fever is ordinarily of short duration.

LEUCOCYTOSIS

Another characteristic sign of coronary thrombosis is leucocytosis. Libman[52] has shown that it may occur within two hours of the attack and begins to disappear usually after two days. The average total white blood cell count is from 12,000 to 15,000, but much higher

figures have been reported. The height of the leucocyte count has been taken as a guide of the extent of myocardial infarction. Recently the prognostic value of the nonfilament and eosinophile percentages has been emphasized.[55]

Although it has been stated that nearly every attack of coronary thrombosis is followed by leucocytosis, the white blood count was less than 10,000 in two-fifths of our patients (Table XVIII). However, the fact must be considered that a number of our patients came under our observation one to two weeks following their attack when the leucocytosis may have subsided. A leucocytosis of 15,000 or more was found in nearly one-fourth of the cases. In these the incidence of cardiac insufficiency was no higher than in the patients with a normal or only a slightly elevated white blood count.

TABLE XVIII

LEUCOCYTE COUNT IN 120 ATTACKS

	LESS THAN 10,000	10,000-14,900	15,000-19,900	20,000 OR MORE
No. of cases	49	43	19	9*
Cardiac failure	32 (65%)	31 (72%)	13 (68%)	6 (67%)
Left only	10 (20%)	7 (16%)	3 (15%)	2 (22%)
Left and right	22 (45%)	24 (56%)	10 (53%)	4 (45%)
Temperature 101° F. or higher.	13 (26%)	26 (60%)	12 (63)%	7 (77%)
Mortality rate	2 (4%)	11 (26%)	6 (31%)	2 (22%)

*Two other patients excluded from this group suffered from an associated lobar pneumonia.

The difficulty of correlating leucocytosis with cardiac failure may be explained in part by the presence of so many other conditions giving rise to leucocytosis, such as pulmonary infection, ventricular mural thrombosis, deep vein phlebitis, and embolization from the latter two sources.

The presence of leucocytosis gives a poor prognosis. The mortality rate of the seventy patients with a white count of 10,000 or more was definitely higher than in those with a normal white count. However, the prognosis was apparently not worse with a count of 20,000 than with one of 10,000. Although there was usually a correlation between leucocytosis and fever, one was present in the absence of the other in a small group of patients.

HYPERTENSION AND CARDIAC ENLARGEMENT

Hypertension has been shown by most writers to be a significant predisposing factor in coronary artery thrombosis, but its relation to heart failure has not been extensively studied. Averbuck[56] found that heart failure in hypertension was usually associated with coronary sclerosis or, less often, with thrombosis. White,[57] too, reported that

in a large series of hypertensive patients coronary thrombosis was not infrequently the factor inciting congestive heart failure. They, as well as numerous other writers,[58-62] found that cardiac enlargement was almost a constant precursor of cardiac failure. Starling and his co-workers[33, 58] established the principle that a heart put under strain compensates by an increase in muscle fiber length and by active stretching of the ventricular wall and therefore a fatigued heart dilates in order to carry on the same circulation and amount of work as a normal heart. When the ventricles are unable to empty themselves completely, dilatation is inevitable and is, as Fishberg[17] has aptly stated, a useful adaptation by the heart to increasing work. Hypertension with its increased arterial resistance induces dilatation which if prolonged is followed eventually by hypertrophy.

Nemet and Gross[61] have shown that in the absence of hypertension muscle damage in chronic coronary disease may lead to cardiac hypertrophy. They accepted the view that increased initial fiber tension, resulting from muscle damage rather than increased work, may be the stimulus to dilatation and hypertrophy, and they emphasized the fact that congestive failure in coronary disease is usually the failure of the hypertrophied heart. In a post-mortem study, Nathanson[59] showed that in the absence of definite cardiac enlargement congestive failure rarely develops in patients with acute or chronic coronary artery disease. The enlarged heart has been shown to be an inefficient heart. Since its oxygen consumption is related to the degree of dilatation,[33, 63] an enlarged dilated heart consumes an increased amount of oxygen and liberates a high quantity of energy but the useful work accomplished is relatively small, and hence the mechanical efficiency is low.

Evidence of hypertension, that is, a systolic blood pressure of 150 mm. or more or a diastolic of 90 mm. or more, was established in 70 per cent of our patients either at the time of observation or from a reliable history (Table XIX). Cardiac insufficiency developed in almost three-quarters of these hypertensive patients, but in only half of those without elevated blood pressure. The presence of hypertension had only slight if any effect on the mortality rate. An analysis of cases with cardiac failure showed a history of antecedent hypertension in only 75 per cent, that is, in one-fourth of the patients failure was apparently not preceded by hypertension.

TABLE XIX

HYPERTENSION AND HEART FAILURE (140 ATTACKS)

	NO HYPERTENSION	HYPERTENSION
No. of cases	43	97
Cardiac failure	23 (53%)	70 (72%)
Left only	4 (9%)	22 (23%)
Left and right	19 (44%)	48 (49%)
Mortality rate	7 (16%)	23 (24%)

A more constant association was found between cardiac enlargement and heart failure than between hypertension and heart failure. A heart was considered enlarged if dullness was increased to the left (midclavicular to anterior axillary line) or to the right (at least 3 cm. to the right of the midsternum) or if the transverse diameter on teleroentgenogram measured more than one-half the total internal thoracic diameter of the chest. By either of these standards, the heart was found definitely enlarged in 65 per cent of the cases (Table XX). Evidence of cardiac insufficiency, usually of both ventricles, was present in nine-tenths of these. Although dilatation theoretically must occur in a normal-sized heart which becomes insufficient, six patients with definite congestive failure showed no clinical evidence of cardiac enlargement. The incidence of cardiac enlargement in the patients who developed congestive failure was much higher, 87 per cent (Table XXI). In nearly all instances the insufficiency was of both the left and right ventricles. Moreover, only one-fifth of the patients who did not develop cardiac insufficiency had an enlarged heart. It may be concluded that patients with coronary thrombosis are much more prone to develop congestive failure when cardiac enlargement is present.

TABLE XX

HEART SIZE AND HEART FAILURE (140 ATTACKS)

	NORMAL	ENLARGED
No. of cases	49	91
Cardiac failure	12 (24%)	81 (89%)
Left only	6 (12%)	20 (21%)
Left and right	6 (12%)	61 (67%)
Mortality rate	0	30 (33%)

TABLE XXI

HEART ENLARGEMENT AND HEART FAILURE

	CASES	ENLARGED HEART
Cardiac failure	93	81 (87%)
Left only	26	20 (77%)
Left and right	67	61 (91%)
No cardiac failure	47	10 (21%)
Total	140	91 (65%)
Fatal attacks	30	30 (100%)

It may be assumed that the existence of cardiac enlargement in the majority of our patients was due primarily to preexisting hypertension since this was present in 85 per cent of those with enlarged hearts and in only 41 per cent of those with normal-sized hearts. Such a high incidence in the former group emphasizes the rôle of hypertension as a factor in cardiac enlargement and helps to explain the greater incidence of cardiac insufficiency in the hypertensive patients.

In a small number of cases the cardiac enlargement observed in a patient with coronary thrombosis may be attributed to the congestive

heart failure. A large infarction occurring in a previously normal-sized heart may produce sufficient myocardial weakness to lead to cardiac dilatation and congestive failure. Observation in such cases may show the heart to enlarge as the signs of passive congestion appear. In a patient under our care for many years, repeated teleroentgenograms showed a normal-sized heart. After an attack of pulmonary edema, initiated by a coronary occlusion, there was a sudden enlargement of the cardiac shadow which has persisted since recovery from the thrombosis.

MULTIPLE ATTACKS

In a large series of cases of coronary thrombosis already reported,[64] a history of one or more previous occlusions was elicited in approximately one-half the patients. Our own observations, as well as those of other authors, attest to the great frequency of multiple attacks.[65-67] In the present group a typical history of a previous attack was obtained in 47 per cent of the patients (Table I). Of these, four-fifths developed congestive failure, the incidence rising with each succeeding attack, that is, from 53 per cent in the initial attack to 88 per cent in the third attack. It is interesting to note that as many as half the patients suffering an initial attack of thrombosis developed failure since some authors[2] have emphasized that this sequence is uncommon. A history of a previous occlusion was obtained in only 12 per cent of the patients who did not develop heart failure.

The mortality rate, like the incidence of cardiac insufficiency, rose with each succeeding attack, being 11 per cent in the initial and 50 per cent in the third attack. Conversely the majority of patients dying of coronary thrombosis have had a previous occlusion as well as cardiac failure. Repeated attacks, then, are attended by increasingly more frequent failure and, consequently, contribute to a poorer prognosis.

LOCATION OF INFARCT

Attempts have been made in the past to localize the site of myocardial infarction by the type of heart failure present. It was thought by some investigators[12, 68, 69, 70] that occlusion of the right coronary artery led to predominately right ventricular failure while occlusion of the left coronary artery was associated with predominately left ventricular failure. Since thrombosis of either the left or the right coronary artery results in infarction of the left ventricle, such an attempt to localize the site of thrombosis seems theoretically unsound, a conclusion borne out by our own data and that of Fishberg and his coworkers.[2] The latter authors found that left ventricular failure or combined left and right ventricular failure resulted from either infarction of the anterior or posterior surface of the left ventricle. They concluded, therefore, that a differentiation of the left and right coronary thrombosis could not be made from the type of heart failure

present. Nevertheless, Libman[68] has observed several cases in which right heart failure, as manifested by a rapidly enlarging liver, appeared a few hours after occlusion of the right coronary artery.

Analysis of the electrocardiograms and post-mortem material in our series (Table XXII) reveals that infarction of the anterior surface of the left ventricle (T_1, Q_1 type) was not much more common than infarction of the posterior surface. The right coronary artery was involved as often as the left. Other authors[2, 71] have made the same observation. The incidence of cardiac failure in both groups was practically the same. Moreover, there was only a slightly higher incidence of right heart failure in posterior than in anterior infarction. As many as one-third of the patients with signs of occlusion of the left anterior descending coronary artery developed manifestations of combined left and right ventricular failure. The mortality was the same for both groups. But when signs of involvement of both surfaces of the left ventricle were present (T_1, T_2, T_3 type), probably due in many cases to occlusion of more than one vessel, both the incidence of cardiac insufficiency, particularly combined left and right failure, and the mortality rate rose considerably.

TABLE XXII

LOCATION OF INFARCT AND HEART FAILURE

	ANTERIOR $T_{1,2}$	POSTERIOR $T_{2,3}$	ANTEROPOSTERIOR $T_{1,2,3}$
No. of cases	57	48	32
Cardiac failure	34 (60%)	31 (65%)	27 (85%)
Left only	13 (23%)	8 (17%)	5 (16%)
Left and right	21 (37%)	23 (48%)	22 (69%)
Mortality rate	9 (16%)	7 (15%)	11 (34%)

It has been suggested by Libman[72] and Fishberg and his associates[2] that infarction of a large portion of the interventricular septum may lead to predominantly right ventricular failure, with distended neck veins, high venous pressure and engorged liver. In our own series gross septal infarction was found in half the fatal cases that were examined post-mortem. All but one had developed a moderate degree of right ventricular failure. This condition, however, was just as frequent and just as severe in the fatal cases that showed little or no septal infarction. Therefore, no direct correlation between septal infarction and right ventricular failure can be drawn from our present material.

FATAL CASES

Our fatal cases and post-mortem observations yielded instructive information. Of the 140 cases reviewed here, death occurred in 30 and autopsies were performed in 23. With two exceptions these patients had manifestations of moderate to severe cardiac failure, which was in most instances combined left and right ventricular failure (Table

XXIII). The two patients who did not develop congestive failure died suddenly early in the attack, one of a ruptured left ventricle and the other in a convulsion, probably due to a cerebral embolus.

TABLE XXIII

HEART FAILURE IN FATAL ATTACKS

	NONFATAL ATTACKS	FATAL ATTACKS
No. of attacks	110	30
Cardiac failure	65 (59%)	28 (93%)
Left only	25 (24%)	1 (3%)
Left and right	40 (35%)	27 (90%)
No cardiac failure	45 (41%)	2 (7%)*

*Two sudden deaths: (a.) rupture of left ventricle; (b.) convulsive seizure.

Acute thrombosis of the left and right main arteries or their branches occurred with equal frequency, a finding which corroborated our earlier conclusion drawn from the electrocardiographic studies. More than one artery was acutely involved in seven cases; in three of these as many as three arteries had been occluded by recent thrombi. Five of the seven cases also showed evidence of previous occlusions. In seven other cases there was recent occlusion of one artery without evidence of occlusion of any other artery. Four of these were in the left anterior descending or left circumflex and two in the right circumflex artery. Death resulting from a closure limited to only a branch of the right coronary is rare, but the occurrence of two such cases in a series as small as this disproves the contention of some investigators[73] that such a finding is almost never observed at postmortem examination. In these seven cases with a single closure congestive heart failure was absent in two and was not marked in two others.

In view of the fact that recent articles[66] have emphasized that infarction may occur without evident thrombosis and vice versa, it is interesting to report that in one case myomalacia was present, but no evidence of a recent thrombosis was found.

Evidence of previous occlusions was present in fourteen cases. In nearly all, the left anterior descending artery was involved alone or together with the right coronary. Only two cases showed an old occlusion of the right coronary without involvement of the left. It appears then that an initial thrombosis occurs usually in the left anterior descending artery. In the cases in which this could be accurately determined, it was found that the initial occlusion involved this vessel ten times and the right coronary only four times. In the second or third attack the right coronary is more frequently involved than the left. Neither the degree nor type of heart failure depended upon the site of the thrombosis, even when gross infarction of the septum was present. As one might expect, however, the more severe cases proved to have multiple occlusions either old or recent.

We may conclude that in the majority of fatal cases one or two vessels have already been occluded by old thrombosis and that the recent thrombosis frequently involves two or three different large vessels. This explains the tendency to repeated attacks in the same patient and the infrequency in fatal cases of a closure limited to one vessel, an observation made also by Sprague and Orgain[74] and Saphir and his coworkers.[66]

Although coronary thrombosis may occur in a patient with a heart of normal size, practically all the patients examined post-mortem had hypertrophied and dilated hearts. Since all but two of these patients had definite congestive failure, it confirms the conclusion reached earlier that cardiac enlargement is invariably associated with congestive failure.

We have stressed the importance of congestive heart failure in determining the severity and outcome of an attack of coronary thrombosis, but we do not wish to leave the impression that congestive failure was responsible for death in every fatal case. In addition to the congestive failure, severe circulatory collapse played a definite rôle in the fatal issue in seven cases, cerebral vascular accidents in four, pulmonary embolization in three, pneumonia in one, uremia following carcinoma of the bladder in one, and hemopneumothorax following exploration for carcinoma of the stomach in one. However, in those cases, congestive heart failure aided in hastening the fatal outcome.

DIFFERENTIAL DIAGNOSIS

Early recognition of an acute coronary thrombosis is of primary importance. We have found that the patients who succumbed in the first twenty-four to forty-eight hours after admission to the hospital were usually those who had not been told of the seriousness of their condition or in whom the disease was not recognized and who were permitted to walk about or work. It is occasionally very difficult to confirm the diagnosis of coronary thrombosis, but in doubtful cases the patient should be kept in bed until the diagnosis is certain.

We have not infrequently observed the occurrence of coronary artery occlusion even in the presence of marked congestive failure, notwithstanding the impression that such a sequence is rare. Indeed it has been suggested by Luten[75] that many factors in heart failure, such as slowing of the coronary blood flow, may contribute to the onset of coronary thrombosis. At any rate, a sudden increase in the manifestations of heart failure in a patient with chronic coronary disease, even in the absence of precordial pain, should make one suspicious of an acute coronary thrombosis,[7] particularly if the patient has suffered a previous thrombosis. Our post-mortem examinations have stressed this observation. In at least three of our fatal cases with chronic congestive failure, the presence of acute coronary thrombosis, manifested

by rapidly increasing heart failure in the absence of precordial pain or characteristic electrocardiographic changes, was confirmed at autopsy.

We did not find evidence to support the common belief that coronary thrombosis does not occur in patients with auricular fibrillation. Two such cases appeared in our series. It must be remembered, however, that an acute thrombosis may be ushered in with a paroxysm of auricular fibrillation as the only symptom.

The difficulty that often arises in the differentiation of coronary thrombosis from attacks of cholecystitis or other acute abdominal conditions is well known and will not be discussed further here. Serial electrocardiograms may be necessary in the differential diagnosis from pneumonia and pulmonary embolism. The characteristic elevation of the RS-T interval, steadily progressing into an inverted T-wave, is not seen in these conditions. In fact, we believe that only pericarditis with effusion may completely simulate the electrocardiogram of coronary artery thrombosis including the RS-T and T-wave changes. Another differential point is that pulmonary embolism is usually characterized by intense cyanosis and tachypnea out of all proportion to the clinical signs and not relieved by oxygen.

The signs of congestive heart failure should be sought carefully. Although in this investigation we have made use of such aids in diagnosis as determinations of the venous pressure and circulation times, clinical observation alone will be sufficient in the majority of cases. Râles in the lungs and enlargement of the liver are the earliest signs of congestive failure to appear. Occasionally râles in the lungs are absent despite such clear-cut signs of left ventricular failure as low vital capacity and x-ray evidence of pulmonary congestion. This point has been emphasized by Robb and Weiss.[15] We have had the same experience, but we believe that if the patient is regularly and carefully examined râles will rarely be missed when left heart failure is present.

Heart failure in coronary thrombosis is frequently simulated by complicating conditions in the lungs. These may be due directly to the myocardial infarction, as in pulmonary embolism and infarction secondary to mural thrombosis of the right ventricle, or they may be associated conditions such as pneumonia, chronic bronchitis, and emphysema and bronchial asthma. It is in the differential diagnosis that we have found the circulatory measurements, such as the venous pressure and circulation times, most valuable.[76] Although pulmonary disease may be accompanied by dyspnea, orthopnea, cyanosis, low vital capacity, and physical and x-ray signs in the lungs, these circulatory measurements are usually normal. Furthermore, the persistence of fever for more than two weeks should make one suspect that the signs in the lungs may be due to pneumonia and not to congestion. However, the simultaneous presence of both is not uncommon, for the vascular congestion predisposes to infection in the lungs.

We have not infrequently observed moderate azotemia and albuminuria. This does not necessarily indicate primary kidney disease, for congestive failure may also produce these changes. Determining the specific gravity often aids in diagnosis; if it is high, it suggests congestive failure.

A sign of cardiac failure in coronary thrombosis not mentioned heretofore is the appearance of large P-waves in the electrocardiogram. In a recent study Master[1] showed that congestive heart failure was very common following coronary thrombosis, occurring in 36 of his 40 cases and that it was usually associated with large P-waves. The explanation offered was that the injury to the left ventricle or the increased intra-auricular pressure in venous stasis would lead to auricular dilatation. The degree of P-wave enlargement was closely correlated with the degree of congestive failure present.

TREATMENT

Once a diagnosis of coronary artery thrombosis was made, the patient was immediately put to bed. Absolute mental and physical rest was enjoined; this included being fed and avoiding visitors, business cares, and overattention by an anxious family. Enemas and catharties were not given during the first few days unless distention was severe. The fluid intake was limited to 1,200 c.c. except when azotemia was present. Salt was restricted in cardiac failure.

The patients were underfed the first week, and then, if improvement took place, they were placed on an 800 calorie diet. The diet was adequate and well balanced, consisting of approximately 100 gm. carbohydrate, 50 gm. protein, and 20 gm. fat. Occasionally a Karell diet was given for one or two days a week. This regime of undernutrition eliminates gastrocardiac reflexes, lowers the basal metabolic rate, and diminishes the work of the heart.[77] The systolic and diastolic blood pressure, the pulse pressure, and the heart rate are decreased, indicating a lowering in cardiac output and work of the heart. It is true that the basal metabolic rate is elevated in congestive failure, but it is less high when a diminished calorie intake is used than when the patient is on a regular diet.

We did not use digitalis, for it is usually unnecessary and may actually be harmful. When precordial pain was present, we considered it contraindicated. Levine[6] advocates the use of digitalis when failure complicates coronary artery thrombosis. Very occasionally we have seen digitalis of benefit in severe congestive heart failure in the subacute or chronic phase of the disease, and it may be necessary in the rare cases of auricular fibrillation with rapid ventricular rate in which cardiac failure is impending. We believe, however, that the mercurial diuretics with acidifying drugs like ammonium chloride and ammonium nitrite are usually more efficacious in cardiac failure. Mercupurin has been

given hundreds of times without harmful results even when kidney involvement was a complication. If profuse diuresis occurs, salt must be given to prevent excessive dehydration. The mercurial diuretics together with the acidifying drugs were useful in relieving paroxysmal and nocturnal dyspnea, Cheyne-Stokes breathing and cardiac asthma.[78] Morphine should not be given in conjunction with the mercurial diuretics as it has an antagonistic action.

The xanthine preparations, such as theophyllin and ethylenediamine (aminophyllin), occasionally gave good results when administered intravenously. We observed no definite effect when they were given by mouth. Morphine, or better, dilaudid (Bilhuber-Knoll) has been found an invaluable aid in pain, restlessness, sleeplessness, dyspnea, orthopnea, and cardiac asthma.[64] We prefer dilaudid since it is not so constipating as morphine or codeine.

Some years ago it was suggested[79] that quinidine sulphate be given prophylactically in coronary thrombosis to prevent ventricular tachycardia. Although the authors believed the drug aided in stopping the tachycardia, seven of their eight patients died, an unusually high mortality rate. We object to the use of this drug in myocardial infarction. First, it is unnecessary, for the arrhythmias, particularly the paroxysmal tachycardias, are usually transitory and remit without treatment. Second, we consider quinidine sulphate a dangerous drug; it is a protoplasmic poison. It may stop an arrhythmia, but it may cause more harm by direct action on the cardiac muscle.

We gave glucose intravenously to very few patients since with the regime of undernutrition in the early days following the coronary thrombosis additional food was not required. Even if nausea or vomiting is present, it is unnecessary to resort to intravenous injection because these symptoms last only a day or two. We feel that the benefit derived from the use of glucose intravenously simply to maintain a high glycogen content of the heart muscle is largely theoretical and that in left ventricular failure other measures, such as the use of morphine and the mercurial diuretics, are more efficacious.

Venesection is indicated in pulmonary edema and, perhaps, when there is markedly increased venous pressure with engorged veins, large liver, cyanosis, and high blood pressure. As in other forms of severe congestive failure venesection at times will produce remarkable temporary improvement.

Oxygen therapy was helpful as it occasionally relieved severe pain and was of benefit in cyanosis, marked dyspnea, and pulmonary edema. As ordinarily used, however, an oxygen tent may be uncomfortable and do more harm than good. The moisture should be adequate and excessive cold avoided.

SUMMARY AND CONCLUSIONS

Congestive heart failure occurred in 66 per cent of patients with acute coronary thrombosis. It usually consisted of failure of both ventricles, occasionally of the left ventricle alone.

The mortality rate was 30 per cent in the presence of heart failure and only 4 per cent when it was absent.

The incidence of heart failure and the mortality rate were the same in both sexes. The average age of patients with heart failure was fifty-seven years; of those without it forty-nine years.

The measurements utilized for determining the degree of heart failure were the vital capacity, venous pressure and arm-to-tongue and arm-to-lung circulation times. The vital capacity proved to be the simplest and the most reliable gauge of pulmonary engorgement in failure of the left ventricle.

The following clinical signs were associated with heart failure and with a poor prognosis: pulse rate of 100 or more, pulse pressure of 20 mm. or less, "muffled" or "tic-tac" heart sounds, diastolic gallop rhythm, respiratory rate of 28 or more, cyanosis, orthopnea, pulmonary edema, fever above 101° F. and severe shock. Pulmonary edema at times was the only sign of coronary thrombosis. In cases with shock very profound acrocyanosis might be present.

Arrhythmias of all types were observed. Usually they were transient, disappeared spontaneously and did not alter the prognosis.

Heart failure was more common in patients with a history of a previous occlusion or long-standing hypertension and in those with enlarged hearts. The relation between cardiac enlargement and heart failure is discussed.

Pulmonary complications such as infarction and pneumonia were frequent. The differential diagnosis from heart failure is discussed.

Heart failure was severe when the area of myomalacia was large and when both anterior and posterior surfaces were damaged. However, no correlation was found between the incidence, type, and degree of heart failure and the site of infarction.

Analysis of the fatal cases revealed both heart failure and cardiac enlargement to be almost constant findings. At post-mortem examination it was found that old thrombosis in addition to the acute occlusion was present in the majority of cases, that the left anterior descending branch of the left coronary was usually the initial vessel occluded, that thrombosis was rarely limited to one vessel, and that the incidence of anterior and posterior infarction was about equal.

Treatment consisted of prolonged bed rest, low calorie diet, morphine, mercurial diuretics, oxygen for dyspnea and cyanosis, and venesection if pulmonary edema was present. Digitalis and quinidine were considered unnecessary and even harmful.

REFERENCES

1. Master, A. M.: P-Wave Changes in Acute Coronary Artery Occlusion, Am. Heart J. 8: 462, 1933.
2. Fishberg, A. M., Hitzig, W. M., and King, F. H.: Circulatory Dynamics in Myocardial Infarction, Arch. Int. Med. 54: 997, 1934.
3. Harrison, T. R.: Failure of the Circulation, Baltimore, 1935, Williams & Wilkins Company, p. 316, 328.
4. Hamman, L.: The Symptoms of Coronary Occlusion, Bull. Johns Hopkins Hosp. 38: 273, 1926.
5. Christian, H. A.: Cardiac Infarction (Coronary Thrombosis); An Easily Diagnosable Condition, Am. Heart J. 1: 129, 1926.
6. Levine, S. A.: Coronary Thrombosis—Its Various Clinical Features, Medicine 8: 245, 1929.
7. Scott, J. W., and Harvey, J.: Myocardial Damage in Coronary Occlusion, South. M. J. 20: 510, 1927.
8. Hope, J.: A Treatise on the Disease of the Heart and Great Vessels, London, 1932, William Kidd, p. 196, 205, 346, 352.
9. Welch, W. H.: Zur Pathologie des Lungenodems, Virch. Arch. 72: 375, 1878.
10. Fraentzel, O.: Verlesungen über die Krankheiten des Herzens. 1. Die Idiopathischen Herzvergrasserungen, Berlin, 1889, August Hirschwald, p. 53.
11. Lian, C.: Le Syndrome d'insuffisance ventriculaire gauche, Presse méd. 18: 49, 1910.
12. Wasserman, S.: Neue Klinische Gesichtspunkte zur Lehre vom Asthma Cardiale, Berlin and Vienna, 1926, Urban & Schwarzenberg.
13. Wenkebach, K. F.: Herz und Kreislaufinsuffizienz, Dresden and Leipzig, 1931, Theodor Steinkopf, p. 6.
14. Hirschfelder, A. D.: Diseases of the Heart and Aorta, ed. 3, Philadelphia, 1918, J. B. Lippincott Company, p. 216.
15. Robb, G. P., and Weiss, S.: The Velocity of Pulmonary and Peripheral Venous Blood Flow and Related Aspects of the Circulation in Cardiovascular Disease and Their Relation to Clinical Types of Circulatory Failure, Am. Heart J. 9: 742, 1934.
16. White, P. D., and McGinn, S.: The Importance of the Clinical Recognition of Weakness and Failure of the Left Ventricle Without Failure of the Right Ventricle, Tr. A. Am. Physicians 48: 104, 1933.
17. Fishberg, A. M.: Some Cardinal Circulatory Syndromes, Am. Heart J. 7: 279, 1932.
18. Hutchinson, H.: On the Capacity of the Lungs and on the Respiratory Functions, with a View of Establishing a Precise and Easy Method of Detecting Disease by the Spirometer, Medico-Chir. Trans. London 29: 137, 1846.
19. Peabody, F. M., Wentworth, J. A., and Barker, B. L.: The Basal Metabolism and Minute Volume of Respiration in Patients with Cardiac Disease, Arch. Int. Med. 20: 468, 1917.
20. Pratt, J. H.: Long Continued Observations on the Vital Capacity in Health and Disease, Am. J. M. Sc. 164: 819, 1922.
21. Blumgart, H. L.: The Velocity of Blood Flow in Health and Disease: Velocity of Blood Flow in Man and Its Relation to Other Measurements of the Circulation, Medicine 10: 1, 1931.
22. Winternitz, M., Deutsch, J., and Brüll, Z.: Eine klinische brauchbare Bestimmungsmethode der Blutumlaufszeit mittels. Decholininjektion, Med. klin. 27: 986, 1931.
23. Fishberg, A. M., Hitzig, W. M., and King, F. H.: Measurement of the Circulation Time With Saccharin, Proc. Soc. Exper. Biol. & Med. 30: 651, 1933.
24. Hitzig, W. M.: The Measurement of Circulation Time from Antecubital Veins to Pulmonary Capillaries, Proc. Soc. Exper. Biol. & Med. 31: 935, 1934.
25. Miller, H. R.: The Velocity of Blood Flow in Part of the Pulmonary Circulation, Proc. Soc. Exper. Biol. & Med. 31: 942, 1934.
26. Clark, A.: A Study of the Diagnostic and Prognostic Significance of Venous Pressure Observations in Cardiac Disease, Arch. Int. Med. 16: 587, 1915.
27. Eyster, J. A. E.: The Clinical Aspects of Venous Pressure, New York, 1929, The Macmillan Company.
28. Taylor, F. A., Thomas, A. B., and Schleiter, H. C.: Direct Method for Estimation of Venous Blood Pressure, Proc. Soc. Exper. Biol. & Med. 27: 867, 1930.

29. Hitzig, W. M., King, F. H., and Fishberg, A. M.: Circulation Time in Failure of the Left Side of the Heart, Arch. Int. Med. 55: 112, 1935.
30. Blumgart, H. L., and Weiss, S.: Clinical Studies on Velocity of Blood Flow: XI. Pulmonary Circulation Time, the Minute Volume Flow Through the Lungs and the Quantity of Blood in the Lungs, J. Clin. Investigation 6: 103, 1928.
31. Ernstene, A. C.: Observations on Coronary Thrombosis, Am. J. M. Sc. 178: 383, 1928.
32. Evans, C. L., and Matsuoka, Y.: The Effect of Various Mechanical Conditions on the Gaseous Metabolism and Efficiency of the Mammalian Heart, J. Physiol. 49: 378, 1915.
33. Starling, E. H., and Visscher, M. B.: The Regulation of the Energy Output of the Heart, J. Physiol. 62: 243, 1927.
34. Harrison, T. R.: See Harrison,[3] p. 260.
35. Bainbridge, T. A.: Influence of Venous Filling Upon the Rate of the Heart, J. Physiol. 50: 65, 1915.
36. Bramwell, C.: Gallop Rhythm, Quart. J. Med. 4: 149, 1935.
37. Coombs, C. F.: Prognosis in Coronary Thrombosis, Bristol Med.-Chir. J. 49: 277, 1932.
38. Parsonnet, A. E., and Hyman, A. S.: Heart Sound Failure: A Phonocardiographic Study of This Phenomenon in Acute Coronary Occlusion, J. A. M. A. 96: 1124, 1931.
39. Wolferth, C. C., and Margolies, A.: Gallop Rhythm and the Physiological Third Heart Sound: I. Characteristics of the Sounds, Classification, Comparative Incidence of the Various Types and the Differential Diagnosis, Am. Heart J. 8: 441, 1933.
40. Holt, E.: Gallop Rhythm, Am. Heart J. 2: 453, 1927.
41. White, P. D.: The Clinical Significance of Gallop Rhythm, Arch. Int. Med. 41: 1, 1928.
42. Thompson, W. P., and Levine, S. A.: Diastolic Gallop Rhythm. A Note on Certain Factors Influencing Prognosis, Am. Heart J. 11: 129, 1936.
43. Master, A. M., Jaffe, H. L., and Dack, S.: A Study of 150 Cases of Coronary Thrombosis Treated with Low Calorie Diet. Discussion, Am. Heart J. 10: 1119, 1935.
44. Campbell, J. S.: Stereoscopic Radiography of the Coronary System, Quart. J. Med. 22: 247, 1929.
45. Kugel, M. A.: Anatomical Studies on the Coronary Arteries and Their Branches. Arteria Anastomotica Auricularis Magna, Am. Heart J. 3: 260, 1928.
46. Calhoun, J. A., Cullen, G. E., Harrison, T. R., Wilkens, W. E., and Tims, M. M.: Studies in Congestive Heart Failure: XIV. Orthopnea: Its Relation to Ventilation, Vital Capacity, Oxygen Saturation and Acid-Base Condition of Arterial and Jugular Blood, J. Clin. Investigation 10: 833, 1931.
47. Lewis, T.: Remarks on Early Signs of Cardiac Failure of Congestive Type, Brit. M. J. 1: 849, 1930.
48. Christie, C. D., and Beams, A. J.: The Estimation of Normal Vital Capacity With Especial Reference to the Effect of Posture, Arch. Int. Med. 30: 34, 1922.
49. Christie, C. D., and Beams, A. J.: Orthopnea, Arch. Int. Med. 31: 85, 1923.
50. Kahn, M. H.: Cardiac Asthma, Am. Heart J. 2: 424, 1927.
51. Hess, L.: Coronarinfarkt und Lungenodem, Deutsches Arch. f. klin. Med. 173: 283, 1932.
52. Libman, E.: The Importance of Blood Examinations in the Recognition of Thrombosis of the Coronary Arteries and Its Sequelae, Am. Heart J. 1: 121, 1925.
53. Herrick, J. B.: The Coronary Artery in Health and Disease, Am. Heart J. 6: 589, 1931.
54. Cohn, A. E., and Steele, J. M.: Unexplained Fever in Heart Failure, J. Clin. Investigation 13: 853, 1934.
55. Goodrich, B. S., and Smith, F. J.: The Nonfilament Leucocyte Count After Coronary Artery Occlusion, Am. Heart J. 11: 581, 1936.
56. Averbuck, S. H.: Heart Failure in Hypertension, Am. Heart J. 11: 99, 1936.
57. White, P. D.: A Note on the Common Occurrence of Serious Involvement of the Heart in Hypertension, New England J. Med. 214: 719, 1936.
58. Patterson, S. W., Piper, H., and Starling, E. H.: The Regulation of the Heart Beat, J. Physiol. 48: 465, 1914.
59. Nathanson, M. H.: Disease of the Coronary Arteries, Am. J. M. Sc. 120: 240, 1925.

60. Stewart, H. J., and Cohn, A. E.: Studies on the Effect of the Action of Digitalis on the Output of Blood from the Heart: III. Part I. The Effect on the Output in Normal Human Hearts. Part 2. The Effect on the Output of Hearts in Heart Failure with Congestion in Human Beings, J. Clin. Investigation 11: 917, 1932.
61. Nemet, G., and Gross, H.: The Interrelationship of Arteriosclerotic Heart Disease and Chronic Congestive Failure, AM. HEART J. 10: 643, 1935.
62. Harrison, T. R.: See Harrison,[3] p. 78.
63. Hemingway, A., and Fee, A. R.: Relationship of the Volume of the Heart and Its Oxygen Usage, J. Physiol. 63: 299, 1927.
64. Master, A. M., Jaffe, H. L., and Dack, S.: The Treatment and the Immediate Prognosis of Coronary Artery Thrombosis (267 Attacks), AM. HEART J. 12: 549, 1936.
65. Conner, L. A., and Holt, E.: The Subsequent Course and Prognosis in Coronary Thrombosis: Analysis of 287 Cases, AM. HEART J. 5: 705, 1930.
66. Saphir, O., Priest, W. S., Hamburger, W. W., and Katz, L. N.: Coronary Arteriosclerosis, Coronary Thrombosis and Resulting Myocardial Changes; Evaluation of Their Respective Clinical Pictures Including Electrocardiographic Records Based on Anatomical Findings, AM. HEART J. 10: 567, 762, 1935.
67. Moritz, A. R., and Beck, C. S.: The Production of a Collateral Circulation to the Heart: Pathological Anatomical Study, AM. HEART J. 10: 874, 1935.
68. Libman, E.: Some Observations on Thrombosis of the Coronary Arteries, Tr. A. Am. Physicians 34: 138, 1919.
69. Pletnew, D. D.: Zur Frage der Intravitalen Differentialdiagnose der rechten und der linken Coronararterienthrombose des Herzens, Ztschr. f. klin. Med. 102: 295, 1925.
70. Kohan, B. A., and Bunin, E. I.: Zur Frage über die Differentialdiagnose der Thrombose der rechten und linken Kranzarterie des Herzens am Lebenden, Ztschr. f. Kreislaufforsch. 20: 199, 1928.
71. Barnes, A. R., and Ball, R. G.: The Incidence and Situation of Myocardial Infarction in One Thousand Consecutive Postmortem Examinations, Am. J. M. Sc. 183: 215, 1932.
72. Libman, E.: Discussion, Tr. A. Am. Physicians 44: 38, 1929; 45: 153, 1930.
73. Vander Veer, J. B., and Brown, L. E., Jr.: The Diagnosis and Prognosis of Coronary Occlusion; the Electrocardiogram as an Aid, Pennsylvania M. J. 39: 303, 1936.
74. Sprague, H. B., and Orgain, E. S.: Electrocardiographic Study of Cases of Coronary Occlusion Proved at Autopsy at Massachusetts General Hospital 1914 to 1934, New England J. Med. 212: 903, 1935.
75. Luten, D.: Contributory Factors in Coronary Occlusion, AM. HEART J. 7: 36, 1931.
76. Master, A. M., Jaffe, H. L., and Dack, S.: The Differentiation of Pulmonary and Cardiac Disease, AM. HEART J. 10: 833, 1935.
77. Master, A. M., Jaffe, H. L., and Dack, S.: Undernutrition in the Treatment of Coronary Artery Disease (Particularly Thrombosis). Effect on the Basal Metabolism and Circulation, J. Clin. Investigation 15: 353, 1936.
78. Friedman, B., Resnick, H., Jr., Calhoun, J. A., and Harrison, T. R.: Effect of Diuretics on the Cardiac Output of Patients with Congestive Heart Failure, Arch. Int. Med. 56: 341, 1935.
79. Levine, S. A., and Fulton, M. N.: The Effect of Quinidine Sulphate on Ventricular Tachycardia; Clinical Observations, J. A. M. A. 92: 1162, 1929.

TRIGONOIDATION OF THE SEMILUNAR VALVES AND ITS RELATIONSHIP TO CERTAIN BASAL SYSTOLIC MURMURS

DONALD R. CHISHOLM, M.D., C.M.
HONOLULU, T. H.

ALTHOUGH Laennec first published the results of his experiments with the stethoscope as long ago as 1819, and although the great clinicians of at least the latter half of the nineteenth century were fully aware of the necessity of distinguishing between organic and so-called functional heart murmurs, yet, even today, there are physicians to whom the term "functional" murmur represents an entity of suspicious vagueness. Sir James MacKenzie[1] accounted for this state of mind several decades ago when he wrote the following in his famous monograph on diseases of the heart: "As a general rule, the more obtrusive a symptom is, the more it impresses the mind of the observer, and much more importance is attached to it than to less conspicuous phenomena. This is particularly noticeable in signs which are detected by auscultation. To the human mind, sounds arising from obscure causes have always been a source of mystery, and the human imagination, when dealing with the mysterious, invariably associates it with something malign." The physician is perhaps justified in adopting this method of rationalization because of his inherent caution against diagnosing a harmless condition when a serious one may really be present. However, it is equally as serious, if not more so, to diagnose an organic condition when the cause of the misleading evidence is of trifling importance.

In order to eradicate the poor rationalization and the occasional tragic diagnoses sometimes prompted by the discovery of certain systolic murmurs, it is necessary to remove the obscurity surrounding the etiology of these sounds. This can be done only by ascribing the murmur to a definite and plausible physical origin. It is simple logic that such a definite physical phenomenon as a murmur must have a cause that is equally definite whether the murmur is organic or "functional." If the cause can be shown to be physiological, the harmlessness of the murmur is evident and can be readily explained to the patient; if it can be shown to be variable, the variability of the murmur can be explained; if it can be shown to be something other than intrinsic valvular or myocardial disease, a clearer concept of the actually responsible factors is stimulated. Finally, if the cause is definitely known, the physician's self-assurance and diagnostic discrimination are increased.

The classification of obscure systolic murmurs has always been admittedly unsatisfactory. Such terms as "physiological," "accidental," "functional," "important," and "unimportant," have only added to the general vagueness and have often been wrong in their interpretation. Thus the murmur that accompanies hypertension or syphilitic aortitis with normal aortic valves may be termed "functional" as far as the valves themselves are concerned, but the term does not take into account the serious organic disease that makes this "functional" murmur possible. Again, the common pulmonary systolic "functional" murmurs may be harmlessly physiological, or they may represent serious organic lung disease. An attempt will not be made here to classify these murmurs. Suffice it to say that the murmurs to be considered are those which occur in the presence of valves which, if they could be examined, would be pronounced intrinsically perfectly normal. The problem to be settled is how such valves can give rise to murmurs and what the conditions are which enable them to do so. The study of this problem may be initiated by considering the systolic murmurs produced at the pulmonary orifice in the presence of intrinsically normal valves.

Systolic murmurs are extremely common over the pulmonary area —Balfour's area of auscultatory romance—yet it is known that structural disease of the pulmonary valves is very rare. So common is this murmur that in the great majority of cases, it must of necessity be regarded as a normal physiological phenomenon. In a smaller group of cases it is due to the effects of excessive metabolic and nervous activity on the heart, and in a few cases it is due to extracardial disease, especially of the lungs. Robinson[2] states: "The soft systolic murmur so frequently heard at the base in healthy individuals, especially during youth, offers an interesting field for speculation. . . . . The pulmonary orifice seems to be especially the one at which vibrations are apt to be set up by the passage of the blood when no structural change in the tissues has taken place."

When we examine the various conditions in which a nonorganic pulmonary systolic murmur may be found, we find that they are all associated with a common factor, viz., overfilling or distention of the pulmonary artery. The occurrence of such a common factor suggests that it is this state of dilatation which is fundamentally responsible for the production of the pulmonary systolic murmur associated with normal valves, and it is believed that the true physical explanation for the murmur can be and has been satisfactorily demonstrated on this basis. Years ago, Austin Flint suggested that the pulmonary systolic murmur was due to a dilatation of the conus arteriosus, but, so far as the writer knows, a physical explanation as to why such dilatation should cause a murmur has never been given.

Let us here briefly note a few anatomical facts in regard to the conus and pulmonary artery. It is a commonly held idea that the conus is separated from the artery itself by a junctional ring of fibrous tissue which supposedly is fairly efficient in preventing dilatation of the pulmonary orifice. If one will take the trouble to look for this ring both macroscopically and microscopically, it will be found to be a greatly overrated and practically nonexistent structure in the human heart. In other words, for all practical purposes, there is no such thing as a pulmonary "ring."

The ends of the free margins of each semilunar valve pocket are attached to the wall of the pulmonary artery itself at some distance above the junction of artery and conus. They are not attached to a fibrous ring. The attachment of the free margins to the wall of the artery is effected through the intermediation of three fibrous nodules, each of which serves as a common point of attachment for the adjacent ends of two cusp margins. Examination will disclose the fact that these fibrous nodules do not stretch when the artery itself is stretched or dilated, and that therefore the adjacent ends of the cusp margins do not pull away from each other when the vessel dilates. The deeper portions of each valve pocket are attached to the endocardium covering the conus.

The pulmonary artery itself is quite a soft, relatively thin, very easily dilatated, and very easily compressed structure. If one places the two index fingers inside the pulmonary orifice and attempts to dilate the latter, it will be found that the first real resistance to stretching is offered by the inelastic valve margins themselves, not by any fibrous ring. If a longitudinal section is made in the pulmonary artery and conus, exactly through one of the common nodules, and the region of the cusps is then transversely stretched, it will be found that stretching is limited by the relatively inelastic valve margins. If each cusp margin is now snipped with the scissors, it will be found that the artery is dilatable for a considerable degree beyond the point at which it was previously limited by the valve edges. With these anatomical facts in mind, we may now consider some of the physical changes which occur at the pulmonary orifice during systole of the ventricles.

If a circle is drawn, say of 1 inch in diameter, or approximately the average diastolic diameter of the pulmonary orifice, and it is divided by three radii into three equal sections of 120 degrees, the diagram may be taken to represent the pulmonary orifice with its valve cusps closed. Now it is a fact that for small circles of this size —and for even much larger ones—the sum of any two of the radii drawn is almost exactly equal in length to the 120 degree segment of circle which they subtend. Thus in the circle given the sum of any two radii is equal to 1 inch, while the segment of the circle which they subtend measures 1.04 inches. It follows from this that, if the valve

opens while the pulmonary artery remains the same size, then each free cusp margin, which is equal to the sum of two radii, will fold back until in almost exact apposition with the wall of the artery. In this position the cusp margin will offer no resistance to the onrush of blood. As a matter of fact, the free margin of each valve cusp is somewhat more than equal to the sum of two radii because of the fact that it extends slightly downward as well as inward toward the central point of the lumen from its mural attachments. This fact enables the margin of the cusp actually to fit back easily against the wall of the undilated artery.

An entirely different relationship results if the pulmonary artery is dilated or becomes dilated at the moment the valve opens, and it is surprising mathematically how little dilatation is necessary to produce this change in relationship. We have seen above that the first appreciable obstruction to wide dilatation of the pulmonary orifice is produced by the unyielding margins of the valve cusps themselves, that the artery itself is dilatable for a considerable distance beyond this

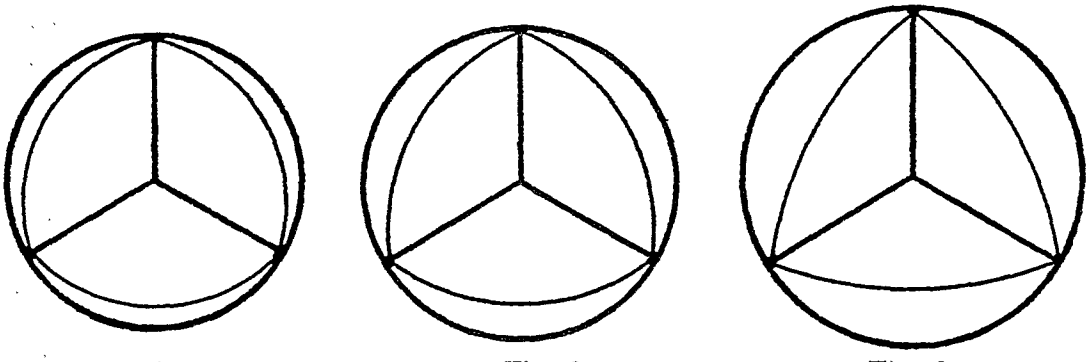

Fig. 1. Fig. 2. Fig. 3.

Figs. 1, 2, and 3.—Successive degrees of dilatation and trigonoidation.

point of resistance, and that the adjacent ends of the cusp margins are attached to common fibrous nodules which do not themselves stretch. Because of these facts, as the artery progressively dilates, the cusp margins fit less and less snugly against the artery wall during systole, as shown successively in Figs. 1, 2, and 3. At a point of maximum dilatation the edges of the cusps would tend to form a triangle within the circle of the artery. It is unlikely that such a true triangle is ever formed, for the onrushing column of blood would cause the margins to bow backward to some degree. Even in well-marked dilatation, Fig. 3 would be a better representation of the relationships than full triangulation.

This tendency of the cusp margins to subtend rather than to fit snugly into each 120 degrees of the pulmonary artery as the latter dilates may be conveniently referred to as "trigonoidation" of the semilunar valves, since the margins arch between their points of attachment to the vessel wall and form the boundaries of a figure which is known in plane geometry as a trigonoid. That such trigonoidation

actually occurs was shown by the following experiment: A heart was obtained at the autopsy of a patient who had died of pulmonary tuberculosis. The inferior vena cava was plugged with a cork and tightly tied around the latter. A cork through which glass tubing passed was similarly used to plug the superior vena cava. A clean, 150 c.c. Erlenmeyer flask was tied by its neck into the pulmonary artery close to the bifurcation. Air was now pumped into the right heart through the glass tubing in the superior vena cava. On looking through the bottom of the Erlenmeyer flask the pulmonary valve margins were seen to become completely triangulated as the conus and artery dilated. Variations in the tension of the valve margins were obviously produced when the right auricle was squeezed and then relaxed, thus varying the pressure and degree of dilatation in the

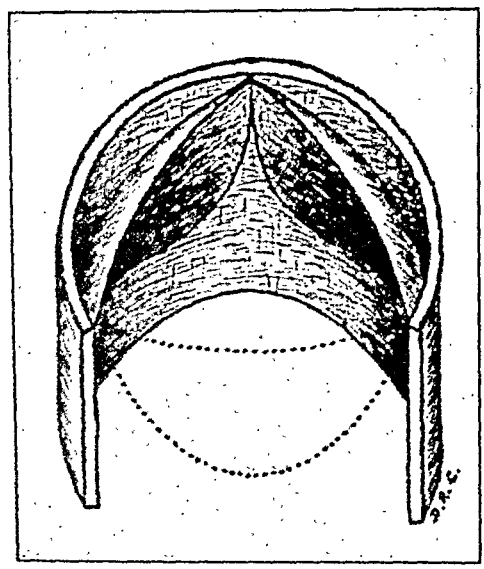

Fig. 4.—Longitudinal section of pulmonary artery through valves, showing trigonoidation.

conus and pulmonary artery. The contrast between the triangulated valve margins and the stretched circumference of the pulmonary artery was striking, there being well-marked sinuses behind the cusps. From the bottom of the Erlenmeyer flask the appearance of the triangulated cusps might be best described as a three-sided funnel within the lumen of the artery.

Trigonoidation of the semilunar valve margins results in ideal conditions for the production of a systolic murmur. It transforms the pulmonary orifice into a structure closely resembling the larynx with its vocal cords, except that here we have three cords instead of two. Figure 4 may be taken to represent a longitudinal section of a pulmonary orifice showing trigonoidation of the valve margins. The taut edges of the somewhat inverted cusps will obviously offer frictional resistance to the moving column of blood and will therefore be

set into vibration. Such a mechanism is so ideal physically for the production of a systolic murmur that, on the basis of trigonoidation, it is no wonder the pulmonary murmur is so common and can be so easily produced. The pulmonary artery dilates considerably, of course, with each systolic stroke of the right ventricle, and the accompanying moderate trigonoidation of the semilunar valves, while perhaps not producing an audible murmur, has an important physiological function. It results in failure of complete obliteration of the valve pocket, and consequently the recoil of the artery following systole immediately distends the valve pockets with blood and thus closes the valve orifice, allowing little or no reflux.

It is to be noted that, while on the average each pulmonary valve cusp occupies 120 degrees of circumference of the pulmonary artery, sometimes one of the cusps is a little larger than the others. This favors the production of a murmur, for any cusp occupying more than 120 degrees, provided that its margin does not exceed the sum

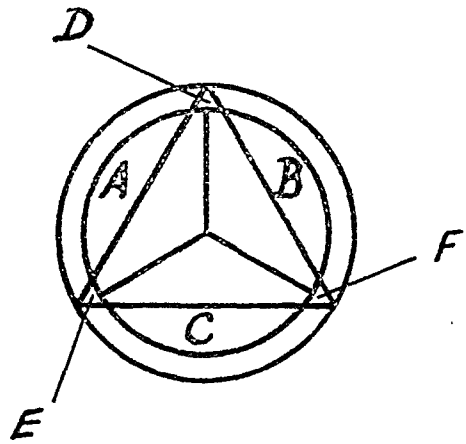

Fig. 5.—Diagram showing the relatively slight dilatation theoretically needed to produce full triangulation of the cusp margins. Each side of the triangle is equal to the sum of two radii of the smaller circle. Actually, more dilatation than here shown is needed to produce full triangulation.

of two radii, will have increased difficulty in folding its margin back to the vessel wall. This was well shown in the above experiment in which one of the cusps occupied slightly more than 120 degrees. Such a relationship accounts for the systolic murmur associated with congenitally bicuspid valves, for in this condition each cusp margin occupies a diameter and subtends 180 degrees.

Figure 5 shows what a relatively slight enlargement in the diameter of a small circle is needed to produce a complete triangulation of the radii. Thus the inner circle, 1 inch in diameter, with the three radii, represents the undilated pulmonary artery with the valves closed, while the outer circle, only about 0.2 inch larger in diameter, shows the valve margins fully triangulated by the moderate dilatation. Actually, more dilatation than this is required to produce triangulation since the cusp margins are slightly longer than two radii.

Figure 5 also demonstrates an important and seemingly paradoxical point, namely, as the pulmonary artery dilates, the area bounded by the cusp margins actually becomes smaller. Thus the combined area of the subtended segments *A*, *B*, and *C* of the undilated artery is lost during dilatation, while the tiny triangles *D*, *E*, and *F* combined represent the area gained. Obviously a great deal more area is lost than is gained. In Fig. 5 full triangulation of the cusp margins reduces the area bounded by these margins by 36.3 per cent. (Area of triangle subtracted from area of smaller circle and result expressed as percentage of latter.) It is not to be understood that this figure represents 36.3 per cent of normal, because, under normal conditions, there is probably some trigonoidation of the valves and hence the percentage loss of area in the above example is no doubt exaggerated. The same relationship would hold for trigonoidation as for triangulation, except that in the case of the former the loss of area is not so great. Probably it is never sufficient to have an obstructive influence. This diminution in cross-sectional area does explain one point, however, viz., the greater the dilatation the more easily is a murmur produced. Nevertheless, no matter what the degree of dilatation, if it is due to back pressure and this has been sufficient to lead to tricuspid incompetence, a pulmonary systolic murmur may not occur.

In general there are three groups of conditions in which a pulmonary systolic murmur may occur in association with structurally normal valves. These groups are as follows:

A. Conditions Which Cause Dilatation of the Pulmonary Artery by Increasing the Peripheral Resistance in the Pulmonary Circulation.—Physiological examples in this group are the pulmonary systolic murmurs which may occur during full expiration or during the Valsalva experiment (attempted forced expiration with the glottis closed). Examples of a pathological nature may be mitral stenosis, emphysema, extensive pulmonary fibrosis, and Ayerza's disease. In some cases of mitral stenosis the dilatation of the pulmonary artery may be so great that the semilunar valves become incompetent. Usually before this time the right ventricle has become pathologically dilated and has lost much of its systolic force, while the tricuspid valve has become incompetent. Because of these factors there may be no trigonoidation murmur.

B. Conditions Which Result in Stenosis and Therefore Proximal Dilatation of the Pulmonary Artery by Producing Kinking, External Pressure, or Traction Distortion of the Vessel or Its Main Divisions.—Under this heading may be placed the pulmonary systolic murmurs which not infrequently accompany pregnancy, obesity, ascites, and other forms of abdominal distention; occasionally extensive unilateral pleural effusions or pneumothorax; pulmonary fibrosis with mediastinal displacement; mediastinal tumors; extensive thoracoplasty, etc.

Of course, the stenosis itself may be responsible for a systolic murmur in these cases. Such a murmur is usually very loud and harsh as compared with a trigonoidation murmur.

C. Conditions Which Result in Increased Venous Return and Therefore Increased Stroke Volume and Increased Systolic Force of the Right Ventricle.—This is the most interesting group, and it accounts for the majority of trigonoidation murmurs. Obviously anything which increases the stroke volume and systolic force of the ventricles should favor the production of this type of murmur.

The common physiological example in this group is exercise, and the mechanism by which it causes an increased venous return is too well known to require discussion.

Arteriovenous aneurysm may be taken as an example of a purely pathological condition causing increased venous return.

Fever is another condition commonly associated with a pulmonary systolic murmur. In fever the basal metabolic rate increases, and there is need for increased elimination of heat. This is provided for by an increased minute output of the heart and a dilatation of the peripheral vessels. The basal metabolic rate increases by about 7 per cent for each rise of 1° F. However, Samson Wright[3] states that the main need increasing the cardiac output is probably not the change in metabolic activity, which is small, but the need for temperature regulation, and that the increase in venous return needed to maintain the raised minute output is presumably brought about by raised capillary and venous pressure resulting from the cutaneous arteriolar dilatation.

It follows from what has just been said that any condition which results in dilatation of the cutaneous arterioles and the necessity for increased heat elimination may result in the development of a pulmonary systolic murmur. Thus Norris and Landis[4] quote F. Howell to the effect that the vascular dilatation induced by prolonged sweat baths is of itself sufficient to cause the appearance of murmurs in the majority of cases.

In thyrotoxicosis there is a marked increase in the minute output of the heart and a corresponding increase in the venous return. The factor of venous return thus explains the basal systolic murmur of thyrotoxicosis.

Conditions which result in anemic and anoxic anoxemia result in an increase in the minute output and venous return as a compensating mechanism and may be accompanied by trigonoidation murmurs. There is probably no such thing as a "hemic" murmur per se, i.e., a murmur due to an alteration in the physical state of the blood itself.

There are two other common conditions which may be classified in this group, namely, excitement and the effort syndrome. These are often accompanied by a basal systolic murmur. They differ somewhat

from the other examples just given in that, in addition to an increased venous return, the systolic force is increased by heightened sympathetic tone. According to Samson Wright, emotional states produce varying degrees of elevation of the cardiac output. DuBois[5] quotes Grollman as having shown that psychic disturbances affect the cardiac output even more than the oxygen consumption. Grollman found in testing medical students that anger was associated with a rise of about 23 per cent in the cardiac output per minute but that worry over their standing in laboratory work caused somewhat smaller changes. Other work in psychoneurotic states has shown that these may be accompanied by a marked rise in cardiac output and therefore in venous return. It is quite possible that accelerated venous return in these cases is largely due to increased muscular tension.

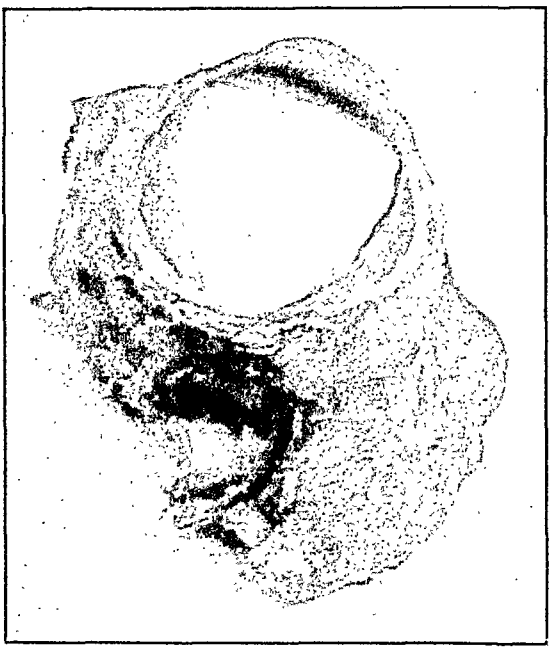

Fig. 6.—Photograph of the pulmonary orifice of a heart which was fixed in a state of distention. In this preparation the valves are pushed back as far as they will go by a plug of cotton in the conus. The photograph demonstrates clearly what is meant by the term "trigonoidation." A point brought out in the preparation of such a specimen is that the sinuses behind the valves are the most distensible portions of the pulmonary artery, thus favoring the production of trigonoidation.

An important subject remaining for consideration is that of systolic murmurs arising at the aortic area in the presence of structurally normal valves. It is of course often difficult to say whether a certain basal systolic murmur originates at the pulmonary or the aortic orifice, because of transmission of the murmur. It is known, however, that pulmonary systolic murmurs are much more common as a whole than aortic systolic murmurs. Since it is felt that many aortic systolic murmurs, like most pulmonary systolic murmurs, are due to trigonoidation of the valve margins, it becomes necessary to explain why the aortic murmurs are so much less common. If one examines

the aorta and compares its qualities with those of the pulmonary artery, it will be noted that the former is thicker, offers considerably more resistance to distention, and proportionately has less maximal dilatability than the latter. The pulmonary artery, being a short structure of relatively small volume, requires considerable dilatability in order to accommodate the stroke volume of the right ventricle. The aorta, on the other hand, has great length and accommodates a large stroke volume with a relatively slight dilatation at any one point. If one will note the systolic expansion of the great vessels in the exposed heart of the dog, he will immediately see this point. The relative dilatabilities of the two great vessels can also be strikingly shown by cutting rings from them and stretching them with the index fingers. That trigonoidation murmurs are less common at the aortic than at the pulmonary orifice is due, then, to the relatively small dilatation of the aorta with each stroke volume of the left ventricle. At the pulmonary orifice most trigonoidation murmurs are due to physiological factors brought into play by normal or mildly pathological states such as exercise, excitement, fever, anemia, etc. These conditions are seldom sufficient to produce trigonoidation murmurs at the aortic orifice. Apart from dynamic dilatation of the aorta, most conditions which cause an aortic trigonoidation murmur are definitely, if not seriously, pathological, viz., hypertension, syphilitic aortitis, aneurysm of the ascending aorta, atherosclerosis, senile ectasia of the aorta, and coarctation. These conditions per se result in enough dilatation of the aorta that the addition of each systolic thrust is sufficient to produce trigonoidation and a murmur.

SUMMARY

Certain anatomical features of the great vessels and their valves are discussed.

Attention is drawn to the fact that basal systolic murmurs associated with structurally normal valves have a common factor in that they are connected with conditions which cause dilatation of the great vessels.

The association of systolic murmurs with dilatation of the great vessels is explained on the basis of physical changes in the relationship of the valve cusps to the lumen of the vessel. Experimental evidence has been given to corroborate this. The particular relationship of the valve cusps responsible for the murmur has been termed "trigonoidation."

An explanatory discussion is given of why various conditions such as exercise, excitement, anemia, thyrotoxicosis, etc., are associated with basal systolic murmurs.

The cause of the relative frequencies of pulmonary and aortic systolic murmurs is discussed and remarks made on their relative significance.

REFERENCES

1. MacKenzie, Sir James: Diseases of the Heart, ed. 3, London, 1921, Oxford Medical Publications, p. 322.
2. Robinson, G. Canby: Nelson's Loose-Leaf Medicine, Vol. 4, page 502.
3. Wright, Samson: Applied Physiology, ed. 5, London, 1935, Oxford Medical Publications, pp. 316, 388, 468.
4. Norris, G. W., and Landis, H. R. M.: Diseases of the Chest, ed. 3, 1924, W. B. Saunders Co., p. 272.
5. DuBois, Eugene: Basal Metabolism in Health and Disease, ed. 3, Philadelphia, 1936, Lea and Febiger, Chapter XX.

Department of Clinical Reports

THROMBOANGIITIS OBLITERANS IN WOMEN

Report of a Case*

Theodore R. Van Dellen, M.D., and Irving S. Wright, M.D.
New York, N. Y.

THROMBOANGIITIS obliterans is rare in women. Twenty-one cases have thus far been reported.[1-10] Herrell and Allen,[10] in a recent review, discuss the criteria for diagnosis in each of these patients. The following brief report is published to add to our meager knowledge of this condition as it occurs in women.

L. V., a Russian Jewess, aged forty-six years, was admitted to the Vascular Clinic of the New York Post-Graduate Medical School and Hospital on Nov. 27, 1934. Her history dated back one year, at which time she had exposed her bare feet to the floor of a cold room. Following this exposure, she noticed a burning sensation in the distal half of her left foot. The condition progressed, so that on admission she complained of a constant burning pain over the sole and medial aspect of her left foot. Moderate relief was afforded by heat, but the condition was greatly aggravated by cold. In the four months prior to admission, walking one block had produced an aching pain in her left foot and ankle, relieved only after a few minutes' rest. Two small ulcers had made their appearance beneath and between the last two toes of her left foot. Both of these ulcers were of four weeks' duration. One week prior to admission, she had noted a dull pain in her left hand and forearm, somewhat similar to the pain in the sole of her foot, but not so severe.

Her past history was essentially negative. In 1930 the fifth finger of her right hand had been amputated because of osteomyelitis associated with an acute infection. She had smoked on an average of eight cigarets a day since she was eight years of age. Rye bread was included in her daily diet, and she denied the use of alcohol.

Physical examination revealed a well-nourished and well-developed female. She was 59 inches (149.8 cm.) tall and 160 pounds (72.7 kg.) in weight. The blood pressure in millimeters of mercury was 130 systolic and 90 diastolic. General examination was essentially negative.

Examination of her extremities revealed a marked rubor of both feet, most prominent over the toes and inner aspect of her left foot. Pallor was present on elevation. The nail of the first toe of the left foot was greatly hypertrophied. Two small, moist ulcers were present under the toes of the left foot. The larger ulcer was located at the base of the fifth toe. Both feet were moderately cold. Examination of the extremities for pulsations revealed no pulsations in dorsalis pedis of either foot, nor in the posterior tibial or popliteal of the left leg. The right posterior tibial and popliteal were palpable. The radial and ulnar vessels of the left arm were not palpable. Both vessels could be felt in the right wrist. The oscillometric readings may be seen in Table I.

The routine complete blood count, blood sugar, urinalysis, and blood serology for syphilis were negative. The electrocardiogram was negative except for a rapid rate

*From the Vascular Clinic of the New York Post-Graduate Medical School and Hospital of Columbia University.

of 101. Roentgenograms of the lower extremities revealed no evidence of arteriosclerotic plaques. No abnormal changes were noted on examination of the eyes. Unfortunately, a Landis hot water immersion test was not performed on admission, but Table II shows the results of a test performed on Jan. 27, 1936. This would indicate the establishment of good collateral circulation, in view of the oscillometric readings, which were still as indicated in Table I.

TABLE I

OSCILLOMETRIC READINGS

	LEFT	RIGHT
Dorsali pedi (arch of foot)	0	0
Proximal to ankle	0	½° at 100 mm. Hg pressure
Distal to knee	1¾° at 100 mm. Hg pressure	2° at 100 mm. Hg pressure
Proximal to wrist	0	½° at 100 mm. Hg pressure

TABLE II

HOT WATER IMMERSION TEST*

TIME P.M.	RIGHT FOOT				LEFT FOOT				
	FIRST TOE	THIRD TOE	FIFTH TOE	DORSUM	FIRST TOE	THIRD TOE	FIFTH TOE	DORSUM	R. T.
1:00	Admitted to clinic for temperature stabilization								
2:00	32.0	32.6	32.5	33.3	28.9	30.1	29.2	30.3	26.6
2:29	31.1	32.0	31.3	32.5	30.6	28.9	28.9	31.3	19.1
	Arms submerged in water at 45° C.								
2:20	31.5	31.6	31.5	32.9	31.5	29.5	29.3	31.6	22.6
2:35	33.0	31.4	30.7	32.6	31.2	30.3	29.6	31.4	24.0
2:50	32.4	33.3	32.8	33.3	31.4	30.5	29.2	31.5	25.0
3:05	33.0	33.3	33.0	33.0	31.8	30.5	29.3	32.0	25.4

*Temperature readings in centigrade. Described by Landis.

Typhoid vaccine* was given intravenously, starting with a dose of 10 million and increasing the dosage gradually to 70 million. The dosage given produced a 2 to 3 degree rise in body temperature, without an initial chill. Both ulcers were completely healed after twenty-seven injections. Eleven additional injections were given, and the patient became symptom-free. During May, 1936, claudication and rest pain returned. Tissue extract 568,† 3 c.c., three times a week, was given intramuscularly, and after five injections the patient continued to have claudication, but no rest pain. Heart muscle extract,‡ 4 c.c., three times a week, was given intramuscularly, and, after nine injections, the patient was able to walk fifteen blocks without developing claudication. Twenty-six more injections were given, and the patient was discharged from the clinic. Since Sept. 12, 1936, the patient has been symptom-free.

DISCUSSION

We believe that we are justified in reporting this case with the diagnosis of thromboangiitis obliterans for the following reasons: (a) the patient is a Russian Jewess; (b) she was forty-five years of age at the

*Special typhoid vaccine (100,000,000 to 1 c.c.) supplied through the courtesy of Kirk Biological Laboratories, Bloomfield, N. J.

†Supplied through the kindness of Sharpe and Dohme.

‡Specially prepared and supplied through the kindness of Eli Lilly and Co.

onset of her symptoms; (c) there was no evidence of calcification to be seen in x-ray films of the affected extremities, taken for special study in that regard; (d) diabetes mellitus is not present; (e) she had smoked an average of eight cigarets a day from the age of eight years (thirty-seven years); (f) rye bread had been an important feature in her diet since infancy, much of which time was spent in Eastern Europe; (g) her pains were burning in character, and she had severe rest pains; (h) she also had claudication, as a residual symptom, after her ulcers healed; (i) her ulcers were deep, moist, located between the last two toes of the left foot and excruciatingly tender; (j) she had marked rubor on dependency and pallor on elevation; (k) there was widespread involvement of the peripheral arteries, as determined by absence of pulsations of the major arteries supplying both feet and the left hand; (l) there was prompt response to intravenous typhoid therapy, with healing of the ulcers, even though the patient was ambulatory.

REFERENCES

1. Buerger, Leo: The Circulatory Disturbances of the Extremities Including Gangrene, Vasomotor and Trophic Disorders, Philadelphia, 1924, W. B. Saunders Company.
2. Koyano, K.: A Clinical Study of 120 Cases of Thrombo-Angiitis Obliterans Among the Japanese, Acta scholae med. univ. imp. in Kioto 4: 489, 1921-1922.
3. Meleney, F. L., and Miller, G. G.: A Contribution to the Study of Thrombo-Angiitis Obliterans, Ann. Surg. 81: 976, 1925.
4. Telford, E. D., and Stopford, J. S. B.: Two Cases of Thrombo-Angiitis Obliterans in Women, Brit. Med. J. 1: 1140, 1927.
5. Dürck, Hermann: Die sogenannte "Thromboangiitis obliterans" im-Rahmen der Infektiöstoxischen Gefässentzündungen, Verhandl. d. deutsch. path. Gesellsch. 25: 272, 1930.
6. Trabaud, J., and Chaty, Choukat: Étude microscopique des lesions dans un cas de maladie de Leo Buerger chez une femme musulmane, Bull. et mém. Soc. méd. d. hôp. de Paris 47: 583, 1931.
7. Trabaud, L., and Mredden: Maladie de Leo Buerger chez une jeune fille musulmane, Bull. et mém. Soc. méd. d. hôp. de Paris 47: 579, 1931.
8. Horton, B. T., and Brown, G. E.: Thrombo-Angiitis Obliterans Among Women, Arch. Int. Med. 50: 884, 1932.
9. Silbert, Samuel: Thrombo-Angiitis Obliterans in Women: Report of Two Cases, Ann. Surg. 101: 324, 1935.
10. Herrell, W. E., and Allen, E. V.: Thrombo-Angiitis Obliterans in Women: Report of a Case, Am. Heart J. 12: 105, 1936.

Department of Reviews and Abstracts

Selected Abstracts

Krebs, A.: The State of the Heart Following the Introduction of Radioactive Substances Into the Organism. Ztschr. f. Kreislaufforsch. 28: 701, 1936.

The author measured the concentration of radioactive substances in various organs obtained post mortem. The material was obtained from five patients who had been exposed in various ways to these substances. The author found that the heart had retained relatively little of these substances as compared with the other organs. This fact was confirmed in animal experiments. Dilatation of the heart which was found in some of these patients is attributed chiefly to the pulmonary hypertension and fibrosis which these substances cause, although a direct action cannot be ruled out.

L. N. K.

Wezler, K., and Böger, A.: The Influence of the Musculature of the Blood Vessels on the Arterial Pressure Dome. Ztschr. f. Kreislaufforsch. 28: 759, 1936.

The methods used have been described previously by the authors. The observations were made on living subjects. It was found that the volume elasticity modulus curves of the elastic and muscular arteries differ in slope even in the same person. Changes in the tone of the smooth muscles of blood vessels alter the arterial pressure dome. The apparent length of the pressure dome increases with elevation in mean blood pressure but to different degrees depending on the tonus of the vascular muscles. Such tonus changes also modify the volume elasticity modulus of the pressure dome. The main significance of the smooth muscle in the wall of the aorta is its tendency to keep the apparent elasticity coefficient of the pressure dome constant when the pressure within it is varied 50 mm. Hg or more. The authors suggest that reflexes from the root of the aorta and carotid sinuses may act not only on the heart and peripheral vessels, but also on the smooth muscle of the aorta to help keep the arterial pressure dome constant.

L. N. K.

Clark, Eliot R., and Clark, Eleanor L.: Observations on Living Mammalian Lymphatic Capillaries: Their Relation to the Blood Vessels. Am. J. Anat. 60: 253, 1937.

The regeneration of lymphatic capillaries has been studied by observation in "round table" chambers inserted into the ears of living rabbits. It has been established that new lymphatic capillaries grow by a process of sprouting from preexisting endothelium and that they form an independent system of vessels.

In the process of the development of blood capillaries, clear perivascular spaces may persist. These spaces occasionally acquire a border of longitudinally arranged connective tissue fibers resembling definite channels. When the lymphatic capillaries invade the areas around the blood capillaries before the dense intravascular tissue has

been formed, they sometimes follow the course of the blood vessels but frequently grow at random in the gelatinous intravascular substance. When the intravascular connective tissue is present the lymphatic vessel usually advances contiguous to the artery or vein. When the contiguous blood vessel is a capillary or thin-walled vein, direct leakage of fluid from the blood stream to the lymphatic vessel may occur.

Following periods of inflammation, localized areas of widening are observed in the blood vessel which accompanies the lymphatic vessel. This enlargement is relatively greater and persists longer on the side next to the lymphatic. At the time of active blood flow, the bulges in the wall of the blood vessel indent the wall of the accompanying lymphatic, encroaching on its lumen, while with decreased pressure in the blood vessel the "aneurysm" is inverted and the wall of the lymphatic then protrudes into the vein. If the endothelium of the blood vessel is weakened, hemorrhages may occur at the bulging place. However, no fistula was observed in any of the preparations.

Because of the sluggishness of lymph flow in peripheral lymphatics, cells which entered a lymphatic from a neighboring blood vessel frequently remain for hours or days within its lumen before moving on. Phagocytosis of degenerated polymorphonuclear leucocytes and of erythrocytes by macrophages occasionally occurs inside the lumen of the lymphatic capillaries. In those instances in which newly formed arteries have acquired active contractility, the accompanying lymphatic is compressed when the artery dilates, and expands when the artery contracts.

E. A. H.

Brückner, G.: A Measure of Cardiac Function. Ztschr. f. Kreislaufforsch. 28: 721, 1936.

The author recorded the venous pulse optically simultaneously with the electrocardiogram and the heart tones. He determined congestion on the basis of alterations of the systolic collapse of the venous pulse. He concluded that the alterations of this part of the venous pulse give the earliest signs of congestive heart failure, and this makes venous pulse registration of value in congestive failure.

L. N. K.

Fischer, R.: Clinical Studies of the Jugular Venous Pulse. Ztschr. f. Kreislaufforsch. 28: 801, 1936.

Stasis in the neck veins below the level of the jugular vein enhances the volume pulsations of the jugular vein. When this stasis exceeds an optimum, the pulsations in the lower part of the neck decrease and disappear but are still noticeable in the upper part of the neck. A large venous pulsation on the left rather than the right side of the neck is a sign of congestive heart failure. Similar significance is to be attached to a unilateral positive venous pulse or to a positive venous pulse occurring only in expiration. The distention of the neck veins with a disappearance of pulsations following pressure on the abdomen is also valuable in indicating stasis.

L. N. K.

Von Borisdorff, B.: Technic of Measuring Arterial Pressure Directly by Means of Arterial Puncture. Acta med. Skand. Suppl. 78. Report of 17th Scandinavian Congress of Medicine, June, 1935, p. 293.

The simple and known technic of arterial puncture under novocaine anesthesia was carried out. The needle was connected to a Broemser manometer through a three-way stopcock by a metal (lead) tube. A syringe half-filled with sodium

citrate solution was attached to the stopcock so that immediately after puncture the needle and adjacent portions of the apparatus could be filled with citrate solution.

The Broemser Frank manometer together with the source of light was mounted on a heavy metal rod, the other end of which was fixed to the camera stand. The rod could be moved vertically and horizontally and fixed tightly within a limited zone. The procedure was to have the rod so placed before puncture of the artery that the manometer with the lead tube projecting was not far from where the point of connection with the needle would be after the latter's insertion. The manometer and lead tube were filled with citrate and the connecting lead tube bent until its conical end could be thrust into the stopcock to which the needle was already connected. A little practice soon enabled one to place the manometer correctly before puncture. Since moving the manometer made necessary readjustment of the optical system, it was essential to have it placed beforehand within the region through which the lead pipe could be conveniently bent. The author issues an interesting warning, namely, that if one has to hunt for the artery and injures it in puncturing, the pulse may disappear. If this happens he recommends giving up the experiment. Very excellent records are shown of arterial pressure during injection of adrenalin and during a Valsalva experiment. Sample curves of two or three varieties of pulse are also reproduced.

J. M. S.

Wolffe, Joseph B., and Digilio, Victor A.: Pancreatic Extract (Tissue Extract No. 568): XIV. Its Use in the Treatment of Hypertension. J. Lab. & Clin. Med. 22: 375, 1937.

The effect of de-insulinized pancreatic extract (tissue extract No. 568) has been studied in a series of 150 unselected cases of hypertension. One hundred patients of the group were used as controls. Blood pressure readings of the patients in bed were taken three times daily and of the ambulatory patients twice weekly. A total of 3,800 injections of tissue extract was given in this study. There were no unusual complications from the injections except slight pain at the site of the injection; mild urticaria in two patients, a sterile area of fatty necrosis in one, and a staphylococcic abscess in a diabetic patient.

In eight of 108 patients suffering from hypertensive cardiovascular disease, there was a marked lowering of systolic and diastolic blood pressure following the administration of the extract. In 62 per cent of this group symptomatic relief which persisted in some cases for over a year was obtained. There was no correlation between the symptomatic relief and the effect on the blood pressure. It is believed that the relief obtained is associated with metabolic changes, probably an improvement in the lipoid metabolism. In six of eight patients with essential hypertension without changes in the eyegrounds and without renal changes, a temporary lowering of the blood pressure was obtained which lasted only while tissue extract was being administered.

E. A. H.

Weicker, B., and Nehrkorn, O.: Myocardium and Tonsillitis. Ztschr. f. Kreislaufforsch. 28: 633, 1936.

The electrocardiogram is the only certain diagnostic criterion of involvement of the myocardium in both acute and chronic tonsillitis. The evidence appears not only as A-V block and extrasystoles, but also as deformities in the various segments of the curve, especially the T-wave.

L. N. K.

Schlomka, G., and Raab, W.: The Significance of the Relative Duration of Systole—Its Relation to Age in Healthy Persons. Ztschr. f. Kreislaufforsch. 28: 673, 1936.

On comparing the duration of electrical systole (the Q-T interval) with the cycle length in 336 normal resting subjects (having an average age of forty-three years) the author found that Fridericia's formula ($S = F \sqrt[3]{C}$) was applicable; F was found to be 8.02 ± 0.02 in this group instead of 8.22 as found by Fridericia and 7.57 as found by Herxheimer. An analysis showed that systole/cycle ratio increased as a person aged, the correlation factor F varying from 7.95 in youth to 8.30 in senility. This is a functional response to aging. In children, F was 7.00; and the short duration of systole in this age group, the authors argue teleologically, permits more time for diastole at the more rapid heart rates which are present in children.

L. N. K.

Brüner, H.: Blood Pressure and Pulse Recording With Electrical Transmission. Ztschr. f. Kreislaufforsch. 28: 814, 1936.

A triode circuit is described in which both grid and plate are provided with a variable oscillatory circuit coupled by a mutual variable inductance. The plate current can drop in the region of resonance of the grid and plate circuits from a maximum to almost zero. One of the condensers in the grid circuit is constructed so as to permit small capacity changes when it is submitted to pressure changes. In this way pressure changes can cause changes in the plate current which can be recorded with an oscillograph. The entire circuit is modeled after one used in industry for measuring thickness of objects. (No description is given of the actual arrangement for connecting the measuring condenser to the animal).

A. K.

Kiss, P. v.: Diphtheritic Alterations of the Heart. Ztschr. f. Kreislaufforsch. 28: 753, 1936.

This analysis is based on an experience with over 500 clinical cases of diphtheria seen by the author. As a result he divides diphtheritic heart involvement into a number of stages as follows:

1. The period of early changes—the period of cardiac dysfunction—which lasts three weeks and consists of the following subdivisions:
   a. The period of toxin invasion occurring during the first two or three days. No anatomical changes occur, and deaths are rare. There is fever, malaise, tachycardia, and an elevated blood pressure. It is a period of cardiac stimulation.
   b. This is then followed by a period during which anatomical changes develop in the heart and/or the conducting system. Hence, block and QRST deformities occur. Bradycardia is also present.
   c. This is then followed by a period in which the ectopic centers become overactive. Tachycardias and arrhythmias occur at this time and these may lead to dilatation, ventricular fibrillation, and death.
2. The period of late changes—the period of heart weakness—which lasts from the third to the eighth or the twelfth week. The heart shows fragmentation and myolysis and also evidence of interstitial inflammation. Clinically, there are the various manifestations of heart failure, and death, when it occurs, resembles that in other types of heart failure.

In diphtheria, in addition to the above, certain rarer complications occur such as emboli from cardiac thrombosis, endocarditis, and anaphylaxis from serum.

L. N. K.

Griffith, J. Q., Jr., Jeffers, W. A., and Lindauer, M. A.: Transient Hypertension in Rats Following the Extravascular Administration of Fluid. Am. J. Surg. 118: 1, 1937.

A report has been made previously of experiments in which intracisternal injection of colloidal kaolin produced marked rise in cerebrospinal pressure and in blood pressure in the rat. Additional experiments are reported in which the effect on the blood pressure of increase in cerebrospinal fluid has been observed. An increased amount of cerebrospinal fluid can be produced by giving hypotonic fluids intravenously, but when blood pressure changes are to be studied, these fluids must be given extravascularly, either by hypodermoclysis or by intraperitoneal injection. A vascular hypertension appeared in 40.5 per cent of 129 rats given fluid, either distilled water or physiologic saline, in amounts not exceeding 30 c.c. per 100 gm. of body weight subcutaneously, or 15 c.c. per 100 gm. of body weight intraperitoneally. The hypertension thus produced was associated with increased cerebrospinal fluid pressure. A correlation with blood dilution or with increased water content of the brain could not be demonstrated. A difference is recognized in the experimental syndrome thus produced from that described by Rowntree because this syndrome can be produced either by physiologic saline, which never produces "water intoxication," or by water in relatively smaller amounts than that used by Rowntree. The animals did not appear to be very ill and seldom had convulsions.

E. A. H.

Tirala, L. G.: The Action of Deep Breathing Upon Blood Pressure. Deutsche Med. Wchnschr. 63: 92, 1937.

By way of introduction the author states that he is unable to divide patients with hypertension, as he sees them in Southern Germany, into the varieties of "red" and "white" hypertension described in Northern Germany. Pale hypertensives have, in his experience, kidney involvement as well. He reports, inadequately, two cases of mild hypertension as examples of what can be done by deep breathing. Only systolic pressure is shown in the charts. In one case it drops from variations between 150 and 120 to between 110 and 90 mm. Hg, in the other, from 170 and 140 to between 140 and 120. Breathing exercises are given three or four times daily for six to eight minutes, and emphasis is placed chiefly upon expiration rather than inspiration because most of his patients' chests were fixed partly in the inspiratory position. The author believes that this mode of treatment is responsible for the disappearance of subjective symptoms such as dyspnea, insomnia, irritability, headache, poor memory, etc., and flatulence as well.

J. M. S.

White, James C., Okelberry, Alfred M., and Whitelaw, George P.: Vasomotor Tonus of the Denervated Artery; Control of Sympathectomized Blood Vessels by Sympathomimetic Hormones and Its Relation to the Surgical Treatment of Patients With Raynaud's Disease. Arch. of Neurol. & Psychiat. 36: 1251, 1936.

Denervation of the sympathetic nerve supply to the arm by ganglionectomy has proved far less effective in relieving the symptoms of Raynaud's disease in the upper extremities than has a similar procedure in relieving the symptoms and restoring adequate circulation in Raynaud's disease of the lower extremities. The

reason for this discrepancy has been obscure until recently. A clue to the solution of the problem may be found in the phenomenon well known to physiologists, since the work of Elliott in 1905, that denervated smooth muscle becomes abnormally sensitive to epinephrine reaching it in the blood stream. The possible clinical significance of this principle was overlooked up to the time of the work of Freeman, Smithwick, and White in 1934. These investigators found that in human beings in whom cervicothoracic sympathectomy had been performed a striking vasoconstrictor response occurs both as a result of intravenous injection of very dilute quantities of epinephrine and as a result of stimulation of the adrenal glands by insulin-induced hypoglycemia.

In order to obtain further information concerning this constrictor response after sympathectomy, a series of experiments was performed on 35 albino rabbits and 3 monkeys. The extent of vasoconstriction in the rabbit's ear in response to cold, fear, psychic or painful stimuli was determined after the following procedures had been carried out: (1) acute denervation by infiltrating the tissue at the base of the ear with a 1 per cent procaine solution; (2) complete surgical sympathetic denervation of the ear including ganglionectomy with subsequent degeneration of postganglionic neurons; (3) surgical sympathetic denervation of the ear including ganglionectomy and resection of one adrenal gland and denervation of the other; (4) preganglionic sympathectomy of the ear by laminectomy and division of the upper thoracic spinal roots or by resection of the inferior cervical and first and second thoracic sympathetic ganglia. In the monkeys, similar tests were performed and adrenalin injection was done following cervicothoracic ganglionectomy and after anterior rhizotomy from the fourth through the tenth thoracic segment. In one animal the two procedures were carried out on opposite sides.

The results of the experiments demonstrate conclusively that the increase in sensitivity of the denervated arterial wall is much greater after ganglionectomy and degeneration of the postganglionic neurons than after destruction of the preganglionic portion of the vasoconstrictor pathway, with preservation of the ganglia. Some circulating hormone mediates the vasospasm which persists after ganglionectomy and degeneration of postganglionic fibers and it is thought to be adrenalin. Sympathin and other as yet unknown substances probably play a contributory rôle.

The difference in results from cervicothoracic ganglionectomy and lumbar ganglionectomy can be explained on the basis of the different anatomic arrangement of the vasomotor outflow to the arms than to the legs; according to Langley, "the vertebral sympathetic ganglia are segmental and each supplies sympathetic fibers to its own spinal nerve. The few fibers which do not arise from the corresponding ganglion arise from the ganglion next above or below." Therefore, lumbar ganglionectomy interrupts the vasoconstrictor outflow to the sciatic nerve in its preganglionic portion in contrast to the cervicothoracic ganglionectomy which causes degeneration of the postganglionic fibers to the brachial plexus. The importance of these experiments to clinical surgery is in emphasizing that the ganglia which are commonly removed in cervicothoracic ganglionectomy for Raynaud's disease are the most important ones to preserve. Section of the thoracic sympathetic chain below the third ganglion and resection of the proximal 2 to 3 cm. of the second and third intercostal nerves produces sympathetic denervation of the upper extremity of man without performing ganglionectomy. Theoretically, such a procedure would prevent the greatly increased sensitivity of arterioles to epinephrine which follows ganglionectomy. Consequently, the results of preganglionic sympathectomy for Raynaud's disease of the upper extremities should be as good as those following the standard type of sympathetic denervation for Raynaud's disease of the lower extremities. There is considerable evidence that this is true.

E. A. H.

Loeffler, Louis: Genesis of Intestinal Infarction Following Embolization of the Superior Mesenteric Artery. Arch. Path. 22: 755, 1936.

One would expect that embolic occlusion of the superior mesenteric artery in man would result in anemic necrosis of the intestine, but it is well known that it causes a hemorrhagic infarct. Numerous investigators, attempting to obtain an explanation, have ligated superior mesenteric arteries in animals. Contradictory results have been obtained. The author ligated the superior mesenteric arteries of rats, immediately and thereafter observed the blood vessels in the intestine, and observed an immediate arrest of the whole circulation except in the few collateral channels. Anemic necrosis resulted. The collateral channels are extraordinarily few and completely unconcerned with the process of infarction. After ligation of the portal vein as well as of the superior mesenteric artery, the collateral circulation is more extensive. Likewise, thrombosis of an intestinal vein or strangulation of an intestinal loop—measures which increase venous pressure—results in hemorrhagic infarction. The author reasons that the cause of the clinical hemorrhagic infarction found in embolization of the superior mesenteric artery is to be sought in the congested and altered state of the circulation caused by cardiac changes which produce the emboli.

H. M.

Spiegel, Rose: Clinical Aspects of Periarteritis Nodosa. Arch. Int. Med. 58: 993, 1936.

Because of the variability of symptoms, periarteritis nodosa mimics other conditions and even with the aid of biopsies has been diagnosed correctly in only about 12 per cent of the proved cases. In recent years diagnoses have been much more accurate, because with such multiplicity of symptoms no other single diagnosis is applicable.

Fifteen cases of periarteritis nodosa with post-mortem studies are presented. More than half had prodromal illnesses—acute tonsillitis, acute sinusitis, scarlet fever, or sensitization asthma. Four clearly had had rheumatic fever. The usual mode of onset was with abdominal pain, associated with articular, cardiac, or renal symptoms. All the patients showed cardiac and renal involvement at autopsy. Twelve had cutaneous lesions of various sorts; 12 had polyserositis; 7 had surgical complications involving the gastrointestinal tract, 3 of which were hemorrhagic pancreatitis; 5 had arteritic lesions of the liver; one had periportal fibrosis; and 2 had fatty degeneration. No one cause of periarteritis nodosa has been found. The periarteritic nodules are small aneurysms, but no case has been proved to be caused by syphilis. Attempts to reproduce the disease in lower animals by inoculation of crushed nodules have been inconclusive. The bacteria principally implicated in the prodromes of periarteritis nodosa are the hemolytic streptococci. The disease may be a superimposed vascular reaction in the course of rheumatic fever. Healing can occur. Healed periarteritic lesions closely resemble arteriosclerosis.

H. M.

Gutzut, R.: Gangrene From Blocking of the Veins. München. med. Wchnschr. 83: No. 40, 1936.

After a lengthy introduction which begins with Harvey's discovery, which follows the increasing emphasis placed upon the vascular system instead of upon the heart alone, and which ends with the statement that the importance of the veins is not yet fully appreciated, the author reports six cases of venous thrombosis. The striking facts common to all save one of the cases were that they occurred suddenly and produced moist gangrene (usually with edema), that the pulsations of the artery

could not be felt, that they were taken to be cases of arterial embolism. That the artery was not occluded was ascertained by operation or autopsy. He states that a reliable means of distinguishing between venous and arterial blockage is surface temperature—in the former the temperature is normal provided gangrene is not already present. Figures for the surface temperatures are not given, however.

J. M. S.

Hunt, John H.: The Raynaud Phenomena; A Critical Review. Quart. J. Med. 5: 399, 1936.

A critical review of the Raynaud phenomena is presented. The differential diagnosis of the various conditions in which these phenomena occur is considered in detail. The probable explanation of the mechanism producing the symptoms and signs and the results from sympathetic ganglionectomy are discussed.

E. A. H.

McKechnie, R. E., and Allen, E. V.: Sudden Occlusion of the Arteries of the Extremities. Surg., Gynec. & Obst. 63: 231, 1936.

The sources and causes of embolus and thrombosis of the peripheral arteries are discussed. In 47 per cent of the cases, the symptoms appeared suddenly and reached their maximal intensity quickly; in the remaining cases the development of symptoms was gradual, requiring from one hour to several hours to reach full development. In only 54 per cent of cases was pain the initial symptom. The incidence of diagnosis of sudden arterial occlusion parallels roughly the suspicion by the physician that it exists. If one examines the extremities for the condition only when severe pain, pallor, and coldness exist, many cases will be overlooked. Thrombophlebitis is the only condition which may be differentiated with difficulty from sudden arterial occlusion. Ordinarily the normal temperature, edema, distended veins, and normal arterial pulsations observed in cases of thrombophlebitis serve as an adequate contrast to the lowered temperature, collapsed veins, and diminished or absent pulsations in the arteries in cases of sudden arterial occlusion. However, arterial pulsations may be absent temporarily in phlebitis, apparently as a result of spasm. In sudden arterial occlusion the veins may be distended, usually after many hours have elapsed, as a result of secondary venous thrombosis. Under such circumstances close attention must be given to the mode of onset and the known possibilities of embolism. In rare instances the diagnosis may not be clear until many hours have elapsed.

The probability that arterial spasm is responsible for the pain in embolism either directly or as a result of the ischemia it produces is so logical and fits so well with recorded observations regarding suddenness of onset, severity, and the difficulty of localizing the pain that there appears to be a distinct cause and effect relationship.

There are three important "don'ts" in the treatment of sudden arterial occlusion: Don't delay treatment for more than two or three hours; don't elevate the extremity; and don't subject it to heat which exceeds by more than a few degrees the temperature of the body. Delayed treatment means a poor prospect of recovery in those instances in which recovery would not occur spontaneously. Until the custom disappears entirely, it cannot be emphasized too frequently that tissue deprived of its normal blood supply does not tolerate heat well. Hot water bottles are frequently of a temperature which exceeds 150° F. The extremity should be placed in a dependent position. When the legs are involved the head of the bed should be elevated; when the arms are involved, the patient should be in the semisitting position. Vasodilators should be given to relieve arterial spasm, if present. The use of intermittent negative and positive pressure has been very successful in some hands and should

be used if a machine is available. On the assumption that one of the chief requisites for a favorable outcome is the induction of collateral arteries to assume a heightened function of transportation of blood, spinal anesthesia may be tried when the lower extremities are involved. Brachial plexus block may produce similar effects in the upper extremities. General anesthesia may be used if the condition of the patient permits, for the same reason that spinal anesthesia may be of value. Sympathectomy, likewise, produces maximal vasodilation and is of value in sudden arterial occlusion, as shown experimentally, but ordinarily the condition of the patient does not warrant such a major operation. If the procedures outlined, exclusive of sympathectomy, do not produce a rapid improvement in the circulation, surgical removal of the clot should be considered when occlusion is due to an embolus.

E. A. H.

Allen, E. V., and Lauderdale, T. L.: Accidental Transmission of Thrombo-Angiitis Obliterans From Man to Man. Proc. Staff Meet., Mayo Clin. 11: 641, 1936.

A surgeon, a Scotchman, forty-five years old, who had been well except for pulmonary tuberculosis, had smoked forty cigarettes daily for twenty-five years. He had never had superficial phlebitis. Six months previously, while he was amputating the toe of a thirty-six-year-old man with thromboangiitis obliterans, a spicule of bone from the patient's toe had accidentally pierced the flesh of the palmar surface of the third finger of his right hand. No local reaction occurred subsequently. One month later, color changes, consisting of cyanosis and pallor on exposure to cold and after wearing a rubber glove, had appeared on the third finger of the right hand, and three weeks later similar color changes had appeared on the fourth and fifth fingers of the same hand. Since then symptoms had diminished gradually but had not disappeared entirely.

Examination six months after the accident disclosed evidence of pulmonary tuberculosis, normal pulsations in the radial, ulnar, femoral, popliteal, dorsalis pedis, and posterior tibial arteries, reduction of temperature of the skin of the third, fourth, and fifth fingers of the right hand and markedly abnormal pallor of these fingers when the hand was elevated. Cervical rib could not be demonstrated by clinical or roentgenological examination. Thermometric studies revealed the temperature of the skin of the third, fourth, and fifth fingers of the right hand to be approximately 30° C., whereas that of the corresponding fingers of the left hand was approximately 35° C. Following the ingestion of 1 ounce (30 c.c.) of ethyl alcohol, the temperature of the skin of the fingers of the right hand increased to 34° C. and that of the corresponding fingers of the left hand, to 36.5° C. A diagnosis of thromboangiitis obliterans involving digital arteries of the right hand was made.

Raynaud's disease was satisfactorily excluded by the unilaterality of symptoms, pallor of the fingers on elevation, failure of arterial relaxation following the ingestion of alcohol, and the sex of the patient. Roentgenologic evidence of cervical rib was lacking. The possibility of the coincidental development of thromboangiitis obliterans of the digital arteries without there being a cause and effect relationship between the accident and the disease is almost certainly excluded by evidence of primary development of an occlusive arterial lesion in the injured finger and the absence of arterial lesions elsewhere in the body. There seems to be no other logical conclusion than that the agent responsible for the occlusive arterial lesion in the digital arteries of the patient was carried to the third digit of the right hand on the spicule of bone from the toe of a patient who had an occlusive arterial lesion.

AUTHOR.

Müller, A.: Mechanical Basis of the Regulation of the Circulation. Schweiz. med. Wchnschr. 65: 339, 1935.

An attempt is made to apply mathematical concepts of hydraulics to the problems of the circulation.

L. N. K.

Hochrein, M., and Matthes, K.: Circulation in Sport. Arzt und Sport, No. 19, 91, 1935.

The authors analyze the circulatory regulation in sport activity in which short and protracted effort are involved. They emphasize the value of the electrocardiogram in investigating the adequacy of the coronary circulation in such sport activities and of vital capacity measurements as an index of uneconomical blood distribution. Oxygen saturation determinations with Matthes method was also found to be valuable in determining how far the circulatory and respiratory adjustments met the work load of the exercise. The combination of these methods may be useful in determining weakness of the heart.

L. N. K.

Hartmann, H., Orskov, S. L., and Rein, H.: The Reaction of the Renal Vessels During the Course of Regulatory Events in the Systemic Circulation. Arch. f. d. ges. Physiol. 238: 239, 1936.

By means of Rein's thermoelectric stromuhr, the blood flow through one or both kidneys of dogs, or through one kidney and leg, and arterial pressure (femoral or carotid) were simultaneously recorded. The conclusions in each case based on nearly one hundred observations upon twenty-five dogs are direct. In general, it appears that the blood vessels of the kidney not only do not participate in systemic vascular reactions but vary in state of contraction to offset general reactions—that is to say, to maintain blood flow through the kidney constant in spite of changes in systemic pressure and flow. The blood flow through the kidney does not change (except perhaps for a small passive increase) when systemic blood pressure rises following closing of the carotid artery central to the carotid sinus, a pressor stimulus, but it decreases when a similar rise in systemic pressure is induced by inhalation of a mixture of gas containing 10 per cent carbon dioxide. Although the blood flow through the kidneys falls, naturally, on stimulation of the peripheral end of the vagus sufficient to stop the heartbeat temporarily, a compensatory dilatation of the renal vessels takes place which allows return of the blood flow to normal at a time when systemic pressure is still exceedingly low. Furthermore, if stimulation of the vagus is gentle, it can be inferred by various time relations that the compensatory renal vasodilatation is dependent upon the reduction in blood pressure and not upon stimulation of the vagus. It is shown that fifty to one hundred times the dose of adrenalin necessary to elicit vasoconstriction in muscle and skin is needed to constrict the renal vessels to a degree sufficient to reduce the flow of blood. The increased sensitivity of the denervated kidney to adrenalin is demonstrated. The authors are inclined to believe that the increased sensitivity is due to removal of a reflex vasodilatation. This view is suggested apparently because time relations between change of systemic blood pressure and decrease in blood flow to the kidney coincide in the ennervated kidney but fail in the denervated one. It appears that vascular reactions peculiar to particular regions, such as the kidneys, exist. That blood flow through the kidney tends to remain constant in spite of systemic pressure and flow changes finds ready application to an understanding of the behavior of kidney function observed in the clinic.

J. M. S.

McCombs, Robert P., and McElroy, James S.: Reversible Autohemagglutination With Peripheral Vascular Symptoms. Arch. Int. Med. 59: 107, 1937.

Five of these patients had blueness of the peripheral parts and numbness on exposure to cold. The authors present a case in which symptoms of peripheral vascular insufficiency appeared on exposure to cold and subsided on warming. Autohemagglutination in vitro occurred at 27° C. The authors believe that the symptoms are caused by intravascular plugging resulting from agglutinated cells. The evidence for this is that local heat relieved symptoms promptly but heat applied elsewhere to the body failed to relieve symptoms in the affected limb or to raise skin temperature. The arms were immersed in water at 43.3° C., and the temperature of the skin in the lower extremities was recorded. Apparently they warmed the arms for only twenty minutes; a longer period would make the evidence even more convincing.

H. M.

Vires, J., May, P., and Balmis, J.: Concerning a Case of Erythromelalgia. Arch. Soc. sc. méd. et biol. 17: 408, 1936.

In the right arm and hand of a fifty-nine-year-old miner attacks of pain, redness, and tingling increased by warmth and by hanging down had been occurring for about three weeks. The authors state that the red blotchy appearance during an attack and the manner in which the attacks occurred were very similar to the disease described by Weir Mitchell. X-ray photographs showed a destructive lesion of the cervical vertebrae and some of the disks with exostoses. These lesions were thought therefore to be due to chronic arthritis for which roentgen therapy of the shoulder region was given. Following treatment the whole syndrome disappeared. They attributed the symptoms therefore to irritation of the cervical sympathetic nerves and consequent vasomotor disturbances.

J. M. S.

Errata

In the article, "Heart Disease in Children," by Irving R. Roth, M.D., Claire Lingg, M.A., and Alice Whittemore, A.B., New York, N. Y., which appeared in the January issue of the JOURNAL, on page 52, line 3, the sentence should read, "Among the 149 first recurrences (Fig. 10*A*) polyarthritis was present, alone or combined, in 74 per cent (110 cases)" instead of, "Among the 94 second recurrences. . . ."

Also in line 5 of the footnote on page 38 the name "Mrs. Henry F. Glazer" should be "Mrs. Henry S. Glazier."

The American Heart Journal

VOL. 13 APRIL, 1937 No. 4

Original Communications

AN ORTHODIAGRAPHIC STUDY OF 291 COLLEGE STUDENTS WHO SHOWED NO EVIDENCE OF HEART DISEASE*

JOSEPH EDEIKEN, M.D., AND FRANCIS CLARK WOOD, M.D.
PHILADELPHIA, PA.

THE material comprising this study consists of the orthodiagrams of 291 male college students between the ages of sixteen and twenty-six years, in whom history, physical examination, and electrocardiographic study showed no evidence of heart disease. Two hundred ninety-nine individuals were examined, but eight were excluded: four, because a tendency to faint precluded accurate orthodiagraphy; and four, because they were found to have heart disease: one showed a congenital lesion, and three had aortic insufficiency. This paper contains a presentation of figures obtained for the various orthodiagraphic measurements in this group; a comparison of them with the generally accepted standards of Eyster and Hodges,[1] a description of the deviations from these standards which were encountered, and a discussion of the adequacy of the orthodiagraphic method for determining pathological cardiac enlargement.

Orthodiagrams were made by the usual technic. They were all done by one of us (J. E.). After completing the upper and lower borders, the area of the silhouette was measured by planimeter. The transverse diameter, cardiothoracic ratio, and anteroposterior diameter were also determined.

Cardiac area was measured in 290 cases† (Fig. 1). In 227 (78.3 per cent) the area was 5 per cent or more below the predicted value. In 172 (59.3 per cent) it was 10 per cent or more below the predicted value. The smallest heart was 28.3 per cent below the predicted figure. On the other hand, only nine students (3.1 per cent) had

*From the Edward B. Robinette Foundation, Medical Clinic, Hospital of the University of Pennsylvania, and from the Department of Student Health, University of Pennsylvania.

†In one case predicted values were not calculated because height and weight were not obtained.

cardiac areas 5 per cent or more above the predicted value and only four showed cardiac areas 10 per cent or more above. The largest area was 13.3 per cent above the predicted figure.

Transverse diameter was measured in 290 cases* (Fig. 2). In 136 (46.8 per cent) the diameters were 0.5 cm. or more below the predicted values. In 39 (13.4 per cent) the transverse diameters were 0.5 cm. or more above the predicted values. In the latter group 27 cases exceeded the predicted figures by from 0.5 cm. to 0.9 cm. Nine exceeded it by from 1 cm. to 1.3 cm. Three students showed transverse diameters which were 1.6 cm., 2 cm., and 2.2 cm. above the predicted figures. In each of the three, the heart was markedly transverse in position.

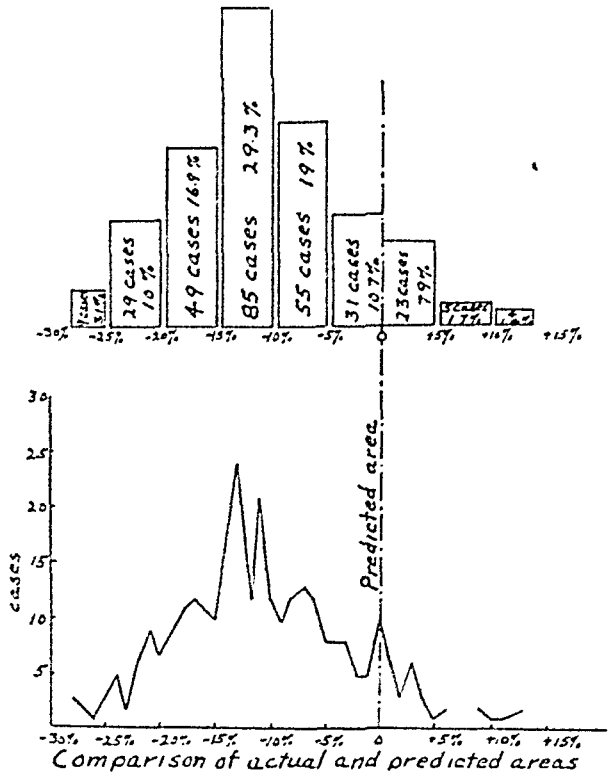

Fig. 1.

Cardiothoracic ratio was determined in 290 cases† (Fig. 3). With the exception of a single student whose ratio was 0.6 the range of variation was 0.37 to 0.53. An examination of the distribution curve shows the vast majority to be in the neighborhood of 0.45. In 247 (85.3 per cent) the cardiothoracic ratios were between 0.40 and 0.50; 24 (8.3 per cent) showed ratios slightly above, and 18 (6.2 per cent), slightly below these figures.

The anteroposterior diameter of the heart was measured in 269 cases, the range of variation being from 45 per cent to 93 per cent of the transverse diameter (Fig. 4). In most cases the anteroposterior diam-

*In one case predicted values were not calculated because height and weight were not obtained.

†In one other case the left margin of chest was not copied.

eter was measured by a line joining the foremost point of the heart with the most posterior point. This line was usually horizontal or slightly diagonal. In some cases, however, in which the angle between

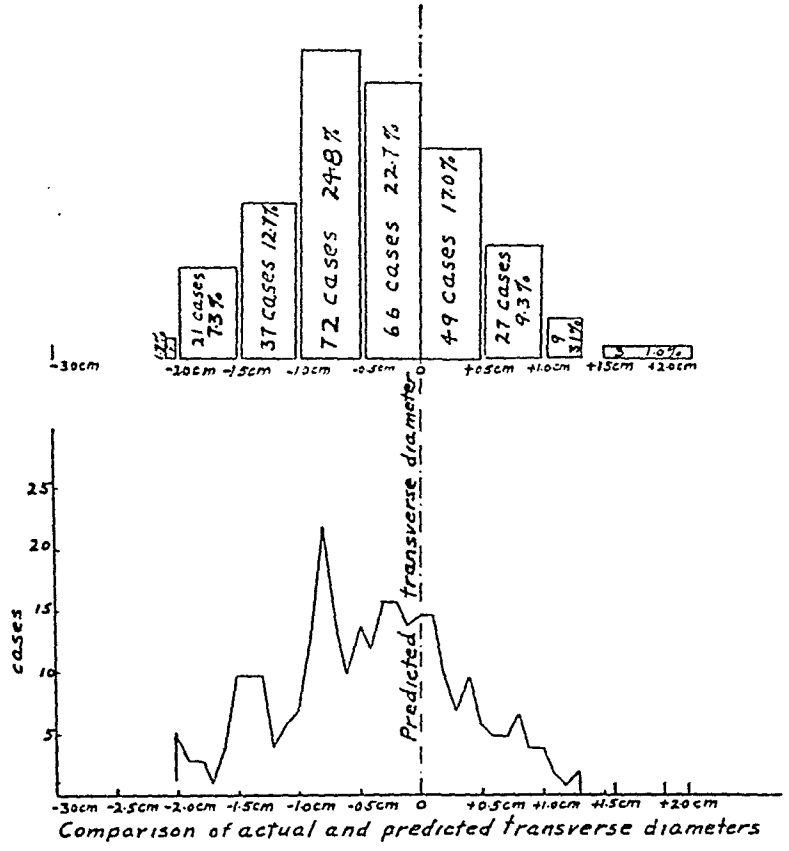

Fig. 2.

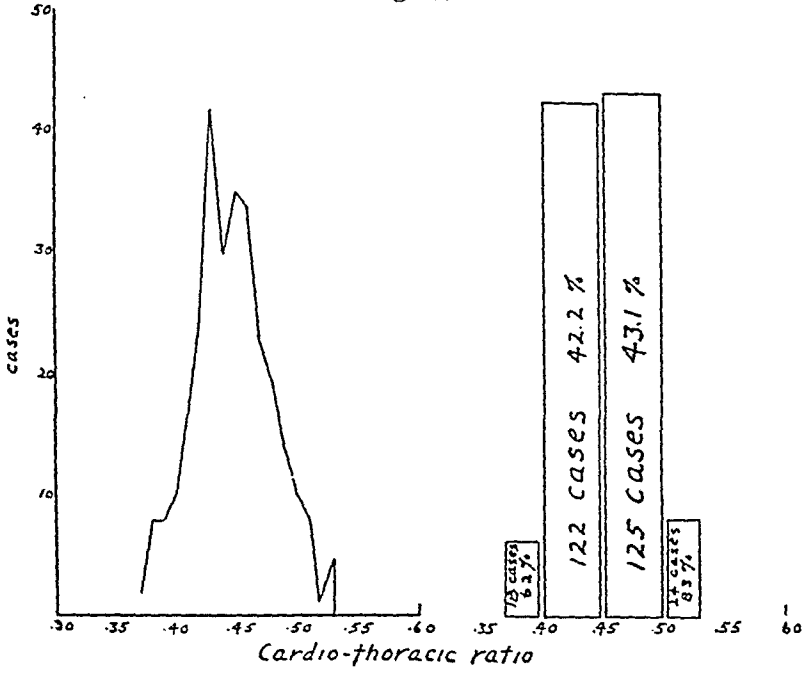

Fig. 3.

this line and the vertical was acute, the anteroposterior diameter was measured in the same manner as the transverse diameter: a vertical line was drawn midway between the spine and sternum and the antero-

posterior diameter considered the sum of the greatest distances which the heart shadow extended in either direction from this line. In 82.6 per cent of the cases, the anteroposterior diameter measured between 60 per cent and 85 per cent of the transverse diameter. These figures are in agreement with those of Roesler,[2] which showed 91.3 per cent of cases with an anteroposterior diameter between 62.5 per cent and 85 per cent of the transverse diameter. His group included both sexes and a wider age group.

DISCUSSION

The two principal roentgenological signs of a cardiac lesion are cardiac enlargement and an abnormal shape of the cardio-aortic shadow. Our studies prompt the following comments upon them:

A. *Concerning Cardiac Enlargement.*—(1) The predicted normal figures of Hodges and Eyster may be too high for young men in this

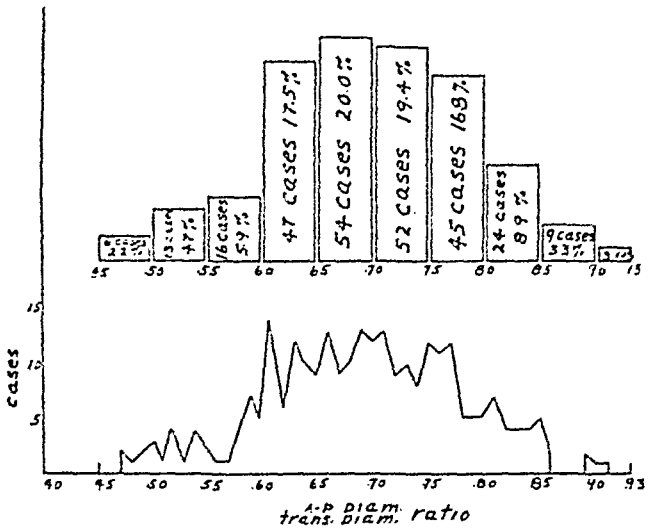

Fig. 4.

age group, and the normal variation allowed on either side may be too narrow. An examination of the distribution curve for cardiac area (Fig. 1) shows that the majority of these subjects fall to the left of the line which marks the predicted value. If this line were moved 10 per cent to the left, it would fall more nearly in the center of the distribution curve. If, in addition, the range of normal variation were considered 15 per cent in either direction, instead of 10 per cent, 272 cases (93.8 per cent) would fall within normal limits, 9 (3.1 per cent) would fall above, and the same number slightly below. Study of the distribution curve for transverse diameter (Fig. 2) shows that the majority of our cases have a transverse diameter which is below the predicted figure. If the line of predicted normal were moved 0.5 cm. to the left and if the normal range on either side were considered to be 1 cm. instead of 0.5 cm., the prediction figures would coincide more nearly with what seems to us correct for our group. (2) In this group

of students when one orthodiagraphic measurement tended to be above normal, its implication was usually neutralized by another measurement. For instance, thirty-eight of thirty-nine cases with a transverse diameter 0.5 cm. or more above the predicted figure, had a cardiothoracic ratio of 0.53 or less. Furthermore, eight of nine subjects with a frontal silhouette area 5 per cent or more above the predicted figure had an anteroposterior diameter which was only from 48 per cent to 71 per cent of the transverse diameter.

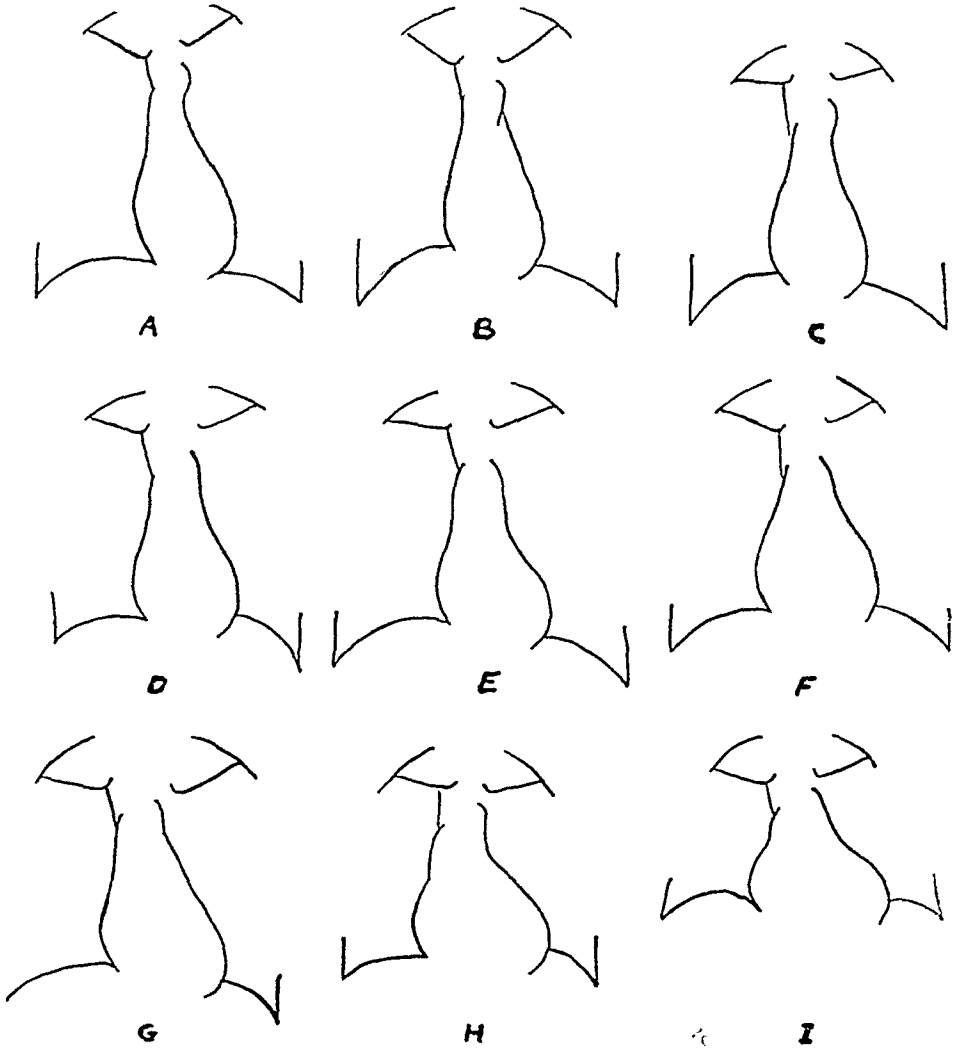

Fig. 5.—Showing the various heart shapes encountered in 291 college students without evidence of cardiovascular disease. The heights and weights of the different individuals are as follows: (*A*) 68 inches, 127 pounds; (*B*) 66½ inches, 130 pounds; (*C*) 66 inches, 122 pounds; (*D*) 70 inches, 138 pounds; (*E*) 69 inches, 148 pounds; (*F*) 70½ inches, 124 pounds; (*G*) 70 inches, 130 pounds; (*H*) 68 inches, 145 pounds; (*I*) 70½ inches, 192 pounds.

B. *Concerning Abnormal Shape of the Cardio-Aortic Shadow.*—Figure 5 shows the various types of silhouettes which were observed. Physique, height of diaphragm, shape of chest, and deformities of the spine influence the shape of the cardio-aortic shadow. Slight degrees of scoliosis are encountered rather frequently. Right scoliosis may produce the so-called mitral configuration. It may also make the aortic knob more readily visible by removing the spine from the background.

Left scoliosis may cause the supra cardiac shadow to appear widened since it displaces the descending aorta to the left. Rotation of the patient to the left in right scoliosis and to the right in left scoliosis tends in most cases to correct the picture and may show the heart to be of normal shape. The descending aorta was visualized in certain of our subjects. Consequently this finding should not be interpreted routinely as indicating arteriosclerosis.

Our observations upon this group of 291 normal students, as well as upon patients with heart disease, make it clear that no rigid roentgenological criteria can be relied upon to determine the presence or absence of heart disease. It is the practice in this clinic to make use of various measurements: the area of the silhouette, the transverse diameter, the cardiothoracic ratio and the anteroposterior diameter. The shape of the heart is also taken into consideration. Any one of these when used alone may be misleading. Together they give a wrong impression less often. In many instances the presence or absence of pathological cardiac enlargement cannot be determined on the basis of x-ray measurements of the heart alone. Furthermore, the diagnosis of heart disease, based upon some abnormality of shape, such as the so-called "mitral configuration," may in certain cases be misleading.

There were thirty-eight cases in which the frontal area of the silhouette was small (20 per cent or more below the predicted figure). In all but four of these, the anteroposterior diameter was of medium length or less (below 85 per cent of the transverse diameter). In this group of cases, therefore, a heart with a small frontal area tended to be small in all its dimensions.

In 1931 we saw two students with unusually large hearts in whom no evidence of heart disease was demonstrated. Both subjects had marked bradycardia. Moreover, many patients with tachycardia and the effort syndrome, without definite signs of heart disease, have been found to have small hearts. These observations have led us to study our present group to see whether it supports the belief that, in a group of normal subjects, unusually small hearts are often associated with tachycardia, and unusually large hearts with bradycardia. The major difficulty is that, for the heart rate, we used the figure obtained from an electrocardiogram taken after the completion of the orthodiagram. The figures are as follows. A. The small heart and tachycardia: Thirty-eight of 291 had small hearts (i.e., the cardiac area was 20 per cent or more below the predicted figure). Of these 38, 4 had a heart rate of over 110, and 2 had a heart rate of between 100 and 110. To approach the question from another direction, 16 of 291 had a heart rate of over 110, and 4 of these had small hearts. Twenty-five of 291 had heart rates of between 100 and 110, and 2 of these had small hearts. Sixteen of 291 had heart rates of 60 or less, and none of these had small hearts. B. The large heart and bradycardia: None of the cases in our group showed really large hearts. The four largest showed

silhouette areas between 10 per cent and 13.3 per cent above the predicted figure. Three of the 4 had heart rates between 60 and 70; the fourth had a rate of 75. Thus, our data seem to suggest some relationship between the extremes of heart size and the extremes of heart rate, but they are not very conclusive.

SUMMARY

1. Orthodiagrams were made in 291 male students between the ages of sixteen and twenty-six years, with no evidence of cardiovascular disease.

2. The measurements suggest that the predicted figures of Eyster and Hodges may be too high for young male adults: that the predicted area is approximately 10 per cent too high, and the predicted transverse diameter 0.5 cm. too long.

3. Hearts which were small in the frontal plane frequently had a small anteroposterior diameter.

4. The shape of the heart varied greatly. It was influenced by (a) physique, (b) height of diaphragm, (c) shape of chest, and (d) spinal deformity. In the vertical or ptotic heart the region of the pulmonary artery was frequently prominent. When combined with a straight left border, it sometimes simulated a "mitral heart."

5. In many cases the shadow of the proximal portion of the descending aorta could be seen above the heart.

6. Measurements of the heart size as well as empirical determinations of cardiac shape should be interpreted with a knowledge of their limitations. In many instances the presence or absence of pathological enlargement of the heart cannot be determined on the basis of x-ray measurements alone.

7. In patients without demonstrable cardiac disease there may be an association between the small heart and tachycardia on one hand, and between the large heart and bradycardia on the other. However, our data do not supply convincing evidence upon this question.

REFERENCES

1. Eyster, J. A. E., and Hodges, F. J.: Estimation of Transverse Cardiac Diameter in Man, Arch. Int. Med. 37: 707, 1926.
2. Roesler, H.: Relation of Shape of Heart to Shape of Chest, With Special Reference to Antero-Posterior Dimension and Morphology of Various Normal Heart Types: Contribution to Question of Accuracy of Ordinary Roentgenological Methods of Heart Measurement, Am. J. Roentgenol. 32: 464, 1934.

CARDIAC PSYCHOSIS AND THE SYMPTOM OF ANXIETY*

JOSEPH WORTIS,† M.D.
NEW YORK, N. Y.

IT HAS been known for a long time that patients with heart failure may develop a psychosis from which they recover if the heart failure is relieved. As early as 1806 Napoleon's physician, Corvisart, described the main features of cardiac psychosis: depression, restlessness and irritability, rising in some cases to excitement with confusion, and continuous anxiety. About two years ago we had the opportunity of observing a number of such cases at Bellevue; we shall here describe some of the mental changes that were found and relate them as far as possible to the course and nature of the disease.

A TYPICAL CASE HISTORY

G. M., a sixty-one-year-old man with signs of congestive heart failure, was transferred from a medical ward to the psychiatric service because of unmanageable excitement and delusions. "I heard fellows over there talking of shooting," he said, "and a raid was made the other night. The beds were moved around. The nurse tried to give me some medicine but that man there knocked it down and drank it himself. They got mean with me." "I was very much alarmed," he said next day. "You know the priest came over to see me. . . . I don't know exactly why, but I felt intimidated. I did feel frightened. Whether I should have reason for feeling frightened, I don't remember now. This nurse, instead of handing me the medicine, gave it to some man, and he drank it, and this nurse laughed in the most sneering manner. But I was careful not to make any move, so that they wouldn't think me insane. That man Jack over there—a porter or something—had the most brutal manner, and tried to intimidate me. It looked like an armed protection; there were people there with guns. There was an old man walking up and down in front of me, and he told me, if I wanted to get out, it had better be now. Last night strange things happened, and I don't know whether it was imagination or not, but this man in the bed beside me kept jumping up and looking out of the window. His throat was cut and gashed. . . ."

This patient was talkative and extremely circumstantial during examination, and at times incoherent. He looked very frightened. The persecutory delusions and hallucinations were vividly described, but only vaguely systematized, and had the quality of nightmares. He appeared weak and admitted feeling frightened, but he rested quietly in bed during the examination. The patient at this time was breathless while at rest, orthopneic, and slightly cyanotic. The teleroentgenogram showed an enlarged heart. The first sound at the apex was of poor quality, and the second aortic sound was accentuated. The rhythm was regular; the rate was 88. There were no murmurs. There were moist râles at the bases of both lungs. The liver was enlarged to two fingerbreadths below the costal margin. There was a moderate

*From Bellevue Psychiatric Hospital. Read in part at the joint meeting of the New York Neurological Society and the New York Academy of Medicine, Section of Neurology and Psychiatry, May 12, 1936.

†Research Fellow, Bellevue Hospital, and Research Fellow in Psychiatry, New York University Medical College.

edema of the extremities, and the blood pressure was usually about 180/90. There was moderate sclerosis of the radial arteries. There was also a history of an attack of polyarthritis at the age of seven years, but the physical findings on the whole pointed to hypertension as the cause of the heart disease.

With bed rest and digitalis the patient showed steady improvement within the next week. There were often restlessness at night and paroxysmal dyspnea, sometimes of marked severity, but at the end of two weeks the patient was up and about and was no longer confused. He was fairly lucid in his speech and amiable in manner and no longer had delusions. Though he was still inclined to ramble, he gave the following account of the psychotic episode:

"Everything was like a dream," he said; "I imagined people were against me and were walking about in a sort of gang and acting mean to me. I remember very clearly the incidents that happened—how they stood together in a corner of the ward, and how somebody came over to my bed and drank my medicine. When I came here, I thought people were in the gang against me, too. I remember looking at the nurse and thinking she was a pleasant person—not the kind you would expect to be in a gang, and I thought there must be something wrong. I was suspicious of you and the other doctor. When you asked if I saw things I said no, because I thought it would be used against me. I feel recovered now."

Since the patient showed further physical and mental improvement during the next ten days, he was finally discharged about a month after admission, still somewhat dyspneic, but with no signs of a psychosis.

Three months later the patient returned, again very dyspneic and orthopneic, with pulmonary congestion and an enlarged liver, and again he was psychotic. "I was courteous as I always am," he declared, "but they have been treating me outrageously . . . one of those patients was smoking a pipe, and I could tell it was opium. He lied deliberately about me and had an insulting manner. . . ." The patient was reported to have threatened another patient with a razor. He was again tense and excited, anxious and depressed, but he again responded favorably to treatment and in a month was again discharged, this time to the medical service of Bellevue Hospital. Less than two years later the patient died.

COMMENT

The frequency with which this clinical picture appeared in cases of cardiac psychosis was striking. One could indeed often suspect the presence of heart failure, merely by talking to the patient and watching him. The breathlessness and weakness, the feeble restlessness, the pallor or cyanosis, the tense, pained look and active eyes, the rambling, low pitched, plaintive and often incoherent speech, were all typical. These patients were unable to answer questions to the point; they talked too much and roundabout, complainingly or with an air of indignation. They showed a peculiar responsiveness to distracting details in the surroundings, and it was not easy to hold the patient's attention in examination. The patient might be at once somnolent and hyperacute, lying with half closed eyes, but starting at the least interruption. Many complained of inability to sleep, or of bad dreams or dreamlike hallucinations, they were often not quite sure which. We shall later investigate these symptoms more carefully.

In the course of further observation it appeared that the mental symptoms most frequently seen were confusion, anxiety and persecutory de-

lusions, and often overtalkativeness and circumstantiality. Thus in a small group of five cases they appeared in the order of frequency shown in Table I.

TABLE I

FREQUENCY OF MOST COMMON SYMPTOMS IN FIVE SELECTED CASES OF CARDIAC PSYCHOSIS

NO.	NAME	AGE, SEX	DIAGNOSIS	CONFUSION	ANXIETY	DELUSIONS OF PERSECUTION	OVERTALKATIVENESS	CIRCUMSTANTIALITY
95380	E. P.	49 F.	Arteriosclerotic heart disease, fibroid heart, auricular fibrillation. Class IIb.	+	+	+	+	+
95484	H. O.	50 F.	Arteriosclerotic and hypertensive heart disease, enlarged heart, fibroid heart, regular sinus rhythm. Class IIb.	+	+	+		+
95451	N. R.	39 F.	Rheumatic heart disease, enlarged heart, mitral stenosis and insufficiency, auricular fibrillation. Class III.	+	+	+		
95498	M. S.	37 F.	Rheumatic heart disease, enlarged heart, mitral stenosis and insufficiency, regular sinus rhythm. Class IIb.	+	+	+	+	+
95553	A. H.	60 F.	Arteriosclerotic and hypertensive heart disease, enlarged heart, coronary sclerosis, probable coronary occlusion, regular sinus rhythm and premature ventricular contractions. Class III.	+	+	+	+	+

These clinical impressions were confirmed by observation of another twenty cases, but an effort was made to use more objective methods.

To find out what was typical of the mental picture in cardiac psychosis, it seemed to be necessary to take a large unselected series of cases of heart failure seen on the psychiatric medical service, reduce the material to a relatively uncomplicated series of cases of cardiac failure, and then tabulate the frequency of the leading mental symptoms. A list of one hundred such cases was prepared from the hospital records and the individual case records were then studied.

In this series of one hundred consecutive cases of heart disease in failure it was found that the cases fell into the following groups:

About one-third (thirty-seven subjects) were subjects sixty-five years of age or over with more or less advanced arteriosclerosis, whose mental symptoms could possibly be attributed to senile or arteriosclerotic changes. In the senile group confusion and gross memory defects were

especially prominent. The mental changes, however, were more or less chronic, and the mental picture did not change markedly with the fluctuations in the cardiac reserve. Many of these cases were undoubtedly senile psychoses in which the heart disease was merely a contributing factor.

About one-third (thirty-seven subjects) had other significant complications which could in themselves explain the psychosis. Of these, thirteen were hemiplegic or aphasic, and twelve were alcoholic. Two cases were complicated by pneumonia, while carcinoma and diabetes occurred in each of two other subjects. One patient had an unexplained temperature of 103° F. In four cases there were histories of chronic psychosis; two classified as schizophrenia, one as psychopathic personality, and one as manic-depressive psychosis.* One patient was excluded because the psychosis followed parturition, and in another case the patient died before he was adequately examined. A case of hyperthyroidism was also excluded.

In many of these subjects the psychosis may have been wholly or partly due to the heart failure, but for the purpose of this study it was thought best to eliminate them, so that a final group of only twenty-six subjects remained, all of whom were relatively uncomplicated cases of congestive heart failure. One must say relatively, because there is probably no really uncomplicated case of heart failure. There are for example always the etiologic factors to consider: hypertension, arteriosclerosis, rheumatism, syphilis, and chronic pulmonary emphysema; and these etiological agents are all likely to affect the function of organs other than the heart. Whenever there was no evidence of a central nervous system lesion, however, and no indication of a psychosis preceding the onset of heart failure, and when, moreover, the patient was less than sixty-five years of age and had no other complications likely to produce mental symptoms, the subject was included in this study. In a few of these subjects there was some evidence of kidney damage, subfebrile temperature, or a mild degree of anemia, and in one case there was a cystitis. It may be that these complications contributed to the development of the psychosis, but where they appeared relatively unimportant, the cases were included. It is noteworthy in any case that the age level of the series is so high, but it appeared in the course of the study that the clinical picture of cardiac psychosis in a young individual with uncomplicated rheumatic carditis did not differ in essentials from others in the group.

The findings in the remaining cases are recorded in Table II.

By reference to the table one can see that cardiac psychosis is characterized mainly by confusion, delusions of persecution, and anxiety.

*In two instances the presence of complications was discovered only after the original period of observation, by reference to State Hospital records. One was a case of chronic alcoholism, the other of long-standing manic-depressive episodes. In both cases the original diagnosis of cardiac psychosis was incorrect. Both patients recovered.

TABLE II

TWENTY-SIX CONSECUTIVE CASES OF CARDIAC PSYCHOSIS

NUMBER	NAME	AGE AND SEX	DIAGNOSIS	NO. DAYS OBSERVED	CONFUSED	APPREHENSIVE	DELUSIONS OF PERSECUTION	OVERTALKATIVE	CIRCUMSTANTIAL	OUTCOME
1118*	G. V.	15 M.	Active and inactive rheumatic heart disease, enlarged heart, mitral stenosis and insufficiency, sinus tachycardia. Class IIb.	12	+	+	+	+		Not traced.
169429*	J. J.	55 M.	Arteriosclerotic and hypertensive heart disease, enlarged heart, mitral stenosis and insufficiency, auricular fibrillation. Class III.	11	+				+	Died ten weeks later.
169783*	E. S.	53 M.	Arteriosclerotic and hypertensive heart disease, enlarged heart, auricular fibrillation. Class IIb—III.	15	+	+	+		+	Died three months later.
168835*	J. S.	59 M.	Arteriosclerotic and hypertensive heart disease, coronary sclerosis, enlarged heart. Class III.	10	+	+	+	+		Not traced.
94475*	C. R.	48 F.	Arteriosclerotic, hypertensive and syphilitic heart disease, enlarged heart, dilated aorta. Class IIb.	2	+		+			Died during observation.
94313*	I. H.	63 F.	Arteriosclerotic heart disease, fibrosis myocardii, auricular fibrillation. Class IIb.	12		+	+	+		Not traced.
94297*	M. G.	58 F.	Arteriosclerotic and hypertensive heart disease, enlarged heart, aortic and mitral stenosis. Class IIb.	4	+	+	+	+	+	Not traced.

*Cases marked by an asterisk were personally observed. The data in other cases are from hospital records.

TABLE II—CONT'D

167292*	B. L.	60 M.	Arteriosclerotic and hypertensive heart disease, enlarged heart, coronary sclerosis, fibrosis myocardii, auricular fibrillation. Class IIb.	8	+	+	+	+	+	Died during observation.
94828*	D. R.	41 F.	Active rheumatic heart disease, enlarged heart, mitral stenosis and insufficiency, sinus tachycardia. Class III.	20	+	+	+	+		Died six weeks later.
94906*	W. H.	40 F.	Rheumatic heart disease, enlarged heart, mitral insufficiency and stenosis, auricular fibrillation. Class IIb.	15	+	+	+		+	Died ten weeks later.
93345	M. S.	43 F.	Inactive rheumatic heart disease, enlarged heart, mitral stenosis and insufficiency, auricular fibrillation. Class III.	12	+	+	+	+	+	Died two months later.
93419	S. D.	59 F.	Arteriosclerotic and hypertensive heart disease, enlarged heart, dilated aorta. Class IIb.	10	+		+	+	+	Still psychotic two years later. Hypertensive.
94046	E. J.	44 F.	Syphilitic heart disease, enlarged heart, aortitis, aortic insufficiency, Austin Flint murmur. Class IIb—III.	5	+	+	+	+	+	Died eighteen months later.
168236	D. H.	54 M.	Arteriosclerotic and hypertensive heart disease, enlarged heart, coronary sclerosis. Class III.	40	+	+		+	+	Not traced.
102261	E. V.	36 F.	Rheumatic heart disease, enlarged heart, mitral stenosis, and insufficiency. Class IIb.	17	+	+	+	+		Died ten weeks later.
175797	G. M.	55 M.	Arteriosclerotic and hypertensive heart disease, enlarged heart. Class III.	6	+		+	+		Died during observation.
93135	H. W.	54 F.	Arteriosclerotic and hypertensive heart disease, enlarged heart, dilated aorta, auricular fibrillation. Class III.	25	+		+			Died two months later.
94321	M. W.	59 F.	Arteriosclerotic and hypertensive heart disease, enlarged heart, auricular fibrillation. Class III.	5	+	+	+	+	+	Died one month later.
166755	E. C.	63 M.	Arteriosclerotic heart disease, enlarged heart, coronary sclerosis, fibrosis myocardii, auricular fibrillation. Class III.	15	+		+			Died six weeks later.

TABLE II—CONT'D

NUMBER	NAME	AGE AND SEX	DIAGNOSIS	NO. DAYS OBSERVED	CONFUSED	APPREHENSIVE	DELUSIONS OF PERSECUTION	OVERTALKATIVE	CIRCUMSTANTIAL	OUTCOME
166140	S. F.	56 M.	Arteriosclerotic and hypertensive heart disease, enlarged heart. Class III.	22	+	+	+			Died five weeks later.
95231	S. G.	43 F.	Hypertensive heart disease, enlarged heart, paroxysmal auricular tachycardia. Class IIb.	7	+	+	+			Not traced.
94671	A. W.	50 F.	Syphilitic heart disease, enlarged heart, aortic stenosis and insufficiency, aortitis. Class III.	6	+	+	+	+	+	Died during observation.
93624	C. C.	58 F.	Hypertensive and arteriosclerotic heart disease, enlarged heart, aortic sclerosis and dilatation. Class IIb.	6	+	+	+	+		Not traced.
94136	A. C.	42 F.	Hypertensive heart disease, enlarged heart, sclerosis and dilatation of aorta, aortic insufficiency. Class IIb.	12	+	+		+		Improved. No cardiac failure.
165909	M. B.	62 M.	Arteriosclerotic and hypertensive heart disease, enlarged heart, coronary sclerosis, fibrosis myocardii, auricular fibrillation. Class IIb.	25	+	+	+			Bedridden, seriously ill and psychotic two years later.
			Number		25	20	23	17	12	
			Percentage		94%	77%	89%	65%	46%	
172152*	G. M.	61 M.	Arteriosclerotic and hypertensive (rheumatic?) heart disease, enlarged heart. Class III.	29	+	+	+	+	+	Died eighteen months later.

This tabulation of symptoms, however, has only a qualified significance. Patients who are merely somnolent and comatose are not as often sent to psychiatric hospitals as those who are excited and unmanageable, and the latter are more than likely to show symptoms of anxiety. With due allowance for this qualification, however, the prevalence of anxiety, confusion, and persecutory delusions in these cases is, nevertheless, striking. It will be instructive to compare these results with the findings of other authors.

ON THE HISTORY OF CARDIAC PSYCHOSIS

The early account of Corvisart has already been mentioned. There is a typical case discussed in Corvisart's book. In 1818 Nasse wrote of the prominence of anxiety in cardiac psychosis as of a well-known fact; but even Corvisart and Nasse appear to have had their predecessors. There are references in the writing of Morgagni and of Antonio Guiseppi Testa on the relation of the heart to madness,* but the literature grows less reliable the farther back it goes. Thus Pliny and Valerius Maximus reported the presence of a "cor hirsutium," "hairy heart" or heart with vegetations, in the Messenian Aristomenes, who had alone slain three hundred Lacedaemonians before he died, but this seems to be incompatible with our observations on the cardiac reserve of patients with psychosis.

The literature of the last century was much concerned with the relations between heart and brain, but both the observations and speculations reflect the spirit of an oversimplified materialism, and there was an undue emphasis on the presence of heart murmurs among the insane or of heart lesions at autopsies. The popular association of the heart with the emotions no doubt prepared the way for the promulgation of the theories. One finds, however, descriptions of unmistakable cases of cardiac psychosis in the early literature. Thus Stosch in 1836 gave an excellent description of a typical case, with the heart lesion confirmed by autopsy; the psychosis was marked by confusion, anxiety, and circumstantiality, whereby the patient "spoke continually and with excitement of the most trivial things."

Unfortunately, few authors limited their observations to psychoses associated with actual heart failure. Saucerotte in 1843 on the basis of seven observations (of which at least two were incorrectly diagnosed) was the first to relate definitely the mental changes to "cardiac crisis." Bergmann in 1844 wrote of "metatastic mania proceeding from the heart." Later a considerable number of cases were described. Mildner (1857) appears to have originated the unfounded theory that mitral disease produces depression and aortic disease excitement, and Ziehl in 1854 gave a vivid description of a patient with persecutory delu-

*In the sixteenth century, Amatus Lusitanus wrote on the relation of the heart to madness; later Daniel Sennert, Wepfer, Severinus, Greding, Lieutaud, William Cruikshank, and Soemmering all wrote of the influence of the heart on the brain, or described cardiac lesions in the insane.

sions who had attempted suicide "with an expression of the most awful anxiety on his face." An admirable detailed description of a similar case by Silbernick of Würzburg appeared in 1875. In Italy in 1869 Golgi reported a number of typical cases. In 1882 Lombroso declared that no alienist could any longer doubt the important influence of heart disease in provoking mental disorders. D'Astros (1881) revived Mildner's theory, called attention to the terrifying nocturnal hallucinations and emphasized the grave prognosis. The French literature of this period abounds in typical case histories.

In America in 1884, a Dr. Alice Bennett undertook to discover the incidence of heart disease among the insane and examined five hundred inmates of a women's asylum. She found forty cases of what she considered to be true cardiac psychosis and reported them. "I must ask your forbearance if these prove somewhat monotonous," she wrote, "for it is largely in this very fact that their interest resides." It appeared that the "form of mania with which heart disease was most constantly associated was that characterized in its beginning by hallucinations of hearing with fixed delusions of persecution and a mania of suspicion."

Mickle (1888) in the course of an elaborate study of heart disease associated with insanity cited the case of a porter in his own employ who died of rheumatic heart disease and who had developed a paranoid psychosis as the heart failure progressed.

Benjamin Ball of Paris wrote an excellent short account of cardiac psychosis with case reports in 1890, and descriptions of typical cases are found in papers by Armaingaud (1878), Duplaix (1882), Fauconneau (1890), Eichhorst (1898) and Telgmann (1899). Henry Head as a young house physician (1901) observed the occurrence of the symptom of fear among cardiacs and concluded that "there is no doubt that a state of fear can exist in which there is no fear of any particular object . . . but it is usually so closely mixed up with hallucinations or other manifestations that it becomes peculiarly difficult to investigate."

House (1905) classified the different kinds of mental change associated with heart disease. He emphasized "the state of fear or apprehensions, usually accompanied by more or less panic." "It will be found," he concluded, "that the symptom of fear is commonly found in all the subdivisions and classes." In a valuable study Ducros (1906) came to the same conclusion: cardiac patients are easily frightened and tend to develop delusions of persecution.

In 1909 Alfons Jakob wrote the most comprehensive study of circulatory psychosis that had yet appeared, founded on personal observations, and interpreted with caution and keen insight. Bonhoeffer (1910), the German authority on symptomatic psychoses, did not at first recognize any specific features in cardiac psychosis but later acknowledged the prevalence of anxiety and reported its presence in nine out of twelve cases.

J. I. France (1915) recognized the prevalence of anxiety in cardiac patients, and declared that this "emotional state, arising from a mechanical difficulty, resembles closely that arising from a psychic state, and the emotional state so caused may either remain vague and unexplained, or there may be induced hallucinations and delusions to explain it."

There have been other papers and case reports by Leendertz (1908) and Bolten (1930) in Holland; S. Wasserman of Vienna (1921); Riesman (1921), Hamburger (1923), Viko (1926) and Morris (1931) in America; Arsimoles (1910) and Urechia (1932) in France; and Massini (1924) and Jaquet (1922) in Switzerland; Targowla (1923), Leyser (1924), G. E. Störring (1934), Engel and Mentzinger (1934) in Germany; Castex and Vivaldo (1917) in the Argentine. The clinical pictures are almost invariably the same: confusion and anxiety, with delusions of persecution. Some other studies concerned with pathogenesis need not be mentioned here.

Some recent authors have put considerable emphasis on psychological factors and on the prepsychotic history. The view put forward in this paper is that the delusions of persecution are not essentially psychological in origin, but develop from the organic symptom of anxiety, and that the individual history of the patient is of no fundamental importance in the genesis of the anxiety. We are indebted to Freud for the recognition of this mechanism in the anxiety neuroses. In a remarkable essay written forty years ago he declared that the anxiety neurosis develops from a subjective state of physical tension; "the anxiety neurosis," he said, "has no psychic mechanism, but invariably influences the psychic life, so that anxious expectation, fears, and hypersensitivity to pain are among its many symptoms."* What follows is an application of this theory toward the understanding of cardiac psychosis.

DISCUSSION OF THE SYMPTOMS

Confusion and Anxiety.—The two key symptoms of cardiac psychosis seem to me to be the confusion and the anxiety.

Practically all of the patients showed varying degrees of confusion, especially at night. In the severe cases they appeared to be unable to orient themselves, or even to make accurate perceptions. In the milder cases they were unable to integrate their perceptions into orderly patterns.† The talk of these patients sounded fragmentary and it was very often difficult to grasp connections. The sensory misinterpretations (hal-

*Freud: "Über die Berechtigung von der Neurasthenie einen Symptomencomplex als 'Angstneurose' abzutrennen" (1895). Ges. Schriftem I, p. 306. We shall not here discuss the particular factors to which Freud attributed the state of anxiety in his cases: a state of anxiety can be induced in more than one way.

†According to this description, the confusion does not differ in essentials from what is sometimes called dissociation. I find it difficult to distinguish sharply between the two. Perhaps the underlying organic cause is the same, dissociation being but a milder and more chronic type of confusion. For a valuable discussion of confusion, see Hartmann and Schilder: Zur Klinik und Psychologie der Amentia. Zentr. f. d. g. Neurol u. Psychiat. 35: 356, 1924.

lucinations) and the false integrations (delusions) are thus closely related, and appear to have their common cause in some organic disturbance of the brain itself.

Twenty of twenty-six cases (77 per cent) showed clear evidence of anxiety, but the actual incidence is probably higher, and in none of the cases tabulated as negative could it be said that anxiety was actually absent. Anxiety, especially when associated with confusion, is a less striking symptom than a delusion and was therefore not always noted in the histories. More stoic patients could conceal their fear, even while admitting delusions of persecution, and in other cases the anxiety was inconstant. Some patients were at times in a state of mere anxious expectancy: they were not frightened, but they easily could be. One woman patient, for example, grew very frightened while the syringe was being prepared for a blood specimen and all but fainted when the specimen was taken. Other patients will jump at the sound of a closing door, or start when another patient moves his arm. They are hyperacute, or hyperresponsive, and ordinary sensations or events take on the proportions of a threat to them.* It is this which explains their distractibility. We are obliged to conclude that in cardiac psychosis the patients are not only frightened, but their susceptibility to fright is very much increased.

One may at first attribute the anxiety of the patients to their knowledge that they are seriously ill, or to the presence of hallucinations or delusions, but it is remarkable and significant that many of the most apprehensive patients did not realize that they were ill, and in many cases the anxiety was present while there were no delusions.† "I just feel frightened," a patient will say, "but I don't know why." The appearance and disappearance of the anxiety with the corresponding signs of heart failure indicated that the anxiety in these cases derived from a body state somehow involved in the process of heart failure.

The Delusions of Persecution.—Twenty-three of the twenty-six subjects (89 per cent) had delusions of persecution.‡

Patients with cardiac psychosis usually have hallucinations, especially at night, but these are generally vague and unorganized, and are easily forgotten. Patients often say, "It may have been a dream," and the hallucinations do in fact have dreamlike qualities: shadowy figures outside the window, chloroform under the bed, silver-colored figures on the ceiling, and the like. When imaginary sensations, or misinterpretations,

*Douty (1885) cited the case of a woman in terminal cardiac delirum who mistook the rumbling of a wheelbarrow for a terrible thunderstorm, and the sound of a water tap for the splashing of a huge waterfall.

†The theory that the patient is frightened by his own delusions, as Grandousier was frightened by his monstrous child Gargantua, is seductive, because it seems to blame the fear on some external influence. But to attribute the patient's fright to his frightful delusions is merely to beg the question. We would still have to ask: Why are the delusions frightful?

‡By way of comparison, delusions of persecution have been found to occur in 20 per cent of cases of manic-depressive psychosis, and 56 per cent of cases of schizophrenia, cf. K. M. Bowman and A. H. Raymond: A Statistical Study of Manic-Depressive Psychoses, Am. J. Psychiat. 11: 111, 1931.

are elaborated into more of a story, we speak of delusions. We must now ask ourselves: In what way does the sensation of anxiety contribute to the content of these delusions?

A simple answer suggests itself: The delusions, if they are to be compatible with the sensation of anxiety, must be threatening; they must, in other words, become delusions of persecution. A patient, for example, would develop a fear amounting to panic when one approached with a syringe for a blood specimen. If the patient happened not to be very confused at the time, he would say, "I feel afraid of the needle." If he was confused, he might mistake the syringe for a gun, and the doctor for a soldier. The result is a delusion of persecution. I think therefore that the delusions of persecution in these cases were a joint product of the anxiety and the confusion.

Anxiety is properly described as fear without a clearly conceived object. In contrast to ordinary fear it has at first no adequate motivation, and the conscious mind attempts to find it one.* One might say that the delusions of persecution were an attempt of the patient to explain his anxiety to himself. That his explanation was so absurd was due in turn to the element of confusion. Many patients were lucid but apprehensive during the day, but definitely confused at night: it was only during the night that these patients had real persecutory delusions. Occasionally a patient shows evidence of anxiety without confusion and without persecutory delusions, but with the relatively reasonable and justifiable fear of dying. If the anxiety were more constant and chronic and the confusion less pronounced, perhaps the setting for a chronic systematized paranoia would be complete. The lack of systematization in cardiac psychosis points to the relative acuteness of the mental changes.

Unmotivated depression is familiar to everybody, but the existence of unmotivated anxiety is less widely recognized. Except that we are dealing with a different mood, the mechanism described here is, however, essentially the same as that found in a depression: as long as the higher levels of consciousness or integration are intact, the patient will provide an apparently reasonable explanation for his mood; when the higher functions are disturbed as well, as they are for example in general paresis, delusions may merge with the depression to produce, let us say, absurd hypochondriacal complaints. One cannot, in other words, think a mood—one can only think a thought, but the nature of the thought will be more or less dependent on the underlying mood. When the underlying mood is anxiety, the specific fear that the patient expresses will proceed from his special predisposition or from his repertoire of

*" 'J'ai peur, disait un malade à M. Esquirol.' 'De quoi?' 'Je ne sais rien, mais j'ai peur'." (*Des maladies mentales*, 1838.) Cited by Griesinger.

favorite fears.* G. Stanley Hall has given a full account of the common fears of normal people in his *Study of Fears*, and Burton's *Anatomy of Melancholy* has a long catalogue of paranoid fears and phobias from classical literature. "Pacify them for the one," he wrote, "and they are instantly troubled with some other fear; always afraid of something, which they foolishly imagine or conceive to themselves, which never peradventure was, never can be, never likely will be; troubled in mind upon every small occasion, unquiet, still complaining, grieving, vexing, suspecting, grudging, discontent, and cannot be freed so long as their melancholy continues."†

Other Symptoms.—Seventeen of twenty-six patients (65 per cent) were overtalkative, and twelve out of twenty-six (46 per cent) were circumstantial. The talkativeness may be looked upon as a form of motor restlessness and should not be mistaken for euphoria, and the talk is rambling because the patient is confused. The patient dwells on details because they have become unduly important to him. It may be that the talk is importunate and querulous because the patient feels he needs to explain and justify himself to an unsympathetic observer. Not all patients are talkative, however, and some of the patients are so suspicious that they become unduly reticent.

Sometimes there is a bitter and aggressive reaction to the sensation of distress. The persecutory ideas are diffuse and correspond to the formula: "The whole world is against me."

Since the anxiety is often marked, the patient's delusions involve threats of bodily harm; the patient may attempt suicide or attack his supposed persecutors. It is often some such act that brings the patient to the psychiatric hospital.

Patients often complain of imaginary odors, "smoke in the room," "ether" or "chloroform," or simply "heavy air." A particularly common kind of dreamlike delusion is that of being covered with a cloth, or wet rag, or being "hit over the face with a towel." It may be that all such delusions are referable to the respiratory distress. Delusions of being moved about or rhythmically up and down may be vestibular in origin.‡ Rhythmic auditory hallucinations with repetition of a single word or syllable are also described by some patients. Death and murder are frequent subjects of delusions, though the patient may project the death or murder to another person. "There was a woman in the bed beside me dying of heart disease," one woman patient said, "and the doctors came and took her insides out, but next morning she was alive again." The theme of death and resurrection reappeared several times in different subjects.

*Roubinovitch (1895) was able to show that the delusional phobia which found expression during a cardiac psychosis was already present to a mild degree before the onset of heart failure.

†Part. I. Sect. III. Mem. I. Subs. II.

‡Cf. Schilder, Paul: The Vestibular Apparatus in Neurosis and Psychosis, J. Nerv. and Ment. Dis. 78: 1, 1933.

The psychological mechanisms here brought into play furnish interesting material for further study, but it suffices here to say that the content of the psychosis is modified on the one hand by the nature of the physical disease and on the other by the past experience of the patients. In other words, the psychosis, like a dream, reveals the patient and his complexes. The patient can talk and think only in terms of these experiences and complexes, for they are the only language he knows. But the *content* of the psychosis does not explain its *cause*, any more than the content of a dream explains the cause of dreaming.

THE DIAGNOSIS OF CARDIAC PSYCHOSIS

Some authors believe that only 1 per cent of patients with cardiac disease develop a psychosis. Lilienstein declares that fully 90 per cent of patients show some degree of mental change. A. G. Gibson found that 10 per cent of his cases showed major mental symptoms. Wyckoff* estimated that 8 per cent of the cases on his medical service at Bellevue showed mental symptoms.† Even when mental changes occur, an anxiety psychosis is by no means the rule, or even common, in advanced heart failure. Mild depression and somnolence may be more frequent, but they hardly require the special care of a psychiatric hospital. On the other hand, the occurrence in any particular case of the same clinical picture does not prove the presence of a cardiac psychosis. The present study gives no information on the specificity of the clinical picture described here since no other groups of organic psychoses were studied for comparison. It is not difficult, however, to find cases with a clinical picture differing in no essentials from those here described, perhaps even associated with dyspnea, but with no history or findings suggesting heart disease. My own impression is that the same clinical picture may occur elsewhere, but much less frequently and typically, and at any rate it is known that shock, hemorrhage, head injury, brain tumor, and a variety of drugs may all produce a combination of confusion and anxiety associated with persecutory delusions. A similar syndrome is produced by spontaneous hypoglycemia, and is relieved by a piece of candy. Wolff and Curran found that anxiety and persecutory delusions are almost a regular occurrence in a variety of symptomatic psychoses associated with conditions ranging from alcoholism and copper poisoning to carbuncle and malaria. Though it is probable that each of these agents tends to produce different mental pictures, there is always some overlapping and there are always some common features; but even the occasional occurrence of the same clinical picture in other diseases indicates that "cardiac" psychosis is due to something physi-

*Lecture notes for Bellevue medical students.

†Horner (1910) found that valve lesions were revealed at autopsy in a high proportion (21 per cent) of fatal cases of acute "dementia praecox." It is probable that many of these cases were cardiac psychoses.

ologically more fundamental than circulatory failure—perhaps anoxemia* or some other nutritional deficiency in the nerve cells—which may occur in a variety of diseases.

But even when the psychosis is associated with cardiac symptoms, there are several considerations that must be remembered in diagnosing cardiac psychosis. The first is that the heart disease and failure must themselves have some cause, and this etiologic factor may quite independently cause a psychosis. Syphilitic heart disease, for example, may be associated with general paresis, or arteriosclerotic heart disease with senile dementia. Similarly, the same acute infection which leads to myocardial damage and heart failure may independently cause a psychosis.

The second consideration is that sensations around the heart, especially cardiac pain, are peculiarly common in all kinds of psychoses. On the one hand, strong emotions react upon the heart, and on the other hand, both heart and brain are peculiarly sensitive to common noxae.† In diabetic ketosis and in hypoglycemic shock, for example, the patient will experience anxiety and complain of pain around the heart; while low oxygen pressure, to give another example, may produce both confusion and precordial pain.‡

Finally, cardiac or precordial sensations of various origin, even, says Wenckebach, an intercostal neuralgia, are especially likely to produce anxiety, whether as a specific visceral sensation or simply as a conditioned association, one cannot yet say. Stransky (1903) appears to be the first to have related the symptom of psychotic anxiety to an imaginary visceral sensation from the heart. Braun has written two stimulating but unconvincing books to support the claim that all anxiety comes from or through the heart. "All anxiety," to quote Fleming, "is a mild angina pectoris." But the transitory sensations produced by tachycardia, premature ventricular contraction, or an anginal attack are not usually associated with confusion and do not produce a psychosis.

The main criteria in diagnosis are the association of the psychosis with an episode of heart failure, the presence of a typical clinical picture, and the absence of complicating features.

---

*See Hitzenberger, Karl: Über Störungen des Bewusstseins bei Kreislaufkranken infolge Sauerstoffmangels, Wien. Klin. Wchnschr. 46: No. 28, 1933. Anxiety can be described in physiological terms as a state of hyperexcitability and hyperresponsiveness of the nervous apparatus. Anoxemia has been experimentally shown to induce such a state, cf., eg.: N. Morris: Anoxemia and the Increased Electrical Excitability of the Neuro-myone, Brit. J. Exper. Path. 3: 101, 1922; also Heinbecker and Bishop: Effect of Anoxemia, CO_2, and Lactic Acid on Electrical Phenomena of Myelinated and Unmyelinated Fibres of the Autonomic Nervous System, Am. J. Physiol. 96: 612, 1931.

†Cannon, W. B.: Stresses and Strains of Homeostasis, Am. J. Med. Sc. 189: No. 1, 1935.

‡Cf. Rothschild and Kissin: Production of Anginal Syndrome by Induced General Anoxemia, Am. Heart J. 8: 729, 1933: also McFarland, Ross A.: The Psychological Effects of Oxygen Deprivation (Anoxemia) on Human Behavior, Arch. of Psychology, No. 145, Dec., 1932.

COURSE AND PROGNOSIS

After the tabulation of our series of cases, it was noticed that practically all of the subjects had advanced heart failure and fell into the functional class specifications IIb and III of the American Heart Association. Subjects with only slightly diminished cardiac reserve almost never developed a psychosis. All of the patients had a degree of dyspnea sufficient to interfere seriously with ordinary activity, though not all of the patients showed dyspnea while at rest. One is entitled to conclude tentatively at least that the development of the psychosis is ordinarily associated with a considerable degree of dyspnea. Apparent exceptions to this rule proved to be cases of cerebral embolism, thrombosis, hemorrhage, or senile psychoses associated with heart disease. Practically all of the cases in the series developed the psychosis only after the heart failure had persisted for some time; in none of the cases did the psychosis precede the onset of failure. In most of the cases the psychosis survived the period of extreme or congestive failure by a few days or even weeks.*

No cases were observed in which the psychosis was static, or survived as a chronic psychosis after the cardiac failure was relieved.

Of the twenty-six patients listed in our table, seven could not be traced. Of the remaining nineteen, sixteen had died within the following two years, and three were still alive. Of these, two were in State Hospitals, one bedridden and seriously ill, the other up and about but still psychotic and with severe hypertension. A single patient was attending the cardiac clinic and was said to be improved. Of the sixteen known deaths, four had occurred within the period of observation and eight within three months after the period of observation.

The high mortality rate of this series indicates that the psychosis is a bad omen. It indicates a failure of the central nervous system, following upon and complicating the failure of the circulation. The elaborate physiological mechanism called into play to compensate for the deficiency of circulation has broken down, and the course thereafter is downhill.

SUMMARY AND CONCLUSIONS

We could not estimate the frequency of psychosis in heart failure (but it is generally admitted to be uncommon); nor did we try to explain the fundamental cause of the psychosis, which is still unknown. We have simply investigated some clinical features of the psychosis when it occurs. It was found to be mainly characterized by confusion, anxiety, and delusions of persecution, and the patients were often overtalkative

*This discrepancy between the period of psychosis and the period of extreme failure led to the erroneous belief that the psychosis was due to the resorption of the poisonous disintegration products of edema, rather than to the circulatory failure as such. This theory was advanced by Eichhorst forty years ago. There is, however, no relation between the absorption of the edema, as measured by loss of weight and increased diuresis, and the onset or duration of the psychosis.

and circumstantial. The development of a psychosis in the course of heart failure appears to be of grave prognostic significance, for of nineteen patients who could be traced, sixteen had died during, or within two years after, the period of observation.

In addition, the study of the psychosis led to several other conclusions: (1) that anxiety is a body state and can be provoked by physical disease, (2) that anxiety may induce delusions of persecution, and (3) the persecutory delusions are dependent on the degree of associated confusion. Cardiac psychosis thus directs attention to a fundamental psychological mechanism and furnishes at the same time a well-circumscribed condition in which the physical or physiological basis of anxiety can be studied.

This study was completed during the tenure of a research fellowship and was made possible by the kind cooperation of the Medical Department of Bellevue Psychiatric Hospital under Dr. Norman Jolliffe.

REFERENCES

Ameghino, A.: Existe una locura cardiaca? Rev. Asoc. méd. argent., Buenos Aires, Soc. de neurol. y psiquiat. 37: 163, 1924.

Armaingaud: Sur une relation pathogénique entres les maladies du coeur et l'hystérie chez l'homme. Mém. et bull. de la Soc. de méd. et de chir. de Bordeaux, 1878.

Arsimoles, L.: Troubles mentaux dans les maladies du coeur, Écho méd. du nord. 14: 189, 1910.

Auban and Beurnier: Délire de type maniaque chez un cardiaque, Toulouse méd., 2.s. 2: 216, 1909.

Arndt, R.: Über die haüfig zu beobachtende Verstärkung des Aortentones bei Geisteskranken, Deutsche med. Wchnschr. 8: 359, 1881.

Bagot, M.: Des complications cérébrales des affections cardiaques, Thèse de Paris, 1881.

Ball, B.: De la folie cardiaque, Médecine moderne 1: 557, 1890.

Benda, T.: Über den Zusammenhang von Herz und Geisteskrankheiten, Berlin, 1881.

Bennett, Alice: Relation of Heart Disease to Insanity, Tr. M. Soc. Pennsylvania 16: 103, 1884.

Bergmann: Mania metastatica von Herzen ausgehend, Allg. Zeit. f. Psychiat. 1: 574, 1844.

Bignon, J.: Des accidents cérébraux et en particulier des accidents psychiques dans les maladies chroniques du coeur, Paris, 1880.

Bolten, G. C.: Psychosen ten gevolge von Hartandoeningen, Geneesk. gids. 8: 362, 1930.

Bonhoeffer, K.: Die symptomatischen Psychosen, Leipzig and Vienna, 1910, F. Deuticke.

Braun, Ludwig: Herz und Psyche, Leipzig and Vienna, 1920, F. Deuticke.

Braun, Ludwig: Herz und Angst, Vienna, 1932, F. Deuticke.

Burman, J. W.: Heart Disease and Insanity, West Riding Lunatic Asylum Reports 3: 216, 1873.

Castex, M. R., and Vivaldo, J. C.: Los trastornos mentales en los cardiacos, Prensa med. argent. 3: 317, 1916-17.

Coombs, C. F.: Mental Disorder in Cardiac Disease, J. Ment. Sc. 74: 250, 1928.

Corvisart, Jean-Nicolas: Essai sur les maladies et les lésions organiques du coeur, Paris, 1806, Migneret.

Curtin, R. G.: The Delirium Noticed in Cardiac Disease, Philadelphia Hosp. Rep. 6: 10, 1905.

D'Astros, L.: Étude sur l'état mental et les troubles psychiques des cardiaques, Thèse de Paris, 1881.

Douty, J. Harrington: The Mental Symptoms of Aortic Regurgitation: With a Summary of the Notes on Fourteen Cases, Lancet 2: 336, 1885.

Ducros, Marcel: Recherches sur la valeur des troubles psychiques dans maladies du coeur, Paris Thèses, 1906-07, No. 17.
Duplaix: Troubles psychiques, hallucinations dans un cas d'insuffisance tricuspide, Encéphale 2: 287, 1882.
Eichhorst, N.: Toxämische Delirien bei Herzkranken, Deutsche med. Wchnschr. 24: 389, 1898.
Engel, R., and Mentzingen, A. von: Psychotische Zustandsbilder und cerebrale Herdsymptome bei dekompensierten Herzkranken, Deutsches Arch. f. klin. Med. 176: 163, 1933-34.
Fabre, Augustin: La folie dans les affections cardiaques, from "Les relations pathogéniques des troubles nerveux," Paris, 1880, V. A. Delahaye.
Fauconneau, J.: De la folie d'origin cardiaque ou des troubles psychiques consecutifs aux maladies du coeur, Thèse de Paris, 1890.
Felberbaum, D., and Finesilver, B.: Cerebral Manifestations of Heart Disease, M. J. & Rec. 129: 247, 1929.
Fiessinger, C.: La psychologie du cardiaque, Rev. de l'hypnot. et psychol. physiol. 17: 303, 1902-03.
France, J. I.: Some Observations on the Nervous and Mental Symptoms of Heart Disease, J. A. M. A. 64: 652, 1915.
Gibson, A. G.: Mental Changes in Heart Disease, J. Ment. Sc. 76: 632, 1930.
Hamburger, W. W.: Acute Cardiac Psychoses: Analysis of the Toxic and Circulatory Factors in Five Cases of Acute Confusion, Med. Clin. North America 7: 465, 1923.
Head, Henry: Certain Mental Changes That Accompany Visceral Disease, Brain 24: 345, 1901.
Herz, M.: Die Angst der Herzkranken, Prag. med. Wchnschr. 25: 271, 1910.
Hirtz, Lucien: De quelques manifestations cérébrales dans les affections cardiaques, Thèse de Paris, 1877.
Horner, A. A., Jr.: Incidence of Heart Disease in Acute Psychoses, Boston M. & S. J. 163: 200, 1910.
House, W.: The Psychoses of Heart Disease, J. A. M. A. 45: 1306, 1905.
Jakob, A.: Zur Symptomatologie, Pathogenese und pathologischen Anatomie der "Kreislaufpsychosen," J. f. Psychol. u. Neurol. 14: 209; and 15: 99, 1909.
Jaquet, A.: Über nervöse und psychische Störungen bei Herzkranken, Schweiz. med. Wchnschr. 52: 245, 1922.
Kiernan, J. C.: Insanity and Cardiac Disease, Am. J. Neurol. & Psychiat. 3: 32, 1884.
Klingmann, T., and Millett, M. S.: Significance of Circulatory Disturbance in Certain Psychoses After Fourth Decade of Life, J. Michigan M. Soc. 31: 694, 1932.
Krisch, Hans: Die Symptomatischen Psychosen und ihre Differentialdiagnose, Berlin, 1920, Karger.
Leendertz, P. P.: Intoxicatie psychose bij hartlijden, Psychiat. en Neurol. Bl. Amst. 12: 530, 1908.
Leyser, E. P.: Herzkrankheiten und Psychosen; eine klinische Studie, Abhand. a. d. Neurol. (etc.), Berlin, 1924, Heft 25, 7.
Lilienstein: Psychoneurosen bei Herzkrankheiten, Arch. f. Psychiat. 52: 954, 1913.
Limbo: Contribution à l'étude des encéphalopathies d'origine cardiaque, Thèse de Paris, 1878.
Lombroso, C., and Ferri, E.: Su A. Faella e sugli osteomi e le cardiopatie negli alienati, Arch. di psichiat. etc. 3: 118, 1882.
Malherbe, A.: Folie; insuffisance aortique; hypertrophie du coeur; mort subite, Franç. méd. 14: 301, 1867.
Massini, R.: Über Delirien bei Herzkranken, Schweiz. med. Wchnschr. 54: 397, 1924.
Matsuoka, R.: Über die psychischen Störungen bei den Herzkrankheiten, Mitt. a. d. med. Akad. zu Kioto 11: 308, 1934.
Mickle, W. J.: Goulstonian Lectures for 1888: On Insanity in Its Relation to Cardiac and Aortic Disease and Phthisis, Brit. M. J. 1: 503 and 575, 1888.
Mickle, W. J.: Aortic Aneurysms and Insanity, Brain 12: 117, 1889.
Mildner, Emanuel: Aus d. kk. Irrenanstalt in Wien, Beitr. z. Monatsr. f. d. Monat April, Wien. med. Wchnschr., Nos. 46 and 48, 1857.
Moersch, F. P.: Nervous and Mental Phenomena Associated With Paroxysmal Tachycardia, Brain 53: 244, 1930.

Morris, N.: Mental Concomitants of Heart Disease, U. S. Vet. Bur. Med. Bull. 7: 651, 1931.
Mouisset, F., and Gaté, J.: Troubles psychiques, hystéro-épileptiques chez une cardiaque, Rev. de méd. 32: 428, 1912.
Muller, L. R.: Über die Beziehungen von seelischen Empfindungen zu Herzstörungen, München. med. Wchnschr. 53: 14, 1906.
Murrati, E.: Des troubles mentaux dans l'asytolie, Thèse de Paris, 1880.
Mut, Antonio: La Angustia cardiaca y su Tratamiento, Revista iberoamer. de ciencias médicas. 9: 60, 1934.
Nasse, Friedrich: Von der psychischen Beziehung des Herzens, Ztschr. f. psychische Aerzte 1: 49, 1818.
Parant, Victor: La folie chez les cardiaques, Ann. méd.-psychol. 7s. 9: 419, 1889.
Pelnar, J.: Troubles psychiques au cours des maladies du coeur, Cong. intern. de med. C., 1903. Madrid, sect. de path. int. 14: 586, 1904.
Riesman, D.: Acute Psychoses Arising During the Course of Heart Disease, Am. J. M. Sc. 161: 157, 1921.
Roubinovitch: A propos des phobies dans un cas d'insuffisance mitrale. Ann. méd.-psychol. 8s. 2: 106, 1895.
Roulland, A.: Des folies dites cardiaques, Poitou méd. 4: 145, 1890.
Saathoff, L.: Herzkrankheit und Psychose, München. med. Wchnschr. 57: 509, 1919.
Satterthwaite, T. E.: Psychopathies and Neuropathies of Cardiovascular Diseases, New York M. J. 111: 617, 1920.
Saucerotte: De l'influence des maladies du coeur sur les facultés intellectuelles et morales de l'homme, Ann. méd.-psychol. 4: 173, 1843.
Silbernick, Kadisch: Ueber Delirien bei Herzkranken, Würzburg, 1875.
Störring, G. E.: Zur Psychopathologie und Klinik der Angstzustände, Berlin, 1934, S. Karger.
Stosch: Manie in Folge eines organischen Herzleidens, Wchnschr. f. d. ges. Heilk., Berl., p. 481, 1836.
Stransky, E.: Zur Klinik und Pathogenese gewisser Angstpsychosen, Monatschr. f. Psychiat. u. Neurol. 14: 128, 1903.
Strooman, G.: Über die psychotischen Störungen bei dekompensierten Herzkrankheiten, speziell über die Zusammenhänge mit der therapeutischen Entwasserung, Nervenarzt 3: 396, 1930.
Targowla, R.: Folie cardiaque et insuffisance ventriculaire gauche, Bull. et mém. Soc. méd. d. hôp. de Paris 3s. 47: 615, 1923.
Telgmann, J.: Toxämische Delirien bei Herzkranken, Deutsch. med. Wchnschr. 25: 305, 1899.
Theisen, A. C.: Über psychische Störungen bei Herzkranken, Kiel, 1916.
Urechia, C. I.: A propos de la psychose cardiaque, Arch. internat. de neurol. 51: 473, 1932.
Van Lier, J. L.: Mental Disease and Heart, Nederl. tijdsch. v. geneesk. 2: 2661, 1925 (Abst. J. A. M. A. 86: 660, 1926).
Viko, L. E.: Cardiac Neurosis Associated With Rheumatic Valvular Heart Disease, Am. Heart J. 1: 539, 1926.
Vorobyeff, V.: O nervenîkh razstroîstvakh pri serdechnîkh bolienznyakh. (Nervous Disturbances in Cardiac Diseases.) French abstract in Cong. internat. de med., 1897, Moscow, III. sect. 5: 295, 1899.
Wasserman, S.: Zur Entstehungsweise der Kreislaufpsychosen. Wien. Arch. f. inn. Med. 18: 449, 1929.
Wasserman, S.: Über psychische Störungen in Verbindung mit dem Cheyne-Stokeschen Psychose, Med. Klin. 17: 814, 1921.
Weber, A. N.: Über psychische Störungen bei Herzkranken, Jena, 1901.
Weiss, S.: Interaction Between Emotional States and Cardiovascular System in Health and in Disease, Libmann Anniv. Vol. 3: 1181, 1932.
Wenckebach, K. F.: Herzkranke, die es nicht sind, Wien. med. Wchnschr. 84: 621, 650, 1934.
Witkowski, L.: Über Herzleiden bei Geisteskranken, Allg. Ztschr. f. Psychiat. 32: 347, 1875.
Wolff, N. G., and Curran, D.: Nature of Delirium and Allied States, Arch. of Neurol. and Psychiat. 33: 1175, 1935.

THE MECHANISM OF IMPAIRED AURICULOVENTRICULAR CONDUCTION IN ACUTE RHEUMATIC FEVER*

HOWARD G. BRUENN, M.D.
NEW YORK, N. Y.

IMPAIRMENT of auriculoventricular conduction is common during the course of acute rheumatic fever. Its importance is accentuated by the present-day concept that it indicates active rheumatic carditis.[1] According to various authors,[1-4] the incidence of conduction defects in this disease varies from approximately 27 to 87 per cent in the different series reported. This wide range is probably due, in part, to the varying frequency with which electrocardiograms are taken and, in part, to the severity of the cases studied. According to figures given in the literature, approximately from 28 to 30 per cent of all cases of acute rheumatic fever observed in a general medical service show some degree of heart-block during the course of the disease.

Three theories have been advanced in explanation of this disturbance. The first, or anatomical, is the most commonly accepted. It implies the presence of structural changes involving the auricles and the bundle of His, in the form of acute inflammation, vascular changes, edema, and fibrosis. The second theory ascribes the abnormality to a direct effect of toxins on the conduction system. According to a third hypothesis, there is a heightened vagal action or an increased response to vagal control under the influence of the toxins of the infection.

In studying serial electrocardiograms in a case of acute rheumatic fever with impairment of auriculoventricular conduction, the transient character of the block is impressive. It usually makes its appearance at the height of the activity of the disease. In most cases, the conduction defect will subside within a few days or several weeks; in the majority of cases it tends eventually to return to within normal limits. It is the purpose of the study reported in this paper to attempt to analyze the mechanism of this disturbance.

The study is based on twenty-two patients with acute rheumatic fever who were admitted to the wards of the Medical Service of the Presbyterian Hospital during the last three years. There were nine males and thirteen females. The average age was 25.3 years, with a range of from 9 to 42 years. In every case, the diagnosis of acute rheumatic fever was

*From the Department of Medicine, College of Physicians and Surgeons, Columbia University, and the Presbyterian Hospital.

This investigation was aided by a grant from the Josiah Macy, Jr., Foundation.

A preliminary report of this work has already been published. See Bruenn, H.G.: Effect of Atropine on Impaired Auriculoventricular Conduction in Rheumatic Fever. Proc. Soc. Exper. Biol. & Med. 32: 562, 1934.

made on ample clinical and laboratory evidence, i.e., polyarthritis, which subsided rapidly with salicylate therapy; high sedimentation rate; leucocytosis; and fever. Twenty of the patients showed evidence of cardiac damage by the presence of valvular defects. Congestive heart failure was not present in any. Each case showed impairment of auriculoventricular conduction in the electrocardiogram. The degree of block varied from prolongation of the P-R interval above 0.2 sec. to incomplete heart-block. None of the patients had received digitalis or quinidine. Salicylates were being administered to over half of the cases at the time of the experiments. In several cases observations were made before and after salicylate therapy.

The behavior of the conduction times in these patients, and in a control group of seven individuals of comparable age without evidence of heart disease, and presenting normal electrocardiograms, was studied after the intravenous injection of atropine or the subcutaneous injection of epinephrine. Two control electrocardiograms were taken, one hour apart. Further records were then made at intervals of from one to four minutes during the periods of observation.

Atropine.—It has been shown that relatively large amounts of atropine must be administered in order to produce paralysis of the terminals of the vagus nerves in the heart.[5] Enough of the drug was given to these patients to produce dryness of the mouth in all cases; pupillary dilatation and flushing of the skin occurred occasionally, but no undue subjective discomfort was induced. It was found that from 1.5 to 3 mg. of atropine sulphate injected intravenously sufficed to produce these symptoms. The maximum effect of the drug occurred during the first fifteen minutes after the injection. In a number of cases, observations were continued over a period of six hours; at the end of this time the ventricular rate and the auriculoventricular conduction time had returned approximately to their control levels. In every case the action of the drug had disappeared completely in the course of twenty-four hours. A series of thirty observations was made on the group of twenty-two rheumatic subjects.

The intravenous administration of atropine sulphate to individuals without evidence of heart disease is characterized by an acceleration of the ventricular rate within the first minute after injection. This acceleration, in the control group, was found to be 42 beats per minute on the average. The range was from 20 to 57 beats per minute. The conduction time before atropinization varied from 0.13 to 0.17 sec., with an average of 0.147 sec. Following the administration of the drug, the average decrease in conduction time was found to be 0.014 sec., with a range of 0.01 to 0.03 sec. (Table I).

In 20 of the 22 patients comprising the rheumatic group (91 per cent), shortening of the conduction time exceeding the limits set by the

TABLE I

EFFECT OF INTRAVENOUS INJECTION OF ATROPINE SULPHATE UPON VENTRICULAR RATE AND AURICULOVENTRICULAR CONDUCTION TIME IN PATIENTS WITHOUT HEART DISEASE*

CASE	AGE	SEX	CONTROL		AFTER ATROPINE INJECTION				CHANGE AFTER ATROPINE	
			VENTRICULAR RATE	P-R INTERVAL (SEC.)	AMOUNT GIVEN (MG.)	TIME OF MAXIMUM CHANGE (MIN.)	VENTRICULAR RATE	P-R INTERVAL (SEC.)	VENTRICULAR RATE	P-R INTERVAL (SEC.)
1	23	F	65	0.15	2.0	10	122	0.14	57	0.01
2	13	M	90	0.13	1.5	5	140	0.12	50	0.01
3	36	M	75	0.17	2.0	10	100	0.16	25	0.01
4	35	M	110	0.13	1.8	1	150	0.11	40	0.02
5	13	M	105	0.13	1.5	6	140	0.12	35	0.01
6	25	M	75	0.17	2.0	10	100	0.16	25	0.01
7	35	M	112	0.14	1.8	5	145	0.11	33	0.03
Average	24.3		90.3	0.147					38	0.014

*None of these patients received aspirin.

control group was noted after atropinization. The decrease in auriculo-ventricular conduction varied from 0.04 to 0.17 sec., with an average of 0.07 sec. A typical protocol is given in Table II.

TABLE II

EFFECT OF EXERCISE AND INTRAVENOUS INJECTION OF ATROPINE SULPHATE IN A PATIENT WITH ACUTE RHEUMATIC FEVER

A. S., Female, Aged 25 years. Mitral Stenosis and Insufficiency. U. H. 450891

DATE 1935		TIME	VENTRICULAR RATE	P-R INTERVAL (SEC.)	REMARKS
April 27		10:30	90	0.22	
April 29		11:10	90	0.24-0.25	
May 2		10:25	80	0.24	
May 3	*Control*	9:20	90	0.23	
	Control	10:14	102	0.23	Exercise*
		10:16	105	0.21-0.23	
		10:17	90	0.24	
		10:19	90	0.24	
		10:21	95	0.23	
		10:26	86	0.24	
		10:31	85	0.24	
		10:46	88	0.25	
		11:16	90	0.24	
		11:43			Atropine 1.5 mg.
		11:44	105	0.18	
		11:46	110	0.18	
		11:48	115	0.18	
		11:53	110	0.17	
		11:55			Mouth dry, face flushed
		11:58	110	0.18	
		12:13	110	0.20	
		12:43	105	0.22	
		1:43	85	0.23	
		2:43	80	0.24	
		3:43	65	0.25	
		4:43	58	0.25	
May 4		10:20	90	0.24	
May 13		2:25	70	0.22	
May 20		10:25	70	0.20	

*Exercise consisted of sitting up and lying back in bed fifty times within two minutes.

In general, it was found that the greater the degree of block before giving atropine, the greater the decrease of the P-R interval following injection of the drug.

The change in ventricular rate ranged from −5 to +65 beats per minute, with an average acceleration of 26.4 beats per minute. There was no uniformly consistent relationship between the degree of acceleration of rate and the extent of shortening of the conduction time. In one case an increase of 50 beats per minute was accompanied by a decrease of only 0.04 sec. in conduction time. In another instance there was a decrease of 5 beats in ventricular rate following injection of atropine, associated with a decrease of 0.17 sec. in the P-R interval. The latter case is illustrated (Table III) in order to show the complete independence of these two factors from each other under the given experimental conditions.

TABLE III

INTRAVENOUS INJECTION OF ATROPINE SULPHATE IN A PATIENT WITH ACUTE RHEUMATIC FEVER. MARKED DECREASE IN AURICULOVENTRICULAR CONDUCTION TIME WITH SLOWING OF VENTRICULAR RATE

G. W., Female, Aged 23 Years. Mitral Stenosis and Insufficiency. U. H. 354940

DATE 1936		TIME	VENTRICULAR RATE	P-R INTERVAL (SEC.)	REMARKS
May 19	*Control*	10:59	88	0.33	
	Control	2:17	105	0.33	
		2:18			Atropine 2 mg.
		2:19	100	0.16	
		2:22	102	0.16	
		2:24	106	0.16	
		2:29	110	0.16	Mouth dry
		2:34	100	0.17	
		2:45			Mouth dry
		2:49	103	*	
		3:19	95	0.29	
		4:19	76	0.33	
May 20		9:55	95	0.17-0.37	
May 21		11:20	75	0.33	
May 22		10:00	90	0.29	
May 28		2:40	70	0.16	
June 1		11:23	75	0.15	

*Prolonged conduction; P-waves superimposed on the T-waves.

In two patients the degree of block was unaffected by atropine. One died suddenly in another hospital six weeks after our observations were made. The other has been followed for almost a year, during which the auriculoventricular conduction time has been persistently prolonged, probably due to fibrosis of the junctional tissues resulting from rheumatic lesions. In nineteen of the cases in which atropine was effective in reducing the degree of block, normal auriculoventricular conduction appeared from a few days to a few months subsequent to the experiment.

Three cases, in addition to impairment of auriculoventricular conduction, showed delay in intraventricular conduction time. Atropine had no effect on this disturbance.

In fifteen patients receiving aspirin at the time of study, nineteen observations were made (Table IV). When compared with the group of seven patients who had received no aspirin (Table V), it was found that the only essential difference was in the initial ventricular rate and its degree of acceleration following the injection of atropine. While the initial ventricular rates in the group which had not received aspirin were higher, on the average, than in the group which had (100.6 beats per minute as compared with 82), the average initial P-R intervals were practically identical (0.238 and 0.245 sec.). Following the injection of atropine, the average decrease in auriculoventricular conduction in the untreated group was 0.072 sec., with an average maximum acceleration in the ventricular rate of 33.7 beats per minute. The average decrease in the P-R interval of the group receiving aspirin was found to be 0.07 sec., with an average increase in the ventricular rate of 23.6 beats per minute.

TABLE IV

EFFECT OF INTRAVENOUS INJECTION OF ATROPINE SULPHATE UPON THE AURICULOVENTRICULAR CONDUCTION TIME IN PATIENTS WITH ACUTE RHEUMATIC FEVER WHILE RECEIVING ASPIRIN

NAME	AGE	SEX	CONTROL		AFTER ATROPINE INJECTION				CHANGE AFTER ATROPINE		SEDIMENTATION RATE
							MAXIMUM CHANGE				
			VENTRICULAR RATE	P-R INTERVAL (SEC.)	DOSE OF ATROPINE (MG.)	TIME OF MAXIMUM CHANGE (MIN.)	VENTRICULAR RATE	P-R INTERVAL (SEC.)	VENTRICULAR RATE	P-R INTERVAL (SEC.)	
I. M.	20	F	65	0.22	1.8	15	120	0.14	55	0.06	76
J. S.	25	M	80	0.22	1.5	3	95	0.18	15	0.04	50
			70	0.24	2.0	8	90	0.18	20	0.06	48
			75	0.22	1.8	1	90	0.17	15	0.05	23
J. W.	13	F	80	0.24	1.8	15	100	0.17	20	0.07	50
J. F.	41	M	85	0.28	2.0	1	100	0.22	15	0.06	70
			80	0.25	2.4	4	85	0.19	5	0.06	--
			70	0.22	2.4	4	90	0.16	20	0.06	70
L. S.	38	F	90	0.24	2.0	3	105	0.18	15	0.06	130
S. E.	40	M	70	0.23	2.0	1	100	0.18	30	0.05	--
H. L.	35	F	90	0.21	2.0	2	135	0.16	45	0.05	35
M. C.	28	F	85	0.32	2.0	3	116	0.20	31	0.12	50
J. H.	15	F	90	0.22	1.5	1	110	0.17	20	0.05	--
A. S.	25	F	90	0.24	1.5	10	110	0.17	20	0.07	27
A. C.	9	M	108	0.23	1.0	5	135	0.15	27	0.08	--
A. S.	34	F	75	0.28	2.0	7	110	0.20	35	0.08	37
G. W.	23	F	105	0.33	2.0	1	100	0.16	-5	0.17	70
L. C.	20	F	70	0.24	2.0	4	105	0.18	35	0.06	85
G. P.	15	F	100	0.23	1.8	10	130	0.16	30	0.07	130
Average	25.4			0.245				0.175	23.6	0.07	

TABLE V

EFFECT OF INTRAVENOUS INJECTION OF ATROPINE SULPHATE UPON THE AURICULOVENTRICULAR CONDUCTION TIME IN PATIENTS WITH ACUTE RHEUMATIC FEVER NOT RECEIVING ASPIRIN

NAME	AGE	SEX	CONTROL		AFTER ATROPINE INJECTION				CHANGE AFTER ATROPINE		SEDIMENTATION RATE
			VENTRICULAR RATE	P-R INTERVAL (SEC.)	DOSE OF ATROPINE (MG.)	TIME OF MAXIMUM CHANGE (MIN.)	MAXIMUM CHANGE				
							VENTRICULAR RATE	P-R INTERVAL (SEC.)	VENTRICULAR RATE	P-R INTERVAL (SEC.)	
C. L.	13	M	50	0.33	2.0*	10	75	0.23	25	0.10	60
H. B.	20	M	105	0.20	2.0	1	150	0.13	45	0.07	18
J. D.	13	M	125	0.20	1.5	7	165	0.14	40	0.06	57
			140	0.24	1.5	1	165	0.19	25	0.05	57
			95	0.22	0.5	3	145	0.17	50	0.05	--
M. C.	28	F	95	0.20	2.0	15	160	0.12	65	0.08	--
J. H.	15	F	125	0.23	1.5	3	135	0.16	10	0.07	--
B. B.	42	M	70	0.24	2.0	10	85	0.20	15	0.04	--
E. F.	38	F	100	0.28	1.5	10	128	0.15	28	0.13	--
Average	24.1		100.6	0.238			134.2	0.167	33.7	0.072	

*Intramuscular injection of the drug.

Thus, while the initial ventricular rate was higher in the group which did not receive aspirin, the increase which followed atropinization was also greater, by 20 per cent, than in the group of patients who had been given aspirin. The change in auriculoventricular conduction was the same for both groups. It would seem, therefore, that the administration of aspirin to this group of patients with acute rheumatic fever tended (1) to lower the cardiac rate; (2) to diminish the degree of response of the ventricular rate to atropinization. There was no apparent effect upon auriculoventricular conduction.

Influence of Emotion.—In all cases control electrocardiograms were taken about one hour prior to the start of the experiment. These tracings were developed and read in order to be sure of the presence of an auriculoventricular conduction defect. Second control electrocardiograms were taken just before the injection of atropine sulphate. In most of the cases, the explanation of what was being done, as well as the actual performance of the procedure, was unattended by any subjective discomfort. Three individuals, however, manifested some degree of fear and anxiety, either by tears or vocal protests. The second control electrocardiograms, when taken on these patients, showed marked decrease in auriculoventricular conduction, with little or no change in ventricular

TABLE VI

EFFECT OF EMOTION UPON THE AURICULOVENTRICULAR CONDUCTION TIME IN A PATIENT WITH ACUTE RHEUMATIC FEVER

E. F., Female, Aged 38 Years. Mitral Stenosis and Insufficiency. U. H. 444414

DATE 1935		TIME	VENTRICULAR RATE	P-R INTERVAL (SEC.)	REMARKS
March 9		9:50	90	0.16-0.32	
March 30		10:05	95	0.27	
April 1		11:10	115	0.27	
April 3	*Control*	9:58	100	0.28	Patient quite apprehensive when procedure was explained to her
	Control	10:50	95	0.16	
		10:55			Atropine 1.5 mg. intravenously
		10:56	128	0.14	
		11:00	118	0.14	
		11:05	115	0.13	
		11:10	110	0.14	
		11.12			Mouth dry
		11:25	118	0.14	
		11:55	100	0.15	
		12:55	108	0.14	
		1:55	100	0.15	
		2:55	100	0.15	
		3:55	98	0.18	
		4:55	100	0.28	
April 4		9:48	100	0.28	
April 5		10:50	96	0.28	
April 17		11:35	90	0.18	
April 25		10:50	80	0.17	

rates. Atropine was then injected in the usual way, and a further decrease in the P-R interval was obtained. In Table VI is given one of these protocols.

Epinephrine.—It seemed possible that the changes in auriculoventricular conduction which occurred during the period of emotional tension might be due to depression of the vagal influence by excitation of the sympathetic nerves to the heart. In an effort to reproduce this effect, epinephrine, in varying doses, was administered subcutaneously to five patients with acute rheumatic fever who showed a conduction defect by the electrocardiogram (Table VII). In all of these cases the prolonged

TABLE VII

EFFECT OF THE SUBCUTANEOUS INJECTION OF EPINEPHRINE HYDROCHLORIDE (1:1000) UPON THE AURICULOVENTRICULAR CONDUCTION TIME IN PATIENTS WITHOUT HEART DISEASE

NAME	DATE (1936)	TIME	AGE	SEX	CONTROL		ADRENALIN GIVEN (MIL.)	TIME AFTER INJECTION (MIN.)	MAXIMUM CHANGE	
					VENTRICULAR RATE	P-R INTERVAL (SEC.)			VENTRICULAR RATE	P-R INTERVAL (SEC.)
M. J.	June 9		35	F	100	0.13	0.5	8	+20	-0.03
H. A.	July 9	2:25	23	M	85	0.15	0.5	10	+ 8	0.00
		2:47			90	0.15	0.5	5	+ 2	0.00
W. B.	July 8	2:16	24	M	70	0.14	0.5	3	+ 5	-0.01
		2:39			72	0.14	1.0	20	+12	-0.02
M. F.	June 9	2:48	35	F	75	0.16	0.5	5	+18	-0.04
		3:05			75	0.15	1.0	4	+25	-0.08*

*Ectopic auricular rhythm.

P-R intervals were shown to be susceptible to atropine. A control group of four individuals who showed no evidence of heart disease or electrocardiographic abnormalities was similarly treated (Table VIII).

As can be seen, the injection of relatively small doses of epinephrine produced a slight acceleration of the ventricular rate, which averaged 11.2 beats per minute in the rheumatic, as compared with 12.8 in the control group. The change in the P-R interval was also practically identical in the two groups, 0.018 sec., in the rheumatic and 0.02 sec., in the control group.

When a second dose of epinephrine was administered subcutaneously 20 minutes after the first injection, wide variations in the effect on rate and conduction were observed. In the control group ventricular acceleration was again obtained, but not to a marked degree, averaging 13 beats to the minute. The decrease in conduction averaged 0.03 sec. with a range of 0.00 to 0.07 sec. In the case which showed the maximum fall, there was a change from the regular sinus mechanism to an ectopic auricular rhythm. In the rheumatic group, two cases showed a decrease

TABLE VIII

EFFECT OF EPINEPHRINE HYDROCHLORIDE (1:1000), INJECTED SUBCUTANEOUSLY, UPON THE AURICULOVENTRICULAR CONDUCTION TIME IN PATIENTS WITH RHEUMATIC HEART DISEASE

NAME	DATE (1936)	TIME	AGE	SEX	CONTROL		ADRENALIN (MIL.)	TIME AFTER INJECTION (MIN.)	MAXIMUM CHANGE		CHANGE IN SYSTOLIC B.P. FROM CONTROL (MM. HG)
					VENTRICULAR RATE	P-R INTERVAL (SEC.)			VENTRICULAR RATE	P-R INTERVAL (SEC.)	
A. C.	June 22	3:40	9	M	118	0.25	0.3	3	+ 7	-0.02	
		4:03			115	0.24	0.5	10	+20	-0.03	
A. S.	April 23	10:39	34	F	72	0.23	0.5	21	+18	0.00	- 6
		11:05				0.23	1.0	7	-25	*	+54
G. W.	May 19	11:00	23	F	88	0.33	1.0	15	+12	-0.04	+10
		11:17			100	0.29	1.0	8	0	-0.11†	+26
L. C.	Jan. 16	3:26	20	F	70	0.24	0.5	4	+12	-0.01	+15
	Jan. 18	9:10			75	0.21	1.0	4		*	+54
G. P.	July 29	11:19	15	F	75	0.24	0.5	18	+ 7	-0.02	+ 6
		11:38			82	0.22	0.5	16	+ 8	+0.06	+52

*Complete heart-block.
†Ectopic auricular rhythm.

in the P-R interval. In one, with a shortening of 0.03 sec., the ventricular rate increased 20 beats. In the second, with a shortening of 0.11 sec., there was no change in ventricular rate. The remaining three cases all showed an increase in conduction time. In two of these, transient, complete heart-block was observed. In all cases, numerous premature beats, of both nodal and ventricular origin, as well as shifting of the pacemaker, were observed. These effects were temporary, and the electrocardiogram returned to its original form within twenty minutes after the second injection of epinephrine.

It is well known that acceleration of the heart rate due to epinephrine results from stimulation of the endings of the accelerator nerves in the heart muscle; this is the characteristic feature of the action of epinephrine. With large amounts, acceleration may be temporarily replaced by retardation (Table IX). "This second phase of slowing is not observed if the vagi are divided or if atropine is given before adrenalin, so that it obviously arises from excitation of the vagus center. This is not mainly a direct adrenalin action but is largely a secondary result of the high blood pressure, which induces congestion of the brain and arouses the vagal center to activity. After a short time, the blood pressure beginning to fall, or the vagus center becoming exhausted, the accelerator stimulation again gains the upper hand."[16]

It may be possible, then, that the changes in rhythm observed in this series of rheumatic subjects following injection of the larger amounts of epinephrine are an expression of a hyperirritable vagal center. This

TABLE IX

EFFECT OF SUBCUTANEOUS INJECTION OF EPINEPHRINE HYDROCHLORIDE (1:1000) UPON THE VENTRICULAR RATE AND AURICULOVENTRICULAR CONDUCTION TIME IN A PATIENT WITH ACUTE RHEUMATIC FEVER

L. C. Female. Age 20. Mitral Stenosis and Insufficiency. U.H. 474067

DATE 1936		TIME	AURICULAR RATE	VENTRICULAR RATE	P-R INTERVAL (SEC.)	BLOOD PRESSURE	REMARKS
January 18	*Control*	9:05		75	0.21	102/58	
		9:10					Epinephrine 1 c.c.
		9:11		100	0.18	104/58	
		9:12		110	0.18		
		9:13				122/70	
		9:14	*100	75			
		9:15				160/94	
		9:17		96	0.18-0.34		
		9:18				166/88	
		9:20		85	0.21-0.22		
		9:21				150/72	
		9:24				134/74	
		9:25		80	0.21		
		9:27				126/70	
		9:30		82	0.21-0.22	120/60	
January 20		10:10		70	0.20	108/70	
January 21		10:20		60	0.20	117/70	
January 30		10:20		90	0.18	122/70	
February 11		2:45		70	0.18	120/80	
February 19		9:55		90	0.18	125/82	
February 28		10:25		98	0.18-0.19	118/76	
March 11		10:43		100	0.18	112/86	

*Complete heart-block.

explanation suggests that the source of vagal hypertonia may be not in the heart but in the medulla oblongata. Further evidence in support of this hypothesis is being sought.

Four of the rheumatic patients complained of transient, moderately severe, nonradiating precordial pain, occurring from twelve to fifteen minutes after the injection of the second dose of epinephrine. The increase in blood pressure was at its height at this time. An ice bag placed on the precordium was effective in controlling the pain, which never lasted more than several minutes. This symptom was not encountered in the control group, despite administration of comparable doses of epinephrine.

Exercise.—Observations on the effect of exercise upon prolonged auriculoventricular conduction time did not yield conclusive results. Only two patients were studied. The exercise consisted of sitting up and lying back in bed fifty times. In one case there was an increase in ventricular rate of 3 beats per minute, with a reduction of the P-R interval from 0.23 to 0.21 sec. (Table II). In the other case there was an increase in the cardiac rate of 4 beats per minute, with a fall in conduction time from 0.28 to 0.25 sec.

COMMENT

Loewi[7] has demonstrated that the vagus nerve does not act directly on the heart muscle. His evidence is simple and direct. Two frog hearts were isolated, one with its vagus nerve, the other without. Both hearts were filled with a small amount of Ringer's solution. The vagus nerve to the one heart was stimulated continuously for a few minutes and then the Ringer's solution from this heart was placed within the other. The second heart reacted as if its own vagus had been stimulated. If this second heart had previously been atropinized, no effect was exerted by the transferred fluid. Therefore, excitation of the vagus nerve produced or increased in amount a chemical substance which brought about slowing of the heart. This substance, which he called *Vagusstoff*, he was later able to prove to be, in all probability, identical with acetylcholine.[8]

Atropine counteracts the effect of vagal stimulation. It has been shown that the impairment of auriculoventricular conduction in these cases of acute rheumatic fever was temporarily diminished or abolished by the injection of atropine. It appears, therefore, that the conduction defect is caused, at least in part, by an increase in vagal tone. The significance of this fact is enhanced by the observations of Hall, Ettinger, and Banting.[9] These investigators injected eight dogs with a 1:10,000 solution of acetylcholine daily over a period of months. All of the animals died with terminal signs of cardiac failure. Examination of the hearts at necropsy showed severe damage to the myocardium and coronary arteries.

Attempts have been made to reproduce lesions in the myocardium and coronary arteries by vagal stimulation, similar to those achieved with the use of acetylcholine. These have not been successful.[10] Experiments on animals are being conducted in this laboratory along similar lines.

SUMMARY

Impairment of the auriculoventricular conduction time was studied in twenty-two patients with acute rheumatic fever. Observations were made (1) after the intravenous injection of atropine sulphate, (2) during a period of acute emotional stress, (3) following the subcutaneous administration of epinephrine hydrochloride, and (4) after exercise.

Atropine completely abolished the conduction defect in nineteen of the twenty-two cases studied. There was a marked diminution in the degree of block in the one case in which the drug was given intramuscularly. The effect was always transient. Since acceleration in ventricular rate did not necessarily parallel decrease in conduction time, it appears that these two effects are not directly related. In one of the two cases which did not show a reduction in the degree of block after atropinization, the impairment persisted for a year and was probably due to organic changes

in the junctional tissues. Three cases, in addition to impairment of auriculoventricular conduction, also showed delay in intraventricular conduction. Atropine had no effect on this disturbance.

In three individuals, who gave evidence of emotional stress at the time of the observations, marked reduction in the P-R intervals was noted, despite little or no acceleration of ventricular rate.

Small doses of epinephrine, injected subcutaneously, in five cases produced a result similar to that observed in a control group. Larger dosage, however, exerted two opposite effects; it either diminished the conduction defect (two cases), or markedly increased it (three cases). The latter result was not seen in a control group under similar conditions.

After moderate exercise, there was some decrease in the P-R interval, with slight increase in ventricular rate.

It is concluded that, in cases of acute rheumatic fever, impairment of auriculoventricular conduction is due, in part at least, to an increase in vagal tone. The significance of this fact is briefly discussed. It is suggested that the focus of vagal irritation lies in the medulla.

REFERENCES

1. Parkinson, J., Gosse, A. H., and Gunson, E. B.: The Heart and Its Rhythm in Acute Rheumatism, Quart. J. Med. 13: 363, 1920.
2. Swift, H. F.: Rheumatic Fever, Am. J. M. Sc. 170: 631, 1925.
3. Rothschild, M. A., Sachs, B., and Libman, E.: The Disturbances of the Cardiac Mechanism in Subacute Bacterial Endocarditis and Rheumatic Fever, Am. Heart J. 2: 356, 1927.
4. Levy, R. L., and Turner, K. B.: Impaired Auriculoventricular Conduction in Rheumatic Fever, Arch. Int. Med. 43: 267, 1929.
5. Lewis, T., Drury, A. N., and Iliescu, C. C.: Some Observations Upon Atropine and Strophanthin, Heart 9: 21, 1921.
6. Cushny, A. R.: Pharmacology and Therapeutics, ed. 7, Philadelphia, 1918, Lea and Febiger, p. 368.
7. Loewi, O.: Ueber humorale Uebertragbarkeit der Herznervenwirkung, Pflügers Arch., V 189: 239, 1921.
8. Loewi, O.: The Humoral Transmission of Nervous Impulse, Harvey Lectures, 1932-1933, Series 28, p. 219.
9. Hall, G. E., Ettinger, G. H., and Banting, F. G.: An Experimental Production of Coronary Thrombosis and Myocardial Failure, Canad. M. A. J. 34: 9, 1936.
10. Ettinger, G. H., Hall, G. E., and Banting, F. G.: Effect of Repeated and Prolonged Stimulation of the Vagus Nerve in the Dog, Canad. M. A. J. 35: 27, 1936.

DISSECTING ANEURYSM OF THE AORTA, CORRECTLY DIAGNOSED

With Description of a Sign Heretofore Not Mentioned*

H. Roesler, M.D., U. G. Gifford, M.D., and W. Betts, M.D.
Philadelphia, Pa.

Case History.—J. B., male, aged seventy-five years, was supposed to have had typhoid fever at the age of sixty years. Six months ago he felt well. His blood pressure at that time was 180/95, and the urine showed a trace of albumin. Progressive shortness of breath developed during the last two months.

On the evening of May 24, 1936, he ate a heavy meal and immediately afterward carried a heavy pail for thirty yards. Ten minutes later, while standing and talking to a neighbor, he was suddenly seized with a severe pain in the back of his neck and upper dorsal region. The pain became more severe lower down the back and under the lower sternum. There was no radiation into the arms. He walked to his house, upstairs to his room, and became gray and perspired. Vomiting was induced but brought no relief. He was very restless and walked from room to room.

He was given morphine and admitted to the hospital on the next evening. His blood pressure was 165/140 in the right arm and 180/140 in the left arm. The heart was enlarged to the left, and there was a wide, heaving apical impulse. There was a mitral systolic murmur and a well-marked protodiastolic gallop rhythm. The aortic second sound was greatly accentuated; no murmurs were heard. Both lung bases were full of moist râles, and bloody, frothy mucus was raised. The temperature was 99° F. The heart rate was regular, 104 per minute, but the next day premature ventricular beats were heard, and short runs of tachycardia, thought to be of ventricular type, appeared. The pulmonary edema cleared up. The blood pressure remained constantly elevated, 165 to 240 systolic and 118 to 140 diastolic. The temperature did not exceed 100° F. Pain, requiring relief by morphine or dilaudid, continued for five days.

On the ninth day a pulsating area was discovered in the left interscapular area, at the level of the eighth interspace, the center being 6 cm. from the spinous processes. Three days later it was found to be 9 cm. out. Over this pulsating area the aortic second sound was very accentuated. On the fifth day of this illness he complained of pain in the lower dorsal and upper lumbar region.

Laboratory Findings.—The leucocyte count varied from 10,000 to 15,000. The urine showed albumin but no casts, with a specific gravity of 1.025. Blood urea nitrogen was 9 mg. per 100 c.c. Electrocardiograms were taken on the third and fifth days of his illness. There was present an isoelectric T_1, left axis deviation on the second occasion, and a few premature auricular beats. The first bedside roentgenograms were taken on the eleventh day following the attack. There was an aortic configuration with enlargement downward and to the left. There was a definite widening of the supra-aortic shadow in the region of the right innominate artery. The aortic shadow appeared moderately widened, markedly elongated, with the descending aortic contour slightly convexly curved and prominent. The air content of the left lung field was diminished. The left anterior oblique view revealed a prominence of the

*From the Chester County Hospital, West Chester, Pa., and the Departments of Medicine and Roentgenology, Temple University School of Medicine, Philadelphia, Pa.

descending thoracic aorta dorsad, with poor definition of its contour because of the diminished contrast. The second bedside roentgenogram was taken seven days later, a few hours preceding the patient's death. A very marked, rather sharply defined, bulging prominence was noted in the cranial portion of the descending thoracic aorta. Its level coincided exactly with the area of pulsations in the left interscapular space.

Death occurred suddenly on the eighteenth day of the illness. The clinical diagnosis was hypertensive atherosclerotic cardiovascular disease with dissecting aneurysm of the aorta.

Post-Mortem Examination on June 11, 1936 (Dr. I. P. P. Hollingsworth). The heart weighed 490 grams. There was marked left ventricular hypertrophy and dilatation. The coronary arteries showed thickened walls, with plaques and diminished lumina. There was no evidence of thrombosis or infarction. The valves were normal. The entire thoracic aorta was moderately widened; the innominate artery was dilated, and its walls were thickened. The aorta, particularly the abdominal

Fig. 1.—Roentgenograms, anteroposterior projection. The criteria for comparing correctly the two films are not completely fulfilled. The development of a bulging prominence in the course of the descending thoracic aorta, however, is clearly demonstrated. There is also a marked widening in the area which corresponds to the innominate artery.

portion and all main branches, showed advanced atherosclerotic changes with calcareous plaques. There were thrombi in both iliac arteries. At a point 15 cm. from the aortic valve was the beginning of a large dissecting aneurysm which extended downward for 15 cm. This area bulged distinctly, showed a dark discoloration, and the external coat of the aorta was thinned. On the lateral and posterior aspect a rupture 0.25 cm. long had occurred. The diameter of the aorta at the point of rupture was 7 cm., the average diameter of the aneurysmal sac 5.5 cm. The left pleural cavity was completely filled with blood. There was a hemorrhagic retroperitoneal infiltration at the left side, following the sheaths of the muscles, extending well up on the lateral abdominal wall. It was thought that this infiltration had occurred from the pleural cavity at the root of the diaphragm, no other aortic or arterial rupture having been found. The kidneys were slightly enlarged, with roughened surface. On section they were of pale pinkish color with poorly defined corticomedullary boundary.

Microscopic Study: Aneurysm—the muscular coats of the media were markedly separated by hemorrhagic infiltration. Kidneys—chronic glomerulonephritis and arteriosclerosis.

DISCUSSION

As to the clinical picture and the pathology of dissecting aneurysm, the reader is referred to the monograph of Shennan[1] and to the article of Weiss,[2] in which there are ample references.

In our case we considered in differential diagnosis cardiac infarction, pulmonary infarction, and dissecting aneurysm of the thoracic aorta.

Fig. 2.—Post-mortem specimen. The lower probe leads into the lumen of the aorta. The probe to the right indicates the place where the dissecting aneurysm ruptured into the left pleural cavity.

The last diagnosis was established because of the type of pain, persistence of high blood pressure, absence of electrocardiographic changes characteristic for cardiac infarction. Full certainty was gained because an area of pulsation was observed to appear in the back and to move laterally. The second roentgenogram permitted a visualization of the rapid progression of the aneurysmal bulge at that level. It was not studied, however, until the patient had died and to this extent did not influence the already established diagnosis.

The observation of a rapidly shifting (increasing) area of pulsation, indicating the development of a dissecting aneurysm, has apparently not been reported before. In Wyss' case[3] there was a pulsating area present below the right clavicle. It increased slowly in the course of many weeks and the post-mortem examination revealed a dissecting aneurysm, 12 cm. in size, starting 6 cm. above the aortic valves. Such a slow increase may be found in connection with an aneurysm of the ordinary variety. In Bahrdt's case,[4] with correctly diagnosed dissecting aneurysm of the abdominal aorta, there was present a pulsating tumor the size of a hen's egg above the navel.

A number of recent articles dealing with proved cases of dissecting aneurysm of the aorta provide roentgenological descriptions, and most of them illustrations also.[2, 5-14] Kienböck and Weiss' case[21] is convincing but was not verified anatomically. In order to understand the varying roentgenological appearance, a very short anatomical discussion is needed. The size, extension, and amount of circular dissection vary greatly. Rupture near the aortic arch is common, and the dissection may travel distally or proximally. The newly formed blood path may almost completely encircle the aortic tube, thus forming a case or coat. More frequently only half to two-thirds of the circumference is involved. Thus it may come to lie essentially in a frontal or sagittal plane of the aortic vessel proper. The form may be either saccular-circumscript or, more often, cylindrical-diffuse.

A marked fluid collection in the pleural cavity or a diffuse extravasation of blood into the mediastinal tissues can easily interfere so that the roentgenological diagnosis becomes impossible. With the dissection extending between the brachiocephalic vessels or almost entirely encircling portions or the entire length of the thoracic aorta, the differentiation of a simple dilatation or cylindrical or saccular aneurysm of the thoracic aorta is impossible. An exception to this general statement must be made. The aorta may contain lime salt deposits, and its contour will then be visualized as a denser, linear shadow within a larger, usually cylindrical, but occasionally globular, and otherwise homogeneous shadow mass. If the newly formed aneurysm involves only a part of the circumference of the aortic vessel and has a predominantly lateral location, with respect to the direction of projection, it will be visualized as an outer, lighter shadow, usually of fairly even width, superimposed in a shell-like fashion upon the aortic shadow proper. The latter then appears as a more dense nuclear shadow, the size and shape of which is commonly, though not necessarily, altered in the sense of dilatation, fullness and tortuosity. Again, lime salt deposits may form a line of demarcation.

Dissecting aneurysm of the aorta has seldom been correctly diagnosed in the past, but this is changing recently. Thus Shennan[1] accepts six cases[3, 4, 5, 9, 15, 16] in his analysis of 300 cases up to and including 1932.

We reject one[2] but add another.[6] Since then there have been ten additional cases.[2, 7, 13, 14, 18, 19, 20] This, then, is the seventeenth case correctly diagnosed.

SUMMARY

A case with dissecting aneurysm of the thoracic aorta is reported in which the correct diagnosis was established.

A new diagnostic sign is described, consisting in the appearance of an area of pulsation which shifts rapidly; associated with it is the rapid change in the roentgenological appearance of the aortic shadow.

The roentgen findings in general are discussed.

The cases in which the diagnosis was correctly made are cited.

REFERENCES

1. Shennan, T.: Medical Research Council, Spec. Rep. Ser. No. 193, London, 1934, His Majesty's Stationery Office.
2. Weiss, S.: Med. Clin. North America 18: 1117, 1935.
3. Wyss, O.: Arch. Heilk. 10: 490, 1869.
4. Bahrdt, R.: Arch. Heilk. 13: 473, 1872.
5. Davy, H., and Gates, M.: Brit. M. J. 1: 471, 1922.
6. Hirschboeck, F. J., and Boman, P. G.: Minnesota Med. 5: 724, 1922.
7. Patrick, C. V., and Taylor, J. F.: Lancet 1: 181, 1929.
8. Tidmarsh, C. J.: Canad. M. A. J. 23: 416, 1930. (See also Wood-Pendergrass-Ostrum.)
9. Barton, E. M.: Tr. Chicago Path. Soc. 13: 399, 1930.
10. Wood, F. C., Pendergrass, E. P., and Ostrum, H. W.: Am. J. Roentgenol. 28: 437, 1932.
11. Canigiani, Th.: Fortschr. a. d. Geb. Röntgenstrahlen 45: 416, 1932.
12. Holzmann, M.: Acta radiol. 13: 21, 1932.
13. Hamman, L., and Apperly, F. L.: Internat. Clin. 4: 251, 1933.
14. Osgood, E. E., Gourley, M. F., and Baker, R. L.: Ann. Int. Med. 9: 1398, 1936.
15. Swaine: Tr. Path. Soc., London 7: 106, 1855, 1856.
16. Moosberger, W.: Schweiz. med. Wchnschr. 54: 327, 1924.
17. Kellogg, F., and Heald, A. H.: J. A. M. A. 100: 1157, 1933.
18. White, P. D., Badger, T. L., and Castleman, B.: J. A. M. A. 103: 1135, 1934. (Footnote.)
19. Lounsbury, J. B.: Yale J. Biol. & Med. 7: 209, 1935.
20. Löffler, W.: Schweiz. med. Wchnschr. 65: 790, 1935.
21. Kienböck, R., and Weiss, K.: Fortschr. a. d. Geb. Röntgenstrahlen 44: 212, 1931.

THE CLINICAL VALUE OF COMPARATIVE MEASUREMENTS OF THE PRESSURE IN THE FEMORAL AND CUBITAL VEINS*

EUGENE B. FERRIS, JR., M.D., CINCINNATI, OHIO, AND
ROBERT W. WILKINS, M.D., BOSTON, MASS.

THE USE of accurate methods for measuring systemic venous pressure has resulted in a definite increase of our knowledge of cardiac failure, particularly failure of the right ventricle. In addition, accurate measurements of venous pressure in both arms have been shown to be of value in locating lesions in the upper mediastinum which obstruct the superior vena cava, the innominate or the subclavian veins.[1, 2] When such lesions exist, however, the venous pressures as measured in the arms obviously are of no use in estimating the degree of heart failure. Villaret and Desoille[2] and others[3, 4] have demonstrated the importance of comparative determinations of venous pressure in both the arms and the legs when lesions press upon or obstruct the inferior vena cava. They have pointed out that in conditions such as pregnancy, ascites, and tumors of the abdomen, the pressure in the leg veins is high but is normal in the arm veins. Aside from these reports, the diagnostic importance of comparative venous pressure measurements has received little attention. The purpose of this paper is to demonstrate the clinical value of comparative observations of the pressure in the cubital and femoral veins and to describe instances in which puncture of the femoral veins has been particularly useful.

FEMORAL VENEPUNCTURE

Puncture of the superficial veins of the legs may be difficult if not impossible, especially when there is edema or obesity. Puncture of the femoral vein, on the other hand, because of its constant position in relation to well-recognizable anatomical landmarks, is an easy procedure and has been used in several clinics for a number of years.[5, 6, 7] It may be used not only for the measurement of pressure in a vein draining directly into the inferior vena cava, but also for the removal and administration of blood or other fluids. In preparing to puncture the femoral vein, one locates the pulsation of the femoral artery in the groin below Poupart's ligament. The skin is cleansed with alcohol and an area just medial to the artery is infiltrated with novocaine. An 18 or 19 gauge needle, 1½ inches long, is then inserted through the skin and guided toward a point approximately 1 cm. medial to the maximal arterial pulsation; the needle should be directed upward and at an angle of about 60 degrees from the plane of the skin. By main-

*From the Thorndike Memorial Laboratory, Second and Fourth Medical Services (Harvard), Boston City Hospital, and the Department of Medicine, Harvard University Medical School; and the Department of Internal Medicine, University of Cincinnati College of Medicine.

taining a slight negative pressure in the syringe, blood will appear the moment the vein is punctured. If the artery is continually palpated during this procedure, the position of the neighboring vein can be more accurately localized. Should the needle pass through or medial to the femoral vein, the pubic bone will be encountered. The femoral artery may be inadvertently punctured, but no harm will result if the needle is withdrawn and firm pressure maintained over the area for two or three minutes. The direction of the needle should not be changed while deep in the tissues because of the danger of tearing the arterial or venous wall. Solutions which are prone to cause thrombophlebitis should not be administered by this route.

METHOD OF MEASURING VENOUS PRESSURE

The direct method of Moritz and von Tabora[8] has been used to obtain venous pressures. A description of a simple and practical modification of this method for measuring the pressure in the cubital veins can be found elsewhere.[1] This method consists in using a graduated manometer connected by means of a three-way cock with a needle and a syringe containing normal saline solution. The pressure in the femoral veins can be obtained best by including a rubber tube between the manometer and the syringe, thus giving the system more flexibility. The patient should be placed in a horizontal position when possible, and it is essential that he be relaxed. The venous pressure as measured in the manometer is related to the manubrium sterni by means of a spirit level, and in turn to the right auricle by adding 5 cm. which is the average distance that the auricle lies below the manubrium. Our observations indicate that the normal venous pressure range is from 4 to 10 cm. of water, with an average of 6 cm. of water.

CLINICAL OBSERVATIONS

During the past two years we have routinely made comparative direct measurements of venous pressure in the femoral and cubital veins in cases in which the history or physical findings suggested the possibility of an elevation of venous pressure, due either to an obstruction or to questionable cardiac failure. The following examples illustrate the types of cases observed and the information obtained from venous pressure determinations.

CASE 1.—E. F., an eighty-eight-year-old woman, entered the Boston City Hospital complaining of mild dyspnea, weakness, and attacks of palpitation for one year. She had lost considerable weight. Examination revealed that she was dyspneic but not orthopneic. The neck veins were slightly distended. There was no tumor in the neck. The heart rate was 120 per minute, the rhythm grossly irregular, and the blood pressure 150/40. The peripheral pulse was bounding and the extremities were warm. There was no edema. The history of palpitation and loss of weight and the findings of warm extremities and a large pulse pressure suggested hyperthyroidism. Since the pressure was found to be 10.5 cm. of water in the cubital veins and only 5 cm. in the femoral veins, the diagnosis of a substernal thyroid with slight superior

caval obstruction was entertained. This was later confirmed by x-ray examination. The basal metabolic rate was +35 per cent. Because of her age and the danger of tracheal collapse, operation was rejected in favor of iodine and deep x-ray therapy. The basal metabolic rate came down to +17 per cent, and she was allowed to go home. Four months later she reentered the hospital with bronchopneumonia and empyema from which she died. Autopsy revealed a large adenomatous thyroid weighing 300 gm., which filled a large part of the upper mediastinum.

Differential venous pressures were of aid in determining the presence and the location of a mediastinal tumor in this case.

CASE 2.—C. H., a twenty-six-year-old male, entered the Boston City Hospital because of weakness, substernal oppression, dyspnea, cough, and hemoptysis for three weeks. There was no orthopnea. Physical examination revealed marked distention of the veins of the neck and arms, and dilatation of the superficial venules of the thorax. There was slight cyanosis of the face, lips, and fingernail beds. He had definite gynecomastia. There were signs of consolidation at the apex and of fluid at the base of the right lung. In addition to these findings, x-ray films showed the presence of several areas of density in the left lung. Although the syndrome of acute superior vena caval obstruction was fairly obvious in this case, the possibility of inferior caval obstruction or of superimposed cardiac embarrassment could not be entirely ruled out. The venous pressure was found to be 23.5 cm. of water in the right arm, 23 cm. in the left arm, and only 4.5 cm. in the femoral vein, clearly indicating a superior mediastinal obstruction involving the superior vena cava but not affecting the inferior cava or the cardiac function. The urine was later found to contain large amounts of prolan B, and in the absence of testicular abnormality a diagnosis of primary mediastinal chorionepithelioma was made. At autopsy the diagnosis was confirmed, and the location of the tumor was found to agree with the clinical impression. The mass completely filled the upper mediastinum, and tumor tissue had invaded the lumen of the superior vena cava, causing almost complete obstruction. The inferior vena cava was not involved either through encroachment or invasion by tumor tissue.

CASE 3.—N. H., a forty-five-year-old male, was admitted to the Cincinnati General Hospital complaining of progressively enlarging abdominal veins for two months. For two years previously he had had a chronic cough with moderate amounts of purulent sputum. During this period the diagnosis was thought to be either chronic lung abscess or encapsulated empyema because a small amount of pus had been obtained from the right chest by thoracentesis. Physical examination revealed an undernourished male, comfortable in bed with no orthopnea or dyspnea. The veins of the neck and arms appeared moderately distended and tense. A large plexus of dilated, tortuous veins was seen over the entire abdominal wall and lower part of the anterior chest (Fig. 1). The direction of flow was difficult to determine. The left lung was normal, but there were flatness and absence of breath sounds over the entire right lung, with some retraction of the trachea and heart to the right. The heart was essentially negative; blood pressure 132/86. The abdomen was negative to palpation. Both saphenous veins were prominent, but appeared thrombosed because no blood could be obtained from them. Venous pressure measurements at the time of admission were median cubital vein (both arms), 35 cm. of water; abdominal vein at center of plexus, 22 cm.; and femoral vein, 8.0 cm. X-ray studies showed a complete atelectasis of the right lung. Bronchoscopic examination demonstrated an occlusion of the right main stem bronchus at its bifurcation. Biopsy specimens were unsatisfactory, but a clinical diagnosis of advanced bronchogenic carcinoma was made. Before differential venous pressures were available, there was considerable discussion as to whether the patient had superior or inferior caval obstruction or both since the direction of blood flow in the abdominal veins

was difficult to determine. The value of these determinations in localizing the lesion in the upper mediastinum is obvious. It should be pointed out that the appearance of anastomosing abdominal veins does not help in differentiating superior from inferior caval obstruction as the same veins are involved in either case.

The patient died four months after admission to the hospital. Autopsy showed extensive carcinoma which appeared to be primary in the right main stem bronchus, where it caused complete occlusion. The entire right lung was inelastic and filled with multiple small abscess cavities. The growth had extended to the superior vena cava, which was completely occluded from its entrance into the right auricle to a

FIG. 1.—Photograph of N. H. (Case 3) showing the venous anastomosis which resulted from superior vena caval obstruction.

point about 1 cm. below its bifurcation into the innominate veins. The inferior vena cava was patent throughout. It is of interest that in both this and the preceding case the caval obstruction was brought about by extension of the tumor into the lumen of the vein.

CASE 4.—H. C., a thirty-four-year-old male, entered the Boston City Hospital complaining of increasing dyspnea, hoarseness, and cough with small amounts of whitish sputum for two months. For two weeks he had been unable to sleep at night because of orthopnea and attacks of smothering. He also complained of a constant

dull substernal ache of ten days' duration. Examination revealed a well-nourished man with moderate cyanosis and severe respiratory distress of Cheyne-Stokes character. There was engorgement of the veins of the neck and arms and distention of the venules on the anterior chest. There was nothing remarkable about the leg veins. Except for moist râles at both bases, the lungs were clear. The left border of the heart was 11 cm. from the midsternal line, while the right border was at the sternal margin. There was a gallop rhythm but no murmurs. The heart rate was 110; rhythm, regular; blood pressure, 110/80. The abdomen, extremities, and reflexes were normal.

On the basis of the history and physical signs, suggesting a substernal lesion obstructing the superior vena cava, involving the recurrent laryngeal nerve, and embarrassing the heart and respiration, a provisional diagnosis of an upper mediastinal tumor was made. Simultaneous direct venous pressure determinations revealed a pressure of 17.5 cm. in both the femoral and cubital veins. This finding definitely ruled out a single upper mediastinal lesion and proved that the difficulty was cardiac in origin, either pericardial, myocardial, or endocardial, or a combination of these. An electrocardiogram showed left bundle-branch block and T-wave changes of severe myocardial disease. Fluoroscopy revealed no evidence of pericardial effusion or adhesions. With rest in bed the patient improved and venous pressures dropped to 9.5 cm. in both arms and legs. The etiology of the myocarditis remained obscure.

This case illustrates the fact that mere inspection of the veins, especially the leg veins, is of little value in estimating the venous pressure. It also demonstrates the necessity of comparative venous pressures, not only in the arms, but also in the legs in order to rule out superior caval obstruction and to establish the diagnosis of cardiac decompensation.

CASE 5.—J. D., a fifty-two-year-old male, entered the Boston City Hospital complaining of intermittent smothering sensations, hoarseness, and pain in the left shoulder for three years, and of painful swelling and contracture of the fingers of the left hand for two months. Physical examination revealed a well-nourished, apprehensive man, comfortable when flat in bed. At times he talked in a hoarse voice and he also had an intermittent dyspnea in bed. Heart, lungs, and abdomen were normal. There was marked limitation of motion of the left shoulder with spasm of the pectoral muscles. The fingers of the left hand were contracted and cyanotic, and the hand was moderately edematous. Some observers thought the left arm veins were distended. Direct venous pressures were the same, 9.5 cm. of water in both of the cubital and the femoral veins. This definitely ruled out a venous obstruction as the cause of the complaints in the left arm and hand and also cast grave doubt on the presence of a substernal lesion as a cause of his hoarseness and smothering. It developed that he had been known for years, by many hospital admissions, as a hysterical individual. He had lately been selling medical books which he had read, with the result that he had a surprising store of odd medical facts. X-ray films revealed hypertrophic arthritis of the left acromioclavicular joint. Laryngoscopy showed a normal larynx. With orthopedic treatment and strong psychotherapy his symptoms subsided.

CASE 6.—E. W., a fifty-six-year-old male, entered the Cincinnati General Hospital complaining of swelling of the legs for three months, dyspnea on exertion for two months, and nocturnal attacks of dyspnea for three weeks. Ten months before this admission he had had a transurethral prostatic resection for the relief of urinary retention. A biopsy at that time revealed carcinoma of the prostate. Physical examination showed a poorly nourished male propped up in bed, with rapid, but not

labored, respirations. The veins of the arms were distended but appeared to collapse at a normal distance above heart level. Percussion revealed the left border of the heart 14 cm. from the midsternal line. The rhythm was regular, and there were no significant murmurs. The blood pressure was 128/92. There were signs of bilateral hydrothorax. The liver was not felt. There was marked edema of the legs and trunk. In the left scrotum there was a fluctuant swelling about 10 cm. in diameter. Numerous enlarged firm nodes were palpated in both inguinal regions. On rectal examination a large irregular mass was felt anteriorly.

Because of the history of dependent edema, dyspnea on exertion, and paroxysmal nocturnal dyspnea, the patient was thought on admission to have congestive failure independent of prostatic carcinoma and was treated with digitalis and diuretics. Also 600 c.c. of fluid were removed from the left chest and 650 c.c. from the right. This fluid had the character of a transudate. These procedures relieved the dyspnea out of proportion to the edema which was still marked ten days after admission. Venous pressures at this time were 5 cm. of water in the cubital veins, 29 cm. in the right femoral vein, and 23 cm. in the left femoral vein.

X-ray studies revealed infiltrative lesions throughout both lung fields and extensive bone metastases, both osteoclastic and osteoblastic in nature. Laboratory studies showed a secondary anemia, a negative blood Kahn reaction, and a total serum protein of 8.7 grams per 100 c.c.

The venous pressures in this case clearly established the presence of a local venous obstruction as the principal cause of the edema of the lower part of the body. Together with the x-ray findings, they also made it fairly certain that the lung metastases and pleural effusions, rather than cardiac failure, were responsible for the dyspnea.

CASE 7.—M. Q., a fifty-year-old male, entered the Boston City Hospital because of ascites and edema of the legs which resulted from alcoholic cirrhosis of the liver, later proved at autopsy. The abdominal fluid reaccumulated so rapidly that frequent abdominal taps were necessary. Simultaneous determinations of the venous pressure in the cubital and femoral veins were made before and after removal of the fluid on eight occasions. Depending on the tenseness of the abdominal wall, the femoral venous pressures, before tapping, ranged from 17 to 24.5 cm. of water. After removal of as much fluid as possible they fell to from 10 to 12 cm. of water. The pressure in the median cubital vein was unaffected by removal of the fluid and remained at a normal level of 7 to 8 cm. of water. Further observations demonstrated that the height of the pressure in the femoral vein was directly related to the intra-abdominal pressure. When a few hundred cubic centimeters of fluid were removed, there was a drop in venous pressure out of proportion to the amount of fluid removed. This initial drop coincided with a relaxation of the anterior abdominal wall, and thereafter the venous pressure appeared to equal the hydrostatic pressure of the ascitic fluid alone. Thus when a manometer was attached to the paracentesis trocar the ascitic fluid rose several inches within the tube only as long as the abdominal wall was tense. Correspondingly, the pressure in the femoral vein approximated the level to which this fluid rose. As fluid was removed, the excessive tension on the abdominal wall was quickly relieved, and the fluid level fell below the trocar, while the venous pressure likewise fell rapidly. Thus, in ascites, the intra-abdominal and femoral venous pressures depend in part on the tension of the abdominal wall as well as on the actual amount of fluid present.

CASE 8.—E. H., a fifty-year-old woman, entered the Boston City Hospital complaining of painless swelling of the abdomen for one year. There was mild dyspnea on exertion but no orthopnea or any other complaint. The past history was entirely negative. Physical examination showed a well-nourished woman comfortable flat in bed with slight cyanosis and marked distention of the neck veins. The lungs were clear except for high diaphragms and atelectatic râles at the bases. The heart was of

normal size, the sounds of good quality, with a reduplicated second sound at the apex, but no murmurs. The rate and rhythm were normal. The blood pressure was 135/80. The abdomen was markedly distended with fluid, and the liver edge was felt 8 cm. below the rib margin. There was slight pitting edema of the lower legs. Laboratory studies revealed normal blood and normal kidney and liver function. The Takata-Ara tests on blood and ascitic fluid were negative. The electrocardiogram was normal. Fluoroscopy revealed slightly decreased pulsations of the heart, but otherwise no abnormality.

The abdomen was repeatedly tapped to remove the rapidly reaccumulating fluid which had the characteristics of a transudate. Venous pressures immediately before the abdominal tap were 34 cm. of water in the femoral veins and 33 cm. in both median cubital veins. Immediately after the removal of 9.5 liters of fluid the venous pressures were 20 cm. in the femoral veins and 18 cm. in the cubital veins. After the tap the vital capacity rose from 1,600 to 2,000 c.c. As the fluid reaccumulated, the venous pressures gradually returned to their previous levels.

The clinical picture was that of an active woman, free of symptoms except for swelling of the abdomen, with the peripheral signs of severe right-sided heart failure. The venous pressures proved that the difficulty was cardiac, and in the absence of significant signs of valvular or myocardial disease suggested constrictive pericarditis. She was seen in consultation by Dr. Elliott C. Cutler, who agreed to operate. At operation a dense tough pericardium, 3 mm. thick, was found adherent to the heart everywhere by tough adhesions, causing constriction. The pericardium was excised from the heart on all sides down to the venae cavae. She went through the three-hour procedure in excellent condition with pulse and blood pressure unchanged. The venous pressures throughout fell from a preoperative level of 18 cm. of water to 8 cm. of water postoperatively.

This case illustrates the value of comparative venous pressure determinations in both the arms and the legs in ruling out cirrhosis of the liver and in establishing the presence of a lesion embarrassing the heart. The fall in venous pressures as well as the rise in vital capacity after the removal of abdominal fluid in this case was interpreted as the result of the improved cardiac and respiratory function with the release of the intrathoracic pressure due to high diaphragms. Exactly the same observations were made in a second case of constrictive pericarditis diagnosed clinically but not proved by operation or autopsy.

CASE 9.—R. N., a thirty-six-year-old male, was admitted to the Boston City Hospital with a history of drinking one-half pint of alcohol a day for two years and a pint to a quart a day for three months. He had eaten a grossly inadequate diet which became more deficient, the more he drank. He complained of increasing dyspnea for one month, dependent edema for three weeks, cough for ten days, and orthopnea with sleeplessness for one day. Examination revealed an apparently well-nourished man with severe orthopnea and massive edema of every dependent part. The skin of the hands and lower legs showed typical pellagrous scaly pigmentation. The neck veins were engorged. There were signs of congestion over the lower one-third of both lungs. The heart was enlarged to the right and left, and there was a blowing systolic murmur with a gallop rhythm. The heart rate was 120 per minute and the blood pressure 110/50. The liver was palpated 4 cm. below the costal margin, but the spleen was not felt. Knee jerks were greatly diminished, and ankle jerks were absent. Laboratory studies revealed normal blood except for moderately lowered serum proteins: total protein, 5.2 gm. per 100 c.c. plasma; albumin, 2.92 gm.; and globulin, 2.28 gm. The Takata-Ara test on the blood was negative. Venous pressures in both arms and legs were 26 cm. of water and rose on the third day to 32 cm. On this day the patient suddenly went into circulatory collapse and died. Post-mortem

examination revealed marked dilatation of the right heart, and microscopic sections showed edema of the myocardium, both findings said to be typical of beriberi heart disease.[9]

The history and presenting symptoms in this case might suggest a protein-deficiency type of edema. The abnormal venous pressures clearly demonstrated the presence of myocardial failure, confirmed at autopsy as the chief cause of death.

CASE 10.—S. M., a forty-year-old male, entered the Boston City Hospital complaining of increasing edema, dyspnea, orthopnea, and cough for one week. He had had milder attacks of a similar nature, consisting of dyspnea, rapid pulse, and edema for five years. On physical examination the patient was restless and slightly orthopneic, with a respiratory rate of 40 per minute. There was ashen cyanosis of the lips and the nail beds, marked pallor of the face and extremities, and profuse sweating. The veins of the neck appeared distended, but the superficial veins of the extremities were completely collapsed and would not fill when occluded above. The heart was enlarged, rate 150, but no significant murmurs were heard. The blood pressure could not be obtained by the auscultatory method, apparently because of the minute pulse pressure. Palpation of the barely perceptible pulse at the wrist, however, demonstrated the systolic pressure to be about 120 mm. Hg. The lungs were filled with râles, and there was pitting edema up to the hips.

The pressure in the cubital vein could not be obtained because the superficial veins were bloodless, but the pressure in the femoral vein was 41 cm. of water. In addition to having severe circulatory collapse as evidenced by pallor, sweating, restlessness, and weak pulse, there was advanced congestive failure. The almost complete absence of blood flow to the skin and extremities, which is so frequently the case in collapse, plus the inability of the blood in the superficial veins to flow backward past the valves, probably accounts for the absence of blood in these veins. In such instances, the central venous pressure can be obtained only in a large vein, such as the femoral, which communicates directly with the right auricle without intervention of valves.

CASE 11.—M. R., a twenty-nine-year-old woman, entered the Boston City Hospital complaining of profound muscular weakness, a red scaly rash over the face and knuckles for eight months, and generalized edema for four months. She was studied extensively and diagnosed dermatomyositis by Dr. J. C. Turner, who will report the case in full.[10] Because of the marked generalized brawny edema, puncture of superficial arm or leg veins was practically impossible. The femoral vein was penetrated easily, and the pressure found to be 10 cm. of water. At the same time blood was removed for chemical analysis. The femoral venepuncture in this case not only ruled out cardiac failure as a factor in her edema, but also furnished blood for diagnostic study.

DISCUSSION

The simplicity and the accuracy of direct determination of the venous pressure in the larger veins make it a valuable diagnostic aid in any case in which there is a question of a circulatory disorder. In many instances careful observation of the superficial veins will give a fairly accurate estimation of the pressure in these veins. However, this method cannot be applied to the veins of the legs with any degree of accuracy, or even to the veins of the arms, in the presence of a very high venous pressure, venous thrombosis, edema, or obesity. A knowledge of the pressure in both cubital veins enables one to detect an obstruction in either of the subclavian or innominate veins. Since normally the pressure on the two sides is the same, any difference indicates an obstruction, and the amount of the difference gives an

estimate of the degree of obstruction. Likewise a knowledge of the pressure in both the cubital and the femoral veins enables one to determine the location and degree of an obstruction in either the superior or inferior vena cava, or both.

The femoral vein, because of its constant position, its large size, and the absence of valves between it and the heart, offers at times the only practical site for the determination of systemic venous pressure or for the removal of blood. Leading as it does directly into the inferior vena cava, which in turn leads directly into the right auricle, the femoral vein is always well filled with blood under at least the same pressure as in the right auricle. Abnormal variations of pressure in the auricle such as occur with tricuspid regurgitation are freely transmitted to the femoral vein without interference from values. A knowledge of the pressure in the right auricle is essential in order to estimate the functional state of the heart and the peripheral circulation. When the pressures are determined simultaneously in both the cubital and the femoral veins, the significance of the measurements is increased, not only in relation to the general circulation but also in relation to local obstructive lesions which interfere with venous flow.

SUMMARY

1. A knowledge of the pressures obtained simultaneously in the veins of the arms and legs is of clinical significance. Cases are reported which illustrate the value of comparative measurements of the pressure in the cubital and femoral veins.

2. The femoral vein may be advantageously utilized not only for measuring the venous pressure but also for obtaining blood and for administering intravenous medication.

REFERENCES

1. Overholt, R. H., and Pilcher, L. S., Jr.: Changes in Venous Pressure After Thoracoplasty—Its Significance in Relation to the Extent of Rib Removal, J. Thoracic Surg. 4: 269, 1935.
2. Villaret, M., and Desoille, H.: Quelques examples cliniques montrant l'intérêt général de la phlébopiézométrie au point de vue du diagnostic, du prognostic, et de la thérapeutique, Presse méd. 40: 1477, 1932.
3. Griffith, G. C., Chamberlain, C. T., and Kitchell, J. R., Jr.: Observations on the Practical Significance of Venous Pressure in Health and Disease, With a Review of the Literature, Am. J. M. Sc. 187: 642, 1934.
4. Brams, W. A., Katz, L. N., and Kohn, L.: The Effect of Abdominal Distention and Release on the Blood Pressures in the Arteries and Veins, Am. J. Physiol. 104: 120, 1933.
5. Weiss, Soma, and Ellis, Laurence B.: The Circulatory Mechanism and Unilateral Edema in Cerebral Hemiplegia, J. Clin. Investigation 9: 17, 1930.
6. Florkin, M., Edwards, H. T., and Dill, D. B.: Oxygen Utilization in the Legs of Normal Men, Am. J. Physiol. 94: 459, 1930.
7. Harrison, T. R., and Pilcher, C.: Studies in Congestive Failure: I. The Effect of Edema on Oxygen Utilization, J. Clin. Investigation 8: 259, 1930.
8. Moritz, F., and von Tabora, D.: Ueber eine Methode, beim Menschen den Druck in oberflächlichen Venen exakt zu bestimmen, Deutsches Arch. f. klin. Med. 98: 475, 1910.
9. Weiss, Soma, and Wilkins, Robert W.: The Nature of the Cardio-Vascular Disturbances in Vitamin Deficiency States, Tr. A. Am. Physicians 51: 341, 1936.
10. Turner, Joseph C.: Dermatomyositis: Unpublished Studies.

THE VALUE OF DIRECT VENOUS PRESSURE ESTIMATIONS IN AMBULATORY CARDIAC PATIENTS*

A. R. Berger, M.D.
New York, N. Y.

WELL-DEFINED congestive heart failure presents a clinical picture which is unmistakable. Preceding this state, patients usually have subjective evidence of diminished cardiac reserve—namely, dyspnea on effort and abnormal fatigue. Such symptoms, however, by their very nature are notoriously unreliable. They are exaggerated by the neurotic and apprehensive, and minimized by the stolid and phlegmatic types of patients. They may be caused by many conditions wholly unrelated to cardiac insufficiency.

Detection of the earliest objective signs of heart failure—if possible before subjective symptoms are particularly noticeable—is of extreme value in the management of ambulatory cardiac patients. The patient's habits of living, or his medication, may be rearranged, or any other necessary therapy may be introduced to prevent, if possible, the development of failure. A search for objective phenomena includes the application of the following methods of approach: response to effort; determination of cardiac output, venous pressure, and vital capacity.

Various procedures have been devised to increase the work of the patient in a standard manner in order to detect objective evidence of heart failure.[1-5] The criteria usually employed are the blood pressure and the heart rate. However, the complex phases of metabolism in muscular exercise and the effect of training come into operation. It is readily apparent that these tests merely record the efficiency of the vasomotor control of circulation and that they do not indicate true cardiac efficiency. Respiratory tests[6-8] are subject to similar criticism, and additional complications exist in the form of diseases of the lungs, pleura, mediastinum, or of the respiratory musculature. In both types of tests, neurogenic or psychogenic factors (fear and apprehension), and deliberate malingering are potent sources of error.

Although the heart has long been compared to a pump, it is extremely difficult to determine the efficiency of this biological machine by means of cardiac output. It is not possible to make direct observations in man without a certain amount of hazard. Ever since the work of Fick in 1870, interest has been stimulated in the gasometric determi-

*From the Department of Medicine and Therapeutics, New York University College of Medicine, the Third (New York University) Medical Division of Bellevue Hospital, and the Cardiac Clinic of Bellevue Hospital.

nation of cardiac output. The original method and its subsequent modifications are rather complicated and require a highly specialized technic. Inadequate mixture in the lung-bag system and failure to obtain equilibrium between the gases in the alveolar air and those in the blood introduce errors. As Grollman[9] has pointed out, there are inaccuracies in determinations in normal subjects, and there may be an elevation of even 25 per cent because of psychic disturbances. The only advantage which the indirect method recently described by Bazett[10] has over the respiratory method is its applicability to very ill persons.

Physiological study has shown that within certain limits increasing the initial tension on skeletal muscle during contraction increases its work done. Patterson and Starling[11] and Straub[12] have demonstrated the same facts for cardiac muscle. The initial load in the ventricle just prior to systole is the pressure of the blood within it. This is determined by filling from the auricle, which, in turn, is modified by venous return and venous pressure. Hence, the peripheral venous pressure bears a linear relationship to the initial intraventricular pressure.

If the "backward-failure" hypothesis of Hope (the evidence for which is considered comprehensively by Harrison[13]) is accepted, the measurement of venous pressure, on theoretical grounds, should prove the best objective evidence of early failure. As stated by Eyster,[14] "careful and frequent determinations of venous pressure show that the changes in pressure in many cases precede the changes in symptoms and signs, and may thus serve as an indicator of impending change." In the case of the right ventricle it is simple to measure the venous pressure. The venous pressure in the pulmonary circulation, which conditions the initial left intraventricular pressure, cannot, however, be determined in man. For this reason, the vital capacity may be studied to detect early left ventricular failure.

It was hoped that these two objective signs—peripheral venous pressure and vital capacity—might furnish early evidence of failure so that treatment could be instituted promptly before clinical failure developed. With this in mind, the following study was undertaken.

MATERIAL

The results embodied in this paper were obtained from an intensive study (over a period of four years) of 68 male patients in the adult cardiac clinic of Bellevue Hospital. The distribution according to etiology and rhythm is shown in Table I.

The rheumatic group includes those patients without any history of the manifestations of rheumatic fever but in whom, nevertheless, the typical structural changes of rheumatic heart disease are found. In

TABLE I

RHEUMATIC (AND UNKNOWN-RHEUMATIC TYPE)		ARTERIOSCLEROSIS AND HYPERTENSION		ARTERIOSCLEROSIS AND UNKNOWN (PREVIOUS HYPERTENSION)		RHEUMATIC HYPERTENSION —ARTERIO-SCLEROSIS		HYPERTENSION AND UNKNOWN (RHEUMATIC)		ARTERIO-SCLEROSIS		HYPER-THYROID		UNKNOWN	
RSR*	AF†	RSR	AF	RSR	AF	RSR	AF	RSR	AF	RSR	AF	RSR	AF	RSR	AF
2	27	5	8	2	9	-	2	2	-	2	-	1	-	2	6

*Sinus rhythm.
†Auricular fibrillation.

the group designated "arteriosclerosis and unknown," the unknown factor is most probably an antecedent hypertension. The "hypertension—unknown (rheumatic)" group includes two patients who have mitral stenosis and insufficiency so that the unknown factor here is considered to be rheumatic fever. The "unknown" group comprises patients with organic heart disease without any definitely ascribable etiology. The other group labels are self-explanatory. All the patients with the rheumatic type of heart disease, thirty-three in number, have mitral stenosis and insufficiency, and nine also have aortic valve disease (seven with aortic insufficiency and two with aortic insufficiency and aortic stenosis). The diagnoses of tricuspid or pulmonic disease, or adherent pericardium, were not made clinically, nor were they encountered in the cases which came to necropsy. The ages range from twenty-two to seventy-nine years.

The control group includes twenty male patients convalescent from minor ailments. They are selected only so far as they show no evidence of organic heart disease and they parallel the age group of the patients' series.

METHOD

The method* is a modification of the one described by Moritz and von Tabora.[15] The apparatus consists of a manometer capable of being adjusted so that its zero reading is in the same horizontal plane as the right auricle. In the recumbent position, the level of the right auricle is considered to be in the fourth intercostal space, 5 cm. below the sternum. A three-way stopcock connected to a syringe and to the manometer insures proper cannulation before the manometer is put into communication with the vein. The system contains a sterile 5 per cent sodium citrate solution and the needle is 1 inch long and of 18 gauge caliber. The vein usually used is the median basilic or a major tributary. All constricting upper garments are removed. A basal rest period of at least fifteen minutes, in which the patient remains absolutely quiet, flat on his back, precedes the test. All readings are checked, and a Valsalva experiment is performed each time. Heart rate and respirations are recorded at the same time and vital capacity is determined the same evening. The patients complained of no discomfort when the operator was sufficiently skillful.

*Before undertaking this investigation, Dr. Erna Enderle and Dr. M. S. White made a preliminary survey of the relative ease and merits of the indirect and direct methods of venous pressure determination. One hundred unselected patients, representing the population of a general medical service, male and female, young and old, cardiac and noncardiac, were studied. Following a basal rest period of fifteen minutes, during which it was noted that no marked variation occurred in heart and respiratory rates, venous pressure was determined first by the Eyster method, and then immediately afterward by the modified Moritz—von Tabora method. In 32 patients, no suitable (visible) vein could be found. Of the remaining 68 cases, venous pressures could be obtained by the indirect method in only 51 because of various difficulties with the apparatus. A reading was obtained by the direct method in all 100 patients. In none of the 51 cases with indirect and direct pressure readings was any exact coincidence noted. Because of its ease, accuracy and reliability, the direct method was selected for use in the present study.

TABLE II

		CONTROL	RHEUM.		AS.-HYP.		AS.-UNK.		RH. HYP. AS	HYP. UNK.	AS.	HY-PERTH.	UNK.	UNK.
			AF	RSR	AF	RSR	AF	RSR	AF	RSR	RSR	RSR	AF*	RSR
NO. OF CASES		20	27	2	8	5	9	2	2	2	2	1	6	2
AV. FOR GROUP		7.7	9.4	6.8	7.5	4.6	7.2	4.0	10.7	5.9	7.0	4.7	8.8	4.4
Range between min. and max.	0- 2.9	15	3	1	1	3	2	1	-	-	-	-	-	1
	3- 5.9	4	11	-	3	1	3	1	1	2	-	1	4	-
	6- 8.9	1	5	-	4	1	2	-	1	-	1	-	2	1
	9-11.9	-	6	1	-	-	1	-	-	-	1	-	-	-
	12-14.9	-	-	-	-	-	1	-	-	-	-	-	-	-
	15-17.9	-	2	-	-	-	-	-	-	-	-	-	-	-

*Includes one case of auricular flutter.

RESULTS

The results obtained from the study of a group of 20 normal individuals are summarized in the first column of Table II. These observations were made at about the same time each day under the same controlled conditions, namely, rest period of fifteen minutes, and heart and respiratory rates showing only very slight fluctuation. Fifteen cases show a range of 2.9 cm. or less between minimum and maximum;

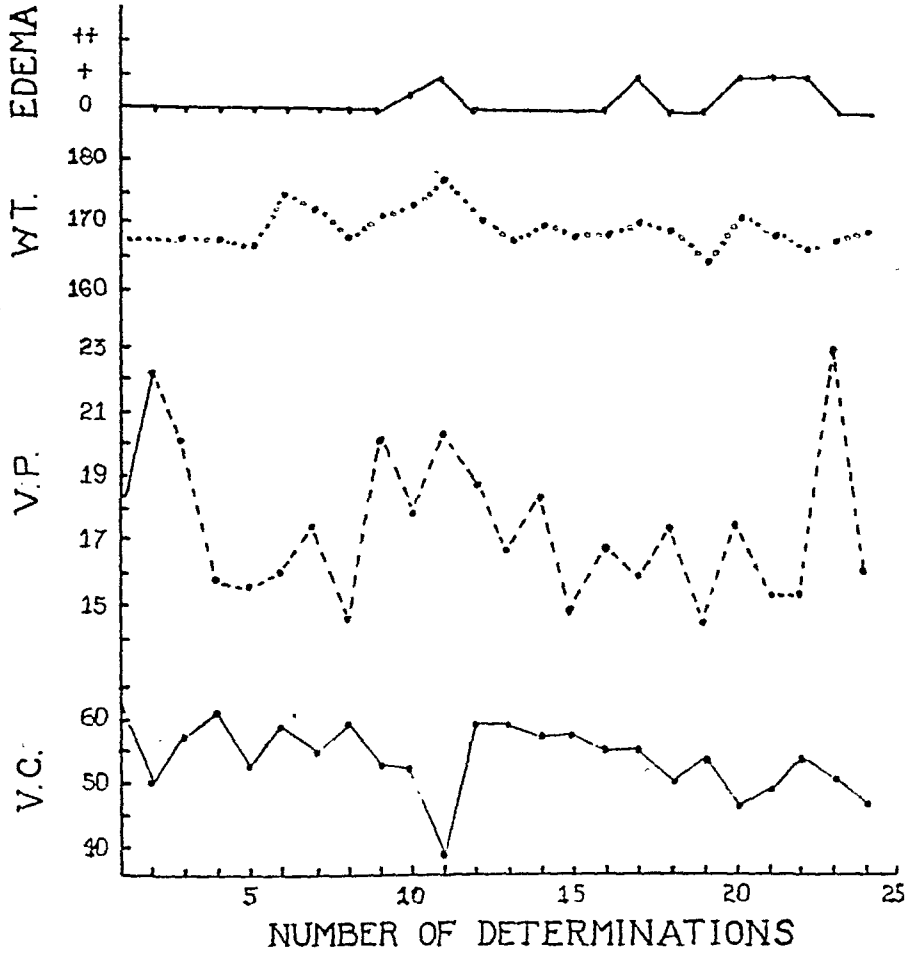

Fig. 1.—Typical case of rheumatic heart disease, with mitral stenosis and insufficiency and auricular fibrillation. Vital capacity (*V.C.*) in percentage of normal (according to the Peabody scale), venous pressure (*V.P.*) in centimeters of water, weight (*Wt.*) in pounds, and the degree of peripheral edema are plotted for each clinic visit.

14 cases range from 3 to 5.9 cm.; and one case ranges between 6 and 8.9 cm. Case 19 shows the fluctuation over a nineteen-minute interval of continuous observation. Cases 21, 22, and 23 illustrate the changes

CASE 19	CASE 21	CASE 22	CASE 23
6:20 9.4	10:30 A.M. 8.5	10:30 A.M. 4.0	4:15 4.2
6:22 8.3	11:30 A.M. 9.0	11:00 A.M. 4.1	4:45 4.1
6:25 6.5	meal	meal	meal
6:27 7.4	12:15 P.M. 6.2	2:45 P.M. 2.2	5:30 3.6
6:28 7.2	12:45 P.M. 6.0	4:00 P.M. 2.2	5.45 3.4
6:29 6.7	4:00 P.M. 8.4	4:30 P.M. 3.0	6:15 4.3
6:30 6.0		5:00 P.M. 4.4	
6:33 6.1			
6:36 6.2			
6:39 6.3			

during the day and also suggest that meals may influence venous pressure, contrary to the statement of Eyster.[14]

The remaining columns of Table II summarize the results of the study of 68 patients. They are tabulated according to etiology and rhythm. Although the group as a whole has well-advanced heart disease, a reading is not included if the patient was considered clinically to be in congestive failure at the time the determination was made. All the patients are well digitalized and the factor of heart rate is controlled. The respiratory rate did not show any significant change.

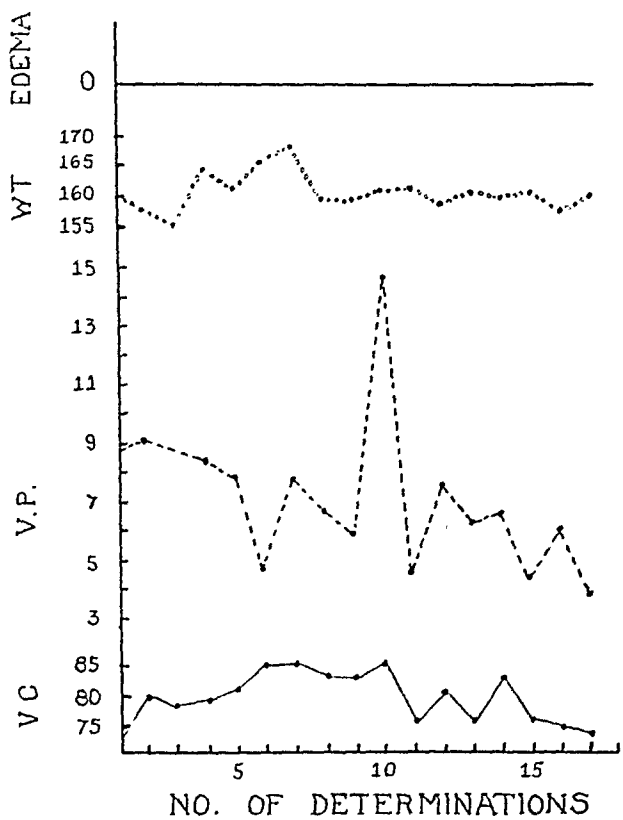

Fig. 2.—Typical case of hypertensive-arteriosclerotic heart disease with auricular fibrillation.

The average venous pressure for the group as a whole is essentially the same as in the control group—7.6 cm. for the cardiac patients against 7.7 for the normal subjects. The fluctuation between minimum and maximum is greater than in the normal series. Within the series, the rheumatic-hypertension-arteriosclerosis group has the highest level of venous pressure (10.7 cm.). The numerically largest group (rheumatic with 29 cases) has the next highest level (9.2 cm.), and this is above the normal group value.

Figures 1 and 2 are taken from two typical cases. Vital capacity, weight, edema, and venous pressure are plotted for each visit. These

cases illustrate a finding noted on several occasions, namely, an inexplicable rise in venous pressure, unassociated with any change in the patient's immediate condition or in his subsequent course.

The effect of cardiac rate and rhythm on venous pressure when these factors produce congestive symptoms has long been appreciated.[14] Fig. 3, taken from the case of auricular flutter, illustrates the effect of carotid sinus pressure. The ventricular rate was reduced from 120 to 60 and the venous pressure dropped from 10.6 cm. to 4 cm. This observation was repeated once at a later date.

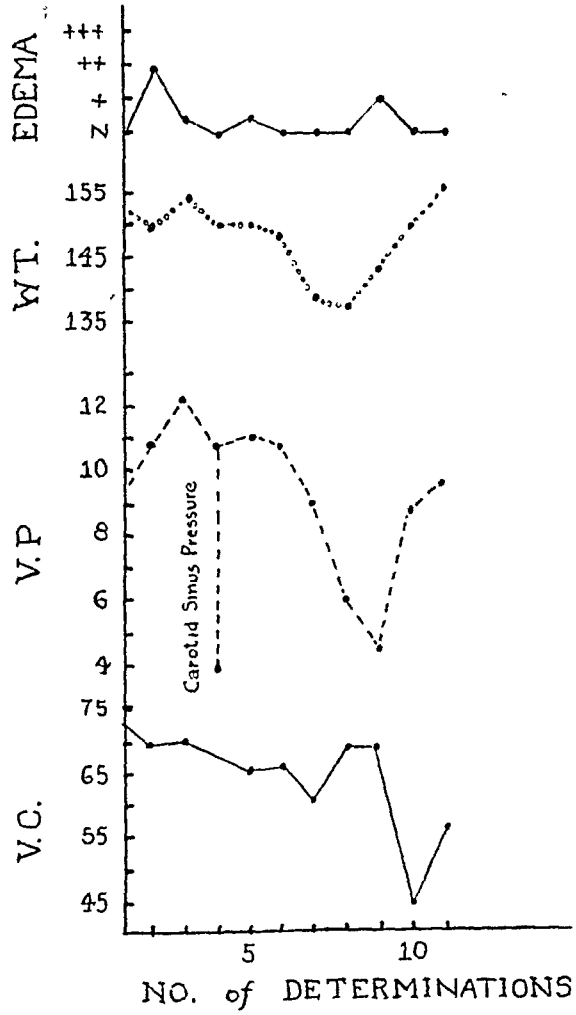

Fig. 3.—Case of auricular flutter of ten years' duration. The effect of carotid sinus stimulation on venous pressure is shown.

Although patients showed sporadic elevation of venous pressure without congestive failure, there was a distinct correlation between a sustained rising venous pressure and the appearance of failure, as noted by Eyster. However, the usual clinical signs were apparent at the same time that the pressure first became elevated. Case 71 had clinical evidence of well-defined failure with a pressure of 8.1 cm. On at least ten other occasions, his pressure was over this value, ranging up to 11.0 cm. Thus, this case might be considered to be one of failure in the absence of any marked elevation of venous pressure.

In Case 45 the patient was in congestive failure on Feb. 23, 1933, with a pressure of 13.7, yet on Aug. 24, 1933, with a pressure of 13.6, he apparently was entirely free from clinical symptoms.

There were four cases in which negative venous pressures were obtained, three in the arteriosclerosis and hypertension group, and one in the arteriosclerosis and unknown group.

DISCUSSION

A critical evaluation of the significance of changes in venous pressure in ambulatory cardiacs must include answers to these questions: 1. What is the normal range and variation in venous pressure? 2. Can venous pressure become elevated above normal without other signs of failure being present? 3. Is a rise in venous pressure the earliest or the most reliable sign of failure?

In the normal group the average venous pressure did not exceed 10.4 cm. although a maximum of 13.3 was obtained. This average figure is in accord with the normals quoted by Eyster.[14] Hooker and Eyster,[16] with indirect measurements, found that "a variation between a few centimeters of positive pressure up to 18 cm. is not uncommon, and the range of pressures was large" in a normal group. Bedford and Wright[17] also reported a considerable normal variation, using the direct method. Inasmuch as both the direct and indirect methods have been employed, any implication that variation is due to the direct determination is not justifiable. If normal venous pressure is subject to such fluctuation, its significance in determining an abnormal state is automatically lessened.

The answer to the second question calls for a consideration of the sporadic marked elevations in pressure referred to previously. No satisfactory explanation could be found at the time of the observation on the basis of physical findings or even in subjective complaints. The subsequent course during the next few months likewise failed to give any clue to the rise. Local causes and technical errors excluded, one can only conjecture at some mechanism which produces a temporary venous hypertension.

The exact nature of this mechanism is not clear. Henderson and his associates[18] have demonstrated variations in intramuscular tonus and found that this tonic intramuscular pressure is of extreme importance in the venous return to the heart. Widespread variation in muscle tonus, affecting venous return and pressure, may be the underlying cause for the fluctuations noted. Another theoretical explanation is that of venous spasm, a mechanism analagous to that invoked for arteries in many cases of transient arterial hypertension. The occurrence of venous spasm is supported by the clinical experience in which a vein contracts rapidly when a venipuncture is attempted.*

*This has been seen by Evans: New England J. Med. 207: 934, 1932.

In this series, a sustained rise in venous pressure could not be demonstrated in any case at an appreciable interval before clinical signs of failure developed. To be sure, a rise roughly paralleled the appearance of failure, but venous pressure itself could not be used in the long-range prognostication of impending failure. Therefore, unless one is aware of the fact that sporadic marked elevations of pressure can occur, finding such an elevation on a single occasion might lead to the erroneous conclusion that failure is impending. The evidence gathered in this study indicates that, although venous pressure rises with the appearance of congestive heart failure, it is not the most reliable, nor necessarily the earliest, sign of failure.

SUMMARY

A brief summary of the methods in use for studying circulatory efficiency is given and the physiological rationale of venous pressure determinations is discussed.

The results of an intensive study of 68 ambulatory cardiac patients are analyzed and compared with a control series. The average venous pressure for the cardiac group as a whole is the same as for the control group, although the former shows a greater fluctuation. Rise in venous pressure roughly parallels the development of congestive heart failure but it does not antedate the appearance of clinical symptoms.

The author wishes to thank Dr. Arthur C. DeGraff for his helpful suggestions throughout the course of this investigation.

REFERENCES

1. Brittingham, H. H., and White, P. D.: Cardiac Functional Tests, J. A. M. A. 79: 1901, 1922.
2. Gillespie, R. D., Gilson, C. R., and Murray, D. S.: Effect of Exercise on Pulse Rate and Blood Pressure, Arch. Int. Med. 12: 1, 1925.
3. Schneider, E. C.: A Cardiovascular Rating as a Measure of Physical Fatigue and Efficiency, J. A. M. A. 74: 1507, 1920.
4. Schmitz, H. W.: Vital Capacity, Respiratory Frequency, Pulse Rate and Systolic Blood Pressure in Heart Disease: Their Importance in Classifying Patients, Arch. Int. Med. 36: 628, 1925.
5. Master, A. M.: The Two-Step Test of Myocardial Function, Am. Heart J. 10: 495, 1935.
6. Peabody, F. W., and Sturgis, C. C.: Clinical Studies in Respiration. VII. Effect of General Weakness and Fatigue on the Vital Capacity of the Lungs, Arch. Int. Med. 28: 501, 1921.
7. Peabody, F. W., and Sturgis, C. C.: Clinical Studies in Respiration. IX. Effect of Exercise on the Metabolism, Heart Rate and Pulmonary Ventilation of Normal Subjects and Patients With Heart Disease, Arch. Int. Med. 29: 277, 1922.
8. Peabody, F. W., and Wentworth, J. A.: Clinical Studies in Respiration. V. Vital Capacity of the Lungs and Its Relation to Dyspnea, Arch. Int. Med. 20: 443, 1917.
9. Grollman, A.: Cardiac Output in Health and Disease, Baltimore, 1932, Charles C. Thomas.
10. Bazett, H. C., Cotton, F. C., Laplace, L. B., and Scott, J. C.: The Calculation of Cardiac Output and Effective Peripheral Resistance From Blood Pressure Measurements, With an Appendix on the Size of the Aorta in Man, Am. J. Physiol. 113: 322, 1935.

11. Patterson, S. W., and Starling, E. H.: On the Mechanical Factors Which Determine the Output of the Ventricles, J. Physiol. 48: 357, 1914.
12. Straub, H.: Dynamik des Säugetierherzens, Deutsches Arch. f. klin. Med. 115: 531, 1914.
13. Harrison, T. R.: Failure of the Circulation, Baltimore, 1935, Williams & Wilkins Company.
14. Eyster, J. A. E.: The Clinical Aspects of Venous Pressure, New York, 1929, Macmillan Company.
15. Moritz and von Tabora: Über ein Methode, beim Menschen den Druck in oberflächlichen Venen exakt zu bestimmen, Deutsches Arch. f. klin. Med. 98: 475, 1910.
16. Hooker, D. R., and Eyster, J. A. E.: An Instrument for the Determination of Venous Pressure in Man, Bull. Johns Hopkins Hosp. 19: 274, 1908.
17. Bedford, D. E., and Wright, S.: Observations on Venous Pressure in Normal Individuals, Lancet 2: 106, 1924.
18. Henderson, Yandell, Oughterson, A. W., Greenberg, L. A., and Searle, C. P.: Muscle Tonus, Intramuscular Pressure and the Venopressor Mechanism, Am. J. Physiol. 114: 261, 1936.

THE TRANSITIONS BETWEEN NORMAL SINUS RHYTHM, VENTRICULAR ESCAPE, A-V NODAL RHYTHM, AND A-V DISSOCIATION

A Report of 12 Cases, Including 7 Showing Interference Dissociation*

Frank B. Cutts, M.D.
Providence, R. I.

DURING the past two years there have appeared at this hospital five patients whose electrocardiograms have shown the control of the ventricular beat changing frequently between the sino-auricular node and the auriculoventricular node. Interest in these cases stimulated a search through the electrocardiographic files, which contain tracings on somewhat over 8,000 patients, and seven additional cases were discovered exhibiting this same unusual condition. As previous reports in the literature on this subject have been based, in most instances, on study of two or three patients, it was felt that a group of cases of even this modest size might yield some information of interest.

It is worthy of emphasis that in the electrocardiograms in this series the control of the ventricular beat vacillated almost continuously between the sino-auricular and the auriculoventricular nodes—the disturbance in rhythm being usually discernible in all the three conventional leads. Therefore, the following types of related rhythm abnormality are not considered here: (1) Tracings in which the P-wave changes in form or amplitude but maintains its normal position in front of the QRS complexes. Such changes are believed to be due to the displacement of the site of impulse formation from the more irritable upper to the less irritable lower portions of the sino-auricular node, resulting perhaps from variations in vagal tone.[1, 2] (2) Instances of complete heart-block. (3) Instances of isolated or relatively infrequent ventricular escape. This exclusion of transient ventricular escape is admittedly arbitrary, for the same factors that produce ventricular escape will, if they become more pronounced, result in persistent interference dissociation or A-V rhythm.[3] However, transient ventricular escape is relatively common and well understood, while the types of irregularity under discussion here are rather rare.

It will be well at this point to indicate what we mean by A-V rhythm, A-V dissociation, and interference dissociation, and to outline the conditions under which these abnormalities in rhythm may appear. A-V

*From the Heart Station of the Rhode Island Hospital, Providence, R. I., under the direction of Dr. Frank T. Fulton.

rhythm occurs when the entire heart, both auricles and ventricles, responds to impulses arising in the A-V node. Under such conditions the A-V node is more irritable than the S-A node, thereby discharging impulses at a more rapid rate. The QRS complexes are usually similar, except for minor variations, to those occurring when the heart responds to impulses of sino-auricular origin. The P-waves are usually inverted (indicating retrograde conduction) and may appear shortly before, during, or after the QRS complexes. In a few instances, however, the P-waves may be upright in lead I.[4, 5] A-V dissociation occurs when the auricles and ventricles are beating independently, the auricles responding to the S-A node and the ventricles to the A-V node. When both forward and retrograde conduction between the auricles and ventricles are blocked, at a slow heart rate, the common type of complete heart-block results. When, however, as occurs in seven of the cases under discussion here, (1) only retrograde conduction is blocked and (2) the A-V node is more irritable and is discharging impulses at a faster rate than the S-A node; the ventricles respond part of the time to the A-V node and part of the time to the S-A node, the latter occurring when impulses from this node fall at a time when the ventricles are no longer refractory as a result of the previous contraction. Because of the retrograde conduction block, the auricles respond only to the slower S-A node. Thus beats of S-A origin are interspersed in a record that otherwise has the appearance of complete A-V dissociation. This interplay between the S-A and the A-V nodes, with the resulting ventricular irregularity, is an example of interference dissociation.[6] In this condition the P-waves are upright (except perhaps in Lead III),[7] and they characteristically do not have any constant time relation with the QRS complexes.[8]

In order for the transitions between normal sinus rhythm, ventricular escape, A-V rhythm, and A-V dissociation to occur, it is usually necessary for the S-A and the A-V nodes to have, temporarily at least, nearly the same rate of impulse formation. Under such conditions a relatively slight change in the rhythm of one node or the other, due to variation in vagal or sympathetic tone or some other cause, may cause a transition to some other type of rhythm. In one case observed by Jones and White,[9] a change from the recumbent to the sitting position was frequently followed by a change from S-A to A-V rhythm.

There are three conditions under which the A-V node may become more irritable than the S-A node and hence initiate a change from normal sinus rhythm to ventricular escape, A-V rhythm, or A-V dissociation:[10] (1) When there is considerable depression of the S-A node. Such a condition is often associated with marked sinus arrhythmia and may arise as a result of deep respiration,[11] pressure on a sensitive carotid sinus,[10] digitalis[10, 12] or quinidine[13] administration, ocular pressure,[14] or some ill-defined or unknown cause. It has been shown to be associ-

ated at times with the partial asphyxia occurring with Cheyne-Stokes respiration.[15] (2) When there is increased irritability of the A-V node. This may result from infection,[16] especially rheumatic infection,[8] from administration of atropine,[10] especially in the first few minutes of its effect,[12, 14, 17] or again from unknown causes. (3) When there is a combination of the two effects described in 1 and 2.[10] In experimental animals the A-V node may become more irritable than the S-A node as a result of (a) destruction of the S-A node, (b) cooling the S-A node, (c) warming the A-V node, or (d) stimulation of the right vagus and the left sympathetic nerves.[18]

Following are brief summaries of the hospital records of a few representative cases. For the most part only the cardiac symptoms and signs are recorded here.

CASE 1.—(Case 9 in Table I.) B. F., thirty-seven-year-old white, single, French knitter, was admitted Nov. 19, 1934, complaining of weakness for several years and a slow heart rate for an unknown period. The past history was irrelevant. Fifteen and seven years previously she had "nervous breakdowns," the nature of which she could not explain adequately. Six years ago she noticed the onset of a head tremor, which has persisted to date. Four weeks prior to entry she had the grip and since that time had been conscious of a slow forceful heart action and increased weakness.

The significant findings on physical examination were the presence of a constant fine tremor of her head and the cardiac abnormality. On November 21 the following was noted: The heart appeared slightly enlarged to percussion. The rate was 48 per minute, and the rhythm was not completely regular, as the heart was observed to speed up for a few beats about every 20 seconds. There were no definite murmurs, but the heart sounds were not always the same—at times the first and second sounds were loud and clear, while at other times both sounds seemed slurred and reduplicated. Occasional vigorous pulsations were observed in the neck veins, occurring after the first sound was heard at the apex. On November 27 the patient was fluoroscoped, and an orthodiagram was made. The heart diameter was 11.8 cm. and the chest diameter was 20.5 cm. No definite enlargement of any heart chamber was detected. The cardiac pulsations were very vigorous and at times the auricles could be seen to beat after the beginning of the ventricular contractions. This was best seen in the right oblique view.

Laboratory studies, except electrocardiography, contributed no positive information. The Wassermann reaction was negative; the urine and blood were normal; and the blood urea nitrogen and the blood sugar were within normal limits.

She gradually improved without medication and was discharged Dec. 8, 1934. When last seen, May 4, 1935, she was feeling well and had no complaints.

Electrocardiographic Findings.—The same type of arrhythmia present in Fig. 1 was also present in Cases 1, 4, 7, and 10 (Table I). In order to conserve space, and since little or no information would be added by their detailed presentation, Fig. 1 is considered illustrative of the irregularities of rhythm in these five cases.

It is readily seen that the fundamental abnormality in this record is a change from S-A rhythm to A-V rhythm, and then back again to S-A rhythm. An important predisposing factor in this change is the

presence of marked sinus arrhythmia, the interval between auricular beats varying from 0.92 sec. to 1.60 sec. (the interval between auricular beats 10 and 11 and between 2 and 3). When the auricular rate slows up sufficiently, the A-V node escapes and takes control of the ventricular beat. This is seen to occur at beat 3. Auricular beat 3 is apparently buried within the QRS complex. Auricular beat 4 is of some interest as a transitional beat. The P-wave is nearly isoelectric. This is probably due to the fact that impulses from the S-A and the A-V nodes have reached the auricles at about the same instant so that a portion of the auricles responds to each center. This is the explanation offered by Lewis[18] for similar auricular waves.



Fig. 1.—B. F. Continuous tracing in Lead II, Nov. 20, 1934. The diagrams beneath this and the subsequent electrocardiograms are arranged in identical fashion and may be described together. The vertical black bars in the upper strip marked *A* represent the auricular beats and are placed directly beneath the P-waves in the accompanying electrocardiogram. The interval between the auricular beats is recorded in hundredths of a second. In the middle strip, marked *P-R*, are recorded in hundredths of a second the P-R intervals (preceded by a plus sign) or the R-P intervals (preceded by a minus sign)—depending on whether conduction is from auricles to ventricles or vice versa. The arrows in this middle strip indicate the direction of impulse conduction and are included only when it seems probable that a beat has been actually conducted. In the bottom strip, marked V, the heavy vertical bars represent and are placed directly beneath the ventricular beats. The interval between beats is recorded in hundredths of a second. The auricular and ventricular beats are numbered consecutively in each diagram. Note especially the variation in the form and position of the P-waves.

By beat 5, A-V nodal rhythm is fully established, and there is undisturbed retrograde conduction from ventricles to auricles. Finally at auricular beat 9, the S-A node has discharged an impulse before one has been conducted from the A-V node, and thus the S-A node takes

control of the auricle, causing an upright P-wave. By auricular beat 10, the S-A node has speeded up sufficiently to regain control of the entire heart.

During the period when the ventricles are under the control of the A-V node (beats 3 through 9), it is to be noted that there is some irregularity, the interventricular intervals varying from 1.43 sec. to 1.28 sec., but this arrhythmia is much less pronounced than is the sinus arrhythmia. The QRS complexes are nearly the same regardless of which node is in control. Ventricular beat 3 shows a higher R-wave because of the simultaneous occurrence of R-wave and upright P-wave. Slurring occurs slightly higher on the descending limb of the R-wave when the beats are of A-V nodal origin (e.g., ventricular beats 7 and 8) than when they are of S-A origin (e.g., beats 1 and 2). The R-P interval (0.17 sec.) is practically identical with the P-R interval (0.16-0.18 sec.).

After the control tracing reproduced above was taken, the effect of various other procedures on the rhythm was tried. Right and left carotid sinus pressure for a period of forty seconds produced no detectable changes in the electrocardiogram. A drink of iced water was without effect. The patient rapidly raised her trunk to assume the sitting position twenty times with resulting mild dyspnea, and yet the arrhythmia portrayed above persisted. However, the ventricular rate remained at 46, as in the control tracing, and it is quite possible that more intensive exercise or the administration of adrenalin might have yielded different results. Finally 1/37 gr. (4 tablets of 1/150) of atropine was given subcutaneously. After fifteen minutes the rhythm was much more regular, mostly S-A in origin, but a few A-V nodal beats persisted, the ventricular rate at this time being 76. After thirty minutes the first half of the tracing showed beats of S-A origin, but this then changed to A-V nodal rhythm (rate 56). The most striking change following atropine administration was the disappearance of the gross irregularity in rhythm. The dose of atropine was perhaps not large enough for full atropinization, and the tracings should have been taken more frequently. However, the appearance of A-V nodal beats at a rate of 76 per minute does indicate that at that time the A-V node was released from vagal control[17] or stimulated[18] fully as much by the atropine as was the S-A node.

A tracing was finally made May 4, 1935, some six months after that shown in Fig. 1, and at that time all the beats were of S-A origin though a moderate degree of sinus arrhythmia persisted.

CASE 2.—(Case 12 in Table I.) F. J., sixty-nine-year-old white, married, Roumanian housewife, was admitted on Dec. 21, 1931, with the symptoms and signs of bronchopneumonia. She had been very obese—weight 275 pounds, height 5 feet 2 inches—for years and had become progressively dyspneic over the same period.

The outstanding findings on physical examination were the marked obesity, scattered râles through both chests, and a blood pressure of 230/130. Examination of the heart was unreliable because of the immense fat pads. During the first half of her hospital stay she ran a fever up to 101° F., but she slowly improved and left for a bed-and-chair existence at home on March 9, 1932.

She remained a cardiac invalid and could not take more than a few steps without experiencing dyspnea. She finally died at home in October, 1932. The details of her death are not known, but she apparently suffered from progressive heart failure.

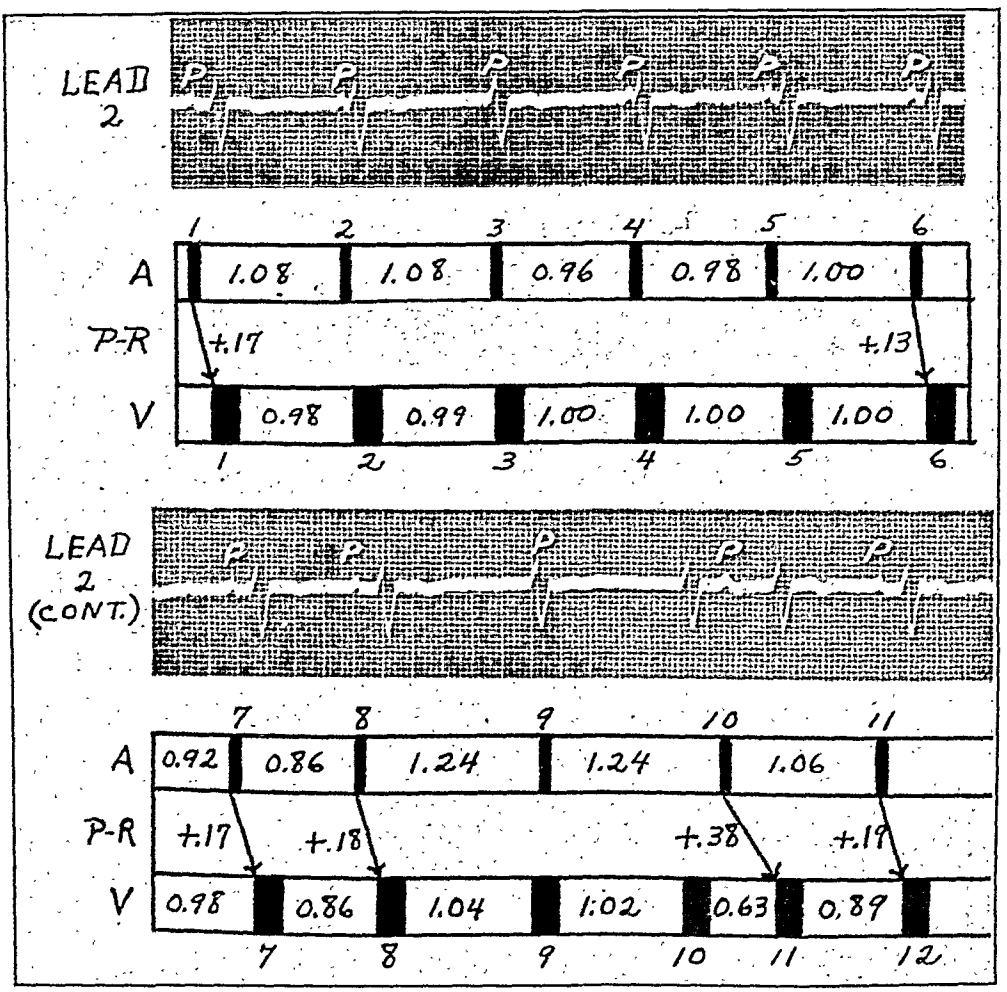

Fig. 2.—F. J. Continuous tracing in Lead II, Jan. 28, 1932. Of especial interest is the auricular beat 10 followed by ventricular beat 11 after a long P-R interval.

Electrocardiographic Findings.—The same type of rhythm abnormality shown here was present in Case 8 (Table I). The tracings in this second case have been published elsewhere[19] and will not be repeated here.

It should be noted at the outset that intraventricular block is present and that the T-waves are depressed, both being evidence of the serious myocardial disease present. At the beginning of the tracing it is observed that the A-A interval is longer than the V-V interval

(beats 1 and 2) and that the P-waves approach and merge into the QRS complex. At this time the control of the ventricular rhythm by the A-V node is greater than that by the S-A node and ventricular beats 2 and 3 are due to stimuli from the A-V node. At this point the S-A node speeds up for some reason and gradually returns to its normal position in front of the QRS complex. Thus by ventricular beat 6, or possibly 7, the S-A node is discharging its impulse sufficiently early so that the whole heart responds to it. However, after beat A-8, the S-A node suddenly slows up considerably and the ventricles again escape, A-9 falling within the QRS and A-10 following V-10. In fact A-10 falls at a time when the ventricles have partially recovered from their refractory period and the early beat V-11 is a response to A-10 after a considerably prolonged P-R interval. This long P-R interval is evidence that the conducting tissues are still partially refractory. After beat V-11, the S-A node speeds up somewhat and regains control of the heart for several beats. Nowhere in the tracing are there inverted P-waves following escaped ventricular beats, but this fact is not significant except after ventricular beats 10 and 11, especially the latter, when the auricles should no longer be refractory themselves to a stimulus arising in the A-V node. Hence the condition of retrograde block is present, at least after ventricular beat 11, and the (at times) slower S-A pacemaker is protected from the (at times) more rapid A-V node. Thus the S-A and the A-V nodes have at this time somewhere near the same rhythmicity (due in large measure probably to a depressed S-A node) and the S-A node, as it waxes and wanes, gains and then loses control of the heartbeat. This has been previously observed by Lewis.[18]

CASE 3.—(Case 3 in Table I.) V. H., a twenty-seven-year-old white, native, married waitress was admitted to the hospital on May 27, 1932, because of dyspnea and evidence of recurrent rheumatic fever. Her first attack of rheumatic fever had been at the age of four years, and she had had several recurrences since then.

The patient was quite ill at entry and had a fever of 103° F., which gradually subsided during the next two weeks. The physical findings of especial interest were limited to her heart. On June 7, 1932, she was examined by Dr. Marshall Fulton and the following description is extracted from his notes:

The heart rate was about 80, and the action was irregular. The impulse was diffusely felt over a wide area, and there was a striking difference in the intensity of the impulse with different beats. This was even more definitely brought out on auscultation. At times the first sound was soft and just audible; at other times it was very abrupt, loud and snappind. At the apex there was a low-pitched diastolic rumble, and at the base, a long diastolic murmur typical of aortic insufficiency. The heart was definitely enlarged. When the heart was irregular, the patient felt it "jumping" in her chest.

The patient gradually improved on bed rest and salicylates and was discharged July 3, 1932. She left town shortly after this and attempts at follow-up have been unsuccessful.

Electrocardiographic Findings.—This tracing is practically identical with that obtained in Case 2 (Table I), which will not be discussed

separately. The auricular rate is again slower than the ventricular (beats 2, 3, 4, etc.), and the condition of retrograde block is present, so that no impulses of A-V origin are conducted back to the auricles. However, it is observed that there is considerably less arrhythmia of the S-A node and that the rhythm of the A-V node is faster than in Fig. 2. Thus the fact that the two nodes have somewhere near the same rhythmicity is due, in considerable part at least, to enhanced irritability of the A-V node. By ventricular beat 4, at least, the ventricular pacemaker in the A-V node has escaped and continues to control the ventricular beat through beat V-10, the auricles responding unmolested to the S-A node. Auricular beat A-10 falls at a time when the ventricle is only partially refractory and so the ventricle responds after a long P-R interval, resulting in the quickened beat V-11. The interval between V-11 and V-12 is also considerably shortened. The explanation for this is to be found in the nearly normal P-R interval between A-11 and V-12, which occurs because A-11 falls at a time when the ventricle is no longer refractory. If the P-R interval between A-10 and V-11 were the same as between A-11 and V-12 (namely 0.21 sec.) the interval between V-11 and V-12 would be 0.77 sec. instead of 0.52 ($0.46-0.21 = 0.25$ and $0.52 + 0.25 = 0.77$). Thus it is seen that V-11 occurs late because of the long P-R interval preceding it.

One other point worthy of comment is to be observed at the end of the tracing. When the S-A node has succeeded in regaining control of the heart, it speeds up for several beats, and the P-wave maintains its normal position in front of the QRS complex. This finding is present in several published electrocardiograms.[1, 8, 17, 20, 21, 22] After a short time, however (not shown in this illustration), the S-A node again slows down, and the whole process repeats itself. This tendency of the arrhythmia to recur at fairly regular intervals is known as allorhythmia.[18]

Why the S-A node often speeds up after it gains control of the entire heart is not clear. Possibly, as suggested by Zeisler,[23] the coronary blood flow, with subsequent better nutrition of the S-A node, may be maximal when the heart chambers are beating in their normal sequence. An apparently related phenomenon was observed by Wilson and Robinson[24] in complete heart-block. They noted that the interauricular intervals which contained a ventricular systole were often shorter than the interauricular intervals containing no ventricular beat.

CASE 4.—(Case 6 in Table I.) J. P., a nineteen-year-old, single, Italian unemployed girl, was admitted March 14, 1936, for the fifth time because of recurrent rheumatic fever. The first attack occurred at the age of seven years.

At entry she had a fever of 102° F., which persisted for nearly three weeks, gradually subsiding to normal. The significant physical findings were limited to her heart, which was moderately enlarged to the left as revealed by physical examination

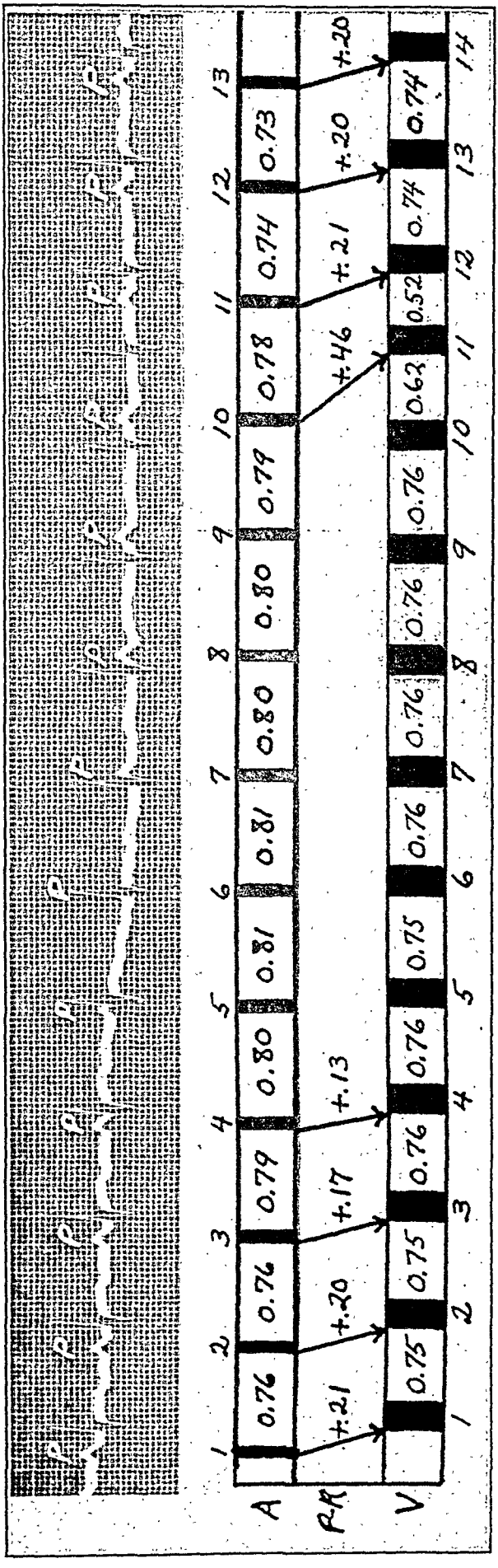

FIG. 3.—V. H. Lead II. June 15, 1932. Note the early ventricular beats 11 and 12, both of sino-auricular origin.

and by x-ray. There was a long blowing diastolic murmur to the left of the sternum, and the blood pressure was 136/30. There was an apical diastolic murmur present also, but the significant lesion appeared to be aortic regurgitation.

She gradually improved and was discharged May 1, 1936, for further rest at home. Unfortunately she was not carefully examined at the time when her heart was exhibiting the irregularity shown in the electrocardiogram, and so we do not know whether she showed variations in the first heart sound, as did the patient in Case 3.

Electrocardiographic Findings.—This is another example of interference dissociation and the abnormality here is very similar to that in Fig. 3. In the first part of the tracing the S-A node slows up, and the A-V node, being more irritable than normal, gains control of the ventricular beat. Retrograde block is present, and the auricular waves fall within and then to the right of the QRS. Finally, at beat A-7, the P-wave falls at a time when the ventricle is only partially refractory

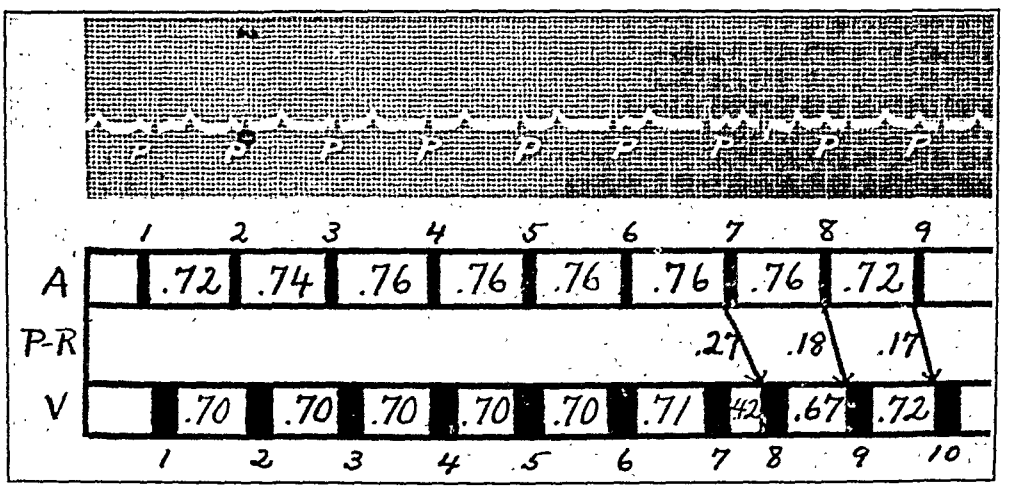

Fig. 4.—J. P. Lead II. March 27, 1936. Another example of interference dissociation. Note auricular beat 7 followed by ventricular beat 8 after a long P-R interval.

and a quickened beat V-8 results, after a long P-R interval. This ventricular complex is somewhat aberrant in form, probably because of some delay or variation in conduction of the impulse through the lower or more terminal portions of the ventricular conducting system. After the S-A node has gained control, it again speeds up for a few beats as in Fig. 3. The quickened beat V-9 has the same explanation as beat V-12 in Fig. 3.

This same patient has had many electrocardiograms taken during her several hospital entries. One taken Aug. 9, 1930, about six years before the one shown in Fig. 4, showed the P-wave approaching and finally merging into the QRS complex. In the short record taken at that time, the P-wave did not appear to the right of the QRS, and there was no interference dissociation. However, the A-V node was undoubtedly hyperirritable (the patient's temperature at this time was 102° F.) and

the same tendencies were undoubtedly present that are shown more strongly expressed in Fig. 4. Thus it is probable that this same arrhythmia may recur in the same patient after long intervals if the proper conditions are present.

CASE 5.—(Case 5 in Table I.) E. P., a twenty-one-year-old, male, Italian peddler, was admitted on July 30, 1935, because of painful, swollen joints of three days' duration. This was his initial attack of rheumatic fever.

His temperature at entry was 103° F., and remained about 102° F. for four weeks after entry. During this time he developed a pericardial friction rub followed by a rather large pericardial effusion. He had a moderately loud apical systolic murmur which persisted throughout his stay, except during the height of the effusion, when the heart sounds became practically inaudible. He was discharged Oct. 7, 1935, feeling well, and he was to remain at home in bed for two months.

He was examined at the time he was showing the electrocardiographic irregularities, and definite variations in the intensity of the first heart sounds were noted. The patient was of rather stolid nature and was not aware of any unusual sensa-

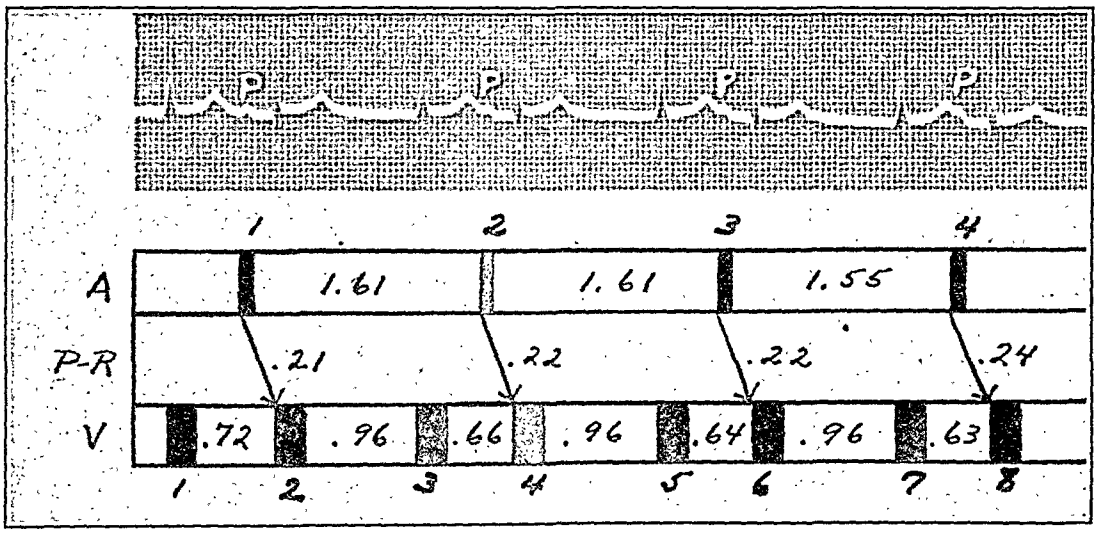

Fig. 5.—E. P. Lead II. Aug. 3, 1935. An unusual type of coupling with a slow auricular rate. Note the difference between the QRS complexes preceded by a P-wave and those with no preceding auricular wave.

tions himself. He was last seen on July 11, 1936. At that time he felt perfectly well. Examination of his heart was entirely negative. The rate was regular at 70, the size was normal to percussion, and there were no murmurs. There was no unusual pulsation of his chest wall and no distention of the neck veins to suggest significant pericardial involvement.

Electrocardiographic Findings.—This is one of several tracings taken on this patient. Several of these showed typical interference dissociation as shown in Figs. 2, 3, and 4. The one reproduced here was selected because it reveals an unusual type of coupling caused by the same mechanism as the arrhythmia in Figs. 2, 3, and 4. In the first place it is to be noted that there is some increase in the conduction time and that there is slight but definite elevation of the S-T interval. Both of these abnormalities are probably associated with the active rheumatic infection, the latter being due, in all probability, to the pericarditis. It is seen that the S-A node is underirritable and is discharging impulses

very slowly. The A-V node is definitely more irritable than the S-A node and gives rise to a ventricular beat (beats V-3, 5, and 7) at a fairly constant interval after the preceding beat of S-A origin (0.96 sec. in the above tracing). The auricular beats A-2, 3, and 4, because of the slow S-A rhythm, fall at a considerable interval after the preceding ventricular contractions, and hence the ventricle responds readily, being no longer refractory. There is no retrograde conduction.

Beats V-1, 3, 5, and 7 then are of A-V nodal origin, while beats V-2, 4, 6, and 8 are of S-A origin. These beats are seen to be different, those of A-V origin being lower and more slurred than those of S-A origin. This has been previously observed by others and is thought to be due to a slightly different path taken by the impulses of A-V origin.[1, 25]

CASE 6.—(Case 11 in Table I.) C. L., a sixty-six-year-old white, married, French housewife, was admitted Nov. 5, 1935, because of increasing dyspnea for the preceding six weeks. The onset of her disability followed a day of unusually hard housework. There had been some indefinite precordial oppression. While at home she had been taking an undetermined number of tablets, thought to be digitalis.

On physical examination she was seen to be quite ill. There were many râles throughout both chests. The heart was apparently enlarged, but there were no murmurs. The rhythm was regular at this time. The blood pressure was 220/140.

In the first electrocardiogram, taken Nov. 6, 1935, the rhythm was regular; there was left axis deviation; and the T-waves were upright in Lead I. In the fourth lead, however, the Q-waves were absent, but the T-wave was inverted normally. It was felt that she had hypertensive heart disease and probably coronary thrombosis of several weeks' duration. Medication consisted of digitalis gr. 1½ three times daily.

She remained about the same for four days and then quite rapidly developed a temperature of 102° F. She failed rapidly and died Nov. 11, 1935, apparently of a terminal bronchopneumonia. Autopsy permission was refused.

Electrocardiographic Findings.—This record was selected for reproduction because, though the waves are rather small and indistinct, it shows one variation of interference dissociation not present in any of our other patients. In this record there is an arrhythmia of the same type shown in Figs. 3 and 4. The A-V node is producing impulses quite rapidly and readily gains control of the ventricles for most of the tracing. There is no retrograde conduction, and beat V-6 is quite comparable to beat V-8 in Fig. 4 and beat V-11 in Fig. 3. There is very little difference in the QRS complex whether the beat originates in the S-A node or the A-V node. The point of especial interest in this record centers about beat A-9 and the interval between beats V-10 and V-11. It is seen that A-9 falls shortly after V-10 and is not followed by a ventricular response. However, the A-V node does not discharge an impulse after the usual interval (0.56-0.60 sec.), and the ventricle only responds after the next auricular beat (A-10). Thus it seems probable that beat A-9, although it did not evoke a ventricular response, has succeeded in discharging the A-V node and in destroying the impulse

that was in the process of being built up there. This might occur if we assume the presence of refractory conducting tissue below but not above the A-V node. These pauses in ventricular rhythm might be caused by a sudden change in the rhythm of the A-V node or by A-V nodal block (comparable to S-A block) independent of the auricular beat. However, our first explanation seems most reasonable because an identical break in rhythm occurred in two places in another tracing on this patient. In these pauses, the sequence of beats was exactly as illustrated in Fig. 6 (QRS→upright P-wave→beat of S-A origin). It seems most improbable that any independent variation in the rhythm of the A-V node would occur only in relation to a QRS complex followed by a P-wave—especially as this sequence (QRS followed by P) appeared only infrequently in the tracings.

The A-V node is thus delayed and does not give rise to another beat before the S-A node has discharged an impulse and taken control of the

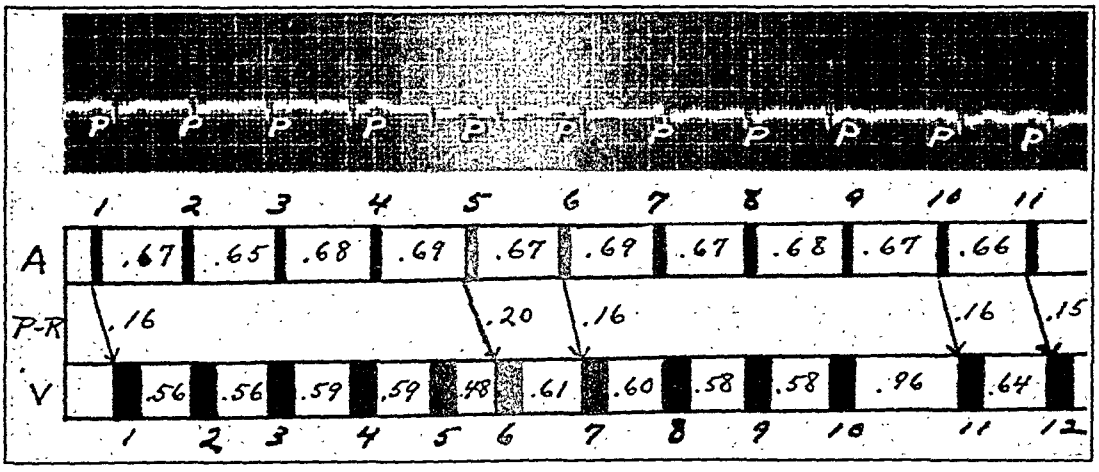

Fig. 6.—C. L. Lead I. Nov. 9, 1935. Especial interest in this tracing centers about the pause between ventricular beats 10 and 11. See discussion in text.

heart. A few beats after A-11, however, the A-V node regained control of the ventricular beat and the interference dissociation reappeared as in the beginning of the tracing.

COMMENT

One abnormality of rhythm not discussed or illustrated here, although closely related to those under discussion, is reciprocal rhythm, in which one retrograde auricular beat is sandwiched between two ventricular beats, one wave of excitation presumably traveling from the A-V node back to the auricle and then reentering the ventricle by some ill-understood path and producing a second ventricular beat. We have one patient, now being followed, who has shown this abnormality on several occasions. Since considerable discussion and several illustrations are necessary to present this patient's case adequately, it is planned to make him the subject of a subsequent report.

TABLE I

NO.	SEX AND AGE	CLINICAL DIAGNOSIS	CHANGES IN FIRST HEART SOUNDS	TEMPERATURE ON DAY OF EKG.	DIGITALIS	DATE OF EKG. AND VENTRICULAR RATE	COUPLED BEATS	DURATION OF IRREGULARITY	DATE LAST SEEN AND CONDITION
C. H. 1	M 21	Rheumatic fever	?	99.4	0	6/25/26 67	0	16± days	6/13/31 Dead
J. C. 2	M 15	Rheumatic fever	?	102.0	0	7/20/32 84	+	1± day	5/16/35 Fair
V. H. 3	F 27	Rheumatic fever	+	101.5	0	6/15/32 80	+	10± days	7/ 3/32 Fair (lost)
A. M. 4	F 11	Rheumatic fever	?	101.5	0	7/15/15 113	0	Few hours	12/16/15 Fair (lost)
E. P. 5	M 21	Rheumatic fever	+	102.0	0	8/ 3/35 74	+	9± days	7/13/36 Good
J. P. 6	F 19	Rheumatic fever	?	102.0	0	3/27/36 88	+	5± days	5/ 1/36 Poor
C. D. 7	M 22	Acute tonsillitis	+	99.0	0	5/27/32 54	0	4± days	5/31/32 Good (lost)
R. N. 8	F 27	Adrenal tumor	+	98.6	0	3/11/35 81	+	Few minutes	5/ 7/35 Dead
B. F. 9	F 37	? Paralysis agitans	+	98.6	0	11/20/34 46	0	15± days	5/ 4/35 Good
S. J. 10	M 67	Coronary thrombosis	?	99.2	0	12/15/32 79	0	?	1/ 9/33 Dead
C. L. 11	F 66	Bronchopneumonia	?	102.0	+	11/ 9/35 107	+	2± days	11/11/35 Dead
F. J. 12	F 69	Hypertensive heart disease	?	98.6	+	1/28/32 69	+	6± days	Oct., 1932 Dead

Table I contains a summary of some of the clinical data on these twelve cases, a portion of which seems worthy of further consideration. It is seen that six of the twelve patients suffered from acute rheumatic fever, and one other patient had acute tonsillitis—a related condition. So far as we know, previous reports on interference dissociation and A-V rhythm that have appeared in English have not mentioned rheumatic fever as an important cause. However, Oettinger and Neslin[8] described the occurrence of interference dissociation in seven patients with acute rheumatic fever. In a footnote they add that after subsequent observations they have noted its occurrence in fourteen out of 200 patients with rheumatic fever studied electrocardiographically. Such a high incidence of this relatively rare arrhythmia in patients with rheumatic fever certainly indicates that this disease must be considered an important predisposing factor in its production. Conversely, the occurrence of the electrocardiographic changes previously illustrated, especially in a young person, is highly suggestive of rheumatic infection. However, it should be mentioned that in our cases the rheumatic fever accompanying the arrhythmia was quite severe and easily recognizable by ordinary clinical observation.

Another apparently significant association was the relation of the arrhythmia observed to a febrile reaction. Thus, nine of the twelve patients had temperatures of at least 99° F. on the day the electrocardiogram showing the arrhythmia was taken. Six of these nine patients had temperatures over 101° F. Of the three patients showing no fever on the day of the electrocardiogram, one patient (Case 12) had just recovered from an attack of bronchopneumonia and had had a temperature of 102° F. a few days previously. Another (Case 9) had not had a temperature in the previous few days but had had a debilitating attack of grip about four weeks previously. The third patient (Case 8) was not observed to have an abnormal temperature but suffered from paroxysms of which marked transient hypertension was the most outstanding objective sign. In this latter patient, who was proved by operation to have a chromaffin cell tumor of the right adrenal,[19] the periods of marked generalized stimulation of the sympathetic system were probably to a large extent causative in inducing the arrhythmia.

Thus in the majority of these cases the association of the arrhythmia with concomitant active infection (Cases 1, 2, 3, 4, 5, 6, 7, and 11) or recent infection (Cases 9 and 12) seems significant. The slight fever in Case 10 was probably associated with recent coronary thrombosis, and the arrhythmia in this case is perhaps associated with faulty blood supply to one or both nodes. In the other cases mentioned above it would seem that infection, especially rheumatic infection, by direct involvement of the heart or perhaps (in nonrheumatic infections) by resulting toxemia, is an important factor in disturbing the rate of impulse

formation in the S-A and A-V nodes. The question may well be raised as to why this arrhythmia does not appear more often with rheumatic fever and infection. There are several possible answers, all speculative. Perhaps it may occur only when some inherent abnormality is present in one node or the other causing it to respond disproportionately or perversely to extraneous stimuli. Possibly, and this seems reasonable in view of what we know concerning rheumatic infection, it occurs when the rheumatic (or infectious) process is especially intense about one node or the other resulting in either stimulation or depression. However, such situations do not seem to occur ordinarily, and the usual result of infection is an increase in the rate of impulse formation of the S-A node, which thus continues to dominate the heart even if the A-V node has been correspondingly stimulated.

As regards contributory factors, comment should be made concerning the rôle of digitalis. Some authors[10, 23] have given much etiological importance to this drug in the production of this type of arrhythmia. It is undoubtedly of occasional importance, but it seems of considerable significance that only two of our twelve patients and none of Oettinger and Neslin's seven patients[8] received any digitalis prior to the appearance of the arrhythmia. Thus, in this group of cases at least, digitalis was of minor importance in the production of the arrhythmia. The patient in Case 12 was receiving only a maintenance dose of gr. 1½ daily and showed no other sign of digitalis intoxication. Case 11 had received 18 gr. in four days and perhaps more prior to entry to the hospital. That digitalis was of significance in producing the arrhythmia in these two patients cannot be denied, but it is our impression that its effect was, at the most, contributory.

Of the twelve patients, five were definitely observed to have changes in the intensity of the first heart sounds on the day when the electrocardiographic arrhythmia was present. This has been observed by others and Oettinger and Neslin[8] by means of a phonocardiograph were able to demonstrate an increased intensity of the first sound when the P-wave and QRS fell together or when the P-wave shortly preceded the QRS. This would be expected as there is a similar increase in the intensity of the first heart sound when the P-wave and QRS fall together in complete heart-block.[18] It is probable that all twelve of our patients would have shown this variation in the first heart sound if careful auscultation had been performed at the time when the arrhythmia was present.

Case 9 showed a sudden vigorous pulsation of the neck veins concomitant with the increased intensity of the first sound. More careful observation would probably have revealed this finding in several other cases. However, since this observation was not recorded in our other cases, we do not have satisfactory objective evidence of its frequent occurrence.

When these sudden intense first heart sounds occur, some patients complain of more or less palpitation. Its presence was definitely noted in Cases 3, 8 and 9. In Case 5 it was absent at the time loud beats were heard, even though the patient was specifically questioned in this regard. In the remaining cases, we do not have exact data regarding its occurrence. It is probable that the more sensitive patients feel these forceful beats, while less sensitive ones do not. The situation is thus comparable to the presence or absence of palpitation with extrasystoles. Wilson[17] had three patients who complained of intense palpitation during experimentally induced A-V rhythm.

As regards the duration of the irregularity, we have no precise data. A rough approximation of the upper limits of duration was arrived at by recording the time interval between the first record showing the arrhythmia and the first record in which it was absent—provided the records were taken at reasonably short intervals. By such means it seems that the irregularity may persist for from a few minutes (Case 8) to sixteen days (Case 1). In the average case it apparently lasts a few days. In Oettinger and Neslin's cases[8] the irregularity lasted usually from one to six days.

Follow-up studies, so far as possible, have revealed that five of the twelve patients are dead (Cases 1, 10, and 12, heart disease, and Case 11, heart disease complicated by bronchopneumonia). In Case 8 death in shock resulted shortly after operation for removal of the adrenal tumor.[19] Three patients (Cases 2, 3, 6) had evidence of advanced rheumatic heart disease when last examined. In Case 4 there was evidence of slight rheumatic heart disease at the last visit. Three patients (Cases 5, 7, and 9) had no definite evidence of heart disease when last studied. As regards the clinical significance of the arrhythmias observed in these patients, the conclusions of Richardson[26] concerning A-V rhythm seem distinctly applicable. He writes, "A-V rhythm is not in itself fatal, but is frequently associated with severe infection or severe and chronic cardiac disease." With this we agree.

SUMMARY AND CONCLUSIONS

1. Twelve patients are reported whose electrocardiograms showed the control of the ventricular beat changing frequently between the S-A node and the A-V node. The electrocardiograms of seven of these patients exhibited interference dissociation.

2. In order for these transitions to appear, the A-V node must become temporarily more irritable than the S-A node. Such a condition may occur (a) when there is considerable depression of the S-A node, (b) when there is increased irritability of the A-V node, and (c) when there is a combination of the two effects described in (a) and (b).

3. If, when the A-V node is more irritable than the S-A node, retrograde conduction to the auricles is possible, A-V rhythm results; if retrograde conduction is blocked, interference dissociation appears.

4. In a given instance of this arrhythmia the auricular rate is usually more variable than the ventricular rate.

5. When control of the ventricular beat varies between the nodes, the QRS complexes may or may not show differences between beats of S-A and A-V origin.

6. Evidence is presented strongly suggesting that the S-A node may discharge a partially formed impulse in the A-V node without a resultant ventricular response.

7. Active rheumatic fever was present in six of our twelve cases and can be an important predisposing factor in the production of the arrhythmias under discussion.

8. Nine of our twelve patients had abnormally high temperatures on the days that the electrocardiograms showing the arrhythmias were taken.

9. Ten of the twelve patients had no digitalis prior to the appearance of these transitions in rhythm.

10. Subjectively these arrhythmias are frequently associated with palpitation and objectively with changes in the intensity of the first heart sounds, with coupled beats, and, at times, with sudden vigorous pulsations of the neck veins.

11. In the average case this abnormality in rhythm lasts a few days.

12. Seven of our twelve patients showed evidence of serious heart disease.

NOTE: It is a pleasure to express our indebtedness to Dr. Paul D. White for constructive criticism in the preparation of this paper.

REFERENCES

1. Pardee, H. E. B.: Clinical Aspects of the Electrocardiogram, New York, 1933, ed. 3, Paul B. Hoeber, Inc.
2. White, P. D.: Clinical Observations on Unusual Mechanisms of the Auricular Pacemaker, Arch. Int. Med. 25: 420, 1920.
3. White, P. D.: The Bigeminal Pulse in A-V Rhythm, Arch. Int. Med. 28: 213, 1921.
4. Sherf, D., and Shookhoff, C.: Further Studies on Conduction in the His Bundle, AM. HEART J. 2: 48, 1926.
5. Personal unpublished observations.
6. Mobitz, W.: Zur Frage der atrioventrikularen Automatie, Deutsches Arch. f. klin. Med. 141: 257, 1923.
7. Herrmann, G., and Ashman, R.: Interference Dissociation in Contrast to Reciprocating Rhythm, Proc. Soc. Exper. Biol. & Med. 28: 264, 1930.
8. Oettinger, I., and Neslin, W.: Über Atrioventrikulare Automatie bei Rheumatischer Karditis, Deutsches Arch. f. klin. Med. 173: 212, 1932.
9. Jones, T. D., and White, P. D.: A-V Nodal Rhythm; Report of Two Cases Exhibiting Bigeminy, AM. HEART J. 2: 226, 1927.
10. White, P. D.: Ventricular Escape With Observations on Cases Showing a Ventricular Rate Greater Than That of the Auricles, Arch. Int. Med. 18: 244, 1916.
11. Wilson, F. N.: Three Cases Showing Changes in the Location of the Cardiac Pacemaker, Associated With Respiration, Arch. Int. Med. 16: 86, 1915.

12. Hewlett, A. W.: Case Showing Rapid Ventricular Rhythm With Periods of A-V Dissociation, Heart 10: 9, 1923.
13. Kerr, Wm.: Nelson's Loose Leaf Medicine, Vol. 4: 640-0.
14. Gallavardin, L., Dufourt, P., and Petzetakis: Automatisme ventriculaire intermittent spontane ou provoque par la compression oculaire et l'injection d'atropine dans les bradycardies totales, Arch. d. mal. du coeur 7: 1, 1914.
15. Resnik, W. H., and Lathrop, F. W.: Changes in the Heart Rhythm Associated With Cheyne-Stokes Respiration, Arch. Int. Med. 36: 229, 1925.
16. Dressler, W.: Zur Frage der Entstehung der Interferenzdissoziation und der retrograden Fortleitung ventrikularen Extrasystolen, Wien. Arch. f. inn. Med. 19: 611, 1930.
17. Wilson, F. N.: The Production of A-V Rhythm in Man After the Administration of Atropine, Arch. Int. Med. 16: 989, 1915.
18. Lewis, T.: The Mechanism and Graphic Registration of the Heart Beat, ed. 3, London, 1925, Shaw & Sons, Ltd.
19. Burgess, A. M., Waterman, G., and Cutts, F. B.: Suprarenal Sympathetic Syndrome With Cardiac Changes Resulting from Pheochromocytoma of the Right Suprarenal, Arch. Int. Med. 58: 433, 1936.
20. Blumgart, H. L., and Gargill, S. L.: The Mechanism of Transitions from A-V Dissociation to S-A Rhythm; Its Relation to the Theory of Parasystole, Am. Heart J. 5: 437, 1930.
21. Marcellus, M. B.: Migratory Pacemaker, With Report of Case Including Autopsy Findings, Northwest. Med. 33: 189, 1934.
22. Goodman, M.: Mechanisms of Cardiac Rhythm Illustrated by Unusual Human Electrocardiograms, Am. J. Med. Sc. 189: 657, 1935.
23. Zeisler, E. B.: A-V Dissociation, J. Lab. & Clin. Med. 18: 225, 1932.
24. Wilson, F. N., and Robinson, G. C.: Heart Block: Two Cases of Complete Heart Block Showing Unusual Features, Arch. Int. Med. 21: 166, 1918.
25. Friedlander, R. D., and Kerr, W. J.: The Clinical Diagnosis of Tricuspid Stenosis. Report of a Case Complicated by Paroxysmal Nodal Tachycardia and A-V Dissociation, Am. Heart J. 11: 357, 1936.
26. Richardson, H. B.: A-V Rhythm and Digitalis, Arch. Int. Med. 29: 253, 1922.

CONSTRICTION OF THE PULMONARY ARTERY BY ADHESIVE PERICARDITIS*

BENJAMIN A. GOULEY, M.D.
PHILADELPHIA, PA.

ADHERENT pericardium has recently attracted considerable attention because of the realization that certain types of the lesion are amenable to surgery.[1, 2] The physical signs and the disturbance in circulatory function produced by pericardial adhesions may be attributed to either constriction or traction of the heart structure. The heart may be generally involved or the disabling effect may be exerted locally on one of the cardiac chambers or upon the great vascular trunks leading to or away from the heart. Thus, two important types that have been accorded clinical distinction are: (1) the constricting adhesive pericarditis, which affects practically the whole heart, especially the ventricles, and causes "failure of diastolic filling"; and (2) constriction of the inferior vena cava with resulting prolonged circulatory failure of the lower half of the body. A third type, rarely seen but equally distinct, is constriction of the superior vena cava with venous congestive failure of the upper half of the body.

Another involvement, which is the subject of this report and which has not been described in the literature as far as we know, is that which affects the pulmonary artery. The adhesions which at times surround this artery may be very dense and may actually compress and narrow the vessel to a striking degree. They are almost certainly the cause of physical signs which in our opinion are sufficiently definite to warrant a clinical diagnosis of pulmonary arterial constriction.

We wish to describe these signs, which are mainly demonstrable in the pulmonary area, and the underlying pathological lesions observed in five patients. We have also included clinical notes on a patient who has survived and who presents physical signs identical with those noted in some of the cases which came to necropsy.

CASE 1.—C. F., twelve years old, negress, had a severe attack of rheumatic fever two years previously, during which pneumonia had been present and involvement of the heart had been recognized. After some months of inactivity, the process again became active. The severity of this attack, which was again complicated by pneumonia, led to her admission to the Medical Service of Dr. Howard Schaeffer, Philadelphia General Hospital, on April 22, 1933. She presented the typical picture of a severe, active rheumatic fever with painful swelling of the large joints, elevated temperature, and considerable substernal and precordial pain.

The heart was greatly enlarged, the transverse diameter being 18.5 cm. by roentgen examination (Dr. C. Burvil Holmes). At the apex there was a blowing systolic

*From the Departments of Cardiology and Pathology, Philadelphia General Hospital, and the Robinette Foundation, University of Pennsylvania.

murmur. The findings we wish to emphasize were those present at the base of the heart, mainly to the left of the sternum. These were (1) increased widening of the cardiac dullness in the second and third interspaces; (2) a marked systolic murmur and thrill; (3) a diastolic shock and marked accentuation of the second pulmonic sound; and (4) a striking wavelike systolic pulsation spreading upward along the left border of the sternum in the second and third interspaces and followed immediately by retraction. Although adhesive pericarditis was suggested by the marked cardiac enlargement and immobility of the apex, there was no systolic retraction except that noted in the pulmonary area. The remaining findings and laboratory data will be omitted except to note that the electrocardiogram showed, among other changes, prolonged P-R intervals.

The temperature ranged between 98° and 103° F. The patient became increasingly toxic and soon after, developing an encephalitis, died on May 12, 1933.

Necropsy (Dr. Bevan).—The heart was found to be greatly enlarged, the left ventricle and the auricles being considerably dilated; the right ventricle and conus showed definite hypertrophy but were only slightly dilated. The mitral valve was the seat of an acute and relatively slight endocarditis, being only very slightly thickened and not at all deformed. Along its free edge, there was a fine line of verrucous fibrinous deposit. The remaining valves were uninvolved and therefore furnished no explanation of the physical signs found at the base of the heart. These are to be explained by the adhesive subchronic mediastinopericarditis, which was particularly heavy and shaggy over the anterior aspect of the right ventricle and conus. The involvement extended well up along the course of the pulmonary artery surrounding and definitely compressing this vessel. This adhesion also actually compressed the pulmonic conus preventing dilatation, and at the same time securely fixed both conus and artery to the overlying chest wall.

Histology.—The appearance of the heart muscle from various chambers will not be described except to say that there was evidence of chronic and also subacute myocardial involvement. The pericardium surrounding the pulmonary artery and left auricle was enormously thickened, measuring as much as 1 cm. The outer portion consisted of rather loose and edematous connective tissue, greatly capillarized and showing rather numerous perivascular collections of lymphocytes. In the inner portion, the cellular activity was more pronounced, the collections of lymphocytes being augmented by small numbers of large mononuclears and plasma cells.

CASE 2.—M. B., a white woman, aged twenty-seven years, had been known to have aortic valvulitis and mitral stenosis for many years as a result of a severe rheumatic infection in early childhood. In spite of this, her health had been good until late in pregnancy, which was terminated by cesarean section. Immediate postoperative recovery was apparently satisfactory; however, early in the puerperium, heart failure developed and progressed to such a degree that hospitalization became necessary one month after delivery, the patient being admitted on May 1, 1934, to the Medical Service of Dr. Bernard Kohn of the Jewish Hospital, who kindly gave me permission to include this case in my series.

On admission, the patient was very weak, dyspneic, and cyanotic. Auricular fibrillation was now noted for the first time; and the liver and the lung bases were congested. There was a definite phlebitis of the right saphenous vein and also a swollen right arm, secondary presumably to thrombosis of the right subclavian vein. In addition to the obvious mitral stenosis and aortic insufficiency, we wish to emphasize these findings: a definite systolic thrill with a loud systolic and soft diastolic murmur present in the second and third interspaces—well out to the left of the sternum—which led to a clinical diagnosis of pulmonary stenosis and regurgitation.

The severe heart failure showed little response to treatment, and the patient died suddenly on May 7, 1934.

Necropsy.—Necropsy examination revealed advanced rheumatic heart disease, multiple pulmonary infarctions, marked passive congestion of the viscera, leg edema, ascites, and edema of the right arm.

The heart was greatly enlarged and the pericardial sac completely obliterated by widespread adhesion; there were many mediastinal adhesions attached anteriorly and laterally to the thoracic cage, the left lung, and the diaphragm. The pericardial adhesions were seen to encroach to a marked degree on the superior vena cava; and they were dense also over the anterior aspect of the right ventricle, but

Fig. 1.—Case 2. Showing unusually thick (13 mm.) pericardial adhesion around the pulmonary artery (*P.A.*); arrows point to the outer layer of the adhesion which everted on opening the conus and artery with subsequent release of tension. The artery is constricted, especially to its upper portion. Note at that level the thickness of tissue separating the artery from the aorta (*A*), marked by double pointed arrow. The pulmonary valve is moderately compressed; the conus (*P.C.*), hypertrophied.

were thickest over the pulmonary conus and artery where they measured 1.3 cm. (Fig. 1). The pulmonic ring was only slightly compressed, but the artery was so narrowed that, at 2.5 cm. above the valve, the index finger could not be inserted.

The mitral, aortic, and tricuspid valves all showed an advanced stenosis. Examination of the superior vena cava showed not only severe constriction due to surrounding pericardial adhesions, but almost complete occlusion above the constriction by an organized thrombus which extended into the right innominate vein.

Both lungs were rather small, gray, and emphysematous, and presented a number of hemorrhagic infarctions. The pulmonary artery exhibited mild atheromatous changes in the larger branches.

The histological examination showed only chronic myocardial changes as seen in old rheumatic hearts and will not be detailed. Sections through the thickened pericardium revealed no evidence of acute change but only old, completely organized fibrotic lesions.

CASE 3.—D. B., an eighteen-year-old negress, had satisfactorily recovered from her initial attack of rheumatic fever in 1929. She was not troubled by the resulting heart lesions until active rheumatic fever again appeared following an acute respiratory infection in October, 1931. Soon after the onset of this illness, she was

Fig. 2.—Case 3. Showing unusually thick pericardial adhesion surrounding the pulmonary artery (*P.A.*). The outer surface of the adhesion is shown by arrows and partly outlined by dotted line. The conus (*P.C.*) is hypertrophied and dilated. The valve ring and the first inch of the artery were unaffected, but the upper portion of the vessel was constricted.

admitted to the Medical Service of Dr. F. Kalteyer. On admission, the patient was obviously ill, being breathless, febrile (temperature, 101° F.), and miserable because of substernal pain. The heart was found greatly enlarged by percussion and roentgen ray examination (Dr. C. F. Nichols), and showed straightening of the left border with a prominent conus arteriosus and some widening of the base. Systolic and presystolic murmurs were present at the apex, and an unusually loud systolic murmur was heard over the second and third left interspaces, followed by a greatly accentuated second pulmonic sound. The various laboratory data will not be presented. After a stormy course, during which pneumonia developed, the patient died on April 10, 1932.

Necropsy (Dr. G. Robson).—There was a marked mediastinopericarditis. The pericardial cavity was closed anteriorly and laterally by very thick adhesions which were most conspicuous over the hypertrophied right ventricle and surrounding the pulmonary conus and artery, and definitely compressed the latter (Fig. 2).

The mitral valve presented a valvulitis with a semirigid, thickened rim affording some degree of obstruction; the aortic leaflets were also moderately thickened.

Histology.—A section of the left auricle and of the adhesive pericarditis showed great thickening of the pericardium, which had developed in at least three well-defined zones of recurring pericarditis. The outermost zone consisted of a loose, rather edematous connective tissue in which there was a scattering of fibroblasts and "epithelioid cells." The second zone consisted of a more compact fibrous tissue, much of which had undergone fibrinous degeneration and which was infiltrated with large basophilic cells, arranged either in Aschoff bodies or else massed in more or less parallel rows together with "epithelioid cells," in the manner described as "palisading."

The third and innermost layer consisted of a fairly dense connective tissue, which was markedly capillarized, and showed occasional perivascular collars of lymphocytes.

The auricular muscle showed a swelling of the individual fibers, a moderate interstitial edema, and a slight increase in the interstitial connective tissue. The small arteries and the arterioles showed a marked thickening of their wall, due mostly to intimal proliferation. Typical Aschoff bodies were present in the auricular myocardium.

CASE 4.—D. H., a negress, aged fifteen years, was admitted to the Philadelphia General Hospital, service of Dr. Henry Jump, on Dec. 29, 1932. Although she had had chorea in 1929, followed by the development of signs of heart disease, she had remained well until four weeks before admission, when an upper respiratory infection was followed by polyarthritis and substernal pain; she became very dyspneic and developed a high irregular fever.

Examination of the heart showed a moderate enlargement to the left, with a definite increase of dullness in the area of the pulmonary artery. There was a loud, blowing, systolic murmur at the apex, transmitted to the axilla. In the third and fourth interspaces to the left of the sternum, but heard also to a lesser degree along the entire border of the sternum, was a harsh, to-and-fro double murmur. There was a systolic thrill in this area, and P_2 was greatly accentuated.

X-ray examination (Dr. H. Ostrum) showed a thickening of the right interlobar pleura and right basal congestion. The heart was enlarged in its transverse diameter (cardiothoracic ratio being 14:23 cm.). The left auricle was enlarged, the left ventricle as well. There was considerable bulging in the left upper border of the heart due to an enlarged pulmonic conus.

The laboratory findings were as follows: erythrocytes, 3,700,000; hemoglobin, 55 per cent; leucocytes, 19,500.

The patient died on January 13 with acute rheumatic pancarditis and bilateral fibrinous pleuritis.

Necropsy.—The exopericardium was reddened and in some places covered with fibrinous exudate, lightly glued to the mediastinal pleura. There was an extensive plastic pericarditis, unusually heavy and tenacious around the base of the heart. The root of the pulmonary artery was definitely constricted by a mass of recently formed adhesions.

Section of the heart showed a slightly hypertrophied left ventricle while the right ventricle was markedly dilated. The muscle of both ventricles showed an acute,

parenchymatous degeneration. The mitral valve measured 6.5 cm.; the mitral rim was slightly stiffened and its line of closure studded by closely set, translucent verrucae.

The other valves were normal.

Histology.—Histological examination shows a subacute fibrinous pericarditis. There was a dense, almost diffuse infiltration of lymphocytes, endothelial cells, and also polymorphonuclears, in a fibrinous exudate showing early organization. Sections of left auricle and left ventricle showed a rheumatic myocarditis including well-defined Aschoff bodies.

CASE 5.—J. G., a negro child aged six years, whose case is not being presented in detail because both the clinical and the pathological pictures repeat the data brought out by the preceding cases, presented the picture of a severe, acute rheumatic fever, with striking physical signs in the pulmonic area (the most striking of which was a loud systolic murmur), which it is believed were the result of constriction of the pulmonary artery by the thick, fleshy, basal pericardial adhesions, found at necropsy. Incidentally, the orifice of the inferior vena was also considerably obstructed by adhesive pericarditis.

CASE 6.—F. M., a negro aged thirty-three years, who had had rheumatic fever in childhood, was admitted to the Medical Service of Dr. F. Kalteyer, Philadelphia General Hospital, because of severe heart failure, manifested chiefly by marked breathlessness and a swollen abdomen.

On examination, the evidences of heart failure were obvious, there being an enlarged, tender liver, considerable ascites, pulmonary congestion, and breathlessness. In addition to an apical systolic murmur, there was a harsh systolic murmur progressively louder in the fourth, third, and second left interspaces, which was followed by a marked accentuation of P_2 and a palpable diastolic shock, accompanied by a systolic thrill. In the area of the systolic thrill and murmur, there was a rather striking systolic pulsation which was immediately followed by retraction.

Fluoroscopic examination (Dr. C. F. Nichols) revealed widening and increased pulsations of the pulmonary artery, and visible adhesions between the base of the heart and that portion of the overlying chest wall which was the site of the systolic retraction, the thrill, and the murmur. These observations led us to feel that adherent basal mediastinopericarditis with constriction of the pulmonary artery was the most likely cause of the unusual physical signs, and that the large liver and ascites might well be ascribed to secondary right heart failure.

The patient ultimately recovered sufficiently to leave the hospital; his further course is not known.

DISCUSSION

Within the last few years, there has been an increasing interest in the physical signs and the radiological aspects of the pulmonic area of the heart, which previously had been largely neglected because of the conviction that physical signs in that area were of functional origin. This latter viewpoint is now undergoing change. Studies, both anatomical and clinical, indicate the presence of pulmonary arterial hypertension in certain types of disease.[3] Constricting basal pericarditis, involving the pulmonary artery, is an uncommon but apparently very effective cause of such hypertension.

Etiology.—The pericardial lesion herein described was caused by rheumatic fever. We have seen at necropsy a few cases of healed tu-

berculous pericarditis, where the pulmonary artery, in common with the rest of the heart, was surrounded by adhesions, but constriction did not exist to the degree noted in these rheumatic cases. Partial compression of the pulmonary artery by large, conglomerate, caseous lymph nodes in association with adhesion was noted in a patient not included in this report because of incomplete clinical data. Other factors may possibly be of etiological importance, but thus far in our experience, rheumatic pericarditis is the outstanding cause.

The Pathological Changes.—The fundamental pathological lesion is a massive mediastinopericarditis, in which thick adherent scar tissue surrounds and constricts the pulmonary artery. In the adult heart, as in the adolescent, the index finger is readily passed through the pulmonary artery up to its bifurcation, but in the cases herein described, this was often impossible. The constriction becomes notable as a rule about 2 cm. above the valve; in one instance, the vessel at its bifurcation was so narrow that a pencil could not be inserted into the origins of the two main branches. The width of these adhesions, which are often fleshy and somewhat edematous, is striking. In four cases they were from 10 to 15 mm. or more in thickness, and in three instances they completely filled in the anterior chest wall for a considerable distance (Fig. 3, *A* and *B*). The artery is possibly drawn forward toward the sternum; it appears, however, in some of the cases that the vessel is fixed or "frozen" in its normal position. Cross-section of the surrounding adhesion may reveal two or three inflammatory layers of different degrees of chronicity, indicative of recurring pericardial inflammation.

The pericarditis is seldom limited to the pulmonary artery. In only one patient (not included in this report) was there such localization. It may be the most conspicuous part of a universal pericardial adhesion, or it may be part of a pericarditis limited to the anterior aspect of the heart. It was not surprising, therefore, to find evidence, in some of the cases, of constriction of other vascular trunks. None of the group presented a typical picture of the Pick syndrome, but necropsy revealed marked constriction of the inferior vena cava in one case. In another there was superior vena caval obstruction. The superior vena cava was constricted by pericardial adhesions, and above the stenosis was a partially occluding thrombus. It is, therefore, evident that the patient who presents signs of pulmonary constriction may also have the picture of superior or inferior vena caval obstruction or of generalized pericardial adhesions. In one case the systemic aorta was partially constricted; as far as we know, there is no reliable method of recognizing this lesion.

All of these hearts showed rheumatic valvular disease. In Case 2 there was advanced mitral stenosis, but in four of the five cases which went to necropsy, the valve lesion was relatively mild, and in one

patient it consisted of a very recent verrucous endocarditis without previous disease. In this instance the pericardial lesion had preceded the valvulitis probably by many months.

Hypertrophy of the right heart was present and notable in every patient except in Case 4 (D. H.) in whom the process, consisting of a subacute fibrinous thickening with only recent organization, evidently was not old enough for the development of marked, right ventricular hypertrophy. Since the valve lesions were early and moderate in degree (except in Case 2), we believe that the right ven-

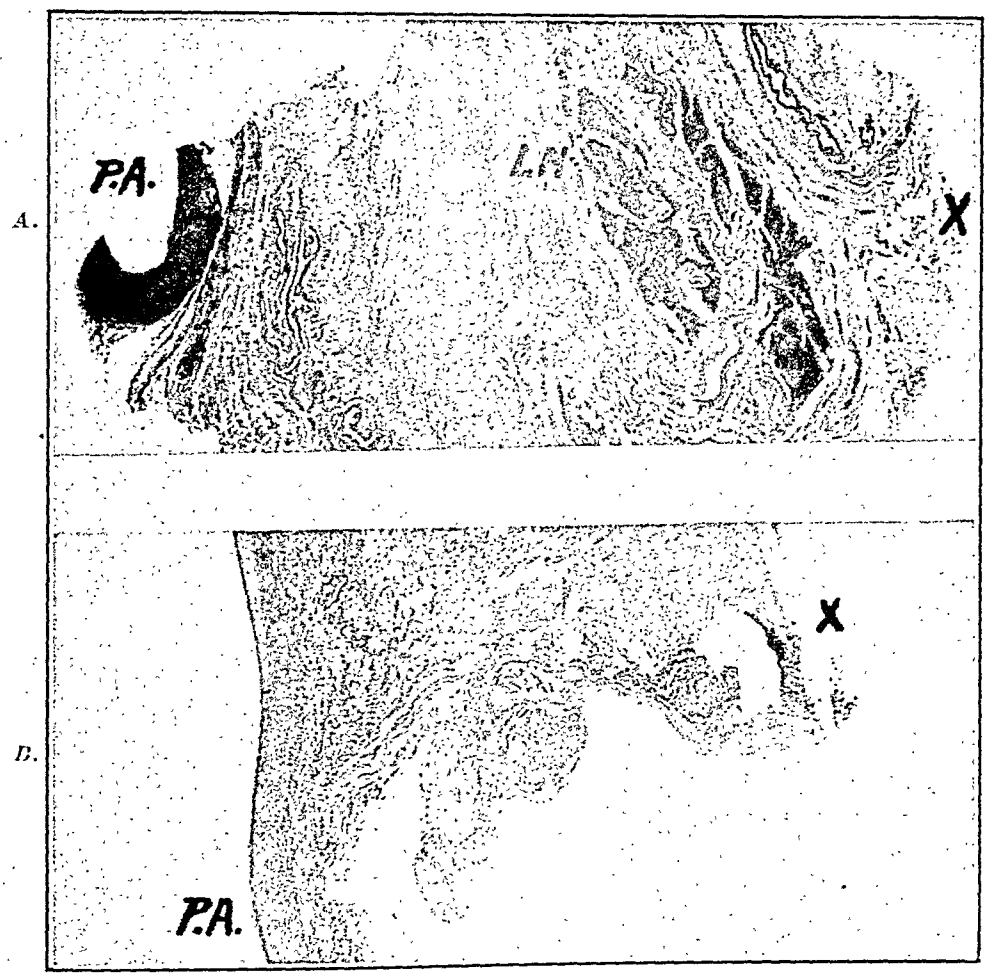

Fig. 3.—Case 3. *A*, Showing a small arc of a cross-section of the wall of the pulmonary artery (*P.A.*), and the massive adhesion which surrounds it and extends to the chest wall; *L.N.* indicates the remains of a mediastinal lymph node; *X*, the rough edge of the adhesion torn away from the anterior chest wall. *B*, Same as above, but in longitudinal section.

tricular hypertrophy is to be explained as one of the results of constriction of the main trunk of the pulmonary artery. It is the result of a proximal, localized pulmonary hypertension, analagous to the proximal, aortic hypertension and secondary hypertrophy of the left ventricle, associated with coarctation of the aorta. Although rheumatic pneumonitis[4] was present in the majority of these cases, marked pulmonary atherosclerosis was seen only once, in Case 2, in association with mitral stenosis. The absence of more pronounced pulmonary

arteriosclerosis and mitral stenosis is probably to be explained by the fact that four of the five cases which went to necropsy were young subjects who did not survive the rheumatic process sufficiently long to develop these changes.

Histological examination of the pulmonary artery in two cases (Cases 3 and 5) revealed a focal degeneration in the media, involving both muscle and elastic tissue. In a number of fields, the smooth muscle nuclei had either disappeared or stained poorly, and lay in a background of mucoid substance similar to that seen in certain degenerations of the aorta. In some places there was considerable



Fig. 4.—Case 5. Focal atrophy in the media of the pulmonary artery. Note disrupted rows of muscle nuclei, focal loss of nuclei, the frothy appearance, and the separation of the rows of the nuclei by a myxoid (?) infiltration. (×151.)

vacuolization between the disrupted rows of muscle nuclei, giving a frothy appearance to the already "moth-eaten" degeneration of the media (Fig. 4). We presume in the absence of cellular infiltration that this is a degenerative rather than an infectious process. The partial fixation of the pulmonary artery and the compression by the surrounding adhesions probably are factors in this focal atrophy of the media.

The Physical Signs.—Examination of the pulmonic area, employing the routine methods of inspection, palpation, percussion, and auscultation, will reveal a variable number of the following physical signs: (1) a harsh systolic murmur in the pulmonic area, in the second and

third left interspaces; (2) a greatly accentuated second pulmonic sound; (3) a diastolic shock in the same area; (4) a systolic pulsation coincidental with the systolic murmur, extending upward in the third and second left interspaces in the direction of the pulmonary artery, which may be followed by (5) a successive retraction of those interspaces, the whole process of pulsation and retraction having a striking sinuous appearance when well defined and seen in a favorable light; (6) the presence in a few cases, but of great importance when obtainable, of a systolic thrill palpable in the area of the systolic murmur and pulsation; (7) increase in the area of cardiac dullness in the third left interspace indicative of hypertrophy and dilatation of the right ventricle (conus portion).

When all of these signs are demonstrable in a given case, the picture is characteristic, and the diagnosis is not difficult. However, as reference to the protocols will show, there may be considerable narrowing of the pulmonary artery by pericardial adhesions without detection of all these signs by physical examination. In those cases that first came under our observation, some of these signs may have been present but were not thought of and consequently were missed. Systolic murmur, accentuated second pulmonic sound, and diastolic shock were present in all cases. Systolic murmurs in the pulmonic area are common and usually are not regarded as important. In these six cases, however, the murmurs were distinctly louder and rougher and heard over a more considerable area than the usual incidental pulmonic murmur, and therefore directed our attention to the existence of a lesion in this area. Systolic thrill was palpable in two instances. Its significance, of course, depends on its association with the other physical signs. Systolic pulsation and retraction in the pulmonic area are very suggestive, but do not constitute in themselves a pathognomonic sign; the retraction can be regarded as having the same significance (and with the same limitations) as the systolic retractions of adherent pericardium noted in other thoracic areas. At times it has proved difficult to be certain whether one is seeing a real retraction or the normal recoil following vigorous pulsations of a pulmonary artery lying relatively close to the chest wall.

In the light of the pathological findings, the physical signs can be reasonably classified on a physiological basis. The systolic murmur and systolic thrill are produced by the compression of the artery; hypertrophy of the right ventricle, especially the conus, the accentuated second pulmonic sound, and diastolic shock can be correlated with right ventricular hypertension and proximal hypertension of the pulmonary artery; the systolic pulsation followed by retraction is indicative of the attachment of the conus and even the pulmonary artery to the chest wall. There is a certain degree of overlapping in the physiological grouping of the physical signs; for example, the systolic

murmur may be attributed not only to compression of the artery, but also to the presence of pulmonary hypertension. We assume the existence of right ventricular hypertension in these cases, a conception that is now generally accepted in all types of pulmonary arterial obstruction, not on the basis of actual physiological observation (of which there is none) but on the more indirect evidence of hypertrophy and dilatation of the outflow portion of the right ventricle.

Differential Diagnosis.—Since no one sign is pathognomonic and since some of the signs, particularly those related to right ventricular hypertension, are to be seen in other disease processes, the diagnosis of stenosis of the pulmonary artery by pericardial adhesion often presents considerable difficulty. Inasmuch as rheumatic fever is the chief cause of this type of constricting pericarditis, the history of such infection and the presence of other cardiac lesions due to rheumatism will be of diagnostic help. Likewise, since the involvement of the pulmonary artery is usually a part of a more extensive pericarditis, other evidences of adhesions in the form of characteristic retractions, fixation of the apex beat, pulsus paradoxus, etc., may add some diagnostic corroboration. Two conditions that immediately enter the diagnostic problem are mitral stenosis uncomplicated by pericarditis and congenital pulmonary stenosis. Although right ventricular hypertrophy and pulmonary hypertension are prominent features in mitral stenosis, the other striking physical signs (of pulmonary arterial compression and adhesion) are not present. In congenital pulmonary stenosis, systolic murmurs and thrills are striking, but chest wall pulsations and retractions are not seen, and the second pulmonic sound is, as a rule, diminished. The many other conditions that produce pulmonary hypertension can usually be differentiated by careful analysis of the signs and their etiological associations. Thus pulmonary artery syphilis, either in the form of Ayerza's disease, or pulmonary artery aneurysm,[5] pneumonoconiosis and sickle-cell anemia[6] can be eliminated probably with little difficulty. As a matter of fact, there have been so far two lesions which in our experience have been the source of error in diagnosis; these are (1) sinus of Valsalva aneurysm, particularly of the left anterior sinus, where the aneurysm presses on the pulmonary conus or artery, giving rise to signs of obstruction in the pulmonary circuit; and (2) mediastinitis. The former manifests itself by systolic murmur, thrill, and pulsation in the pulmonic area, but the diastolic shock is augmented by diastolic murmur; a positive Wassermann reaction is usually present, and the x-ray silhouette is decisive in the case of sinus of Valsalva aneurysm (of the left anterior sinus). Therefore, its globular bulge in the roentgenogram in the pulmonic area, its diastolic murmur, and positive serology serve to differentiate it from the lesion herein described. Such an aneurysm is usually intrapericardial, and while the peri-

cardium overlying the aneurysm is often inflamed and locally adherent, seldom is the heart itself attached to the surrounding structures. The second, more common, confusing condition that enters into the diagnostic problem, indurative mediastinitis, can apparently in certain cases give rise to almost identical physical signs. This lesion is not uncommon in connection with chronic pulmonary pleural tuberculosis, when it can develop as an extensive extrapericardial barrier, especially in the left hilar region. We have seen a tuberculous patient in whom there was marked systolic pulsation, followed by retraction in the pulmonic area in the entire absence, as shown later by necropsy, of intrapericardial adhesion. The mediastinal pleural tissue was extensively thickened, acting as a barrier to the expanding lung; the cushion effect of compensatory expansion of the lung during ventricular systole was then lost, permitting systolic retraction in the second and third left interspaces. A different mechanism occurring in pulmonary tuberculosis is the basis of the recent article by Geneverier and Descamps,[7] entitled "Pulmonary Arterial Syndrome in Sinistrocardia," in which physical signs, similar to those recorded in our patients, were ascribed to "extravascular stenosis of the pulmonary artery." These observers based their conclusions on a radiological study of tuberculous patients, in whom atelectasis of the left lung secondary to fibroid phthisis caused torsion and traction on the heart, pulling it to the left with subsequent "deformity" of the pulmonary artery. We believe that the fluoroscopic and clinical demonstration of a freely moving heart, the indubitable presence of pulmonary tuberculosis, the intense x-ray opacity of tuberculous mediastinitis in the left hilar area would in all probability aid in distinguishing the intrapericardial arterial constriction from obstruction, due to induration in the mediastinum or that possibly due to displacement of the heart.

The Effect of Constriction of the Pulmonary Artery on the Circulation.—Four of the six patients presenting this lesion succumbed relatively early in the course of their rheumatic disease, living at the most two or three years after the onset of the first severe attack. Death was due to recurrence of acute infection, and myocarditis must be accepted as the major factor in the final heart failure; mechanical obstructive heart failure appears to have been an incidental feature, overshadowed by the virulence of the acute infection. It is reasonable, however, to assume that even under these circumstances, compression of the pulmonary artery contributed to the defeat of the right ventricle.

Speculation as to what circulatory changes might have developed had these four patients survived is possibly answered by the histories of Cases 2 and 6. The former died after pregnancy from mechanical right heart failure without recurring infection. It is true that mitral stenosis was present, but the physical signs of pulmonary arterial

compression were also present; and to the extent that compression of the pulmonary artery is at least equal to the mitral lesion in the production of right heart failure, this case may be accepted as one illustrating the final effect of pericardial compression. In Case 6 the patient survived the acute phase of rheumatic disease for many years and did not, during the time of our observation, show any sign of recurring infection. In the absence of demonstrable serious valvular lesions, such as mitral stenosis or aortic regurgitation, this patient, we believe, illustrates even more fully than Patient 2 the evolution of mechanical right heart failure secondary to compression of the pulmonary artery by pericardial adhesions.

SUMMARY

Compression of the pulmonary artery by constricting pericardial adhesions is characterized by physical signs of (a) stenosis of the pulmonary artery; (b) pulmonary arterial hypertension of a proximal type; and (c) adhesive pericarditis.

The underlying pathological lesion in a group of six patients was rheumatic carditis.

While most of this group succumbed relatively early in the course of their rheumatic disease to recurrence of acute infection, in which the feature of mechanical obstructive heart failure was probably only incidental, or at best contributory to the final outcome, two cases were presented in which the adhesive pericarditis with compression of the pulmonary artery was a major factor in the development of cardiac failure.

The writer wishes to express his thanks to Dr. H. Schaeffer, Dr. F. Kalteyer, Dr. H. Jump, medical chiefs of the Philadelphia General Hospital, and to Dr. Bernard Kohn of the Jewish Hospital; to Dr. Gunn, Dr. Bevan, and Dr. Ahlfeldt, pathologists, for permission to use the clinical and pathological material; Dr. George Robson (deceased) performed the necropsy in Case 3.

REFERENCES

1. Churchill, E. D.: Decortication of the Heart (Delorme) for Adhesive Pericarditis, Arch. Surg. 19: 1457, 1929.
2. Beck, C. S., and Griswold, R. A.: Pericardectomy in the Treatment of the Pick Syndrome: Experimental and Clinical Observation, Arch. Surg. 21: 1064, 1930.
3. Moskovitz, E.: Hypertension of the Pulmonary Circulation, Am. J. M. Sc. 174: 388, 1927.
4. Gouley, B. A., and Eiman, J.: The Pathology of Rheumatic Pneumonia, Am. J. M. Sc. 183: 359, 1932.
5. Karsner, H. T.: Productive-Cicatricial Syphilitic Disease of the Pulmonary Artery, Arch. Int. Med. 51: 367, 1933.
6. Yater, W. M., and Hansmann, G.: Sickle-Cell Anemia: A New Cause of Cor Pulmonale, Am. J. M. Sc. 191: 474, 1936.
7. Geneverier, J., and Descamps, H.: Pulmonary Arterial Syndrome in Sinistrocardia, Presse méd. 43: 1065, 1935.

CLINICAL OBSERVATIONS IN ERYTHROMELALGIA AND A METHOD FOR ITS SYMPTOMATIC RELIEF*

ISIDOR MUFSON, M.D.
NEW YORK, N. Y.

THE complaint "burning pain" in one or all extremities, induced or aggravated by warming or the dependency of a limb, and relieved by cooling or the elevation of a limb, is frequently encountered in vascular diseases. This symptom-complex has been named "erythromelalgia." Often, the underlying disease is so apparent, as in obliterative or vasospastic arterial diseases, or in inflammatory and allergic reactions, that this symptom-complex is passed over by the examiner. However, to the patient's comfort, it is very pertinent. Under the name "erythromelalgia" have been grouped those cases of peripheral vascular diseases, in which the presence of this type of pain is often associated with a rubor of the skin and a dilatation of the minute vessels of the skin. The causative agent is not apparent. First described by Weir Mitchell,[8] both Brown[2] and Lewis[6] have emphasized that erythromelalgia is but a symptom-complex. They also gave their criteria for its diagnosis. Lewis has further attempted to explain the mechanism of the pain, by assuming that there is a release of an histamine-like substance from the minute vessels, which, he suggests, are in a "susceptible state." Studies in two cases of erythromelalgia, to be reported here, it is believed, will show unusual underlying causes. Further, with the aid of observations on the blood pressures of the minute vessels, an attempt will be made to explain the mechanism of the pain. During the studies on the second case, we were able to devise a method for the symptomatic relief of the major complaint, pain.

METHODS

The minute vessels of the skin were studied through a binocular microscope with the forearm at the level of the heart. Blood pressure determinations were made on the minute vessels of the skin, near the cuticle margin of the nails by the indirect method.[3] The criteria used were the same as those in our previous work.[10] The pressure recorded is the figure most commonly recurring in twenty to thirty determinations. The final figures from the upper and lower extremes rarely vary more than 5 mm. Hg. The pressure was read on the mercurial manometer when the flow in the visualized capillary was fully reestablished while reducing the obstructing pressure of the closed capsule. The blood pressure in the venules was determined with the same apparatus.[10] Readings were

*From the Department of Medicine, College of Physicians and Surgeons, Columbia University and the Presbyterian Hospital.

made with the first return of color to the skin which had been blanched by the overlying closed capsule. Venous pressure was determined by the method of Moritz and von Tabora.[9] Skin temperatures were determined by means of a resistance thermometer (Leeds and Northrup).

CASE 1.—*Erythromelalgia Symptomatology in an Alcoholic Patient.*

A sixty-year-old man (Unit History No. 350653), divorced, for the past twenty years had drunk daily as much as a pint and a half of whisky. Six years before, a physician told him that he had alcoholic cirrhosis of the liver. He smoked ten cigarets a day. He had had gonococcus urethritis but no chancre. He was admitted to this hospital, complaining of increasing redness of the hands and enough pain in all fingers to render them useless. Nine months before, he first noted that his fingers were becoming awkward while playing cards, his favorite pastime. Four months later, he noted that the color of the skin of his fingers was becoming very red. They felt swollen and less supple. In the next two months the palms became involved. The lightest touch to his affected skin was unbearable. Warmth or hanging his hand down induced pain which could be relieved by cooling or elevation of his arm. He could not feed himself or smoke a cigaret, consequently he became extremely irritable and a "shut-in."

On examination, he appeared as an elderly lean male, chronically ill. His pupils reacted promptly; teeth were missing, nose, ears, and throat appeared normal. Thyroid was not enlarged. Heart and lungs showed no abnormality. His liver was 5 cm. below the costal margin, its surface was smooth but firm. The spleen was moderately enlarged. Rectal and genital examinations were negative. The neurological examination, which included an examination of his spinal fluid, disclosed no abnormality. Blood and spinal Wassermann reactions were negative. He had an eosinophilia of 6 per cent. His serum calcium was 10.8 mg. per 100 c.c. and his other blood constituents were within normal limits. His metabolic rate on several occasions was normal. X-ray examination disclosed no cervical ribs. The phalanges, however, showed an osteoporosis. His brachial blood pressure was 100/65 mm. Hg, and the antecubital venous pressure was 12 mm. water. His radial arteries felt sclerotic.

Both of his hands, especially his fingers and the palms, were bright red. There was no tinge of cyanosis; it rather suggested the color of freshly oxygenated blood. The skin was unbroken; there were neither vesicles nor ulceration, but there was some ironing out of the skin folds. Any attempt to touch his hands brought loud protests. Even after gaining his confidence during the weeks of hospital observation, he would resent the lightest stroking. The flexion of his fingers was also painful. When his arm was hung down over the side of the bed, his skin turned a deeper red, and pain soon set in. Elevating his arm relieved the pain in about a minute. A similar pain was induced when a blood pressure cuff was inflated around his arm. This could be relieved in several minutes by deflating it. Cooling the painful area by means of a spray of ethyl chloride gave him welcome relief, without any change in the depth of the color of his skin. His median nerve was blocked by the perineural infiltration of a 1 per cent solution of novocaine. The skin supplied by the nerve developed an increased surface temperature and its redness deepened.

The capillary microscope disclosed a marked alteration from the normal picture of the minute vessels of the skin. This was especially true of the venules. They were enormously dilated, with a diameter about five times the average. The blood in them was a bright red and accounted for the rubor of the skin. Capillary loops were few, but at the cuticle margin a complete row of them was visible. Their size was normal, and the diameter of their limbs, equal. The venules and the capillaries

contracted promptly when a drop of 1 to 1,000 solution of adrenalin was pinpricked into the epidermis. The skin became colorless. The even flow became slowed and interrupted.

Blood pressure readings of the minute vessels adjacent to the cuticle margin were made. These pressures varied directly with the changes in the temperature of the skin. These are recorded in Table I.

TABLE I

SKIN TEMP. ° C.	B. P. CAPILLARY MM. HG	B. P. VENULE MM. HG
27	34	28
34	45	40

Comment.—This case, on inspection, fitted into that group of cases which we usually catalogue as erythromelalgia, with the etiology usually undetermined. An analysis of the minute vessel studies in this case may enable one to associate the patient's alcoholic excesses with his vascular disturbance. The findings in the minute vessel studies were unusual. The dilatation that was anticipated was found only in the subpapillary venule plexus. The hypertension was localized in the minute vessels, the arterial and venous blood pressures being normal. With a rise in the temperature of the skin to almost blood temperature, the burning pain makes its appearance, and the blood pressures of the minute vessels rise to an extreme high. Lewis[6] assumes that the minute vessels must be in what he calls a "susceptible state" in order to give such severe pain in response to so mild a stimulus as a light stroking of the skin. Our observations lead us to feel that this pain response is due to the inordinate increase in blood pressure in the minute vessels of the skin. Dilatation per se of the minute vessels does not cause a blood pressure increase. Dilatation of the minute vessels is present with a low normal pressure in acrocyanosis, the spasm phase of Raynaud's disease, and in the cyanotic group of congenital heart disease without decompensation. Conversely, the hypertension found in nephritis is associated with vessels that are of a normal or constricted caliber. How, then, can the intrinsic hypertension of the minute vessels be accounted for? Alcohol is known to be toxic to the cytochrome of the tissue cells. Cyanide acts in the same way, more rapidly. An inactivation of cellular oxidation will follow the ingestion of a sufficient dosage. The tissue cell will not then be able to absorb its requirements in oxygen from the blood brought to it by its adjacent minute vessels.[5] This gas will then pass through without being absorbed. It then can be assumed that oxygen saturation will be about equal in the arterial and minute venous vessels. In cyanide poisoning, the skin of the patient has a bright arterial hue. One may assume that our patient has had such an inactivation of the cytochrome of the cells of his skin. His liver cells probably have experienced a similar change. The cellular anoxia enables the oxygen to reach the venule side in very high concentration. It was

found in a study of patients receiving oxygen by nasal catheter that an increase in its concentration caused a rise in the blood pressure of the capillary. In this patient, because of the cellular anoxia, a high oxygen concentration in the venule side of the minute vessels has resulted, and this in turn has stimulated an increase in the pressure of the minute vessels. The relationship of the osmotic pressure of the blood to the hydrostatic pressure of the minute vessels becomes disturbed. The exit of "pain substances" is hastened because the hydrostatic pressure is greater than the osmotic pressure. The distention, alone, of the minute vessels could be sufficient to cause the pain. This is often seen when a solution is given rapidly by vein with an overdistention of its lumen.

CASE 2.—A woman (Unit History No. 396258), aged forty-eight years, was admitted to the medical vascular clinic. For the past five years she had been under the care of various doctors in several of our hospitals. She first noticed a sense of pin-and-needle-like feelings in the first three digits of the left hand. A few weeks later there was severe pain in the left index finger. Not believing in medical care, she went to a cultist. Conditions grew worse, and after a year the pain became so intense that she consulted a physician. During this year she did not notice any loss of sensation or change in color of her skin. She received diathermy treatments and massage. Her tonsils were removed, and injections of several unknown drugs were given for several weeks. Diabetes was next discovered and controlled, but without affecting her pain. Two years before admission, she noticed that there was some blunting of her tactile sensation, though she was not entirely certain of this because of her pain, which was likely to be present at the time of her examinations. At this time she realized that the pain was relieved by cold and induced by warmth. After study in the Neurological Institute at this time the diagnosis was an osteoarthritis of the cervical spine and a provisional diagnosis of syringomyelia. A course of roentgen ray therapy to the cervical cord was given without any relief of her complaints. Next she developed a constricting pain in the middle of her left forearm and arm. Her friends also called her attention to the fact that her left eye appeared to be smaller than the right. She was followed in the neurological clinic, receiving sedatives and various forms of physical therapy. After two years she was referred to the medical clinic for an opinion. On her first visit here, she was discouraged in her failure to be helped and came only as a favor to the neurologists. The only additional finding was that the affected finger was insensitive to a deep pinprick. Her erythrocyte sedimentation rate was slightly elevated, 17 mm. per minute. X-ray studies failed to disclose a cervical rib. Her visual fields were normal. X-ray films of the teeth showed a mild infection which was treated. The basal metabolic rate was -13 per cent. The blood count was normal. Her glucose tolerance test showed a diabetic curve. A diabetic diet without insulin controlled the blood sugar within normal limits. At a medical conference additional hypotheses were suggested: first a vascular disturbance based on a cervical gliosis and, second, a thalamic syndrome involving the nucleus rubor which would explain the pains in the arms and leg.

The patient was then referred to the vascular clinic for further studies. She stressed the relationship of her pains to temperature. She preferred the cold to the warm weather. During the freezing weather, she walked with her affected hand exposed while the other was covered by a glove and a fur muff. At night, she had to keep an icebag on the painful hand in order to be able to fall asleep.

The skin of the affected finger was moderately atrophic, the skin markings being ironed out. The color of the skin was pinker here than that of the other hand. Capillaroscopy at the cuticle margin showed numerous capillaries. Their diameters were normal, with the blood flow occasionally showing an interrupted streaming. There was no dilatation of the subpapillary plexus.

When a blood pressure cuff, placed around the arm, was inflated to 120 mm. Hg, typical pain was induced in the left index finger. Examination of the capillaries under these conditions showed that a great increase in their number had resulted, the venules were dilated, and the blood flow stagnated.

The above procedure was repeated only after the affected finger had been subjected to a compression of 40 mm. Hg by means of an overlying capsule. No pain appeared in the finger when the pressure in the arm cuff was first raised to 120 mm. Hg, and then to 180 mm. Hg. When the finger compression was released, pain promptly appeared in the finger. Compressing the finger with the capsule, after the pain had already been induced by venous congestion, failed to give relief. The relationship of the occurrence of pain to changes in the temperature of the skin was observed. Simultaneously a record of the changes in the blood pressure of the minute vessels was made. These observations are recorded in Table II and are of great interest. The onset of pain when the temperature of the skin is close to blood temperature has been shown before. However, as in the previous case, it is now shown that a hypertension in the minute vessels occurs with the pain.

TABLE II

RELATIONSHIP OF PAIN TO CHANGES IN SKIN TEMPERATURE AND BLOOD PRESSURE OF MINUTE VESSELS

TIME	SPONTANEOUS PAIN				SKIN TEMPERATURE (° C.)				BLOOD PRESSURE (MM. HG)				REMARKS
									CAPILLARY		VENULE		
	R2	L2	R4	R4	R2	L2	R4	R4	R2	L2	R2	L2	
0.00	0	0	0	0	27.2	27.2	26.7	26.2	25	35	10	25	Left forearm immersed in hot water
0.05	0	0	0	0	32.5	32.5	32.0	32.0					
0.15	0	++	0	0	33.0	33.5	33.0	33.5	35	60	20	50	Capillary pulse present

Comment on Case 2.—From these observations, it appeared that the increase in skin temperature induced both an abnormal rise in the blood pressure of the minute vessels, and severe pains in the finger. Such a response is to be expected from a severe local trauma rather than such mild indirect warming of the skin. The minute vessels possess both constrictor and dilator fibers. The overdilatation could result from either group's being involved. With the constrictor pathways degenerated, the normal antagonism to dilatation may fail to exert its influence. Or it may be an exaggerated response by the dilator nerves to ordinary stimulation. In order to choose the mechanism for this response, we refer to the work of Meltzer and Auer,[7] who noted that adrenalin causes a greater constriction of the blood vessels of the ear when it is denervated than when its nerves are intact. Elliott[4] confirmed and extended these findings. He showed that the pilomotor mechanism is especially responsive to injected adrenalin after neurectomy. Others

have confirmed these findings and White has used this method to show why sympathectomy is a failure in Raynaud's disease. Meltzer and Auer[7] showed that this effect developed not immediately after denervation, but when degeneration was complete. Using these observations, one would be justified in concluding that if an exaggerated response to adrenalin be present, a degeneration of the vasoconstrictor fibers has taken place.

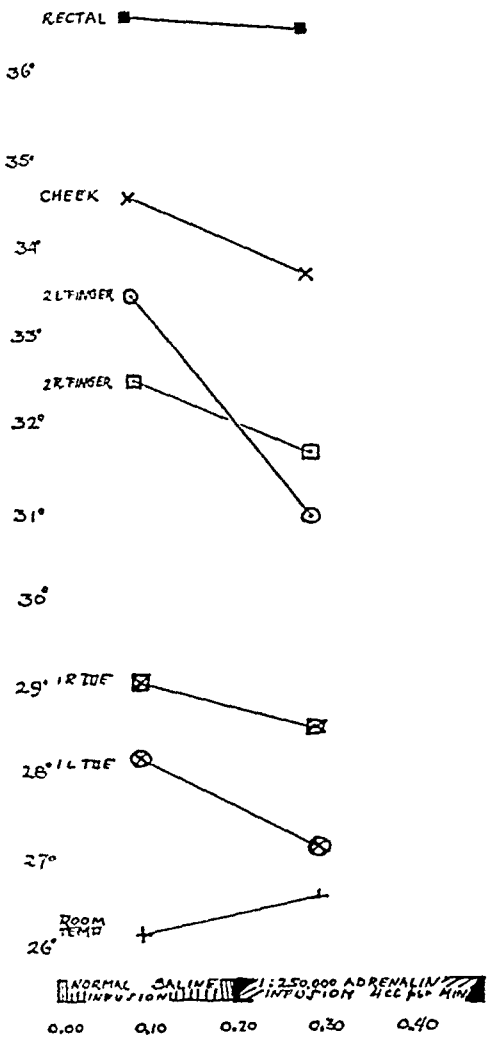

Fig. 1.—Case 2. Adrenalin response in erythromelalgia of left index finger.

Experimental Studies.—It was decided to test out the adrenalin sensitivity of the vessels. A solution of 1:250,000 was given intravenously at the rate of 4 c.c. per minute and frequent recordings of skin temperature were made. Vasospasm will result in a drop in the temperature of the skin. With the solution going in at the rate of 4 to 6 c.c. per minute, normal skin vessels will not become narrowed enough to give a drop in skin temperature. The results of this infusion test as given to this patient are recorded in Fig. 1. The temperature of the skin dropped most sharply in the painful areas of the skin.

As a corroboration of the value of this test, a definite case of syringomyelia with complete denervation of one side was given this infusion. He had a complete absence of sudomotor activity on his left side with the loss of pain and temperature sense. He showed a drop in the temperatures of the skin only in the right finger (Fig. 2). His vessels were sensitized to adrenalin because they had been denervated by the syringomyelic process.

It could therefore be concluded that vessels in the involved skin had been deprived of their vasoconstrictor nerve supply. The exact location where the interruption occurred is problematical. The sympathetic

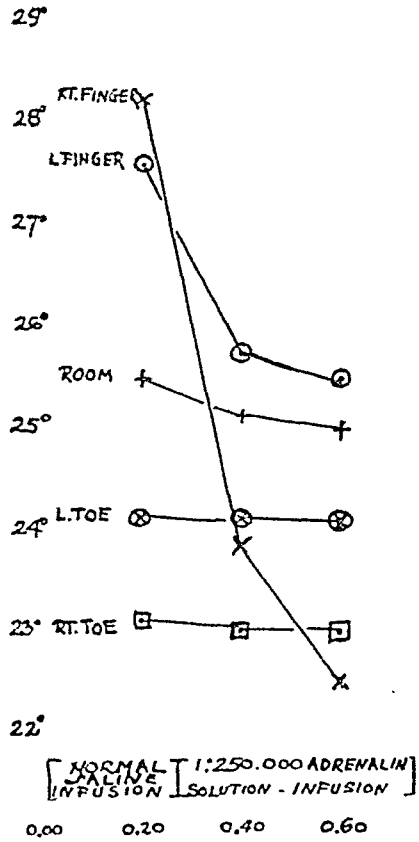

Fig. 2.—Adrenalin response in patient with syringomyelia affecting the right side.

fibers, according to Beattie and others,[1] pass at the dorsal levels through the vestibulospinal tract where they could be destroyed by a hydrops of the nearby spinal canal.

A week after this test had been performed, the patient returned for further studies. At this time, she enthusiastically stated that this was the first week in five years that she had been relieved of her pain and that she wanted more treatments. The infusion was repeated with similar changes in skin temperatures. The patient noted that when it was given rapidly she had greater relief. Normal saline given as a control had no effect. She did not mind the headache nor the palpitations which come with the higher rates of infusion because, as she stated, the relief was worth it. Her finger became pale and so did her face.

Her finger became mobile, and the hyperesthetic state was relieved. She was able to do her ironing. The relief, as was to be expected, lasted only for a few days after the infusion. She felt, however, that she would like to be that way all the time and wanted to come more often. At this time, a solution of adrenalin 1:100 appeared on the market. This was sprayed into the patient's nose and throat during ordinary respiration by means of a special nebulizer. The results were as satisfactory and almost as prompt as with the infusion of the dilute solution of adrenalin. She was told to use this at home, and she reported that she was able in this way to find relief at any time for her burning pain.

Since the patient had had many attempts to help her, and none had given her even temporary relief, it was felt that the response was genuine. Aside from the control infusion of normal saline, the following procedure was carried out to avoid the possibility that suggestion was

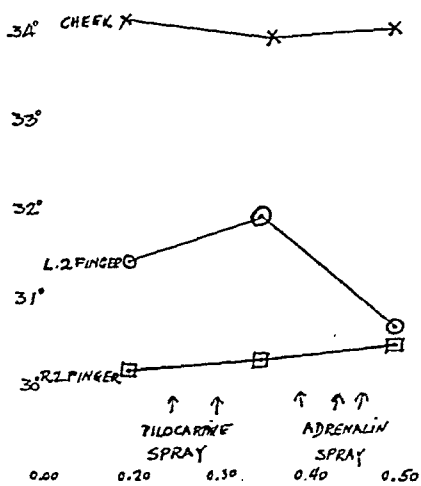

Fig. 3.—Case 2. A comparison of the skin temperatures after the spraying of pilocarpine and adrenalin into the nasopharynx.

the relief medium. One cubic centimeter of a solution of pilocarpine hydrochloride which contained 0.006 gm. of the drug was placed in the nebulizer without her knowledge. This was then sprayed into her nose and throat about fifteen times. After three minutes, she said that her pains were returning in a most severe form to her left hand. She became disheartened and thought that she had better go back to the infusion. She was then given the 1:100 solution of adrenalin by spray with prompt relief of the severe pain in the finger (Fig. 3). She felt more reassured when she was apprised of the experiment. She has since used the solution of adrenalin by inhalation, the total requirements per day varying directly with the temperature of her environment. She has been performing household duties of the so-called heavier type for the first time in five years. She is looking forward to a permanent cure, which, she has been told, is unfortunately not in sight.

SUMMARY

1. It has been reemphasized that erythromelalgia is a symptom-complex, dependent upon minute vessel changes, the etiology of which is not always readily apparent.

2. Capillary microscopy in the two cases studied has shown that the normal physiological response to warmth is disturbed and exaggerated, resulting in an intrinsic hypertension and dilatation of the minute vessels of the skin.

3. This exaggerated dilatation present in erythromelalgia has been shown to be the result of an absence of normal antagonistic vasoconstriction. The method was based on the work of Meltzer and Auer.

4. The use of this test led to the finding of a method for the alleviation of the most distressing pain. Relief of the pain was obtained by the use of adrenalin by infusion and inhalation.

REFERENCES

1. Beattie, J., Brow., G. R., and Long, C. N. H.: Physiological and Anatomical Evidence for the Existence of Nerve Tracts Connecting the Hypothalamus With Spinal Thalamic Sympathetic Centers, Proc. Roy. Soc. Series B 106: 253, 1930.
2. Brown, G.: Erythromelalgia and Other Disturbances of the Extremities Accompanied by Vasodilatation and Burning, Am. J. M. Sc. 183: 468, 1932.
3. Danzer, C. S., and Hooker, D. R.: Determination of the Capillary Blood Pressure in Man With the Capillary Tonometer, Am. J. Physiol. 52: 136, 1920.
4. Elliott, T. R.: The Action of Adrenalin, J. Physiol. 32: 401, 1905.
5. Keilin, D.: On Cytochrome, a Respiratory Pigment Common to Animals, Yeasts and Higher Plants, Proc. Roy. Soc. Series B 98: 129, 1925.
6. Lewis, T.: Clinical Observations and Experiments Relative to Burning Pain in the Extremities and to So-Called "Erythromelalgia" in Particular, Clin. Sc. 1: 175, 1933-34.
7. Meltzer, S. J., and Auer, C. M.: Studies in the "Paradoxical" Pupil Dilatation Caused by Adrenalin: I. The Effect of Subcutaneous Injections and Instillation of Adrenalin Upon Pupils of Rabbits, Am. J. Physiol. 11: 28, 1904.
8. Mitchell, S. Weir: On a Rare Vasomotor Neurosis of the Extremities and on the Maladies With Which It May Be Confounded, Am. J. M. Sc. 76: 17, 1878.
9. Moritz, F., and von Tabora, D.: Ueber eine Methode beim Menschen den Druck in oberflächlichen Venen exakt zu Bestimmen, Deutsches Arch. f. klin. Med. 98: 475, 1910.
10. Mufson, I.: A Study of the Capillary Pressure in Nephritis and Hypertension, Am. J. M. Sc. 183: 632, 1932.
11. White, J. C.: The Autonomic Nervous System, New York, 1935, Macmillan Company.

Department of Clinical Reports

PATENT DUCTUS BOTALLI WITH SUBACUTE BACTERIAL ENDOCARDITIS AND RECOVERY*

WILLIAM CHESTER, M.D.
MAMARONECK, N. Y.

THE following case is of unusual interest because it is the first recorded instance of recovery from subacute bacterial endocarditis in a patient with a patent ductus Botalli.

REPORT OF CASE

D. W., a woman aged twenty-nine years, was admitted to the Montefiore Hospital on Jan. 16, 1931. She had measles as a child. A tonsillectomy performed in 1929 was followed by a prolonged convalescence. She had had two pregnancies, and both children were living and well. In 1924, during her second pregnancy, a congenital heart lesion was detected.

In September, 1930, the patient was confined to bed because of a rise in temperature and weakness. Frequent chills and profuse sweats supervened, followed by anorexia, asthenia, and a rapid loss of weight. Soon she complained of a hacking, nonproductive cough, palpitation of the heart, shortness of breath, and precordial pain. In November, 1930, she was admitted to the Mount Sinai Hospital (New York City), where a diagnosis of patent ductus Botalli and subacute bacterial endocarditis *(Streptococcus viridans)* was made.

Examination on admission at the Montefiore Hospital revealed an emaciated woman weighing 89 pounds. Her face was flushed and the conjunctivae were pale. There was slight cervical lymphadenopathy. The apical beat of the heart was in the fifth intercostal space just outside the midclavicular line. The first sound over the pulmonic area was ringing in character, and the second sound was replaced by a continuous murmur. The heart rate averaged 120 beats per minute. The rhythm was regular, blood pressure 95/50. There were diminished resonance, bronchovesicular breathing and râles at the right base posteriorly. The spleen was firm, not tender; the edge was palpated 2 cm. below the costal margin. There was slight puffiness of the ankles. There was no clubbing of the fingers or toes.

The urine was negative. The blood count showed a hemoglobin content of 65 per cent; erythrocytes, 3,800,000; leucocytes, 10,800; polymorphonuclear leucocytes, 72 per cent; lymphocytes, 23 per cent; monocytes, 4 per cent; and basophiles, 1 per cent. A blood culture showed numerous colonies of *Streptococcus viridans.* The electrocardiogram showed a left axis deviation.

A roentgenogram of the chest showed that the right leaf of the diaphragm was high and moved very little with inspiration. There was marked pulmonary congestion of the central type. The heart was globular, and the left ventricle was rounded. The pulmonary artery and conus were prominent. The aortic arch was narrower than usual. The ascending limb of the aorta was well formed. There was some enlargement of the left auricle. Roentgenograms of the accessory nasal sinuses were negative. The diagnosis of patent ductus Botalli, subacute bacterial endocarditis *(Streptococcus viridans)* and infarcts of the spleen and lung (right lower lobe) were made.

*From the Medical Division of the Montefiore Hospital, Service of Dr. Leopold Lichtwitz.

Clinical Course.—During the patient's stay at the Montefiore Hospital, the clinical picture was that of severe sepsis. On Feb. 23, 1931, she experienced severe pain behind the right breast, aggravated by breathing, associated with dyspnea and cyanosis. Dullness and bronchovesicular breathing were present at the right base. A roentgenogram of the chest at that time revealed pleural thickening and pulmonary consolidation at the right base. Cough with slightly blood-tinged expectoration soon developed. The process was interpreted as pulmonary infarction. The signs at the right base persisted until the latter part of March and were accompanied by a cough with a yellowish expectoration, a low grade temperature, a rapid ventricular rate, and leucocytosis. On March 31, 1931, the patient had a chill, with a temperature of 104° F., and a ventricular rate of 118. She vomited and complained of increased sensitivity in the splenic region. From April 4 to Sept. 2, 1931, the septic course persisted. Frequent episodes of pain at the right base posteriorly and a productive cough were noted. On September 10, the patient was aphonic and showed a complete paralysis of the left vocal cord. The temperature was normal and the ventricular rate accelerated. A blood count at this time showed a hemoglobin content of 60 per cent; erythrocytes, 3,690,000; leucocytes, 6,500; polymorphonuclear leucocytes, 69 per cent; lymphocytes, 28 per cent; eosinophiles, 1 per cent; and myelocytes, 2 per cent.

On Oct. 7, 1931, the blood culture was sterile. The patient's condition was considerably improved. She had been afebrile since Sept. 30, 1931. On Oct. 14, 1931, marked depression, emotional instability, and auditory hallucinations were present. She insisted on going home and was discharged on Oct. 24, 1931, with the mental symptoms as noted. Her weight at this time was 59 pounds. The therapy during the patient's stay at the Montefiore Hospital consisted of the administration of supportive and symptomatic measures.

From Oct. 24, 1931, to February, 1932, the patient was confined to bed at her home. She became mentally clear and less anxious. During this entire period, she was afebrile and free from pulmonary and abdominal symptoms. Her appetite improved, and there was a rapid gain in weight. During the summer of 1932, she resumed her usual household activities and save for slight dyspnea on ascending a flight of stairs felt perfectly well. She commenced menstruating in October, 1932, after a period of amenorrhea of twenty-two months. Severe premenstrual and comenstral pain was present. Physical examination at this time revealed a well-nourished patient weighing 120 pounds, afebrile, and symptom free. The significant findings were the to-and-fro machinery-like murmur and systolic thrill in the second and third left intercostal spaces. The lungs were negative. The spleen could not be felt. There was no tenderness in the left upper quadrant. Fluoroscopy of the heart showed the same findings as noted while the patient was in the Montefiore Hospital.

The patient was again seen on March 18, 1934. Her weight at this time was 125 pounds, and her color was good. The menses had been regular since their onset in 1932, the dysmenorrhea persisting and frequently confining her to bed for a day or two. She performed her household duties without any difficulty. During this period she has had several mild upper respiratory infections, none of which confined her to bed. The heart findings were as noted on the previous examination. The lungs were negative. The abdomen, save for slight tenderness to pressure in the right lower quadrant, was negative.

DISCUSSION

Recovery from subacute bacterial endocarditis is not common. In the large series of patients with subacute bacterial endocarditis studied by Libman and Billings,[1] recovery occurred in from 2 to 3 per cent. Hem-

sted[2] described a complete recovery in a case of subacute bacterial endocarditis superimposed on a congenital defect of the right ventricle.

The unusual course of our patient's illness is remarkable and several points are worthy of emphasis: first, the question of the portal of entry of the *Streptococcus viridans.* In the 330 cases analyzed by Blumer,[3] a possible portal of entry is recorded in 17 per cent. That bacterial systemic infection may follow nose and throat operations is well known clinically. Nephritis and subacute endocarditis have been described complicating these procedures. In the subject of this report, a tonsillectomy with a protracted convalescence antedated the onset of the subacute endocarditis by a few months. It is worth stressing that these minor operations of the nose and throat should be performed during the quiescent stage of disease of the organs involved and that one should strictly consider the indications for operation in all cases and particularly in instances in which congenital or acquired disease of the heart is already present.

The occurrence of the transient left recurrent laryngeal palsy is interesting. This phenomenon was associated with an improvement in the patient's general condition and the commencement of the afebrile period which has persisted to the present time. The left laryngeal palsy present in the case reported by Schrotter and Mead[4] was found at necropsy to be due to the pressure of an enlarged patent ductus Botalli on the left recurrent laryngeal nerve.

The pathogenesis of the pulmonary infarction in this case deserves mention. In the absence of a venous source of emboli to the right side of the heart, one may postulate repeated pulmonary infarction of the right lung, due either to thromboses of the regional pulmonic vessels occurring in situ or to paradoxical emboli passing from the left heart to the right heart through the patent ductus Botalli and lodging in the pulmonary artery.

SUMMARY

Observations over a period of four years on a patient with a patent ductus Botalli and subacute bacterial endocarditis with recovery are presented.

REFERENCES

1. Libman and Billings: Quoted by Blumer.[3]
2. Hemsted, H.: A Recovery From Infectious Endocarditis (Streptococcal), Lancet 1: 10, 1913.
3. Blumer, G.: Subacute Bacterial Endocarditis, Medicine 2: 105, 1923.
4. Schrotter and Mead: Quoted by Abbott, Maude: Congenital Heart Disease, Osler and McRae—Modern Medicine, Vol. 4, Philadelphia, 1915, Lea & Febiger, p. 418.

Department of Reviews and Abstracts

Selected Abstracts

Selected Communications Presented at the Society for Digestive and Metabolic Disorders held in Berlin from July 27 to 31, 1936. (Adapted from the report in the Ztschr. f. Kreislaufforsch., pp. 846 to 850.)

1. Cassisnis (Rome): New Heart Measurements.

Three dimensional measurements made with x-ray show that the heart is definitely bigger in athletes than in nonathletes.

2. Bohnenkamp (Freiburg): Metabolism and Limits of Work of the Heart.

The author reviews the subject. He points out that the heart differs from skeletal muscle in chemical composition. It has more calcium, chlorine, phosphatides, and less potassium and creatin. It has no adenosine phosphoric acid. It depends on a plentiful oxygen supply, and it consumes 4 per cent of the total oxygen consumed by the body. Its oxygen consumption depends on the heart rate and the minute volume output. The oxygen consumption of each beat depends on the diastolic size of the heart. A rapid heart is a less efficient machine than a slow one. In trained individuals, the heart does not speed up as much as in the untrained; hence it is more efficient. At rates above 180 or 200 an inadequacy of coronary flow develops; the heart dilates so that its oxygen consumption increases and it becomes more inefficient. This insufficiency is later contributed to by the development of cardiac irregularities.

3. Knoll (Hamburg): Cardiac Work and Electrocardiograms.

He found a notching of QRS and depression of the S-T segment following severe exercise in normal athletes.

4. Hochrein (Leipzig) confirmed the preceding observations. At times the electrocardiographic picture may resemble that seen in coronary disease. He found that straining causes a sudden outpouring of blood from the lungs into the left ventricle and thereby leads to left axis shift. Later right axis shift develops because the right ventricle works against an increased resistance.

5. Thörner (Bonn): New Observations on Training of Dogs.

Dogs were trained to run on a treadmill. The hearts of those animals running a long distance increased in size when viewed under x-ray.

6. Matteff (Sophia): Orthostatic Circulatory Collapse in Man Following Exercise.

This circulatory collapse is due to gravity shock. The blood pressure sinks to 35 mm. Hg. It can be relieved by placing the individual in a horizontal position and putting elastic bandages on the legs. Hence, it is due to "bleeding into muscle vessels" which follows the stoppage of the muscle pumps.

7. **Rein (Göttingen): The Meaning of Metabolism for the Heart and Respiration.**

His own methods of measuring the blood flow in intact animals have shown that adjustments of the heart and respiration to metabolic needs are peripheral in origin. The first is the adjustment of the blood flow in the muscle to its need. The activity of circulation and respiration increases two seconds after the onset of effort. This early increase must be reflex in origin since it fails when the muscles are denervated. Carbon dioxide is the other stimulus which operates on the vasomotor, cardiac and respiratory centers, and adrenalinemia is a supplementary mechanism.

8. **Broemser (Munich)** emphasized the value of the venous valves in aiding onward movement of the blood.

9. **Kroetz (Altona): Circulatory and Chemical Blood Regulation During and After Exercise.**

Training tends to improve the distribution of blood so that less goes to inactive organs. This acts to lessen the amount of augmentation of minute volume flow required by the heart. There is a linear correlation between flow and exercise, and this correlation is characteristic for each individual and for each type of exercise. The relative acidity of blood during exercise leads not only to a local dilatation of blood vessels but also to dilatation in the lung and thereby aids oxygen exchange. The acidity also leads to dilatation of the coronary arteries, and the increased lactic acid content of the blood makes available a source of nourishment for the heart which keeps down its oxygen consumption. In addition to acidity in general, carbon dioxide acts as a specific stimulant.

L. N. K.

Selected Communications Presented at the Society of German Biologists and Physicians held in Dresden from Sept. 20 to 23, 1936. (Adapted from the report in the Ztschr. f. Kreislaufforsch., pp. 851 to 861.)

1. **F. Volhard (Frankfurt): Value of Eyeground Examination in Hypertension and Renal Disease.**

The author found that uremic amaurosis, uremic spasm, and albuminuric retinitis can occur without appreciable decrease in kidney function. Amaurosis and retinitis are evidence of a deficient cerebral blood supply, and the arterial spasm is evidence of an increased intracranial pressure. Contraction of the small vessels in the eyegrounds in hypertension is a sign of generalized constrictions of these vessels throughout the body, including those of the kidney. It is not related to blood cholesterol content. Albuminuric retinitis (also known as ischemic or angiospastic retinitis) is a danger sign, indicating similar states in vital organs elsewhere.

A drop in blood pressure is an important therapeutic procedure in nephritis since a rise in blood pressure is "a misfortune for the kidney." The elevated pressure in nephritis is not nervous in origin but is due to some chemical substance's being carried away from the kidney by the blood. The kidney is the only organ besides the adrenal and pituitary from which such vasoactive substances seemingly are liberated.

Retinitis occurs in "pale" hypertension and usually not in "red" (essential) hypertension. When it occurs in essential hypertension, it is evidence of the onset of malignant nephrosclerosis.

2. **Thiel (Frankfurt): The Significance of Eyeground Examination in the Diagnosis and Differential Diagnosis of Hypertension and Kidney Disease.**

In essential ("red") hypertension of Volhard only the systolic pressure is elevated, and there are no renal damage and no eyeground changes. In fact, the retinal vessels are dilated. The appearance of sclerosis is indicated by whitish gray streaks along the vessels and small discrete hemorrhages. Later arteriosclerotic retinitis develops with retinal hemorrhages which follow thrombotic arterial closures or venous occlusions. As the hemorrhages disappear, they give rise to white speckling which appears and disappears. Papilledema and vascular spasm with "silver wire" vessels in the eyegrounds is the evidence that the hypertension has changed from the "red" to the "pale" form. At this stage yellowish white spots appear, and the picture is that of angiospastic retinitis.

3. **Siebeck (Berlin),** in discussing the circulatory complications of hyperthyroidism, emphasized the value of potassium iodide (0.5 gm. three times a day) given together with digipurat (2 c.c. intravenously two to three times a day). The arrhythmias and tachycardias of hyperthyroid states are best treated with quinidine.

4. **Bansi (Berlin)** emphasized the frequent occurrence of hypertension in hyperthyroid disease. Tachycardia in hyperthyroid states, when the only abnormality, is not evidence of circulatory insufficiency. Arrhythmias and paroxysmal tachycardia, on the contrary, are indications for surgical intervention. Thyrotoxic myocarditis is difficult to diagnose clinically.

5. **Olivet (Berlin): Arteriolosclerotic Hypertension ("Pale" Hypertension).**

The prognosis of this form of hypertension is from three to six years. A high diastolic pressure is a sign of bad omen. Headache, albuminuria, polyuria occur early in the disease, and eyeground changes are prominent. Late in the disease changes in kidney function become apparent.

6. **Böhme (Rostock)** reported the findings in two cases obtained by roentgenkymography. Kymography of a thirty-two-year-old man who had suffered from pulmonary hemorrhages since the age of eight showed in the left hilus a walnut-sized shadow which had arterial pulsations. This tumor was connected to the aorta. A systolic murmur was audible over the chest in the region. These findings led to the diagnosis of a patent ductus arteriosus with saccular aneurysm of the pulmonary artery. On deep inspiration this aneurysm increased in size and the arterial pressure fell 20 mm. Hg. This aneurysm caused venous stasis and bronchial varicosities by compression of the hilus; and the latter were the source of the pulmonary hemorrhages. Kymography of a twenty-year-old boy with cardiac dilatation following paratyphoid fever showed marked pulsations of the upper third of the left heart border with the pulsations in the lower two-thirds moving in the opposite direction. In this case there was an inspiratory elevation of the cardiac apex which the author considers a sign of cardiac dilatation.

He then reported some observations on animals in which x-ray opaque substances were injected into the circulation. In this way he noted marked fluoroscopic evidence of a systolic suction by the ventricles, which caused the auricles to fill at this time. In animals with damaged circulation or cardiac dilatation he found that this suction action diminished or was absent. In determining the work of the heart, this systolic suction must be included in the calculations.

7. **Kroetz (Altona): Peripheral Veins in Rheumatic Disease.**

The author reports the presence of venous sacculations and venous enlargement in the lower extremities during rheumatic disease. These disappear after the rheumatic fever has healed. He used infra red photographs to study these vessels or employed ruby glass through which he could view the leg. These venous enlargements may be inflammatory or the reaction to the products released in the inflamed joints.

8. **Vodel (Berlin)** advocated the use of breathing exercises to lower blood pressure in hypertension. The breathing was the deep abdominal type used against light resistance. This was carried out two or three times a week, each period being for twenty to twenty-five minutes.

L. N. K.

Selected Communications Presented at the German Physiological Society held in Giessen and Bad Nauheim from Aug. 30 to Sept. 2, 1936. (Adapted from the report in Ztschr. f. Kreislaufforsch., pp. 816 to 820.)

1. **K. Matthes (Leipzig): Studies on Oxygen Saturation of Arterial Blood in Man.**

The author determined oxygen saturation of arterial blood within the ear and finger by his own method and compared it with alveolar oxygen tension. He found that a definite difference existed between the oxygen tension in the blood and the alveoli. He used this method also to determine the blood velocity in terms of circulation time.

2. **W. Springorum (Göttingen) and D. Centenera (Madrid): Blood Flow of Both Kidneys Studied with Rein Stromuhr.**

The flow is not proportional on the two sides, and differences of as much as 100 per cent occur. These differences vary from time to time and are not related to diuresis. Vasoconstrictor substances do not affect vessels of both kidneys equally.

3. **F. Palme (Bad Nauheim): Concerning the Chemical Receptors of the Carotid Sinus.**

Adrenalin in some animal species causes a long lasting blood pressure drop when applied to the carotid sinus. This is due to stimulation of the sinus nerve and seems to depend on the amount of chromaffin cells in the paraganglion caroticum. This and other evidence suggests that the chromaffin material is a hormonal regulator of the carotid sinus. The author believes this will explain many observations previously attributed to chemical receptors.

4. **E. Holzlöhner (Kiel): Systolic Suction of the Human Heart.**

The cardiopneumogram of man is a measure at any moment of the difference between the amount of blood discharge from the thoracic arteries and the amount of blood entering the thorax via the veins. The smallness of the change in the pneumogram occurring during systole indicates that a suction action of the contracting ventricle brings into the chest an amount of blood almost equal to the amount discharged from it in systole.

5. **O. F. Ranke (Berlin): Importance of Position on the Ability to Withstand Acceleration.**

When acceleration exceeds 7 gm. in the lower limbs, petechia occurred. (This acceleration was apparently obtained by the author by centrifugal force, but this is not so stated in the abstract from which this report is made.)

6. E. Schütz and B. Lueken (Berlin): Changes in Irritability of Heart Following Systole.

A method of stimulating the heart at the end of its monophasic action curve with rectilinear electrical impulse of very short duration is described. The threshold of irritability falls rapidly at the end of the monophasic curve and reaches normal in about one-tenth of the time occupied by the monophasic curve. Potassium lengthens the refractory phase, and calcium shortens it. A similar antagonism is demonstrated between adrenalin and acetylcholine. Wherever a marked lengthening of refractory phase occurred, direct leads showed an extremely small and short action current.

7. E. A. Müller (Munster): Heart Work and Heart Volume.

At constant minute volume output an increase of arterial pressure in the pulmonary vessels increases the size of the right heart five to seven times more than the increase produced in the size of the left heart by a similar rise in aortic pressure. It is not possible to study the action of an increased minute volume at constant resistance in the heart-lung preparation since the increased minute volume causes both the right auricular and pulmonary pressures to rise.

8. Kahlson (Lund) and O. Mertens (Göttingen): The Cardiac Minute Volume in the Intact Animal Following Adrenalin.

The authors find that the minute output of the heart never increases and in many cases actually decreases to a slight or marked extent following adrenalin injection. In the rest it is unchanged. The flow in a limb decreases by 70 per cent during the eight minutes of adrenalin action. This is usually more or less compensated for by the splanchnic area.

9. H. Gerstner (Leipzig): The Problem of Blood Pressure Rise Following a Strong Electrical Current.

Both the abdominal and arterial blood pressures rise when a strong electrical current is passed through an animal.

L. N. K.

Springorum, W.: The Reactions of the Vessels of the Skin to Active Principles of the Body. Arch. f. d. ges. Physiol. 238: 353, 1936.

The author employed Rein's thermostromuhr for measuring the blood flow in small arteries known to supply, and small veins known to drain, only skin. The animals used were dogs. Two sites were selected as most convenient: a small artery and vein (1) serving the skin of the ear and (2) those serving an area of the hip and thigh. Simultaneous records were in this way obtained of the flow of blood in a small artery supplying skin, the small vein draining that particular region, and the arterial pressure in the carotid or femoral artery.

Small amounts of adrenalin caused a prompt decrease in blood flow through the artery and a somewhat slower return to the normal rate. Two types of reaction were observed in the veins: one in which the change in rate of flow followed that in the artery almost simultaneously and one in which a small increase accompanied the decrease in the artery and then a delayed decrease which was considerably slower than that of the artery in returning to normal. The latter reaction is of considerable interest, for in this reaction lies the explanation of mobilization of a not inconsiderable amount of blood ordinarily stored in the skin. Figures for the relative frequency of the two types were not given. The flow of blood into the skin through

the artery decreases while that flowing out increases. This dissimilarity in flow may persist for as long as a minute. The author states that he wishes to emphasize the fact that the type of venous flow varies not with the site chosen for study but with the individual animal.

Histamine evokes a sharp *increase* in flow through both the artery and vein, almost simultaneous with the fall in arterial pressure. The venous response may be delayed, thus providing for *storage* of blood in the skin. It was also observed that if the dose of histamine was larger, the curve of increase of peripheral flow might be temporarily interrupted only to continue on to its peak simultaneously, with reestablishment of arterial pressure. This phenomenon appeared to be plainly a passive one to the author and might be capable of explaining variation in the published results. The results obtained with acetylcholine were for the most part very similar to those obtained with histamine, but were, perhaps, more pronounced. The study demonstrates clearly the occurrence of withdrawal or admission of blood to the depots in the skin. In passing, the author mentions the fact that the skin is apparently ten to fifteen times as sensitive to adrenalin as the kidney.

J. M. S.

Bärtschi, W.: The Reaction of Coronary Arteries to Acetylcholine. Arch. f. d. ges. Physiol. 238: 296, 1936.

Because of confusion over the question of the reaction of the coronary arteries to acetylcholine, the literature of which the author briefly reviews, Bärtschi thought that it was worth while to test in a standard manner a rather large number of specimens. Twenty-nine preparations of ox-heart coronary arteries were tested one hundred and eleven times. The almost invariable result was contraction. In one preparation contraction was obtained eleven successive times without diminution. It followed as great a dilution as one part in 25 million in one instance; sometimes as much as one part in 500,000 was needed. Atropine abolished the reaction, adrenalin reversed it; that is to say, adrenalin was followed by dilatation. The experiments were carried out on excised rings of arteries, 2 mm. wide, obtained from animals one and a half to two and a half years old, at times varying from one hour to three days after slaughter. That atropine abolished the reaction would appear to obviate the objection to the use of excised rings.

J. M. S.

Dragstedt, Carl A., and Mead, Franklin B.: A Pharmacologic Study of the Toxemia Theory of Surgical Shock. J. A. M. A. 108: 95, 1937.

The abrupt vasomotor symptoms of anaphylactic shock may be duplicated by rapid intravenous injection of a large dose of histamine. In each instance the presence of a vasodepressor, smooth muscle stimulating substance which is apparently histamine, can be detected by the usual biological assay of heparinized blood plasma or thoracic duct lymph. In nine experiments on dogs in which the surgical shock was produced by traumatization of one or both hind legs or by traumatization of the extruded intestine, or a combination of these procedures, no physiologically active substance could be found in the blood or lymph.

In an attempt to duplicate the gradually progressive blood pressure fall of surgical shock in order to eliminate the objection that histamine might not be detected because it is soon inactivated, the authors used slow continuous intravenous injection of varying concentrations of histamine without success in exact reproduction of surgical shock.

Four twin experiments were performed using two dogs each. In the one dog surgical shock was produced, in the other shock was produced by histamine sub-

cutaneously. Samples of blood and lymph were taken and tested simultaneously. Uniformly, blood samples in surgical shock were negative, while in the same amount of shock by histamine the samples were positive.

L. S.

Brouha, L., Cannon, W. B., and Dill, D. B.: The Heart Rate of the Sympathectomized Dog in Rest and Exercise. J. Physiol. 87: 345, 1936.

The factors which determine the acceleration of the heart rate as a result of exercise have been studied in many experiments. In order to obtain additional information concerning these factors, a series of experiments has been performed on totally sympathectomized dogs. A standard form of exercise on a motor-driven treadmill, running at different speeds for different periods of time, was used to test the behavior of the dogs. From these experiments one can conclude that the cardiac rhythm of the inactive sympathectomized dog is less than that of the normal animal. However, emotional excitement produces definite cardiac acceleration, and on exercise there is an increase in heart rate which is about 30 to 40 per cent below that of the normal dog. The general behavior in dogs is quite different from that of sympathectomized cats. The capacity to withstand intense exercise is not diminished in the sympathectomized dog, but because of lack of training there is a lessened capacity for prolonged exercise for from six to eight weeks following sympathectomy. This differs somewhat from the results obtained in a similar experiment by Samaan, who found that his sympathectomized dogs had an increased capacity for work despite the fact that their heart rates were only two-fifths the normal maximum. Cardiac acceleration after sympathectomy is not due to a rise in body temperature nor to muscular metabolites, secreted adrenalin, or sympathin, but is probably due to a reduction in the tonicity of the cardioinhibitors of the vagi and an increase in the tonicity of the vagal cardioaccelerators.

E. A. H.

Kreuzfuchs, S.: Occult-Pulmonary Cardiopathy. Ztschr. f. Kreislaufforsch. 28: 841, 1936.

The author describes lung conditions which displace the trachea in the x-ray picture and change the aortic shadow. The symptoms in such cases are not to be considered cardiac in origin nor should they be described as neurotic manifestations. They are evidence of the pulmonary involvement.

L. N. K.

Eldblom, L. E.: Investigations of the Difference in Skin Temperatures Between the Lower Extremities in Unilateral Sciatica. Acta med. Scandinav. Suppl. 78, Report of 17th Scandinavian Congress of Medicine, June, 1935, p. 834.

The results of studies on 43 normal and 57 individuals with sciatica are given. The method of measuring what the author speaks of in the title as "skin temperatures" and usually in the text as "heat-transmitting capacity" is of considerable interest. Cylinders lined with cloth are placed about the thighs, the ends being closed by boards with holes in them to fit the leg so lightly that disturbance of the circulation does not occur. The bulb of a mercurial thermometer is thrust through a snugly fitting hole into this rough calorimeter, leaving the scale, reading in 0.1° C., outside. The cylinders are the same size. The two pairs of boards chosen to close the upper and lower ends have apertures of the same size, and so, whether or not the two legs are of the same size, when the cylinder and boards are pushed far enough up the thigh for the apertures to fit snugly, approximately equal areas of skin are included in the two calorimeters. The thermometers are then read until

their recorded temperature has become constant, which takes place within from forty-five to seventy-five minutes. Obviously the temperature in the cylinders bears some relation to the rate of heat production of the enclosed leg and to the rate of heat lost to the room. If the latter is constant, the temperature increases in some fashion with increase in production of heat by the tissue enclosed. The author states that "actual 'absolute' temperature of the skin is at most only an abstract idea," and that relative measurements therefore often furnish adequate data for comparing blood flow.

In 43 normal individuals, the final differences in temperature which were established within the cylinders on the two thighs were 0.2° C. in 7, 0.1° C. in 16, less than 0.1° C. in 3, and 0.0° C. in 17. In 57 individuals suffering from sciatica the calorimeter on the affected leg was less than the normal by from 0.5 to 0.9° C. in 15 cases, by 0.4 in 5 cases, and by 0.3 in 14 cases. That is to say, 34 cases showed differences greater than normal. Ten were borderline cases (0.2° C. difference always, however, lower on the affected side) 8 were normal, and 5 showed temperatures higher on the affected than on the normal leg. He states that all of the last groups had been treated. Eleven cases were studied during recovery, and in each a tendency to increase in temperature with respect to the normal side was observed.

In one experiment a normal individual was subjected to rather excruciating pain by placement of paper clips and "Paens" forceps on the skin of the foot and thigh of one leg. The position of the clips was frequently changed. Contrary to most observations of surface temperature in pain, a rise in heat-transmitting ability occurred not only in the injured, but also in the opposite leg and to the same degree. This suggests that the low temperature usually found in the sciatic limb is not a pain reflex.

Concluding from these observations that many cases of sciatica are associated with, if not due to, a lowered blood supply the author proceeded to treat them with caffeine, which he has previously demonstrated to be a vasodilator of skin vessels, and with "fever treatment" by injecting suspensions of killed colon bacilli. For both of these forms of treatment he claims excellent results although details are not given. With the onset of fever he observes that the heat transmitting capacity of both legs rises and the pain disappears, the affected one lagging behind at first but gradually attaining the same capacity as the normal leg.

J. M. S.

Kenenhof, W. T., and Kohl, H.: Contributions to the Physiology of Age: IX. Chemical and Histological Studies Upon the Aorta of the Horse. Ztschr. f. d. ges. exper. Med. 99: 43, 1936.

The authors have undertaken the present study as a sequel to the studies of Bürger and Schlomka dealing with chemical changes in tissues with age in order to furnish additional evidence concerning purely physiological changes with age. The horse was chosen for study because the cow and ox, studied by Gerritzen, are usually slaughtered before the age of fifteen years.

The aortas were obtained from 69 horses, 20 from 1 to 10, 29 from 11 to 20, and 20 from 21 to 36 years old. The animals had been for the most part engaged in farm work and fed on oats, hay, chopped straw, and bran. The thickness of the wall and content of moisture, nitrogen, cholesterol, and calcium were studied. Histological sections were also made.

The thickness of the wall of the arch increased from 4.75 to 6 mm. (average of the first and third decades), but at the caudal end no increase occurred. The dry weight in grams per cent of fresh tissue increased regularly for each decade, the first 22.56 per cent, the second 25.15 per cent, the third 26.30 per cent, but the

nitrogen content was, interestingly enough, greatest in the second decade, 4.23 gm. per cent of fresh tissue (first decade, 3.88, and third, 3.93 gm. per cent). It follows obviously that the increase of dry weight did not represent merely a uniform loss of water. This conclusion was borne out by the fact that cholesterol and calcium contents increased markedly and were found to be respectively, in the first decade 144.4 and 12.80, in the second, 202.9 and 20.58, and in the third 240.3 and 27.2 mg. per cent.

Histological changes were most striking in the media. Two microscopic sections, one from the aorta of a six-year-old, and one from a twenty-six-year-old horse, are reproduced. The essential changes were decrease in the number and concentration of elastic fibers and nuclei and deposition of an indeterminate gelatinous substance which is, as deduced from staining reactions, not amyloid, hyalin, or glycogen. The substance was found to stain specifically with cresyl violet.

Because of the nature of the diet of these animals, the authors believe that the changes observed were not related to it and that they have, therefore, to do only with physiological aging. They express the opinion that because of the work of Anitschow and subsequent workers entirely too much emphasis has been placed upon the influence of diets rich in ergosterol and cholesterol which were, apparently, conspicuous by their absence in the diet of the horse, and upon the use of nicotine and alcohol which the horses obviously did not use.

One criticism of the criteria used for estimation of age, namely, condition of the teeth, seems, however, to merit attention. It is conceivable that the physiological age of the teeth might parallel the physiological age (as described) of the aorta rather than the chronological age of the animal.

J. M. S.

Weiss, Soma, Wilkins, Robert W., and Haynes, Florence W.: The Nature of Circulatory Collapse Induced by Sodium Nitrite. J. Clin. Investigation 16: 73, 1937.

Sodium nitrite, which in the prone normal subject will produce slight or no circulatory changes, will lead in the upright patient to progressive vasomotor collapse, often terminating in syncope. A study of seven normal adults showed that after administration of sodium nitrite the upright position produced restlessness, yawning, perspiration, cyanosis, ashen color, drowsiness, dilated pupils, and syncope. The systolic blood pressure fell; the diastolic blood pressure was sustained; and the venous pressure fell rapidly to a level below the hydrostatic level of the right auricle; tachycardia was present until bradycardia appeared just before syncope; and the maximal blood flow through the hand was moderately decreased until just before syncope when it decreased to zero. The blood flow to the legs decreased in the upright position before and after administration of sodium nitrite. Skin temperatures and electrocardiograms showed no remarkable changes.

The vasomotor collapse produced by sodium nitrite is essentially due to a disproportion between circulating blood volume and the volume of the peripheral vascular bed, caused by a peripheral pooling of blood.

L. S.

Wilkins, Robert W., Haynes, Florence W., and Weiss, Soma: The Rôle of the Venous System in Circulatory Collapse Induced by Sodium Nitrite. J. Clin. Investigation 16: 85, 1937.

Using the *height* of the plethysmographic tracings as an index of decreased resistance of the "venous" vessels to stretch, and the *steepness* of the curves obtained as an index of arteriolar resistance to blood flow, the authors found a definite decrease in the "venous" tone after administration of sodium nitrite; even in the simul-

taneous presence of an increase in the resistance offered by the arterioles to the flow of blood. There was definite decrease in "venous tone" in four of five subjects tested at 37.5° C. The variable response of the hand at 32° C. became marked response in the presence of reflex vasodilatation produced by placing the opposite hand in water at 45° C. Decrease in resistance to stretch in the veins following administration of sodium nitrite results in an excessive dilatation of these vessels under the additional stress of the hydrostatic pressure of blood when the subject is in the upright position; this results in a peripheral pooling of blood.

These observations demonstrate a blood depot in addition to that in the splanchnic area. Certain types of collapse may be attributable to this peripheral depot.

L. S.

David, F., and Siedek, H.: A Bloodless Method for Measuring Pressure in the Pulmonary Artery. Ztschr. f. d. ges. exper. Med. 100: 54, 1936.

The method was suggested to the authors by the observation during bronchoscopy that a certain portion of the wall of the right bronchus pulsated synchronously with the heart and by the fact that anatomically this portion lies almost against the pulmonary artery. The procedure is to place a small rubber balloon in the bronchus at the point which pulsates, to connect it by a rubber tube to a mercury manometer, a Frank capsule, a Broemser glass membrane manometer, a slow release valve, and a pressure pump. The balloon is then blown up to a pressure exceeding that existing in the artery and allowed to fall slowly. The Frank capsule records the pulsation, the glass membrane manometer the level of pressure (calibrated by the mercury manometer) optically upon photographic paper. The point at which the ordinate passing through the region of maximum pulsation as registered by the Frank capsule cuts the simultaneous record of pressure in the balloon is taken as the pressure in the pulmonary artery.

The four records given as samples of some 35 or 40 experiments on dog and man are far from decisive not only as to where oscillation begins and ends, but even as to where maximum oscillation occurs. Eight comparisons of this method in dogs with direct measurements agree, however, within 10 per cent. The range of pressures found to exist in the pulmonary artery was from 18 to 40 mm. Hg for both dog and man.

The ingeniousness of the method is admitted, but until clearer oscillatory records can be obtained enabling one to estimate systolic and diastolic levels, or at least a clear-cut mean pressure, the method would not appear to be useful. One must recall also that the anatomical proximity of the pulmonary artery to the bronchus is the only evidence offered that what is being measured is really pulmonary arterial pressure.

J. M. S.

Looney, J. M., and Jellinek, E. M.: The Oxygen and Carbon Dioxide Content of the Arterial and Venous Blood of Normal Subjects. Am. J. Physiol. 118: 225, 1937.

A study has been made of the venous blood oxygen and carbon dioxide in 67 normal subjects and of the arterial blood in 29 normal subjects. The levels of these gases in both arterial and venous blood show considerable variation in the same individual at different times. The normal mean value of venous oxygen is lower and the mean value of carbon dioxide is higher than the values commonly accepted.

These differences are thought to be due to too much reliance on oil to protect the blood gases from exchange with the atmosphere. No significant correlation was found between the levels of arterial and venous oxygen or carbon dioxide.

E. A. H.

Kohan, B., and Hoffmann, J.: Electrocardiographic Observations in Malaria. Ztschr. f. Kreislaufforsch. 28: 643, 1936.

There is no characteristic electrocardiographic abnormality in malaria, and there is no relation between the amount of abnormality and the severity of the malaria. A common finding in such cases was a transitory prolongation of A-V conduction during the febrile stage of the cycle. In addition in the febrile stage, transitory changes occurred in the P- and T-waves accompanied by a lengthening of the duration of systole.

L. N. K.

Gotsev, T., Lucken, B., and Simmendinger, W.: The Influence of the Splanchnic Region upon the Systemic Blood Pressure. Ztschr. f. d. ges. exper. Med. 100: 81, 1936.

A series of elaborate and yet, in certain ways, rather crude experiments are described in which various portions of the circulatory system were excluded by ligature from participation in vascular reactions to various drugs. The effects of adrenalin, nicotine, histamine, and acetylcholine were studied, first with the circulation intact; second, before and after extirpation of the splanchnic region; third, after various regions such as the head, forelegs, or hindlegs had been excluded; and fourth, when only the splanchnic region remained in the circulation. Oncometers were usually placed about a portion of the small intestine and occasionally about the spleen. In another series of experiments the outflow from the portal vein was measured. The arterial pressure was always recorded, usually by connecting an artery to a mercury manometer. There is a detailed account of the results in each group of experiments and many reproductions of smoked drum records.

The description of the results for the various groups of experiments and the conclusions drawn therefrom are, to the reviewer, confusing and even, in some instances, contradictory. By the described methods, the following reactions of the intestinal vessels were found to exist: 1. After adrenalin and nicotine, vasoconstriction occurred, followed, as previously described by the authors, by vasodilation. The latter reaction is by the present work proved to be passive, i.e., occurs because the blood pressure remains elevated after the peripheral vessels have returned to normal caliber. An elaborate and perhaps misleading method of calculating peripheral resistance (ratio of change in pressure to change in venous outflow per unit of time) is used to substantiate this argument. 2. Acetylcholine gives rise to vasoconstriction in the splanchnic region followed often by vasodilation. Of interest with regard to this conclusion is a record in which a rise of blood pressure and a simultaneous constriction of the vessels of the small intestine follows injection of acetylcholine when the splanchnic region only is in the circulation. 3. Histamine also is followed by contraction of the intestinal vessels (actually measured as decrease in volume of the intestine) and decrease of the outflow from them. The blood pressure fell, however, in contradistinction to the reaction to the three other drugs. 4. Exclusion of the liver, of the splanchnic region, or of a part or the whole of the nonsplanchnic portions of the systemic circulation did not change essentially the form of the reaction of the peripheral vessels to any one of the

four drugs used. This conclusion is difficult to align with the experiment noted under conclusion 2 since in the intact circulatory system acetylcholine was followed by a fall in arterial pressure.

Some of the results of these studies are interesting because they are contrary to the usual conception of the action of such drugs, as for instance, acetylcholine. Unfortunately, the authors are not clear about the particular type of peripheral vessel (i.e., arteriole, capillary or venule) that they are studying. They accept decrease in outflow from an organ as evidence of increase of peripheral resistance and lightly assume, the evidence being very poor, that there is no storing of blood in the organs. They mention, only to waive, objections such as change in volume of the gut itself to the use of intestinal volume as a record of constriction or of relaxation of the intestinal arterioles. For these reasons, the conclusions appear to need confirmation.

J. M. S.

Sunder-Plassmann, P., and Muller, K.: Raynaud's Disease and the Neurovegetative-Hormone System. Klin. Wchnschr. 16: 145, 1937.

A well-studied case of Raynaud's disease of the hands in a woman, twenty-seven years of age, is reported. Numbness and blanching had been present for six years; severe attacks of pain, pallor and cyanosis, and thickening of the skin, for three years. Infections of the fingers had been frequent since adolescence and always healed slowly. Diathermy and use of padutin were without effect. On examination typical attacks of Raynaud's disease of the hands were witnessed, and permanent tropic changes were noted. The feet were cold but otherwise normal. Blood sugar was low (59-67 mg. per cent), and after injection of suprarenin the blood sugar curve showed a delayed rise suggestive of adrenal insufficiency. The blood calcium level was high (15.2 and 17.2 mg. per cent). The notion of a parathyroid tumor was entertained. Bilateral injection of the stellate ganglion with novocaine afforded such complete and immediate relief that extirpation of the left stellate ganglion was done. This operation was followed by flushing of both hands but only the left grew warm, and so four days later the right ganglion was removed; removal was followed by relief of symptoms and increase of temperature on the corresponding side. Examination nine months later showed that relief was still complete. More remarkable still were the findings that the level of calcium in the blood had returned to normal (12.5 mg. per cent) and that the rise in blood sugar after suprarenin was less delayed. Pathological changes were found in the excised ganglia. The authors believe that the case supports the idea that Raynaud's disease is of "neurovegetative-hormonal" origin.

J. M. S.

Smithwick, R. H.: The Value of Sympathectomy in the Treatment of Vascular Disease. N. England J. Med. 216: 141, 1937.

Dorsal and lumbar sympathectomies for relief of arterial spasm in upper and lower extremities respectively are successful when preganglionic section rather than ganglionectomy is performed. Long-standing success from lumbar sympathetic ganglionectomy is attributed to the resultant preganglionic section since the synapses to the vasoconstrictor fibers in the foot lie in the ganglia below, rather than in those customarily excised. Ganglionectomy in the thoracic region has not met with success because it consists in removal of the ganglia concerned in the sympathetic innervation of the hand and results in marked sensitivity of the vessel wall to sympathicomimetic hormones. Preganglionic section of appropriate dorsal sympathetics, while leaving the ganglia intact, leads to satisfactory vasodilatation in the upper extremities.

In angina pectoris painful impulses from the heart pass only to the upper four to six ganglia of the thoracic sympathetic trunk. Excision of the ganglia or section of the rami between these ganglia and the corresponding intercostal nerves is an operation of magnitude, but it will result in complete denervation. Paravertebral alcohol injection, when skillfully done, is equally satisfactory, carries a negligible risk, and results in very little disability. The majority of cases require left-sided injections only. Good results were obtained in all but three of thirty-five cases so treated by J. C. White.

Seven methods of splanchnic sympathectomy for relief of essential hypertension are discussed. In early cases symptomatic improvement and a marked fall in blood pressure resulted from appropriate splanchnic sympathectomy. Considerable improvement resulted in less advantageous cases. It is possible that sympathectomy will defer or even prevent irreversible, sclerotic changes in the vessels.

H. M.

Pearl, Felix: Peripheral Arteries: Their Importance in Industrial Practice. California & West. Med. 46: 35, 1937.

The important part played by diseases of the peripheral arteries in industrial accidents has not been sufficiently realized in the past. The rôle of the peripheral arteries as related to industrial practice may be divided into two broad phases: (1) direct injuries to previously normal peripheral arteries; (2) industrial accidents occurring in individuals who have chronic arterial disease. The indications for and treatment of peripheral disease in industrial practice are discussed.

E. A. H.

Lindskog, G. E., and Howes, E. L.: Cervical Rib Associated With Aneurysm of the Subclavian Artery. Report of a Case and Review of the Recent Literature. Arch. Surg. 34: 310, 1937.

A new case of aneurysm of the subclavian artery in association with cervical rib is reported and the literature on the subject which has collected since Halsted's summary in 1916 is reviewed. There is no agreement as to the proper method of treatment in such cases. A study of the cases recorded in the literature reveals that this type of aneurysm does not tend to increase in size nor is there great danger of rupture. It would appear that surgical removal of such aneurysms is dependent upon the presence of complications, such as pressure on the brachial plexus. Recent studies indicate that the vascular deficiency in the affected arm is due to reflex effects on the peripheral arteries from local irritation rather than to the pathologic changes in the artery itself. For this reason, when surgery is done, it would seem that scaleniotomy is preferable to resection of the rib. Such a procedure was carried out with satisfactory results in the case which is reported.

E. A. H.

Silbert, Samuel: Thrombo-Angiitis Obliterans and Addison's Disease in the Same Patient. J. A. M. A. 108: 551, 1937.

A twenty-year-old white youth was observed intermittently from April, 1935, to May, 1936. He had experienced symptoms of peripheral arterial occlusion for one year, and had developed gangrene in a great toe. The foot healed under treatment in six weeks, but a month later pigmentation, hypotension, weight loss, and chemical studies led to a diagnosis of Addison's disease. There was no clinical evidence of tuberculosis or syphilis. The chest x-ray film showed no evidence of tuberculosis. Administration of adrenal extract was followed by a satisfactory decrease in the

manifestations of Addison's disease. No clear correlation is presented between the administration of adrenal extract and further improvement in the condition of the affected limb.

The question is raised whether the Addison's disease could be due to atrophy of the suprarenal glands secondary to obstruction of their blood supply by vascular disease. The author points out that thrombosis of intraabdominal arteries in patients with thromboangiitis obliterans occurs only when the disease is very far advanced and that occlusion of the arterial blood supply of both adrenal glands has never been reported.

H. M.

Flint, E. R.: An Unusual Vascular Complication of Cervical Rib. Brit. J. Surg. 24: 622, 1937.

A nonpulsating swelling in the right supraclavicular fossa was seen in a patient with bilateral cervical ribs. Operation revealed a thrombosed aneurysm of the subclavian artery lying on a sharp projection of a cervical rib. The aneurysm was excised, and the pain which had been present in the hand disappeared.

H. M.

Uprus, V., Gaylor, J. B., and Carmichael, E. A.: Vasodilation and Vasoconstriction in Response to Warming and Cooling the Body. A Criticism of Methods. Clin. Sc. 2: 301, 1936.

The reliability of skin temperature measurements as an index of vasodilation and vasoconstriction has been studied by determining the response of the skin temperature to warming and cooling of the body in four normal subjects and in two subjects with damaged spinal cords from fracture of the spine. Vasodilation was produced by a heat tent or by the method of Gibbon and Landis, and vasoconstriction was produced by placing the limbs which were not tested in tanks of water at 9° C. to 12° C. after adequate warming had occurred. The rectal temperature was taken by a special thermocouple placed high in the rectum. The rectal temperature recorded in this way is believed to be a suitable index of arterial blood temperature and, in all probability, the temperature of the blood going to the central nervous system. These experiments indicate that in the normal subject the onset of vasodilation is dependent upon the local temperature of the limb, the posture of the limb, and the rapidity of rise of blood temperature. The hot air bath produced only a low gradient of blood temperature rise, whereas, immersion methods gave a rise in blood temperature adequate to overcome local conditions apart from marked changes in posture. The gradient of rise of blood temperature is of importance in both the vasodilation produced by the hot air bath and immersion methods, but the actual temperature of the blood is of importance only when the hot air bath is utilized. If the blood temperature is not rising rapidly, the time of onset of vasodilation in the limbs of the subject should not be accepted as an indication of disturbance of the nervous mechanism.

E. A. H.

Book Reviews

DIE HERZ- UND GEFÄSS- KRANKHEITEN. By PROFESSOR DR. WALTER FREY, Direktor der Medizinischen Universitätsklinik, Bern. Berlin, 1936, Julius Springer, 341 pages, 61 figures. Price (paper) RM 29.—; (bound) RM 32.60.

Frey has recently published an interesting volume on diseases of the heart and blood vessels in which he discusses the fundamental background of the various abnormalities of the circulation. The book is essentially one of etiology, pathology, and pathogenesis. Much less attention is paid to the clinical side—that is, to the diagnosis, prognosis, and treatment. Hence the work is much more important as a fundamental survey for the student and practitioner than for clinical reference. It is refreshing to find a volume like this from the Old World based on an etiological classification.

The arrangement of the book is as follows:

I. Embryology (a few pages).

II. Congenital defects and developmental defects, with tables of normal growth, and including a discussion of involution in old age. The author refers in this section of the book to the fact that there is no growth hypertrophy of the heart as such.

III. Indurative lesions, including scleroses and abnormal muscle chemistry.

A. Cardiosclerosis.

1. Aortic sclerosis.
2. Valvular sclerosis (in which too much space is given to mitral sclerosis).
3. Coronary sclerosis (in which the arrhythmias are discussed).

B. Arteriosclerosis.

1. Aorta.
2. Pulmonary arteries.
3. Middle sized vessels.

Under this heading there is a discussion of blood pressure, elasticity of arterial walls (with formulas), pulse pressure and the sphygmogram, pulse size, and heart size and form. There is too much included here.

4. Sclerosis of the visceral arteries (arteriolosclerosis) with a discussion particularly of kidneys, pancreas, and spleen.

C. Phlebosclerosis.

These sections complete about half the book. Then we go on to

IV. Bacterial toxic damage, mostly allergic, with a discussion of

A. General pathogenesis.

1. Leucocyte reaction.
2. Metabolic reaction.
3. Fever.

B. Carditis.

1. Endocarditis, subdivided into the rheumatic, ulcerative, and inactive valve lesions. Rather clumsily under heading *A*, there is a discussion of the treatment of myocardial insufficiency and the application of digitalis, etc.

2. Myocarditis.

a. Parenchymatous, as from diphtheria.
b. Interstitial rheumatic.
c. Embolic bacterial.

3. Pericarditis.

a. Contact pericarditis—dry, with effusion, and adhesive. Here it is of interest to note that the author suggests a trial of diathermy in calcification of the pericardium.

b. Rheumatic, in which Brauer's and the so-called Schmieden's (the Delorme) operation are recommended. It has been the general experience, however, that rheumatic pericarditis does not fit into this category, that is, constrictive pericarditis is practically never the result of rheumatic pericarditis and so this recommendation of therapy is misplaced.

c. Bacterial, embolic.

C. Arteritis.

1. Bacterial.

a. Mycotic.

b. Tuberculous.

c. Syphilitic. This discussion of syphilitic arteritis, including the details of treatment, is one of the most satisfactory sections of the book.

2. Toxic, rheumatic.

a. Periarteritis nodosa.

b. Thromboangiitis obliterans.

D. Phlebitis.

1. Bacterial, embolic.

2. Toxic, a-bacterial, reactive.

V. Endocrine and vegetative nervous affections of the heart function.

A. The so-called dysglandular conditions.

1. Hyperthyrosis (hyperthyroidism).

2. Hypothyrosis (myxedema).

3. The climacterium.

4. Adrenal insufficiency.

B. Neuroses.

1. Constitutional, congenital.

2. Acquired.

The volume closes with a brief index.

This book can be heartily recommended to those who wish to study or to review the fundamental causes of cardiovascular disease, but it cannot be satisfactorily used as a textbook for the diagnosis and treatment of these disorders.

Errata

In the article, "Coronary Thrombosis: An Investigation of Heart Failure and Other Factors in Its Course and Prognosis," by A. M. Master, M.D., S. Dack, M.D., and H. L. Jaffe, M.D., New York, N. Y., appearing on page 330 of the March issue, the following corrections are made:

In Table IV the heading "Slightly Prolonged (12-20 sec.)" should read, "Slightly Prolonged (18-20 sec.)" instead.

On page 340, line 12, "(13 per cent)" should be changed to "(26 per cent)."

In Table XII the last three figures in the last column should read: 42%
60%
16 (42%).

The American Heart Journal

Vol. 13 May, 1937 No. 5

Original Communications

THROMBOANGIITIS OBLITERANS IN NEGROES*

Report of Five Cases Studied Arteriographically and Pathologically

Wallace M. Yater, M.D.
Washington, D. C.

THROMBOANGIITIS obliterans, proved pathologically, has apparently never been described in negroes. The only reference in the literature to the occurrence of this disease in a negro is that of Gemmill,[1] who reported a case of bilateral gangrene of the legs as such but who unfortunately did not perform a pathological study of the vessels of the amputated limbs. Questionnaires sent to some of the leading authorities on peripheral vascular disease, including E. V. Allen, Geza de Takats, Saul S. Samuels, and Howard R. Mahorner, produced replies to the effect that they had never heard of or seen a proved case of thromboangiitis obliterans in a full-blooded negro. Personal inquiry of other clinicians and pathologists elicited information from a few to the effect that they had rarely heard of cases thought to be thromboangiitis obliterans in members of this race.

The cause of the apparently great rarity of this disease among negroes has never been explained, just as its rarity among white females has never been satisfactorily explained. It may be, however, that the incidence of this disease among negroes will be found to be not so rare as it seems, just as its incidence among gentiles has been shown to be much more common than was originally supposed. The following five cases of peripheral vascular disease in negroes seem to fulfill sufficiently the criteria of thromboangiitis obliterans to be considered instances of that disease in members of this race.

REPORT OF CASES

Case 1.—*Clinical History.*—D. H., a full-blooded negro laborer aged forty-three years, was admitted to the Gallinger Municipal Hospital on Feb. 9, 1934, with a chief

*From the Georgetown University School of Medicine and the Gallinger Municipal Hospital.

complaint of pain in both feet and deformities of the toes. The history with reference to this complaint dated back to July, 1927. Until that time the patient had not had symptoms referable to the extremities and had been in good general health. On July 10, 1927, for the first time he had a severe "drawing" pain in the great toe of the left foot. There was no history of trauma to the part. Examination at that time at the Freedman's Hospital clinic revealed the left great toe diffusely swollen and extremely tender. On the plantar surface was found a small, firm, nodular area. The pain was lancinating and severe and somewhat relieved by walking. Within several days the entire left foot became swollen and painful. Incision and drainage of the great toe released serosanguinous fluid, after which the patient experienced some relief and the inflammatory process receded somewhat. He continued to have pain, however, and the distal soft parts of the great toe became necrotic and sloughed off, failing to heal and leaving the bone exposed. In August, 1927, therefore, the toe was amputated surgically. Postoperatively the wound healed very slowly, and gradual involvement of all of the toes of the left foot took place, with necrosis, sloughing and exposure of the bone of the distal phalanges. Apparently, there was at this time definite bone destruction, with loss of most of the substance of the phalanges. The condition was considered primarily a dry gangrene. The patient was discharged from the hospital somewhat improved. Subsequently the patient remained at home, reporting at intervals to the hospital out-patient department and complaining of recurring pain in the left foot and chronic ulcerations of the toes of the left foot. In July, 1928, the tips of the toes of the right foot became affected, manifesting ulceration, sloughing and retraction of the soft tissues. The patient now complained of constant, tingling pain in the lower extremities and was unable to walk except with great distress in the feet. Typical intermittent claudication with pain in the calf muscles did not occur, however. At this time the patient also experienced numbness and tingling in the left arm, extending from the elbow to the finger tips, with trophic disturbances in the finger tips. The condition progressed slowly until the winter of 1929, by which time definite scarring of the ends of all of the fingers of the left hand had taken place, with gradual loss of the nails. The patient did not complain of much pain with this affection but stated that the soft tissues of the fingertips showed flattening and star-shaped scarring. Since 1929 he had had recurrences of these attacks each winter, accompanied by chronic ulceration of the toes and periodic severe pain in the lower extremities.

At the time of his admission to the Gallinger Municipal Hospital physical examination revealed dental caries, gingivitis, and chronic tonsillitis. The left cardiac border was found to be in sixth interspace 13 cm. from the midsternal line. A systolic murmur at the apex with an occasional extrasystole was recorded. The blood pressure was 120 systolic and 80 diastolic. The lower extremities were warm, and pulsations were noted as present in the dorsalis pedis arteries of both feet. The foot revealed a healed amputation of the first toe and loss of the distal phalanges of the remaining toes, with dry ulceration and exposure of the bone. The first and fifth toes of the right foot were affected in the same manner. There were stiffness and plantar flexion deformity of the second and third toes of the right foot. No mention was made of the condition of the upper extremities on this admission. The rest of the physical examination was essentially negative.

There was a past medical history of measles, mumps, whooping cough, and chronic tonsillitis. In 1902 the patient had been confined to bed for six months, apparently with acute rheumatic fever. He had had a urethral discharge as a young man and gave a history of a penile lesion in 1908, followed at an unknown later date by seven injections of neoarsphenamine. He had smoked tobacco to a moderate extent until the past year, since which time he had not used tobacco. Since the onset of the

present illness the patient had been in good general health except for pain. This was so severe at times as to cause insomnia. The general history was otherwise negative except for occasional dyspnea and palpitation within the past few years.

An x-ray film of the legs made during this hospitalization was negative for any definite evidence of sclerosis of the vessels. Some chronic periostitis of the middle third of the left fibula was revealed. The bones of the distal phalanges of the left foot were partially destroyed. The Kahn test of the blood was negative. A hemogram was normal except for a slight leucocytosis on one occasion.

The patient was put on a regimen of contrast baths and Buerger's exercises. He responded well to this therapy and in a few weeks was able to walk about the

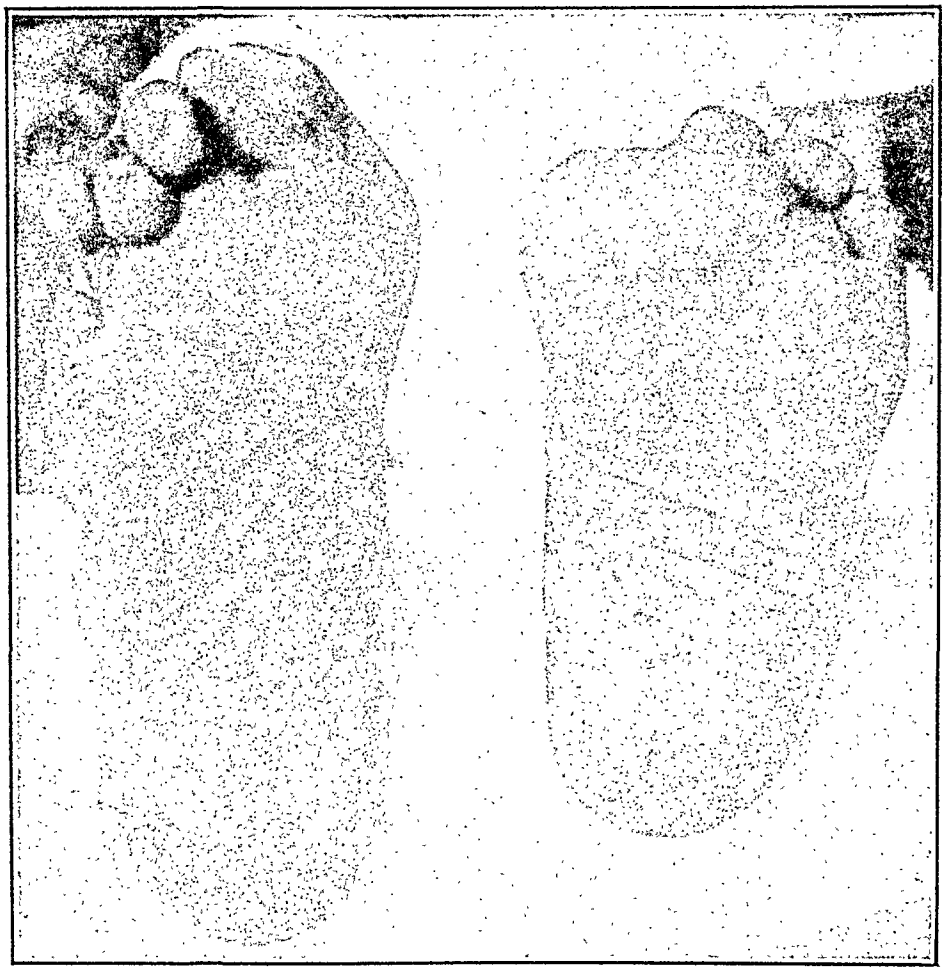

Fig. 1.—Case 1. Appearance of feet in June, 1934.

ward without distress. On several occasions typhoid vaccine up to 20 million bacilli was injected intravenously. Each injection produced a febrile reaction, but apparently little benefit was obtained. These instances were the only ones in the patient's entire hospitalization in which the body temperature rose above normal. When he left the hospital in June, 1934, his condition was considerably improved, the pain having disappeared entirely and healing of the ulcerated areas being almost complete (Fig. 1). He was discharged with a diagnosis of thromboangiitis obliterans of the upper and lower extremities.

The patient was readmitted to the Gallinger Municipal Hospital on Dec. 9, 1935, complaining again of severe pain in the lower extremities and ulceration of the right great toe. On physical examination at this time there were systolic and diastolic murmurs at the base of the heart with occasional extrasystoles. The

cardiac outline was as before. The blood pressure was 120 systolic and 75 diastolic. Examination of the upper extremities showed flattening of all fingertips and some scarring of the soft tissues of the middle finger of the right hand. The left foot was essentially in the same condition as previously with the exception that it was now somewhat swollen. There was a large ulcer in the distal portion of the right great toe, the nail of which had been lost. There was also an ulcerated area between the right great toe and the adjacent toe. The remaining toes were atrophic but not ulcerated. Pulsation was noted in both popliteal arteries but was absent in both dorsalis pedis arteries and in the left posterior tibial artery. The pulsation was good in the right posterior tibial artery. Superficial veins over the tibias were visible and nodular. The rest of the physical examination was essentially negative.

X-ray films of the legs and feet showed no evidence of arteriosclerosis of the vessels, but only trophic changes in the remaining portions of the phalanges. The Kahn test of the blood, the hemogram, the urinalysis, and spinal fluid examinations were all essentially negative or normal. The patient was again placed on Buerger's exercises, experiencing considerable relief in a few weeks. Dry dressings were applied to the toes, which were painted frequently with gentian violet. A heat cradle was used frequently over the lower extremities. Typhoid vaccine was again given intravenously in graduated doses up to 200 million, this time without any febrile reaction and with no apparent benefit to the patient. Antisyphilitic treatment was administered.

On Jan. 15, 1936, thorotrast (stabilized thorium dioxide sol) was injected into the right femoral artery, and arteriograms were made of the leg and foot. These showed the posterior tibial artery relatively normal, but the anterior tibial artery was apparently completely occluded below its lower third. There were many fine collateral vessels, some having a corkscrew appearance. The appearance was that of thromboangiitis obliterans (Fig. 2). On January 18 arteriograms of the left lower extremity were made. They demonstrated occlusion of both tibial arteries in their lower third. Collateral vessels were present as in the right leg, and a few showed a corkscrew appearance. Arteriograms of the upper extremities were not successful.

On January 21 a flat x-ray plate of the abdomen, made after the injection of 100 c.c. of thorotrast intravenously for the making of the arteriograms described, showed the liver of normal density, size, and outline. The spleen also was of uniform density and of average shape and size.

On January 28 surgical exploration of the left posterior tibial artery was undertaken with local anesthesia to obtain a biopsy of a vessel. The artery was dissected out and found to be markedly sclerosed and hypertrophied. A small hypodermic needle was introduced into the artery and a small stream of blood diffused from the artery into the syringe. However, no pulsation was noted. Because of this evidence of blood flow it was decided not to resect the artery.

On February 3 a biopsy specimen was removed from the dorsum of the left third toe. The microscopic section showed only chronic inflammatory reaction throughout. There was considerable round cell and plasma cell infiltration. The blood vessels were very small and few in number. The specimen consisted almost entirely of granulation tissue.

Several days later surgical exploration of the left dorsalis pedis artery was undertaken. It was dissected out under local anesthesia and found to be firm and nonpulsatile. No blood could be obtained from it through a hypodermic needle. The artery was therefore ligated and a portion of it excised.

On February 24 examination of the right upper extremity revealed no further extension of the obliterative process. All of the incisions in the left foot were completely healed. The right first toe had a small, clean, practically healed ulcer on its distal portion. Both extremities were warm, and the patient stated that

Fig. 2.—Case 1. Arteriogram of right leg. Anterior tibial artery occluded in lower third, posterior tibial artery patent. Numerous small collateral arteries visible.

he did not experience any pain and could walk without distress. He felt strong and well. When discharged from the hospital on April 12, 1936, all lesions were completely healed. The patient has been followed in the out-patient department of Georgetown University Hospital since then and has remained well and been free of pain.

Microscopic Study of the Left Dorsalis Pedis Artery.—The portion of dorsalis pedis artery, about 1.5 cm. long, was sectioned at intervals of about 1 mm. and stained with hematoxylin and eosin, van Gieson's connective tissue stain, Masson's trichrome stain, and acid orcein. The lumen was completely occluded with dense fibrous tissue in which were many small blood vessels but no endothelium-lined canals (Fig. 3). Inflammatory elements were not present. The internal elastic lamina was well preserved for the most part, although in one or two small areas it was ghostlike. Adjacent to these areas the fibrous tissue within the obliterated lumen was paler and contained more nuclei but fewer small vessels than the fibrous tissue nearer the center of the obliterated lumen. The acid orcein stain revealed considerable delicate elastic tissue in these portions but very little elastic tissue elsewhere in the obturating tissue, except about one particular small peripheral vessel which had a thick, densely nucleated fibrous collar. The media was irregular in thickness, but on the whole it was thicker than normal. Its inner edge was moderately shaggy, and in places the muscle fibers were disarranged and not parallel. The outer edge was also jagged in places. The media contained slightly more than the normal amount of connective tissue in some sections. Also, in some sections the media was almost normally avascular, while in others there were many small blood vessels. No active inflammatory elements were present. The external elastic lamina was denser and thicker than normal, as was the entire adventitia. Venae comites were not present in the sections. Sections stained for spirochetes by the Dieterle method by Dr. K. M. Langenstrass, of the Blackburn Laboratory of St. Elizabeth's Hospital for the Insane, Washington, D. C. were negative.

Summary of Case 1.—A full-blooded negro, aged forty-three years, had had intermittently for nine years destructive ulcerations of the toes of both feet accompanied by severe pain. Arteriograms revealed arterial changes such as are seen in thromboangiitis obliterans. There was evidence of old superficial phlebitis of both legs. Sections of a biopsy of a dorsalis pedis artery showed the lumen to be filled with fibrous tissue containing small vessels. There had also been trophic disturbances of the tips of the fingers of one hand. The patient had had syphilis, but Kahn tests of the blood and spinal fluid were negative. He had aortic regurgitation; but in childhood he had had rheumatic fever, and the pulse pressure was not increased. It was therefore possible, if not probable, that the aortic regurgitation was due to rheumatic aortic endocarditis.

CASE 2.—*Clinical Course.*—J. P., a full-blooded negro aged thirty-four years, entered Gallinger Municipal Hospital on March 31, 1936, complaining of "sore toes and swelling" of the left foot. About the middle of December, 1935, he had noticed a "sore" on the outer surface of the fifth toe of the left foot. A week later he was forced to stop working as a coal shoveler because swelling of the foot prevented his wearing a shoe. Later, the fourth toe had become similarly affected, and pain had developed. He had remained at home, bathing the foot with a solution of Epsom salts. There was no history suggestive of previous vascular disease. The patient had had a penile ulcer one year before and had received about six injections in the arm at weekly intervals. He was a moderate smoker.

Examination revealed a well-developed but undernourished man. There was nothing of note except in the lower extremities. The fourth and fifth toes of the left foot showed dry gangrene, and the entire foot was cold, dark, "woody" and numb. The skin was broken about 2 cm. proximal to the base of the little toe on the dorsal surface, and thick fluid was oozing therefrom. There were no pulsations in any of the large arteries below the middle of Scarpa's triangle in this limb. Trophic changes were not apparent in the right lower extremity, but, although the femoral and popliteal arteries were felt to pulsate, the dorsalis pedis and posterior

tibial arteries could not be felt. Hemogram, urinalysis, and blood sugar were normal. The Kahn test of the blood was four-plus.

On April 2, 1936, arteriograms were made of both lower extremities with thorotrast. Those of the left thigh and leg showed absence of images usually cast by the femoral and tibial arteries. There were, however, many collateral arteries in both the thigh and the leg (Fig. 4). Many of these were long and superficial; some were undulatory. The arteriograms of the right lower extremity showed the arteries to be apparently normal in the thigh and upper fourth of the leg. Below that point, however, the tibial arteries were seen to be affected by occlusive vascular disease, and there were long, wavy, collateral arteries demonstrable (Fig. 5).

Fig. 3.—Case 1. Cross-section of dorsalis pedis artery (biopsy specimen). Lumen occluded with fibrous tissue containing small vessels; media of uneven thickness; surrounding tissue dense. Masson's trichrome stain. (×40.)

Because of the advanced nature of the gangrenous process affecting the left foot it was decided to amputate without delay. On April 7, 1936, amputation was performed below the knee at the junction of the upper and middle thirds of the leg. This relatively low point was selected because, although the femoral artery was known to be occluded throughout most of its extent, the abundance of collateral vessels augured well for healing. During the amputation there was practically no bleeding and only very small vessels were encountered. Some gangrene developed in the stump, however, and on April 22, 1936, reamputation was performed about 3 inches higher. Following this procedure a heat cradle was kept continuously over the leg, the temperature being maintained at about 100° F., for three weeks. A low-grade fever persisted for several weeks. The patient was discharged from the

hospital on May 31, 1936, with the stump almost completely healed. On July 15, 1936, however, there was still a small unhealed area which was being treated in the out-patient department. Otherwise the patient was quite well.

Fig. 4.—Case 2. Arteriograms of left thigh and leg, indicating occlusion of all major arteries, including the femoral, and showing numerous collateral arteries.

Pathological Study.—The tibial arteries of the amputated leg were recognized with great difficulty. They were small and cordlike, and a lumen could not be seen with the naked eye. The veins were occluded at intervals by thrombi. Microscopic sections were made at various points and stained as in Case 1.

The anterior tibial artery was completely occluded in its upper and middle portions by fibrous tissue containing a moderate number of nuclei and several irregularly shaped, endothelium-lined canals (Fig. 6). Some of these were surrounded by thin

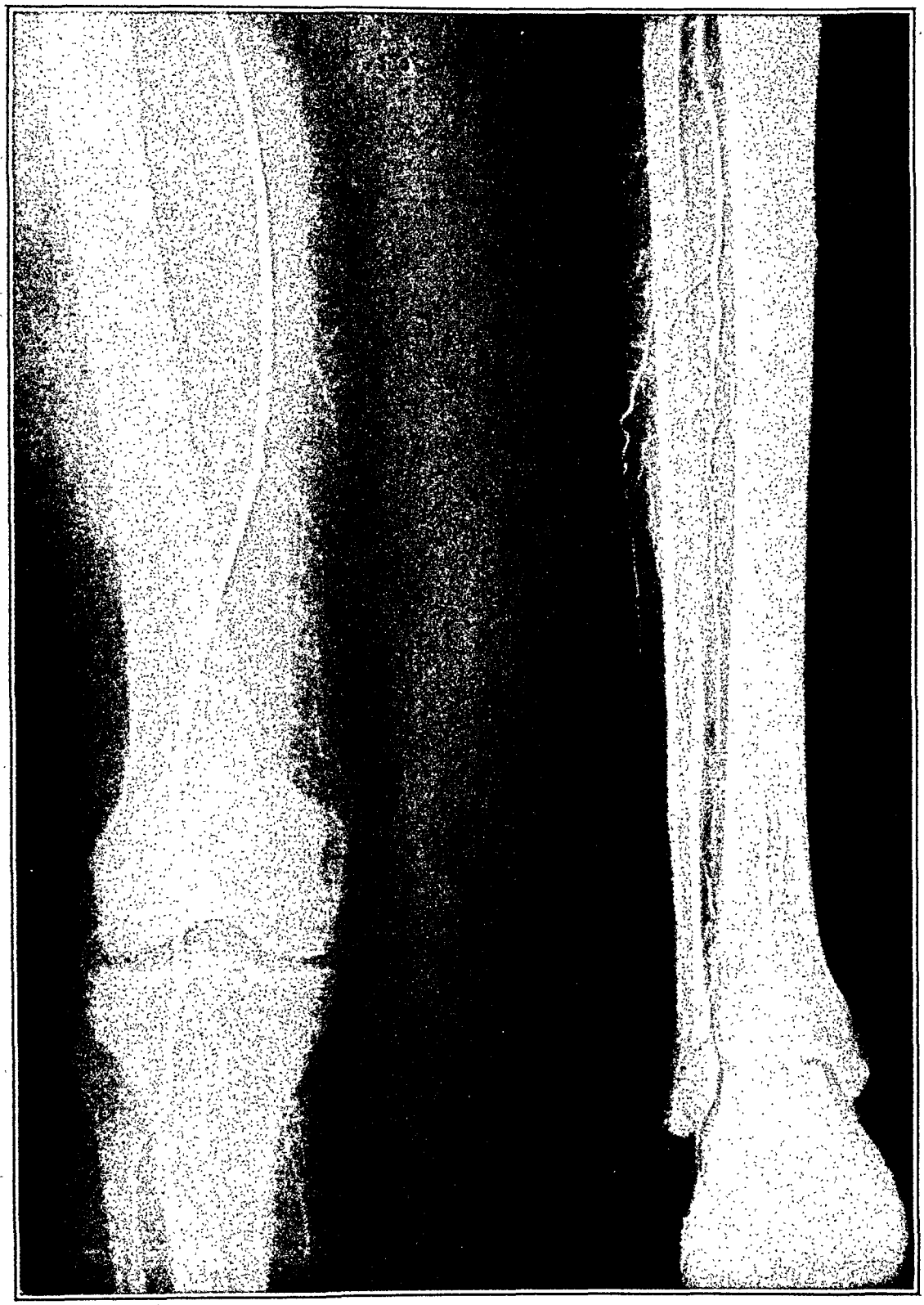

Fig. 5.—Case 2. Arteriograms of right thigh and leg, showing partial occlusion of the tibial arteries and long, wavy collateral arteries in the leg.

muscle sheaths and delicate elastic tissue. Some small vessels were also present. Near the old intima in some areas there were small clumps of hemosiderin. The intima appeared to be somewhat thickened and hyalinized and contained delicate

elastic tissue. The internal elastic lamina was practically intact. The media was slightly thickened and slightly fibrotic. Some small blood vessels were present therein. The muscle cell nuclei were somewhat disarranged. A few discrete lymphocytes were present. The adventitia and immediately surrounding tissues were dense and fibrotic and contained more small blood vessels and elastic tissue than normal. Occasional small groups of lymphocytes were in evidence. Some of the veins had irregular thickening of the intima. One was empty and collapsed, another was distended with a dense, relatively recent clot. The media of this vein was moderately thickened, fibrotic, and vascularized.

Fig. 6.—Case 2. Cross-section of middle of left anterior tibial artery. Lumen occluded with cellular fibrous tissue containing a branching, endothelium-lined canal, smaller vessels and small clumps of hemosiderin. Media thin, fibrotic, and vascularized. Masson's trichrome stain. (×175.)

The lower portion of the anterior tibial artery was empty, and its lumen was collapsed and slitlike but contained some erythrocytes (Fig. 7). The intima was not much altered, but the media was almost replaced by hyaline connective tissue and contained a moderate number of small blood vessels arranged more or less circularly. The surrounding connective tissue was dense and fibrotic. The intima of the veins was considerably thickened and hyalinized in places.

The upper, middle, and lower portions of the posterior tibial artery were similar to the upper and middle portions of the anterior tibial artery. The lumen was filled

with fibrous tissue containing endothelium-lined spaces and small vessels. The media was irregular in thickness, slightly fibrotic, and somewhat vascularized. There was a little elastic tissue in the media. Some lymphocytes were present also, varying in numbers in different sections, but usually not numerous. Several veins were definitely abnormal, with thickening of the intima. Some contained thrombi. One large vein was partially filled with an unorganized thrombus, the free edge of which was covered with a layer of endothelium. The wall of this vein contained a moderate number of lymphocytes, some epithelioid cells in rows and a few polymorphonuclear neutrophiles. One small vein also contained a considerable number

Fig. 7.—Case 2. Cross-section of lower portion of anterior tibial artery and veins, showing artery (in middle) with closed but nonoccluded lumen, very fibrous and vascularized media, and dense periarterial tissue; vena comites (below) shows irregular thickening of intima and fresh thrombus. Masson's trichrome stain. (×25.)

of small lymphocytes and some polymorphonuclear leucocytes in its wall and adventitia. Some veins were collapsed and empty; others contained blood. Spirochetes were not found in the tissues by Dr. Langenstrass.

Summary of Case 2.—A full-blooded negro aged thirty-four years developed gangrene of one of his feet which reached a serious state in three and a half months. He had serological evidence of syphilis. The large arteries of the affected extremity were occluded from Scarpa's triangle down. Arteriograms and physical examination revealed evidence also of occlusive vascular disease of the other leg. The affected

limb was amputated below the knee, and after a secondary amputation the stump gradually healed. Histopathological examination of the tibial vessels of the amputated leg showed fibrosis, vascularization, and canalization of the lumina of the arteries. The media was fibrotic and vascularized and contained some lymphocytes. The adventitia was thickened. The veins showed definite intimal changes and in some places medial and adventitial lesions. Thrombi were present in some.

CASE 3.—*Clinical History.*—R. J., an apparently full-blooded negro laborer aged thirty-six years, was admitted to the Gallinger Municipal Hospital on April 22, 1936, complaining of a painful, tender swelling of the inner surface of the right buttock of two days' duration. At intervals during the preceding two years he had had pain about the anus, sometimes aggravated by defecation. For several days prior to admission the pain had become constant, and he had noticed pus in the stools. On admission a swelling was found in the right ischiorectal region. The temperature was 102° F., the pulse rate was 98 per minute, and the respiratory rate was 20 per minute. On April 23, under ethylene-ether anesthesia, a right ischiorectal abscess was incised and drained, but smears and cultures of the pus were not obtained. On April 25 the patient suddenly began to have severe pain in the calf of the right leg. The affected area became numb shortly thereafter. During the next few days the pain shifted to the foot. Hanging the foot over the side of the bed gave some relief from the pain. The past history was essentially negative except for a urethral discharge fifteen years previously, a course of five injections for "blood disease" in 1925 and a sore on the penis in 1930. There was no history suggestive of peripheral vascular disease. The patient had smoked about twenty cigarets daily for years.

On examination on May 12, 1936, the following abnormalities were noted. There was marked dental caries. The pupils reacted sluggishly to light. Pulsations could not be felt in the vessels of either lower extremity below the femoral triangle. The lower half of the right leg and the right foot felt colder than similar parts of the left lower limb, and a black area was present on the plantar surface of the right little toe. The difference in temperature between the two legs was corroborated by readings with the dermotherm. Oscillometric readings in both thighs were so low as to be of no recording value. The upper extremities were apparently normal. The blood pressure in the arms was 100 systolic and 70 diastolic. The urine contained a faint trace of albumin. The Kahn test of the blood was four-plus. The leucocytes in the blood numbered 40,000 per cubic millimeter.

Several attempts to make arteriograms of the left lower extremity in the usual way were unsuccessful. Finally, an incision was made over the left femoral triangle and the femoral artery exposed. Stabilized thorium dioxide sol was injected directly into this artery, but, peculiarly, arteriograms did not reveal the shadows of more than a few vessels in the upper thigh. The films did not reveal evidence of osteomyelitis of the foot. On May 21 resection of about 2 cm. of the left dorsalis pedis artery was performed for study. This vessel was completely occluded.

By June 13, 1936, the whole right foot had become gangrenous, especially the third, fourth and fifth toes, and the adjacent dorsum of the foot. The temperature had been ranging from 99° F. to 103° F. The hemoglobin had dropped from 80 to 65 per cent. The leucocyte count was still very high, being 26,000 per cubic millimeter of blood with 79 per cent polymorphonuclear neutrophiles and 10 per cent band forms. Amputation was performed at the junction of the upper and middle thirds of the right leg. A tourniquet was not necessary, there being practically no bleeding. Following operation the stump became secondarily infected. The temperature was only slightly elevated, however, thereafter. On July 30, 1936, the patient's general condition was good, but the tibia was exposed in the stump and pus was exuding from the wound. The incisions in the left thigh and foot had

healed promptly and completely. Antisyphilitic treatment was being employed. A secondary amputation of the infected stump about 2 inches higher was performed on August 4, and was followed by healing. The patient left the hospital in good condition on Sept. 2, 1936.

Pathological Study.—Sections were made at short intervals of the portion of the dorsalis pedis artery of the left (nongangrenous) foot, which portion was about 1.5 cm. long, and stained with hematoxylin and eosin, Masson's trichrome stain, van Gieson's connective tissue stain, and acid orcein. All sections showed the lumen of the artery to be filled with fibrous tissue. In some, the obturating tissue contained one or two large irregular endothelium-lined spaces or canals. There were practically no other vessels. A few small collections of hemosiderin granules were

Fig. 8.—Case 3. Cross-section of anterior tibial artery, showing lumen occluded with cellular fibrous tissue containing several endothelium-lined canals; internal elastic lamina almost intact; media fibrotic, with dissolution of muscle fibers. Masson's trichrome stain. (×50.)

present. In one section the lumen was completely closed by cellular fibrous tissue. The hyalinized intima merged imperceptibly with the obturating tissue. There was a large amount of delicate elastic tissue in the obturating tissue, most dense about the new channels. The internal elastic lamina was intact in most of its extent but split into a few layers. A small mass of calcium was present in the subintimal region of one section. The media was irregular in thickness; the muscle fibers were somewhat disorganized; and there was a slight increase in connective tissue. The media was not vascular, however; and there were no inflammatory cells. The adventitia and surrounding connective tissue were densely fibrosed and contained more elastic tissue than normally.

Microscopic sections were also made at various levels of the tibial arteries and veins of the amputated (right) leg. All sections of the anterior tibial artery showed the lumen obliterated by fibrous tissue but containing a number of large, irregular endothelium-lined canals (Fig. 8). The few other vessels present therein were of capillary or precapillary size. The obturating tissue was quite cellular and contained a few small clumps of hemosiderin. The internal elastic lamina was for the most part intact. The media was moderately fibrotic and in some sections slightly vascular. In other respects also this artery resembled essentially the dorsalis pedis

Fig. 9.—Case 3. Cross-section of lower portion of posterior tibial artery and veins. Artery (left middle) not occluded but intima thickened and muscle fibers of media fragmented. Large vena comites (upper right) shows intimal proliferation, organized mural thrombus and media very thin in patches. Small vena comites (below) shows marked proliferation of intima. Masson's trichrome stain. (×5.)

artery of the left foot. The veins in many of the sections were greatly altered, in others relatively little. The main feature was an intimal fibroblastic and angioblastic proliferation, very variable in thickness and distorting considerably both the lumen and the media. This tissue contained a fair number of capillaries. In the larger veins there were wavy projections of this abnormal tissue into and across the lumen, forming endothelium-lined canals of various sizes and shapes. The media in some veins was considerably disrupted and somewhat fibrotic but not inflamed. In some of the smaller veins there was a rim of proliferating intimal tissue within the

lumen. The intervascular connective tissue was dense and fibrotic. In one section there was a small abscess with many polymorphonuclear neutrophiles in this connective tissue and diffusely scattered lymphocytes and histiocytes.

The lesions of the upper portion of the posterior tibial artery were quite similar to those of the anterior. The endothelium-lined canals were longer, thinner, and more definitely branching. The lumen in the middle and lower portions of the artery, however, was not occluded by fibrous tissue, but was narrow and was slightly encroached upon by a thin rim of variable thickness of fibrotic proliferating intimal

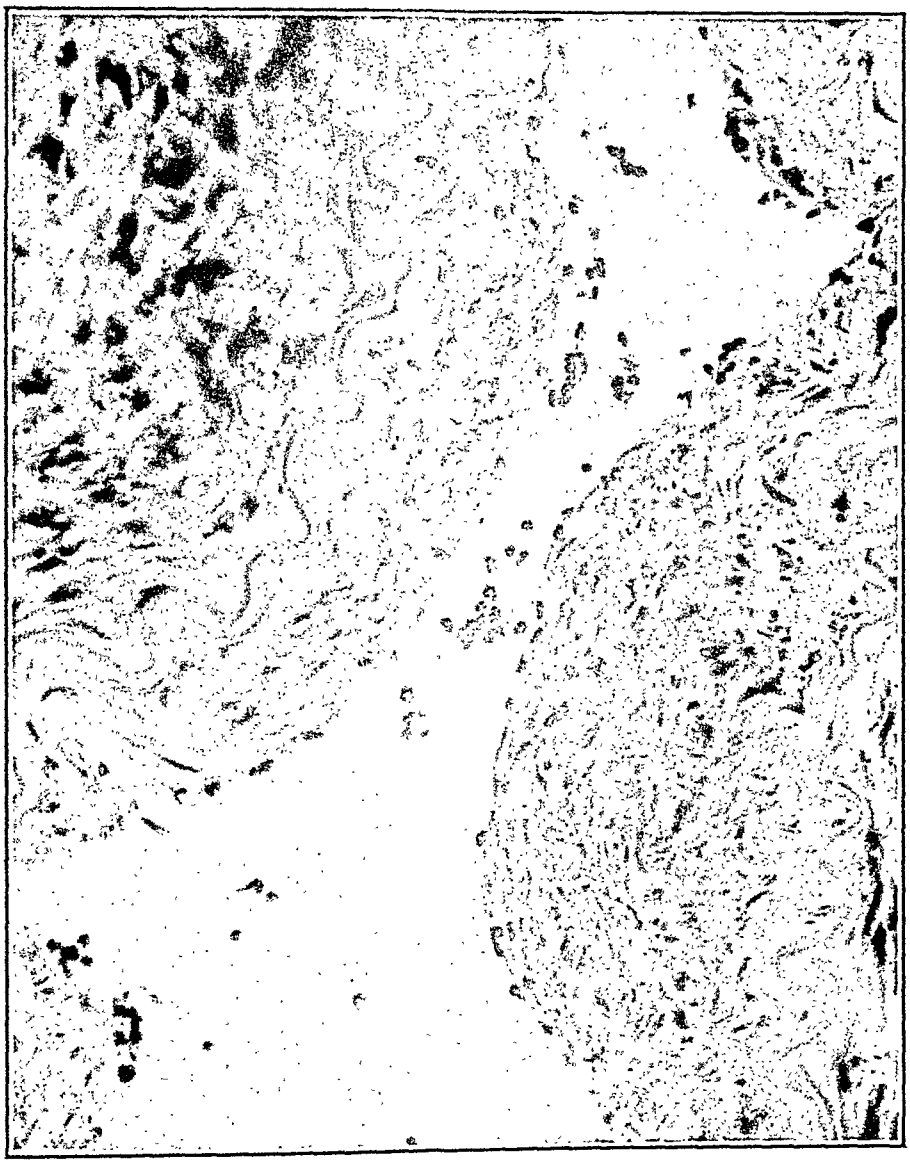

Fig. 10.—Case 3.—Cross-section of portion of wall and lumen of lower part of posterior tibial artery, showing fibroblastic proliferation of intima and fragmentation of muscle fibers of media. Masson's trichrome stain. (×350.)

tissue (Figs. 9 and 10). The media was moderately fibrotic, and the muscle fibers were greatly fragmented. The venae comites of the posterior tibial artery were found to be affected in all of the sections. The larger veins showed jagged or smooth projections of proliferating intimal tissue into, and at times even across, the lumen, often with organized thrombi adherent to these vegetations (Figs. 9 and 11). In some of the large veins these thrombi were very irregular in shape; in others they formed long, smoothly outlined, tonguelike or fingerlike processes projecting into the lumen from a relatively small base. The free edges of these thrombi were covered with endothelium. None of the veins was completely occluded. The media

was irregular in thickness and practically absent in certain areas. The smaller veins did not contain thrombi of any size, but there was often a thick rim of proliferated endothelium partially occluding the lumen (Figs. 9 and 12). Lymphocytes and leucocytes were practically absent in most of the sections. In some, however, there were a few scattered lymphocytes, some free erythrocytes, and a few histiocytes in the perivascular connective tissue. In one section there were many thin-walled blood vessels in this tissue.

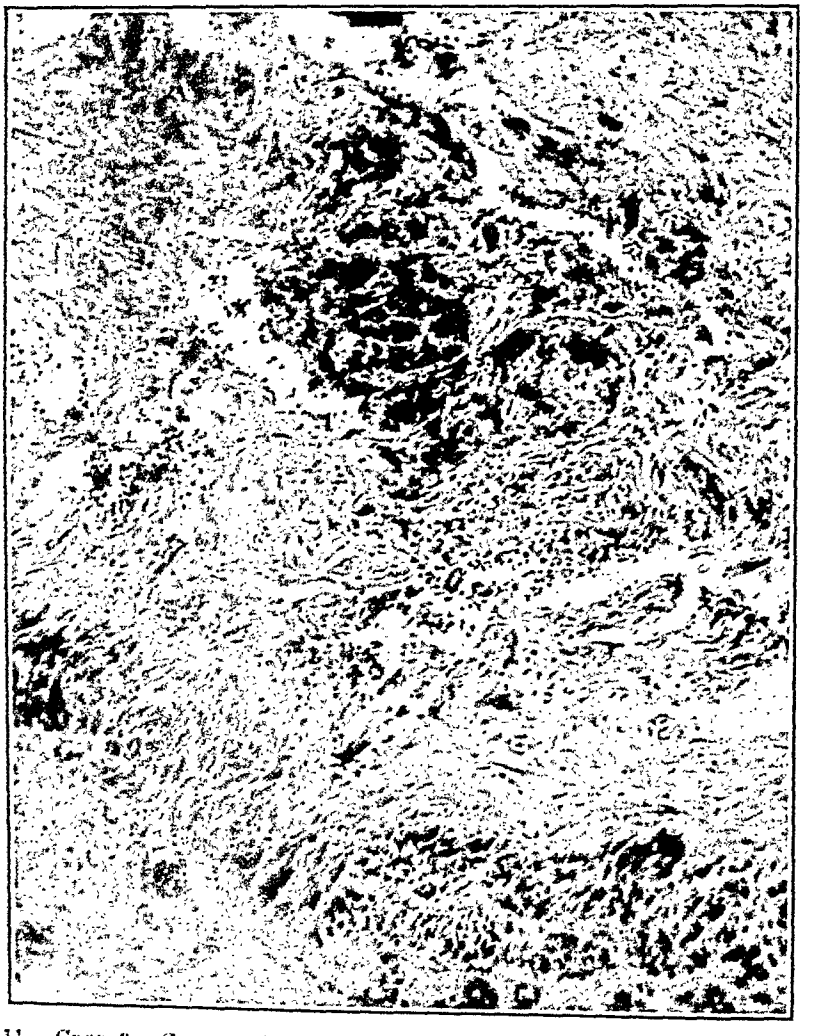

Fig. 11.—Case 3. Cross-section of portion of lower part of large posterior tibial vein, showing fibroblastic and angioblastic proliferation of intima with focal thrombosis; adjacent connective tissue (below) more than normally vascular. Masson's trichrome stain. (×165.)

Summary of Case 3.—A syphilitic negro aged thirty-six years, developed gangrene of the right foot following incision and drainage of a right ischiorectal abscess. Pulsations were not present in either lower extremity below Scarpa's triangle. The right leg was amputated below the knee, and healing occurred after reamputation 2 inches higher. A study of the vessels of the amputated limb and of a resected portion of the left dorsalis pedis artery revealed chronic obliterative vascular disease. The lumina of most of the arteries were filled with fibrous tissue containing endothelium-lined canals and blood vessels. The media in most of the sections was moderately fibrotic and somewhat vascular. The veins for the most part were greatly

altered by endothelial proliferation and incompletely occluded by organized clot. The intervascular connective tissue was densely fibrotic and contained some lymphocytes and at one point a small abscess.

CASE 4.—*Clinical History.*—J. F., an apparently full-blooded negro servant aged thirty-two years, was admitted to the Gallinger Municipal Hospital on April 28, 1936, complaining of a "sore" on the right first toe. His general health had been good. He had had influenza in 1917. About 1924 he had had a penile chancre and a positive blood Wassermann reaction, for which he had received treatment. Blood tests since then had been negative. Eight years before he had had "sores" on the heel of the left foot, and healing was slow at that time when several ingrown

Fig. 12.—Case 3. Cross-section of small vein accompanying lower part of posterior tibial artery. Intima greatly thickened with vascularized fibroblastic tissue; projecting into lumen, a round angioblastic body. Masson's trichrome stain. (×83.)

toenails were removed. For a year he had had severe pain in the calves of both legs when walking. Lately he could walk only a block or two without pain. Four months before admission he had had a "sore" at the base of the right fifth toe which had healed slowly. Three months before he had had an ingrown toenail partially removed from the right first toe, and healing had not occurred. Calluses had formed on the balls of the feet, and the toenails required cutting less often than formerly. Tingling in the feet had been noted, especially after standing. The arms "went to sleep" easily. The patient had smoked about twenty cigarets daily since the age of ten years.

Examination revealed a well-developed and well-nourished negro, apparently normal except for the lower extremities. An infected, granulating surface was present where the portion of toenail of the right first toe had been removed. Pulsations were practically absent in both popliteal arteries. They could not be felt in either dorsalis pedis or posterior tibial artery. When the feet were elevated, the sole of the right foot became definitely pale, and, when lowered, both feet became erythematous. Both procedures caused pain in the feet. The temperature of the skin of the right foot was definitely lower than that of the left. The oscillometric curves were almost flat in both thighs and legs. The blood pressure in the arms was 130 systolic and 80 diastolic. The Kahn test of the blood was negative.

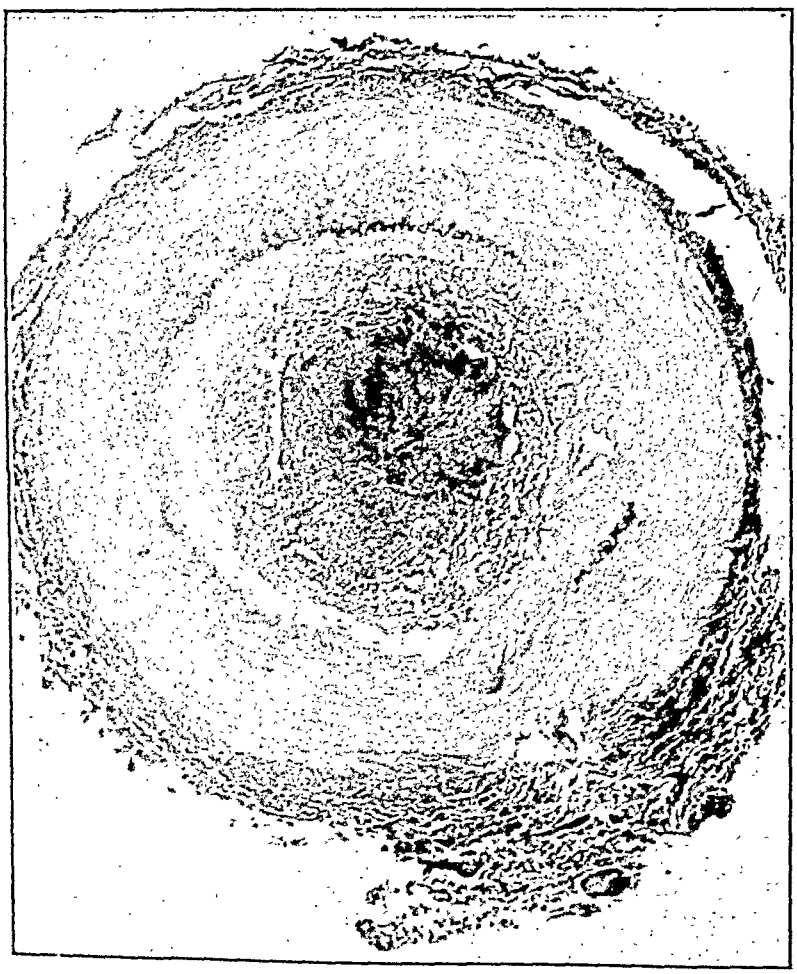

Fig. 13.—Case 4. Cross-section of dorsalis pedis artery (biopsy specimen), showing lumen occluded with dense fibrous tissue containing a small endothelium-lined canal and numerous small blood vessels; internal elastic lamina absent in places; media fibrotic; surrounding connective tissue densely fibrotic. Masson's trichrome stain. (×35.)

Urinalysis was normal. The hemoglobin was 80 per cent, and the leucocytes numbered 10,000 per cubic millimeter of blood. The oral temperature was normal.

Arteriograms made with stabilized thorium dioxide sol were definitely those produced by thromboangiitis obliterans, the main arteries being practically entirely occluded from the popliteal fossae down. Long, corkscrew-like vessels were present in the legs.

On May 25, 1936, a portion of the occluded left dorsalis pedis artery about 2 cm. long was resected for study. On July 1 the remainder of the right big toenail was removed.

In spite of various forms of treatment, including intravenous injections of typhoid vaccine and of hypertonic saline solution, the heat cradle, Buerger's exercises, and antisyphilitic medication, the lesion on the right big toe became progressively worse, until by July 30, 1936, the bone of the distal phalanx was exposed in the base of a deep ulcer involving the distal half of the toe. The whole foot was greatly swollen and very painful, but there was no other evidence of gangrene. The pain was relieved temporarily by the use of typhoid vaccine intravenously, and latterly it had ameliorated to some degree spontaneously, although the foot had to be kept dependent at all times. The left foot was also considerably swollen, and the incision on the dorsum had opened and become infected. This lesion was now granulating over. The oral temperature had been normal except for a few small elevations. By December both feet were entirely healed, and the patient could walk.

Microscopic Study of the Left Dorsalis Pedis Artery.—The portion of dorsalis pedis artery resected was studied as in Case 1. The lumen was completely occluded by fibrous tissue containing a moderate number of small blood vessels and in some sections a small endothelium-lined canal (Fig. 13). The obturating tissue was densest in the center of the occluded lumen. The internal elastic lamina was intact except in a few small areas but was split into several layers. The media was slightly fibrotic and contained some abnormal elastic tissue but no new blood vessels or inflammatory cells. The adventitia and immediately surrounding connective tissue were dense. No veins were present in the sections. Dr. Langenstrass did not find any spirochetes by means of special staining methods.

Summary of Case 4.—A negro, aged thirty-two years, who had had syphilis but whose Kahn test of the blood was negative, had had trouble with his left foot eight years before and intermittent claudication of both legs for a year. An ulcer developed on the dorsum of the right big toe following partial removal of an ingrown toenail. Pulsations were absent in the vessels of both legs, and arteriograms revealed evidence of severe occlusive vascular disease. A biopsy of the left dorsalis pedis artery showed the lumen completely occluded by fibrous tissue and other changes similar to those of the end stage of thromboangiitis obliterans. The ulceration of the right big toe progressed for several weeks and then began to heal slowly. After several months the lesion was completely healed.

CASE 5.—*Clinical History.*—N. B., a thirty-year-old, full-blooded negro, entered Georgetown University Hospital on Sept. 10, 1936, complaining of a "sore toe" of the right foot of three week's duration. While working as a laborer, he had first noticed, one year before, intermittent swelling, coldness, and numbness of his right foot and occasionally of the left, especially at night. After a short time he had begun to have sharp pains in the calves of his legs during exercise, developing in the left leg after they had been present for some time in the right. About three weeks before admission, he had noticed continued swelling of the distal half of his right foot, especially the third toe, which became very painful and throbbing. In a few days a superficial ulcer developed on the distal phalanx of the third toe from which blood-streaked pus was discharged. Bathing the foot at home with a solution of Epsom salts and the local application of various home remedies failed to improve the ulcer. He was a very moderate smoker.

Examination revealed a rather poorly nourished, black-skinned negro with slightly palpable superficial lymph nodes, severe pyorrhea, many carious teeth, and a faint systolic precordial murmur. The blood pressure was 145 systolic and 100 diastolic. The upper extremities were normal, and the vessels pulsated normally. There was a superficial ulcer on the third toe of the right foot, which was discharging a little purulent material. No arterial pulsations were palpable in the right lower

extremity below Scarpa's triangle, and even the pulsation of the first part of the femoral artery was relatively weak. In the left lower extremity the femoral and popliteal arteries were palpable, but the pulsations were slightly reduced in intensity; a faint pulsation was palpable in the posterior tibial artery, but the dorsalis pedis could not be felt. There was no evidence of superficial phlebitis. Oscillometric examination showed moderately diminished amplitude of oscillations and height of the curve. Urinalysis and hemogram were essentially normal. Wassermann and Kahn tests of the blood were four-plus. The oral temperature was normal except when typhoid vaccine was injected intravenously, as it was every few days. The pulse rate varied between 80 and 90 beats per minute most of the time.

Arteriograms were made of both lower extremities by means of thorotrast. Those of the right showed evidence of partial occlusion of the femoral artery in Hunter's canal with numerous collateral vessels in the vicinity. Below this point the femoral and popliteal arteries appeared normal, but the anterior tibial artery was completely obliterated from its middle third down, and the posterior tibial artery presented uneven walls in its upper half, an indirect course and a narrow lumen in its lower half. The collateral vessels in the leg were very fine but not numerous. The arteriograms of the left lower extremity showed normal vascular shadows down to the tibial arteries, both of which had greatly narrowed lumens throughout their course.

An incision was made over the left dorsalis pedis artery, and a portion of that vessel, which was occluded, was removed for examination.

Continuous heating of the legs and feet to 105° F., Buerger's exercises, warm saline soaks, injections of typhoid vaccine, and antisyphilitic treatment were instituted. About one month after admission the ulceration of the toe was completely healed. The surgical incision for the biopsy healed at about the normal rate.

Microscopic Study of the Left Dorsalis Pedis Artery.—The portion of dorsalis pedis artery resected was studied as in Cases 1 and 4. In this case, however, the veins and nerve were included in the sections. The lumen of the artery was completely occluded by very cellular and very vascular connective tissue, undoubtedly the result of organization of a thrombus. The vessels were of arteriolar, precapillary and capillary size. Some small clumps of hemosiderin were present in the center of the obturated lumen. No endothelium-lined canals were present. The internal elastic lamina was wavy and intact. The media was more vascular than normal and moderately fibrotic. The connective tissue surrounding the artery was much thicker and more vascular than normal. Artery, veins, and nerve were matted together. Some small arteries and arterioles near the dorsalis pedis artery also had practically completely occluded lumina. A direct branch was completely occluded. The largest vein showed subintimal fibroblastic proliferation and wavy connective tissue septums in the lumen dividing it into a number of large, irregular and branching, endothelium-lined spaces. The nerve was moderately degenerated, as were the nerves in Cases 2 and 3.

Summary of Case 5.—A negro aged thirty years had had intermittent claudication for a year with coldness and numbness of the feet. A very painful, superficial ulceration of a toe brought him to the hospital after three weeks. Of the vessels of the feet only the posterior tibial artery of the opposite foot was felt to pulsate. Arteriograms showed evidence of occlusive vascular disease mainly of the tibial arteries of both legs. A biopsy of the dorsalis pedis vessel of the nonulcerated foot showed the lumen of the artery occluded by very vascular fibrous tissue. The largest vein was quite pathological. The patient's blood Wassermann and Kahn tests were strongly positive. Complete healing of the ulcer and the biopsy wound occurred in a few weeks under treatment.

DISCUSSION

Several important questions arise in connection with these five cases of peripheral vascular disease in negroes: 1. Do they conform to the clinical and pathological criteria of thromboangiitis obliterans, or Buerger's disease? 2. Are the patients full-blooded negroes? 3. May the cases not be instances of syphilitic vascular disease of the extremities?

The clinical correlation of these cases with cases of thromboangiitis obliterans occurring in Caucasians is not so great as are the pathological similarities. Nevertheless, the clinical histories are not incompatible with the diagnosis of that disease. All five patients were smokers, two of them more than moderate addicts of this habit. All were relatively young men. The history was one of chronic peripheral vascular disease in Cases 1, 4, and 5. Typical intermittent claudication occurred in two cases (Cases 4 and 5). The onset was acute in Case 3, suggesting embolism, but was undoubtedly due to acute thrombosis superimposed upon asymptomatic, bilateral occlusive vascular disease. Gangrene of a toe was the first indication of such disease in Case 2. Evidence of old superficial phlebitis was present in Case 1. The cause for the episodes of gangrene was unexplained in Case 1; gangrene was thought to be provoked by cold weather in Case 2; the opening of an abscess immediately preceded the sudden onset of gangrene in Case 3; and partial removal of an ingrown toenail inaugurated superficial gangrene of that toe in Case 4. The gangrene in Case 1 was intermittent and bilateral; in Case 2 it was subchronic and unilateral; in Case 3 it was acute and unilateral; in Case 4 it was subchronic and bilateral, the gangrene in one foot being due to a surgical incision; and in Case 5 it was subacute and unilateral. Trophic changes were present in the fingers in Case 1. Buerger[2] and Brown, Allen and Mahorner[3] have described cases of thromboangiitis obliterans in Caucasians presenting histories quite similar to those of these five cases.

Physical examination gave incontrovertible evidence of bilateral and extensive occlusive vascular disease in the lower extremities in all five cases. Color changes are not easy to distinguish in negroes and were not prominent. The satisfactory arteriograms were typical of thromboangiitis obliterans as seen in the white race, and the oscillometric studies in two cases confirmed the closure of all large arteries bilaterally. The nature of the gangrene in all cases was similar to that seen in thromboangiitis obliterans.

Pathologically, all five cases were typical examples of the advanced stage of this disease. In three cases the veins were affected as well as the arteries. In the other two cases the dorsalis pedis artery only was studied by means of biopsy of this vessel. None of the lesions was in the active stage of the disease. All students of thromboangiitis

obliterans have commented upon the difficulty of obtaining vessels for study in this stage. Giant cells and purulent foci so characteristic of the acute stage as pointed out by Buerger[2] were consequently not seen in the sections in any of the cases. The lesions in the arteries were more suggestive of panarteritis than simple inflammation of the intima.

The five patients were dark-skinned negroes. Their parents were all negroes. Four were certain they were full-blooded negroes, but one thought that possibly in a remote generation there had been some admixture of Caucasian blood.

Syphilis has been excluded as a prominent or specific cause of Buerger's disease. All five patients undoubtedly had, or had had, syphilis, but the incidence of this disease in negroes is so high that the association of the two conditions may have been purely accidental. However, since the etiology of thromboangiitis obliterans is unknown, it is possible that it is nonspecific and that in susceptible individuals various organisms might cause the condition. Although special studies did not reveal the spirochete, its absence is not sufficient to eliminate it as the pathogenic organism in the healed stage of vascular disease represented.

Whether the form of vascular disease present in these five cases is ever due to syphilis is, however, doubtful, although Warthin[4] believed firmly in such a relationship. A perusal of such careful studies as those made by Druelle[5] and by Letulle, Heitz, and Magniel[6] leaves one skeptical of any definite connection between syphilis and peripheral vascular disease. Herrmann[7] feels that syphilitic disease of the peripheral arteries is not uncommon, but in the three cases he described pathological studies were not made. In the case of Smith and Patterson[8] the patient had syphilis, but the lesions of the vessels were those of thromboangiitis obliterans and were not suggestive of syphilitic arteritis. Certainly, in the five cases here reported the lesions are not suggestive of syphilis. However, it is conceivable that in susceptible individuals the toxins of the spirochete might produce such vascular lesions or even that the end stage of actual spirochetal invasion might present such a pathological picture. Pathologists do not recognize lesions of the medium-sized arteries as being due to syphilis, although syphilis of the large and the small arteries is well known (Conner[9]).

SUMMARY AND CONCLUSIONS

1. Five cases of peripheral vascular disease in negroes studied clinically and pathologically are reported as being instances of thromboangiitis obliterans, or Buerger's disease.

2. Pathologically proved cases of this disease in the negro have not previously been reported.

3. All five patients also had, or had had, syphilis, and the possible etiological connection is discussed.

4. Buerger's disease among negroes may not be so rare as has been supposed.

Photomicrographs used to illustrate this paper were made at the Army Medical Museum, Washington, D. C., by Mr. Roy M. Reeve.

REFERENCES

1. Gemmill, W. F.: Thrombo-Angiitis Obliterans; Report of a Case Occurring in a Negro, Atlantic M. J. 24: 244, 1925-1926.
2. Buerger, L.: The Circulatory Disturbances of the Extremities, Philadelphia, 1924, W. B. Saunders Co.
3. Brown, G. E., Allen, E. V., and Mahorner, H. R.: Thrombo-Angiitis Obliterans. Clinical, Physiologic and Pathologic Studies, Philadelphia, 1928, W. B. Saunders Co.
4. Warthin, A. S.: Syphilis of the Medium and Smaller Arteries, New York M. J. 115: 115, 1922.
5. Druelle, M.: La gangrène des membres par artérite syphilitique, Paris Theses, 1905-1906.
6. Letulle, M., Heitz, J., and Magniel, M.: Claudication intermittente chez un syphilitique avec lésions de l'aorte, des iliaques, et des artères des membres inférieurs, Arch. d. mal. du coeur 18: 497, 1925.
7. Herrmann, L. G.: Syphilitic Peripheral Vascular Diseases: Treatment by Means of Intermittent Negative Pressure Environment, Am. J. Syph. 17: 305, 1933.
8. Smith, R. P., and Patterson, D. W.: Thrombo-Angiitis Obliterans in Association With Syphilis, Brit. M. J. 1: 227, 1927.
9. Conner, L. A.: Development of Knowledge Concerning Rôle of Syphilis in Cardiovascular Disease, J. A. M. A. 102: 575, 1934.

THE HEART FIFTEEN TO TWENTY YEARS AFTER SEVERE DIPHTHERIA*†

WILLIAM PAUL THOMPSON, M.D., SHERMAN E. GOLDEN, M.D., AND PAUL D. WHITE, M.D.
BOSTON, MASS.

IT IS well known to those familiar with the course of severe diphtheria that in this disease the heart sometimes suffers seriously and that actual heart failure may be the immediate cause of death, because of the damage to the myocardium and conduction system occurring in the second or third week or after convalescence has begun. When the heart is involved, various manifestations arise, among them restlessness, apathy, abdominal pain, vomiting, pallor, cyanosis, dilatation of the heart, dyspnea, gallop rhythm, engorgement of the liver, congestive heart failure, tachycardia, bradycardia, premature beats, and various grades of auriculoventricular and intraventricular block. Auricular fibrillation has also been described.[1]

The development of conduction disturbances during diphtheria has come to be regarded as a serious sign, pointing to an unfavorable outcome, although there are now a number of cases on record in which there seems to be no reasonable doubt that conduction disturbances have persisted for a year or two after recovery from diphtheria, and there are a few cases in which these changes have been permanent.

The present study is concerned with the *development* of conduction disturbances some years after the diphtheria has passed, a subject that is controversial and about which little has been written. McCulloch[2] wrote in 1920 that he believed diphtheria may play an important rôle in the development of chronic heart disease years after the diphtheria, but in support of his belief he presented no evidence. In 1927 Jones and White[3] published the results of their study of 100 young people who had had severe or moderately severe diphtheria five to eight years preceding their examination. They found neither clinical nor electrocardiographic evidence of heart disease or conduction disturbances in any of their subjects. In 1930 Butler and Levine[4] published their findings in 20 cases of auriculoventricular block, 14 of them complete, in which none of the usual causes for such disturbance was apparent (rheumatic infection, digitalis, coronary disease). They found past histories of diphtheria in half of these cases, while only 6 per cent of 600 consecutive surgical patients gave histories of diphtheria. They did not comment on the time relationship between the diphtheria and

*From the Cardiac Laboratory of the Massachusetts General Hospital.
†Read in abstract before the New England Heart Association, Boston, Nov. 9, 1936.

the development of the block, but assumed that it had been a late occurrence, and concluded that diphtheria was probably the cause. Other than these papers, we have discovered no references to the development of conduction disturbances years after diphtheria.

The present study is concerned with the same patients examined by Jones and White, 94 of whom we have been able to follow ten years after the previous study, and from fifteen to twenty years after the diphtheria. This group forms an ideal basis for the present study, inasmuch as we know that they did not have heart disease or conduction disturbances ten years ago. If conduction disturbances are to develop as the result of the diphtheria, it seems reasonable to expect to find them now, after this additional period of time. Furthermore, this is an ideal time to study this group, for if more time is allowed to pass, coronary disease developing with increasing age may influence both auriculoventricular and intraventricular conduction.

Among the original 100 individuals, we have been unable to locate 6; 2 are known to be dead (one of rheumatic heart disease developed subsequent to the previous examination, and one of pneumonia); one is well according to his own statement, and 91* have been reexamined. The 91 persons whom we have reexamined are now from sixteen to forty-six years of age (one is sixteen years old, 8 are seventeen, 9 are eighteen, 11 are nineteen, 9 are twenty, 12 are twenty-one, 11 are twenty-two, 6 are twenty-three, 2 are twenty-four, 3 are twenty-five, 5 are twenty-six, one is twenty-seven, 2 are twenty-eight, 3 are thirty, 1 is thirty-one, 1 is thirty-two, 1 is thirty-three, 1 is forty-two, 2 are forty-three, 1 is forty-four, and 1 is forty-six years old). The time that has elapsed since the diphtheria varies between fifteen and twenty-one years (fifteen years have elapsed in 31 cases, sixteen years in 36, seventeen years in 3, eighteen years in 15, nineteen years in 3, and twenty-one years in one). Of these 91 persons, 64 had had severe diphtheria, and 27, moderately severe diphtheria. All of them had been patients at the South Department of the Boston City Hospital, and the diphtheria in all had been proved both by culture and by clinical course. They were all young people at the time of the diphtheria, only 15 having been more than fifteen years of age. All but 7 of the patients severely ill received 24,000 units or more of antitoxin, most of them having required 36,000 units or more. Those with moderately severe illness received from 12,000 to 24,000 units. Twelve of the severe cases had been diagnosed "myocarditis" at the time of the diphtheria, and many others gave some evidence of cardiac abnormality. The basis of the diagnosis of myocarditis varied and was not always clear, for the descriptions of the findings included weak, muffled, split, or reduplicated heart sounds,

*Our thanks are due to Dr. Gerald Flaum of the Third Medical Division at Bellevue Hospital, New York, N. Y., who kindly examined one of the patients and obtained an electrocardiogram for us.

gallop rhythm, systolic murmurs, premature beats, and apparent enlargement of the heart. At any rate, all of the 64 severely ill patients ran toxic courses. Sixteen required intubation and 19 had some form of paralysis. The second group of 27 patients with moderately severe cases ran less serious courses, but they had almost as many functional heart findings.

The follow-up study of Jones and White, conducted five to eight years after the diphtheria, included an after-history, a thorough examination, and an electrocardiogram in each case. No clinical or electrocardiographic evidence of heart disease or heart-block was noted in any individual.

We have conducted our present study along the same plan as that followed by Jones and White but have added fluoroscopic examination and orthodiagraphic measurement of the heart. The present findings in the 91 patients reexamined are as follows:

History.—Two patients gave histories of rheumatic fever which had occurred during the interval following the previous examination. Another gave a history of hypertension which had been subsequently discovered and of hemiplegia lasting a few days. A fourth gave a history of toxemia of pregnancy followed by permanent hypertension. Other than these, all patients had remained essentially well and gave no histories suggesting heart disease.

Examination.—1. Size of Heart: Only one heart was enlarged, either clinically or by fluoroscopic examination. This one instance was in a girl with rheumatic aortic and mitral valve deformity.

2. Heart Rhythm: The only irregularities found were rare premature beats in six instances and sinus arrhythmia in 52 (5 patients showed both).

3. Heart Murmurs: Two patients had the murmurs and other findings of rheumatic valvular disease (one of mitral stenosis and the other of mitral stenosis and aortic regurgitation). There were no others with diastolic murmurs. Forty patients had functional systolic murmurs, of which 18 had been present also at the time of the previous examination. These murmurs were usually located in the pulmonary valve area or were maximal there, and they were usually heard only when the patient was recumbent. Most of them disappeared entirely on deep inspiration or were markedly diminished in intensity by this procedure. In twelve cases in which murmurs were not heard, functional systolic murmurs had been described ten years before.

4. Heart Sounds: As at the time of the previous examination, no weak or muffled sounds were heard, and none were obscured by murmurs. Physiological third heart sounds were heard in 23 patients in their recent examinations; in 8 of these they had been heard ten years before as well. Third sounds were not heard in 19 of those in whom they had been heard before.

5. Blood Pressure: The blood pressure was normal in all but 2 patients. Both of these had hypertension which had developed since the previous examination, and are the ones referred to above.

6. Electrocardiographic Records: In three instances the P-R interval was as long as 0.2 sec. In one of these there has been no change since the previous examination. In two there has been an increase in this length from previous measurements of 0.15 and 0.16 sec., respectively.

In four instances the QRS complexes do not appear to be wholly normal in that they are either at the upper limit of normal in width (0.1 sec.) or are slightly greater than this width. This finding is suggestive of some disturbance in intraventricular conduction because of the prominent or slurred S-waves which are present in Lead II in each instance (sometimes also in Leads I or III). It is particularly significant, however, that in only 2 cases does there appear to be any increase in this width as compared to that of ten years before, and even then the increase is very slight. This possible error in the previous report we now wish to note, although even today the electrocardiograms are still only on the borderline between normal and abnormal. The three cases with P-R intervals of full length and the four with rather wide QRS complexes will be discussed in more detail subsequently.

7. Fluoroscopy and Orthodiagraphy: As mentioned under "Heart Size," the heart was abnormal in size or shape in only one case.

In addition to these 91 individuals, 9 more, not included in the follow-up ten years ago, have been added, so that the present total is again one hundred. These had diphtheria at the same time as the rest of the series, and were also patients at the Boston City Hospital. They are now from nineteen to thirty-one years of age (one is nineteen years old, two each are twenty and twenty-two years old, and one each twenty-one, twenty-five, twenty-seven, and thirty-one years old). These cases were similar to our original group in severity of the infection, and a similar time has elapsed since the diphtheria. Among them, the heart is entirely normal in all cases, and there are no electrocardiographic abnormalities.

SPECIAL CASES

Group 1 (P-R Interval Measuring 0.2 Sec.)

CASE 1A.—This patient, a boy, was admitted to the South Department of the Boston City Hospital in October, 1920, at the age of two years, the day following the onset of severe faucial diphtheria. He received 60,000 units of antitoxin. There were no abnormal heart findings. In July, 1926, at the age of seven years, he was severe pain in both ankles lasting thirty-six hours, but there had been no swelling and no other indications of rheumatic infection. The heart was found to be normal. examined by Jones and White. He gave the history that one year earlier he had had

In January, 1936, when he was seen for the present follow-up, he gave no further history suggesting rheumatic infection. The heart was not enlarged. There was a faint systolic murmur at the apex and a moderate one at the pulmonary valve area, both almost entirely dispelled by deep inspiration. The electrocardiograms taken in 1926 and in 1936 are shown in Fig. 1*A*. In the first the P-R interval is about 0.19 to 0.2 sec. in length, and in the latter one 0.2. It is conceivable that the length of the P-R interval and the murmurs in this case are due to a minimal degree of rheumatic heart disease, but, regardless of the cause, there is no evidence of progressive change during the time between the two electrocardiograms.

CASE 1B.—This patient is a girl who was admitted to the South Department in June, 1920, at the age of six years, two days after the onset of severe faucial diphtheria; 36,000 units of antitoxin were given. There was questionable slight enlargement of the heart; the heart sounds were good; there was a systolic murmur at the apex transmitted upward and, at times, slight irregularity of the heart. A palatal paralysis occurred. In June, 1926, at the age of twelve years, she was seen by Jones and White, who found the heart entirely normal and noted the presence of no murmurs. In February, 1936, at the age of twenty-two years, she gave a history of good health in herself, but reported the occurrence of rheumatic fever in a sister. On examination the heart was normal in size. There was a rough systolic murmur of slight intensity at the pulmonary valve area, largely dispelled by inspiration. At the apex a somewhat louder systolic murmur was heard, not increased by exercise, but there was no diastolic murmur. The electrocardiograms are shown in Fig. 1*B*. In the first the P-R interval is 0.156 sec. in length, and in the second 0.2. It is impossible to state the cause of this increase in the length of the P-R interval, but in a person with a systolic murmur not present before and with a family history of rheumatic fever, it cannot fairly be attributed to a progressive change resulting from the diphtheria.

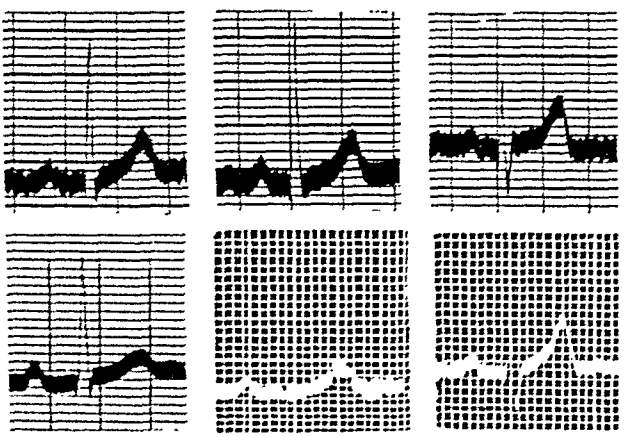

Fig. 1*A*. Fig. 1*B*. Fig. 1*C*.

Fig. 1.—P-R intervals at the upper limit of normal in length. Lead II only is shown in each case. The electrocardiograms shown in the upper row were taken at the time of the previous examination ten years ago, those in the lower row at the time of the present examination.

CASE 1C.—A boy, aged five years, was admitted to the South Department in October, 1920, three days after the onset of severe faucial diphtheria. He was given 70,000 units of antitoxin. There was a faint first heart sound, a faint systolic murmur at the apex, splitting of the second sound at the pulmonary valve area, and, for several days, a pulse as slow as 60 per minute. The size of the heart was normal. A diagnosis of diphtheritic myocarditis was made. In June, 1926, when he was

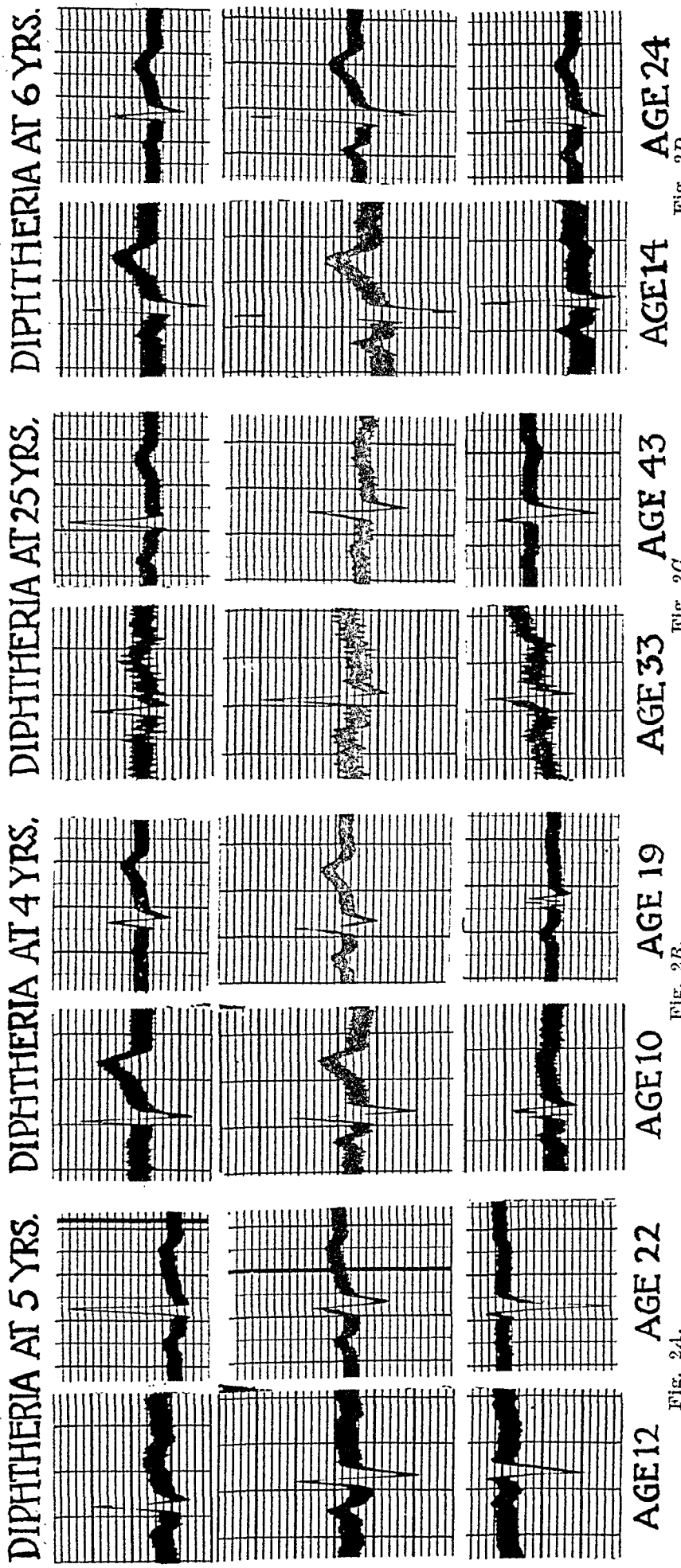

Fig. 2A. Fig. 2B. Fig. 2C. Fig. 2D.

Fig. 2.—QRS complexes of full width. Leads I, II, and III from above downward. Representative complexes from the electrocardiograms taken at the time of the previous examination ten years ago and at the time of the present examination are shown for comparison.

eleven years old, he was seen by Jones and White, who found him to be in good health without heart disease or murmurs. In March, 1936, at the age of twenty years, he was seen for the present follow-up. He reported that he had been well, and no abnormalities were found on examination. The electrocardiograms are shown in Fig. 1*C*. In the first the P-R interval measures 0.15 sec., and in the latter 0.2 sec. It is of interest that in both electrocardiograms there is a slight right axis deviation, in spite of the fact that the patient is rather stocky in build. Although there is no evidence of rheumatic heart disease or rheumatic infection, this change in the P-R interval cannot be unreservedly attributed to diphtheria.

Group 2 (QRS Complexes of Full Width)

CASE 2A.—This patient is a negro girl who had moderately severe faucial diphtheria in October, 1919, at the age of five years. She was admitted to the Boston City Hospital the day after onset and was given 24,000 units of antitoxin. The apex of the heart was found to be 2 cm. outside the midclavicular line, and there was a rough systolic murmur heard best at the apex and transmitted to the axilla. Six weeks later the murmur was described as soft. Two days following that there was no murmur, but the first sound was split. She was then discharged. When she was seen by Jones and White in August, 1926, at the age of twelve years, the heart was entirely normal, and no murmurs were heard. The electrocardiogram taken at that time is shown on the left of Fig. 2*A*. It was reported as normal in the previous paper, but in the light of our present knowledge of the electrocardiogram, it must be looked upon with some doubt. In January, 1936, she was examined again, then at the age of twenty-two years. The findings were entirely normal, and there were no murmurs. The present electrocardiogram, shown on the right of Fig. 2*A*, shows the same rather wide QRS complexes and the prominent S-wave in Lead II.

CASE 2B.—The patient was admitted to the Boston City Hospital in November, 1920, at the age of four years, eight days after the onset of severe faucial and laryngeal diphtheria. She was given 40,000 units of antitoxin and 80 c.c. of convalescent scarlet fever serum. No abnormalities in the heart were described. In December, 1926, at the age of ten years, she was seen by Jones and White, who found the heart normal, but noted a reduplication of the first sound at the apex and of the second sound at the base. The electrocardiogram, Fig. 2*B*, shows QRS complexes of full width and prominent S-waves in both Lead I and Lead II. In December, 1935, at the age of nineteen years, she was seen again. The heart was normal, and the reduplicated sounds of ten years before were not heard. In the present electrocardiogram there is a slight increase in the width of the QRS complexes in Lead II, with increased slurring.

CASE 2C.—A woman of twenty-five years was admitted to the hospital in January, 1918, the day following the onset of severe faucial diphtheria; 48,000 units of antitoxin were given. The heart sounds were good, and there were premature beats and a soft systolic murmur which was not transmitted. The apex of the heart was in the midclavicular line. A diagnosis of diphtheritic myocarditis was made. In June, 1926, Jones and White found her in good health and the heart normal. The electrocardiogram (Fig. 2*C*) shows QRS complexes on the borderline of normal in width. She was seen again in January, 1936, at the age of forty-three years, and was found to be in good health. The intensity of the first sound at the apex was somewhat diminished, and there was a very faint systolic murmur at the apex. The heart was transverse in position and normal in size by fluoroscopy. The electrocardiogram (Fig. 2*C*) shows a slight increase in the width of the QRS complexes, slight slurring of the QRS in Lead II, and a rather prominent S-wave in Lead II. The low T-wave in Lead II and the inverted one in Lead III may be explained on the basis of the rather heavy build of the patient and the transverse position of the heart.

CASE 2D.—The last case is that of a boy who was admitted in May, 1918, at the age of six years, two days after the onset of severe faucial diphtheria. He was given 48,000 units of antitoxin. The heart was normal in size, the sounds were good, and there was a slight apical systolic murmur which disappeared by the time of discharge. When he was seen by Jones and White in April, 1926, he was in good health, and the heart was entirely normal, no murmurs being present. The electrocardiogram (Fig. 2*D*) shows QRS complexes in Lead II of full width and prominent S-waves in Leads I and II. He was seen again in December, 1935, then at the age of twenty-four years. He was well and the heart was normal, without murmurs. The electrocardiogram is essentially unchanged.

SUMMARY AND CONCLUSIONS

Among 100 persons who had severe or moderately severe diphtheria from fifteen to twenty years ago (91 of whom were examined ten years ago as well and reported previously by Jones and White), no clear instance of auriculoventricular or intraventricular block was found. There were three cases with auriculoventricular conduction at the upper limit of normal (P-R interval, 0.2 second) and four cases in which there is a possibility that there may have resulted a slight interference with intraventricular conduction. In two of the three former cases the P-R interval is greater than it was at the time of the previous follow-up examination ten years before, and in the four latter cases the width of the QRS complexes is slightly greater in two cases than it was ten years before, but in no case is true abnormality a certainty. In two of the three cases with P-R intervals of 0.2 second, there was strong suspicion that there had been an intercurrent rheumatic infection. We conclude that, while there are acceptable cases of the development of disturbed conduction during the course of diphtheria and that in very rare cases the disturbance persists permanently, we have as yet no proof that it may develop some years after the illness.*

REFERENCES

1. Parkinson, John: Auricular Fibrillation Following Complete Heart-Block in Diphtheria, Heart 6: 13, 1915.
2. McCulloch, Hugh: Studies on the Effect of Diphtheria on the Heart, Am. J. Dis. Child. 20: 89, 1920.
3. Jones, T. D., and White, P. D.: The Heart After Severe Diphtheria, AM. HEART J. 3: 190, 1927.
4. Butler, S., and Levine, S. A.: Diphtheria as a Cause of Late Heart-Block, AM. HEART J. 5: 592, 1929-30.

*It is planned to reexamine again in ten years the seven special cases noted above.

ELEVATION OF RECTAL TEMPERATURE FOLLOWING MECHANICAL OBSTRUCTION TO THE PERIPHERAL CIRCULATION*

J. MURRAY STEELE, M.D.
NEW YORK, N. Y.

IT HAS been shown that fever accompanying heart failure with congestion may be an integral part of the condition.[1, 2] The evidence presented in support of this statement is as follows: 1. There is frequent close association between the two (fever and heart failure) when diseases known to occasion fever, such as pneumonia, coronary occlusion, or hyperthyroidism, are not found. The closeness of the association is still more clearly shown in two further common experiences. First, fever often subsides abruptly when digitalis is effective in relieving heart failure but is not influenced when it is given to an individual suffering from pneumonia. Second, it disappears when a paroxysm of tachycardia, auricular flutter for example, accompanied by signs of mild heart failure and fever, ceases. 2. When fever accompanies an infectious disease, even in cardiac patients, the weight of the body tends to fall, whereas when fever accompanies uncomplicated heart failure, it increases. 3. In febrile diseases the average surface temperature is higher than normal and falls with fall in rectal temperature. In heart failure it is often lower than normal, but with improvement rises as the rectal temperature falls. A thermal gradient greater than normal has developed during heart failure. Since the distribution of heat within the body depends almost entirely upon the circulation of blood, it follows that failure to convey the usual quantity of heat to the periphery implies failure or slowing of the flow of blood to the surface. This can take place in two ways, either by diversion of flow from the surface (vasoconstriction) or as part of a general decrease in rate of flow. The latter is the usual situation in heart failure.[3, 4]

From these observations it appears that under circumstances in which the peripheral circulation is slow, difficulty develops in distributing heat to the surface of the body where it can be lost. The present study attempts to estimate how great the diminution in peripheral flow must be before rectal temperature becomes elevated. The results show that a relatively short and mild obstruction of the circulation to the extremities is regularly followed by increase of rectal temperature in normal indi-

*From the Hospital of the Rockefeller Institute for Medical Research, New York, N. Y.

viduals and suggest that the rise in heart failure may often depend upon a comparable series of events.

METHODS

The procedure employed in this study follows: The subject was placed in bed in a room in which the temperature could be regulated. A copper constantan thermocouple was attached by adhesive tape to the palm of the right hand; another was attached to the sole of the right foot; and a third, encased in a rubber catheter, was inserted deep (6 to 8 cm.) into the rectum. Blood pressure cuffs were then applied to each extremity just above the knees and elbows. A period of time (approximately an hour), sufficiently long to establish the fact that environmental conditions were such, for the particular subject, that the rectal temperature would

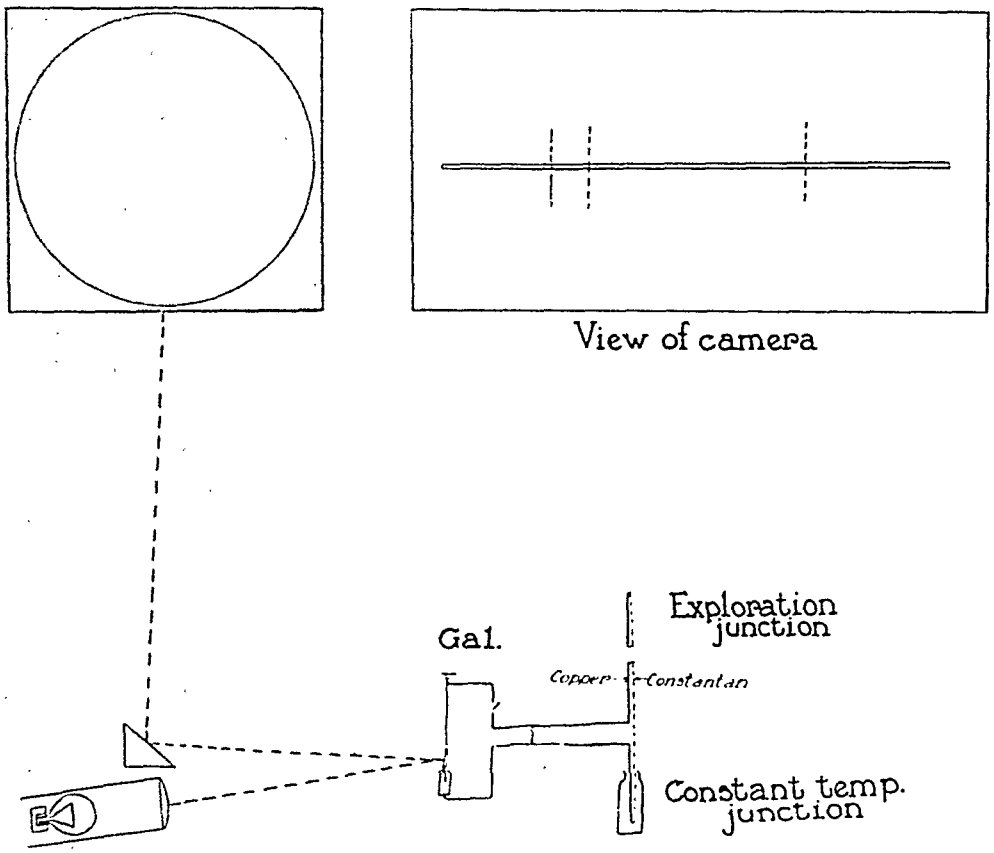

Fig. 1.—A simple diagram of the photographic arrangement is shown in the vertical plane. In the upper right corner is a view of the longitudinal slit in the bottom of the photographic box with the beams of light at right angles to the slit represented by dotted lines. In the left upper corner, the revolving drum is represented as a circle within the square camera box (vertical section).

fall slowly or remain level, was allowed to elapse. The cuffs were then quickly inflated to pressures within from 10 to 20 mm. Hg *below* or *above* diastolic pressure. The range of pressures used extended for the arms from 50 to 95 mm. and for the legs from 75 to 115. Pressure was maintained for from fifteen to forty-five minutes.

Two methods of recording the observations have been used. Thermocouples were connected by suitable switches and resistances to a moving coil suspension galvanometer (Leeds and Northrup, Type R). The deflection of a beam of light was projected from the mirror of the galvanometer through a lens of 1 meter focal length onto a ground glass scale. The beam of light was obtained from a single straight filament bulb (No. G. N. 1019-A, 0.5 amp., 3.5 volts, General Electric Co.). Readings were recorded every two to five minutes and charts were subsequently constructed. Studies carried out in this fashion were begun in 1934.

More recently, the beams of light from the mirrors of three galvanometers (Leeds and Northrup, Type K) have been projected through a slit in an otherwise light-proof metal box onto photographic paper wrapped around an aluminum drum (Fig. 1). The method is simple; a cylindrical lens is not required for the camera.* The photographic paper moves past the slit, which is only 0.5 mm. wide, within such a short distance of it that sufficient definition is obtained. The drum is rotated by a telecron motor coupled to reducing gears allowing, in the present apparatus, three speeds—2, 12 and 50 cm. an hour. To furnish time lines the circuit of an ordinary electric light bulb is completed as often as required by electrical contacts on spindles of appropriate reducing gears driven by the same motor. For convenience in following the progress of an experiment, a part of each beam may be deflected by a mirror onto an ordinary ground glass scale where its deflection is read as desired. Owing to the small changes brought about in the rectal temperature by the procedures employed, the photographic method of making records has been of considerable value in establishing the nature and the regularity of the results.

TABLE I

THE EFFECT OF OBSTRUCTION TO THE CIRCULATION OF BLOOD IN THE EXTREMITIES UPON SURFACE AND RECTAL TEMPERATURES

A short summary of the data is given, arranged in order of decreasing room temperatures. The variation in pressure used tends to obscure the effect of room temperature. With the exceptions of Cases 6 and 13, in which unusually low and high pressures were used, respectively, the rises of rectal temperature are greater and the falls in temperature of the extremities are smaller in the first six than in the last seven cases.

CASE	NAME	AGE	RISE OF RECTAL TEMPERATURE (° C.)	FALL OF HAND TEMPERATURE (° C.)	FALL OF FOOT TEMPERATURE (° C.)	PRESSURE IN CUFF*	DIFFERENCE	DIASTOLIC PRESSURE	ROOM TEMPERATURE (° C.)
1	J. B.	40	0.25	0.8	0.8	60	-12	72	27.5
						70	-14	84	
2	D. H.		0.23	1.1	1.2	80	+12	68	26.5
						90	-10	80	
3	O. C.	32	0.37	1.1	2.0	80	+12	68	26.0
						90	+10	80	
4	M. K.	35	0.25	1.8	2.4	90	+22	68	26.0
						100	-18	82	
5	C. G.		0.22	0.7	1.2	50	-14	64	25.5
						60	-12	72	
6	C. G.		0.08	0.6	0.7	40	-30	70	25.0
						40	-35	85	
7	M. K.		0.18	1.6	2.8	80	+16	64	24.0
						90	+10	80	
8	W. S.	29	0.12	1.3	1.5	50	-10	60	24.0
						60	-12	72	
9	S. M.	35	0.13	1.8	3.1	70	- 2	68	23.0
						80	0	80	
10	C. E.	15	0.18	2.3	3.2	90	+28	62	22.0
						100	+26	74	
11	J. A.	52	0.17	1.9	3.0	110	+10	100	22.0
						120	+12	108	
12	M. K.		0.12	1.8	2.1	50	- 8	68	22.0
						60	-10	70	
13	S. M.	35	0.30	5.0	5.8	110	+40	70	22.0
						120	+36	84	

*The upper figures for each individual are for the arms; the lower, for the legs.

*I am indebted to Dr. Ronald V. Christie, Assistant Director of the Medical Unit of the London Hospital, for suggesting the value of a narrow slit in place of the usual cylindrical lens.

RESULTS

The results were in general uniform (Table I). In all instances (thirteen observations in nine individuals) the rectal temperature began to rise within eight minutes after raising the pressure in the cuffs and fell promptly on its release in nine of the fourteen tests. Even when the temperature did not return to the original level there was, none the less, a fall on release of pressure. The rise in rectal temperature was preceded by, and continued for a variable period of time during, the fall of temperatures at the surface. Conversely when the pressure in the

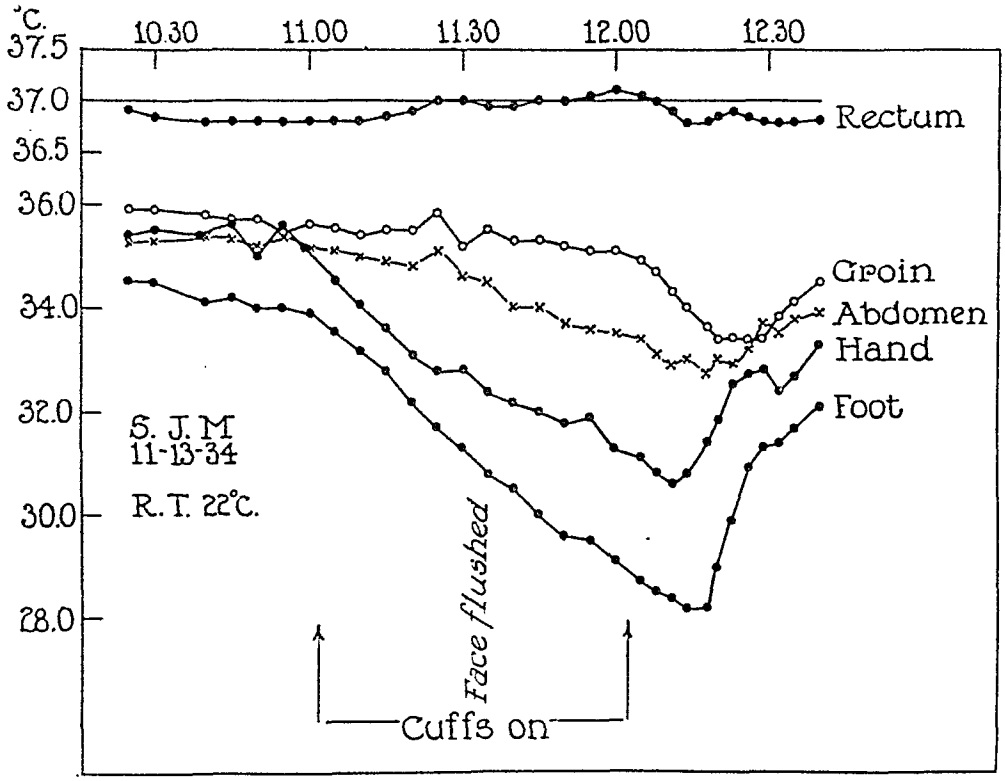

Fig. 2.—This chart is constructed from the recorded temperatures in the way described in the text as the first method. The striking changes in temperature which may be obtained by use of high pressures are well shown. Note the rapid drop in temperature of the groin following release of pressure in cuffs. The slow fall in the temperature of the abdomen and groin during the time pressure was being applied suggests pooling of blood in the extremities and consequent decrease in the effective volume of circulating blood (Case 13, Table I).

cuffs was released, a fall in rectal temperature followed, accompanied by a rise in surface temperature (Fig. 2). The pressures used in the cuffs in this instance were great (110 to 120 mm. Hg for arms and legs, respectively). It was soon found that such high pressures were not necessary. Because of the discomfort involved, this experiment was not repeated. One chart (Fig. 2) is shown as an example of the first method of recording the temperatures. So far as the aim of the present study is concerned, the less striking results which follow the application of lower pressures are of greater moment.

Observations in which the pressure in the cuffs was above diastolic pressure differed from those in which it was below in degree only: when

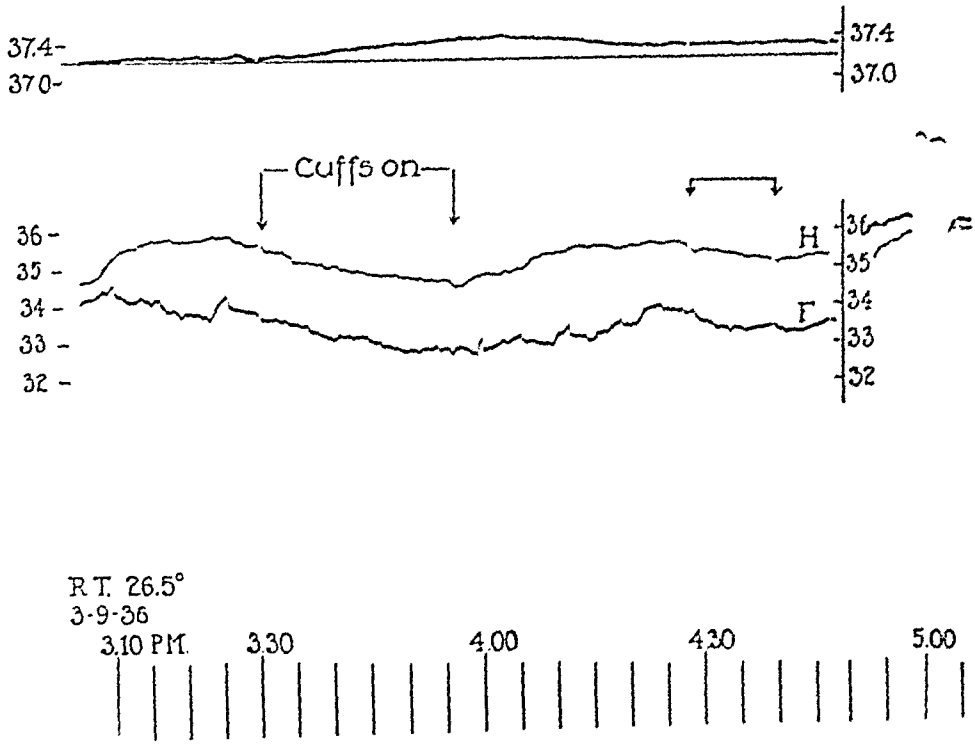

Fig. 3.—The curves in this figure as well as in Figs. 4 and 5 are reproduced from continuous photographic records of temperature obtained by the method described in the text. The ordinates for temperature are drawn in with India ink on the original records, from the calibration lines seen on the extreme right of the photographs. The rise of rectal temperature was, in this instance, occasioned by a pressure of 56 mm. Hg in the arms, 60 mm. Hg in the legs, approximately 13 mm. less than diastolic pressure (Case 5, Table I).

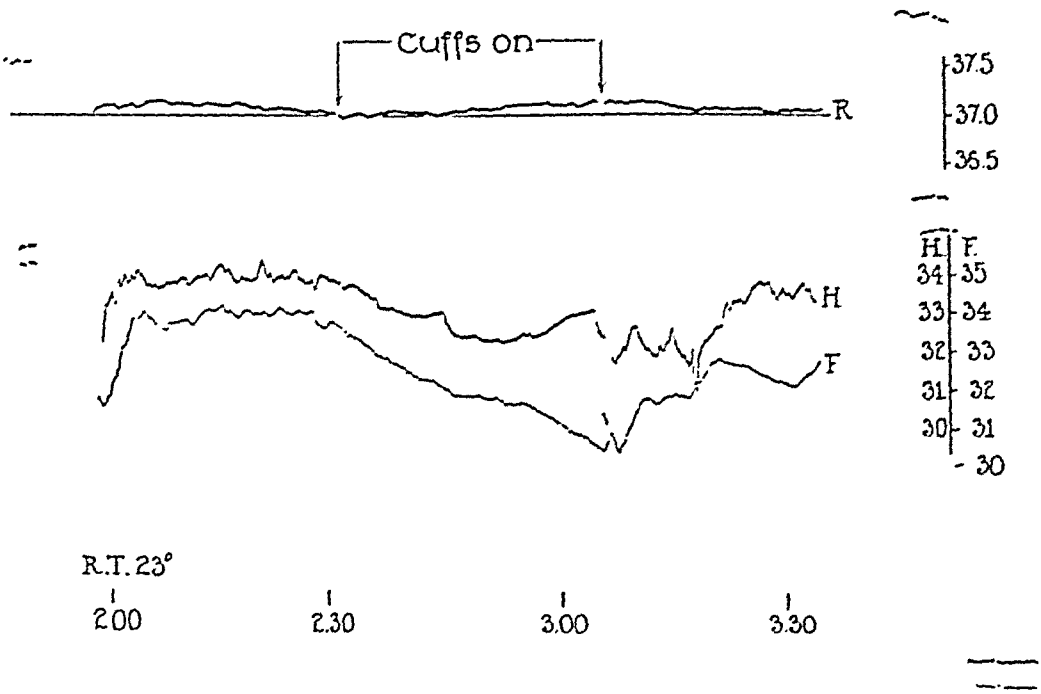

Fig. 4.—The record exhibits the rather small rise in rectal temperature in comparison to the relatively large fall in surface temperature of the extremities often encountered at moderately low environmental temperatures (Case 9, Table I).

the pressure was above the diastolic level the effects were somewhat greater. Pressures as low as 40 and 50 mm. Hg gave rise, however, to small increases in rectal temperature (Fig. 3).

If the room temperature is low (in the neighborhood of 22° C.) the extremities are cool and the vessels are contracted. Under these circumstances obstruction of the circulation decreases the loss of heat but little, and the rise of rectal temperature is, consequently, likely to be small (Fig. 4). If the temperature of the room is in the neighborhood of 24 to 27° C., however, and the hands and the feet are warm, the rise in rectal temperature may be considerable although there is only a slight fall in surface temperature (Fig. 5). Under these conditions the rectal temperature tends to be exceedingly slow in falling after release of the obstruction to the peripheral circulation (Fig. 3).

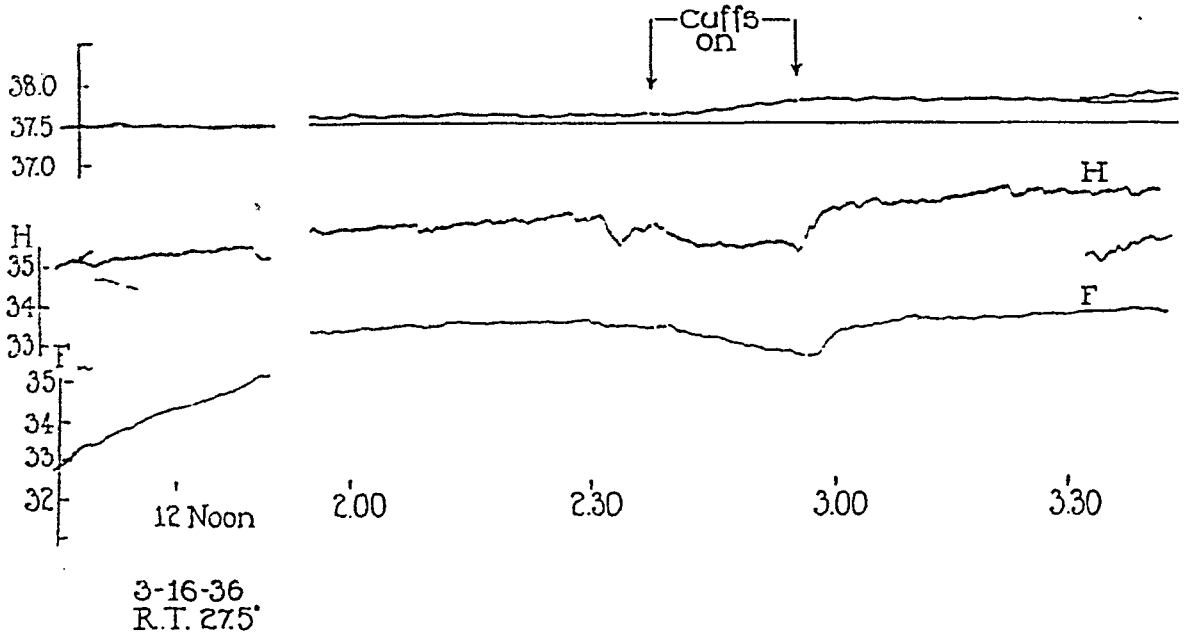

Fig. 5.—The record of an observation carried out at a fairly high environmental temperature is shown. The rectal temperature does not return to its original level and the drop in surface temperatures of the extremities is rather small (Case 1, Table I). The pressures in the cuffs were in this case 13 mm. Hg below diastolic pressure. A portion of the record was omitted because it was irrelevant. The beginning is included to show calibration and scales.

The study of a few observations in which pressure was maintained for upwards of one-half hour develops a point of interest. The temperature of the rectum stops rising after pressure has been applied for from fifteen to twenty minutes, and the new level is thereafter maintained. Although objective evidence of increase in loss of heat from parts of the body to which the circulation was not obstructed was not sought, the subjective sensations, warmth of face and chest, the rubor of these surfaces, and the appearance of small beads of perspiration, appear to constitute ample evidence of increased effort to lose heat from these portions of the body. It seems clear that a new state of equilibrium has been reached.

COMMENT

It was demonstrated long ago that complete stoppage of the circulation gives rise promptly to increase of temperature in the interior of the body and that this takes place while the peripheral temperature is decreasing.[5, 6, 7] The present study demonstrates that even partial, in fact very mild, obstruction of relatively short duration to the circulation of the extremities is promptly and regularly followed by a small rise in rectal temperature. The circumstances under which the observations were carried out precluded the possibility of making quantitative estimations of the degree of slowing of the circulation to the extremities. The venous congestion and faintly cyanotic tinge which appeared during the latter part of the period in which the cuffs were inflated, seem, however, to indicate that a certain amount of slowing of the circulation took place. The slowing of the peripheral circulation which in these observations seems no greater in degree, and is obviously infinitely shorter in duration, than that which occurs in heart failure is, none the less, sufficient to elevate slightly internal body temperature.

The inference is, then, that the degree of slowing of the circulation often observed in individuals suffering from heart failure is capable of interfering with the loss of heat from the body to such an extent that elevation of the rectal temperature follows. There are, of course, reasons for believing that other more complex mechanisms frequently play a part in raising the temperature of the body in heart failure. Some of these reasons have been discussed in previous papers.[2, 8]

SUMMARY

1. A method of obtaining continuous records of temperature is described in which the movements of beams of light reflected from the mirrors of galvanometers connected to thermocouples are photographed.

2. Relatively mild obstruction to the circulation of the extremities obtained by use of pressure cuffs about the arms and legs is followed promptly by rise in rectal temperature.

3. In a warm environment, the rise of rectal temperature tends to be greater and the fall of surface temperature less than in a cool environment.

4. The results suggest that the relatively mild and short obstruction to peripheral circulation used in these observations brings about elevation of rectal temperature and is consistent with the belief that elevation of rectal temperature encountered in the course of heart failure may be due simply to slowing of the peripheral circulation.

REFERENCES

1. Cohn, A. E., and Steele, J. M.: Unexplained Fever in Heart Failure, J. Clin. Investigation 13: 853, 1934.

2. Steele, J. M.: Fever in Heart Failure: Relations Between the Temperatures of the Interior and the Surface of the Body, J. Clin. Investigation 13: 869, 1934.
3. Blumgart, H. L., and Weiss, S.: Studies on the Velocity of Blood Flow: III. Velocity of Blood Flow and Its Relation to Other Aspects of Circulation in Patients With Rheumatic and Syphilitic Heart Disease, J. Clin. Investigation 4: 149, 1927.
4. Winternitz, M., Deutsch, J., and Brill, Z.: Eine klinische brauchbare Bestimmungsmethode der Blutumlaufseit mittels Decholininjektion, Med. Klin. 27: 986, 1931; 28: 831, 1932.
5. Ackermann, Th.: Ueber die physiologischen Wirkungen des Digitalins auf den Kreislauf und die Temperatur, Deutsches Arch. f. klin. Med. 2: 125, 1873.
6. Wunderlich, C. A.: On the Temperature in Diseases: A Manual of Medical Thermometry, New Sydenham Society, London, 1871. Translated from the German, ed. 2, by W. B. Woodman.
7. Heidenhain, R.: Ueber bisher unbeachtete Einwirkungen des Nervensystems auf die Körpertemperatur und den Kreislauf, Arch. f. d. ges. Physiol. 3: 504, 1870.
8. Steele, J. M.: Elimination of Heat by Evaporation of Water From the Lungs in Heart Failure, J. Clin. Investigation 14: 706, 1935.

HEART CHANGES AND PHYSIOLOGIC ADJUSTMENT IN HOOKWORM ANEMIA*

WILLIAM B. PORTER, M.D.
RICHMOND, VA.

INTRODUCTION

WHEN a living organism is confronted with adverse conditions which threaten its physical fitness, there go into action mechanisms calculated to modify the harmful effects resulting therefrom. The success of these adjustment mechanisms is dependent upon many factors, but the length of time allowed for development is unquestionably the most essential factor in that success. The full establishment of these compensatory processes is realized in man, not in periods of months, but rather after the lapse of years.

Much information is at hand which deals with the reaction of man to anemia, but the studies have been concerned with relatively acute reductions in the oxygen-carrying function of the blood; hence, the conclusions are applicable in only a limited degree to the changes developing in individuals with chronic anemia existing over periods of years. To comprehend fully this problem, it must be appreciated that the body functions as a corporate whole, bringing into play many quite different mechanisms each of which is required to lend only a little aid in the handling of the adverse situation. This study was conceived to determine what factors contribute to the physiological adjustment occurring in anemia of varying degrees and duration and whether during the evolution of the compensatory processes there occur anatomical changes.

A study of the reactions to a diminished oxygen-carrying capacity of the blood is immediately concerned not only with the amount of circulating hemoglobin and the heart and vascular systems, but also with the pulmonary apparatus and finally with the tissue cells which are in constant need of varying quantities of oxygen. An effort was made to study as completely as the circumstances permitted both from a physiological and anatomical standpoint those organs and systems which are normally concerned with the problem of oxygen supply and distribution.

The anemia associated with hookworm infestation offers an ideal type for study. It varies in intensity, duration, and rate of development, and may be relieved by medication without the introduction of measures which might confuse the observations.

---

*From the Department of Medicine, Medical College of Virginia, Richmond, Va.
The expense of this study was in part defrayed by a grant from the Valentine Research Fund.

Eighteen patients varying in age from six to forty-nine years were selected and placed in hospitals. These were chosen for the reason that they were free from other diseases which might be confusing. Two of the patients were infested with *Necator americanus* and sixteen with *Ankylostoma duodenale.*

All patients remained in bed on the days physiological observations were made and at all times were confined to a ward. This restriction definitely standardized the kind and amount of physical activity. The blood pressure readings, venous pressure estimations, and rate of blood flow studies were done from three to four hours after the last meal. The vital lung capacity estimations were made on the days not concerned with other physiological studies. All of the recorded primary figures were obtained during the first week of observation and subsequently at weekly intervals, after the beginning of therapeutic measures calculated to reduce the anemia.

METHODS

The arterial blood pressure was determined with the aid of a standard mercury manometer, the venous pressure by direct venipuncture, using the apparatus and technic of Moritz and von Tabora.[1] In the determination of the vital capacity of the lungs, a calibrated spirometer was used. Measurements of the velocity of blood flow were made with the use of the cyanide method of Robb and Weiss.[2] Local novocaine anesthesia was used routinely. The effective dose of cyanide solution was determined by gradually increasing the amount and recording the quantity which would give regularly a reaction consisting of two to four active respiratory cycles, and the final figure was considered standard for the individual after three observations at half-hour intervals using the determined effective quantity. All blood studies were made by the same observer who used counting chambers and pipettes certified by the United States Bureau of Standards. The hemoglobin estimations were done with a Sahli hemometer standardized so that 14.5 gm. were equivalent to 100 per cent (Wintrobe[3]).

The heart size was determined at the beginning and at the end of the period of observation by the use of teleroentgenograms. These were standardized to constant chest diameters and the position of the diaphragmatic level. The electrocardiograms were made under standard conditions at a central station and with the patients in the recumbent position.

TREATMENT

In 1929 it was observed that patients with hookworm disease could be relieved of all symptoms, including the anemia, without the use of anthelmintics if they were placed on a diet rich in complete proteins, large amounts of iron, and liver extract (aqueous extracts).[4] Subsequently

Rhoads, Castle, and their coworkers[5] have confirmed this observation and have indicated that iron in adequate quantities is the important effective agent.

In this study all patients were given an adequate diet rich in complete proteins, ferrous sulphate 1 gm., and liver extracts (aqueous) 45 c.c. daily, the amounts of iron and liver extract being proportioned to the body size of the child patients. No anthelmintics were given.

In every instance there was prompt and progressive improvement in weight, subjective symptoms, and an increase in hemoglobin of approximately 0.2 gm. per 100 c.c. per day.

CASE REPORTS

CASE 1.—D. P., a white female, aged six years, who complained of weakness, anorexia, fatigability, puffiness of the eyelids, and slight swelling of the feet, was admitted July 18, 1932. Pallor had been first noted during December, 1931.

Physical examination showed a poorly nourished child who was very sluggish mentally and physically. Her weight on admission was 39½ pounds, which fell to 36½ pounds during the first week in the hospital and then progressively increased. She weighed 46 pounds when discharged on Sept. 14, 1932.

There was marked pallor of the skin and mucous membranes and slight pitting edema of the ankles. The pulse was 129 per minute and rhythmic; blood pressure was systolic 108, diastolic 45. The veins were not abnormally distended and the jugulars pulsated at a normal level. Heart (Fig. 1): The first sound was loud and booming in quality, and a loud systolic murmur was audible over the entire heart area. The second sounds were normal. The lungs were not unusual except for exaggerated puerile breath sounds throughout.

Laboratory Data.—Hemoglobin in grams per 100 c.c., 2.8; erythrocytes in millions, 1.54; leucocytes in thousands, 12.8. Feces: ova, *Necator americanus*, heavy infestation. Electrocardiogram, Fig. 1.

CASE 2.—R. H., a white female aged eight years, who complained of extreme fatigability, precordial aching with effort, pallor, and edema of the feet and ankles, was admitted April 18, 1932.

Physical examination showed a fairly well-nourished child, extremely sluggish mentally and physically, lying comfortably in bed showing no evidences of respiratory distress. The weight on admission was 41½ pounds which fell to 35 pounds during the first week in the hospital, and then progressively increased. She weighed 48½ pounds when discharged June 17, 1932.

There was extreme pallor of the skin and the mucous membranes and pitting edema over the sacrum, feet, and ankles. The pulse was 127 per minute and rhythmic; blood pressure was systolic 90, diastolic 50. The jugular veins were moderately distended. Heart (Fig. 2): The first sound was booming in quality, and a loud systolic murmur was audible at the apex and base. The second pulmonic sound was definitely accentuated. Medium, moist râles were heard posteriorly over both lung bases. The respiratory rate was increased to 38 per minute; yet there was no apparent distress.

Laboratory Data.—Hemoglobin in grams per 100 c.c. 1.4; erythrocytes in millions, 1.24; leucocytes in thousands 11.2. Feces: ova, *Necator americanus*. Serum proteins: albumin 2.1 gm. per cent; globulin 3.2 gm. per cent; cholesterol 118 mg. per 100 c.c. Electrocardiogram, Fig. 2.

CASE 3.—G. M., a native boy, aged ten years, who had no especial complaint, was admitted July 22, 1935. His parents complained that the child would not play and that his growth was slow.

Physical examination revealed a poorly nourished boy who was very sluggish mentally and physically. His weight was 34 pounds. There was extreme pallor of

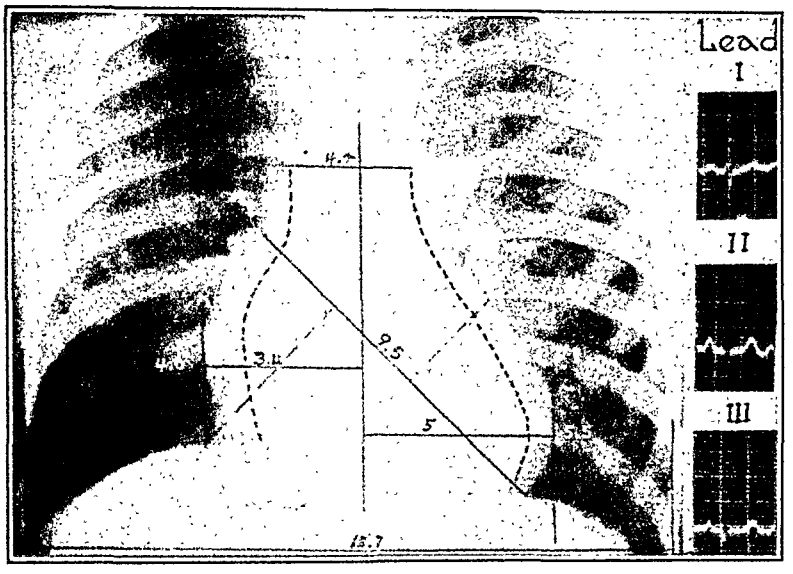

FIG. 1.*—CASE 1.

DATE	HEMOGLOBIN, GM. PER 100 C.C.	CARDIO-THORACIC RATIO	PREDICTED TRANSVERSE DIAMETER HODGES & EYSTER	ACTUAL TRANSVERSE DIAMETER
7/18	2.8	54.0%	data incomplete	10.1 cm.
9/13	11.9	44.9%		8.4 cm.

Electrocardiogram: Sinus tachycardia, rate 112, otherwise normal.

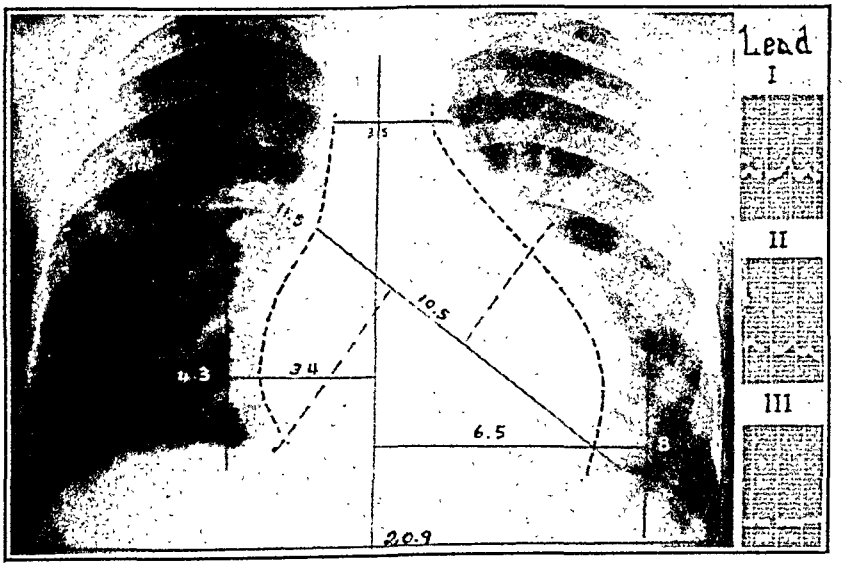

FIG. 2.—CASE 2.

DATE	HEMOGLOBIN, GM. PER 100 C.C.	CARDIO-THORACIC RATIO	PREDICTED TRANSVERSE DIAMETER HODGES & EYSTER	ACTUAL TRANSVERSE DIAMETER
4/18	1.4	58.8%	data incomplete	12.3 cm.
6/14	12.7	47.3%		9.9 cm.

Electrocardiogram: Sinus tachycardia, rate 115, otherwise normal.

*All figures are composed of the first and last teleroentgenograms; the latter is indicated by the dotted line. The outside figures represent the measurements in centimeters of the first and the inside figures of the last teleroentgenogram. The hemoglobin values were obtained on the same day as the x-ray studies. The figures and the cases bear identical numbers.

the skin and the mucous membranes. Arteries were normal. Pulse rate was 110 and rhythmic; blood pressure was systolic 110, diastolic 45. The veins were full, but the jugulars pulsated at a normal level. Heart (Fig. 3): The first sound was loud and booming, and there was an inconstant systolic murmur heard at the mitral area and at the left second costal cartilage. P_2 and A_2 were normal. The thorax was slightly emphysematous in shape. The lungs gave to a marked degree the phenomena of hyperfunctional inflation.

Laboratory Data.—Hemoglobin in grams per 100 c.c., 3.6; erythrocytes in millions, 2.42; leucocytes in thousands, 8.45. Feces: ova, *Uncinaria americana* and *Ascaris lumbricoides*. Serum proteins: albumin, 2.8 gm. per cent; globulin, 2.4 gm. per cent; cholesterol, 82 mg. per 100 c.c. Electrocardiogram, Fig. 3; vital capacity, Table III.

CASE 4.—L. M., a native boy, aged fifteen years, who complained of fatigability, vertigo, tinnitus, and pain under the lower substernal area and breathlessness with effort, was admitted July 2, 1935. He took part in no sports but did some domestic work.

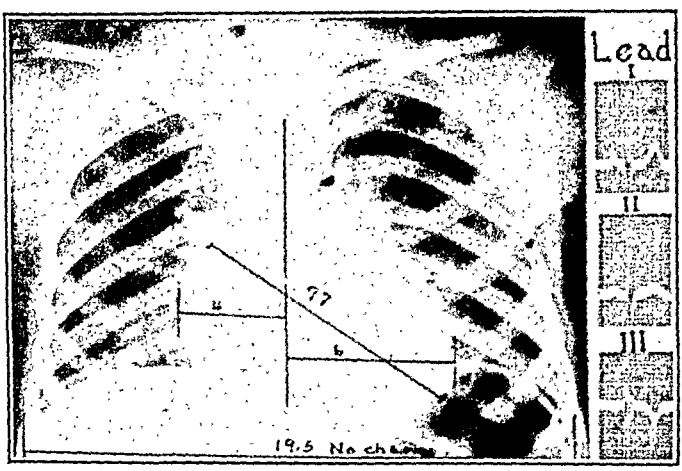

FIG. 3.—CASE 3.

DATE	HEMOGLOBIN, GM. PER 100 C.C.	CARDIO-THORACIC RATIO	PREDICTED TRANSVERSE DIAMETER HODGES & EYSTER	ACTUAL TRANSVERSE DIAMETER
7/22	3.6	51.3%	data incomplete	10.0 cm.
8/14	11.3	51.3%		10.0 cm.

Electrocardiogram: Sinus rhythm, rate 95, P_3 inverted, T_3 sharply inverted.

Physical examination revealed a poorly nourished boy who was very sluggish mentally and physically. His weight was 64 pounds; height, 50 inches. There was marked pallor of the skin and mucous membranes. The arteries showed wide pulsations. The pulse rate was 104 per minute and rhythmic; blood pressure was systolic 105, diastolic 55. The veins were full, but the jugulars did not pulsate above a normal level. Heart (Fig. 4): The first sound was loud and booming in quality. There was an inconstant systolic murmur at the apex and base. P_2 and A_2 were normal. The thorax was markedly emphysematous in shape, but expansion was equal and normal. The lungs showed to a marked degree the phenomena of hyperfunctional inflation.

Laboratory Data.—Hemoglobin in grams per 100 c.c., 2.6; erythrocytes in millions, 1.66; leucocytes in thousands, 7.7. Feces: ova, *Uncinaria americana*, heavy infestation. Serum proteins: albumin, 4.1 gm. per cent; globulin, 1.2 gm. per cent; cholesterol, 100 mg. per 100 c.c. Electrocardiogram, Fig. 4; vital capacity, Table III.

CASE 5.—C. R., a native man, aged twenty-three years, who complained of weakness and blurred vision which began six weeks previously following an attack of diarrhea of three days' duration, was admitted July 10, 1935. He had worked regularly as a laborer on a sugar cane farm.

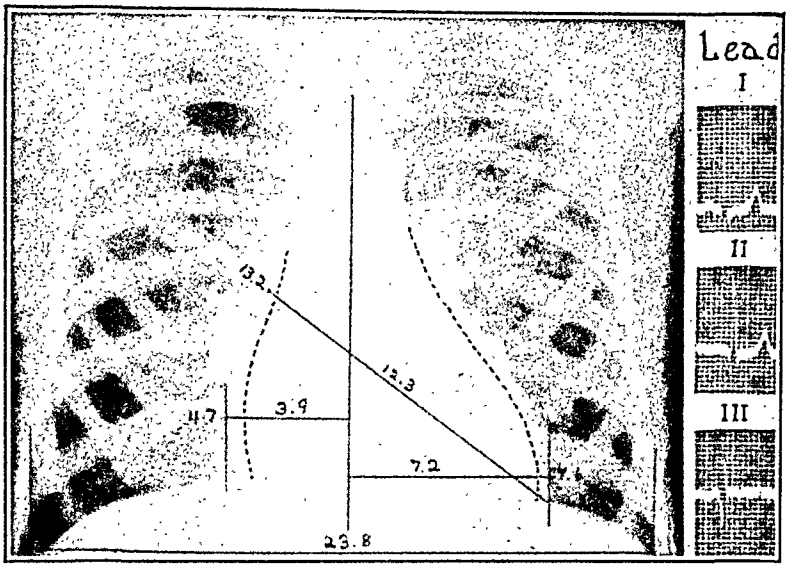

FIG. 4.—CASE 4.

DATE	HEMOGLOBIN, GM. PER 100 C.C.	CARDIO-THORACIC RATIO	PREDICTED TRANSVERSE DIAMETER HODGES & EYSTER	ACTUAL TRANSVERSE DIAMETER
7/3	2.6	51.6%	9.5 cm.	12.3 cm.
8/13	11.8	46.7%	10.0 cm.	11.1 cm.

Electrocardiogram: Sinus tachycardia, rate 103, flat P-waves in Leads II and III, deep Q-wave in Lead III.

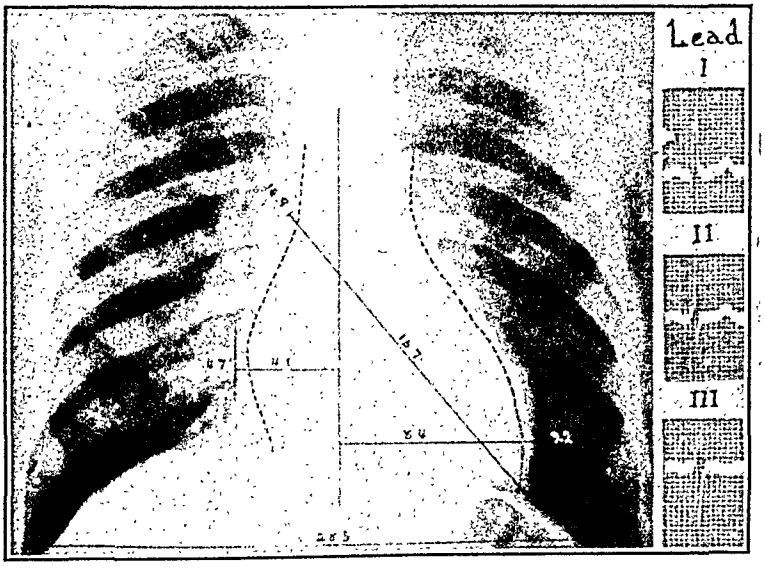

FIG. 5.—CASE 5.

DATE	HEMOGLOBIN, GM. PER 100 C.C.	CARDIO-THORACIC RATIO	PREDICTED TRANSVERSE DIAMETER HODGES & EYSTER	ACTUAL TRANSVERSE DIAMETER
7/10	6.9	48.9%	11.3 cm.	13.9 cm.
8/16	9.5	43.8%	11.4 cm.	12.5 cm.

Electrocardiogram: Sinus rhythm, rate 79, electrical axis, left preponderance.

Physical examination revealed a fairly well-nourished man who was sluggish mentally and physically. His weight was 127 pounds; height, 67 inches. Arteries were normal. Pulse rate was 58 and rhythmic; blood pressure was systolic 92,

diastolic 45. The veins were normal. Heart (Fig. 5): The first and second sounds were normal, and there were no murmurs. The thorax was slightly emphysematous in shape; yet expansion was equal and normal. The lungs gave to a marked degree the phenomena of hyperfunctional inflation.

Laboratory Data.—Hemoglobin in grams per 100 c.c. 6.9; erythrocytes in millions, 2.16; leucocytes in thousands, 6.5. Feces: ova, *Uncinaria americana.* Serum proteins: albumin, 4.9 gm. per cent; globulin, 2.4 gm. per cent; cholesterol, 70 mg. per 100 c.c. Electrocardiogram, Fig. 5; vital capacity, Table III.

CASE 6.—E. V., a native woman, aged twenty-three years, who complained of fatigability, aching in the legs and arms, headache, and vertigo, was admitted July 4, 1935. She did the domestic work for a family of five. There were three living children. Two months previously she had an abortion with blood loss, but the quantity was not definitely stated.

Physical examination revealed a poorly nourished woman who was very sluggish mentally and physically. Her weight was 87 pounds; her height, 63 inches. There

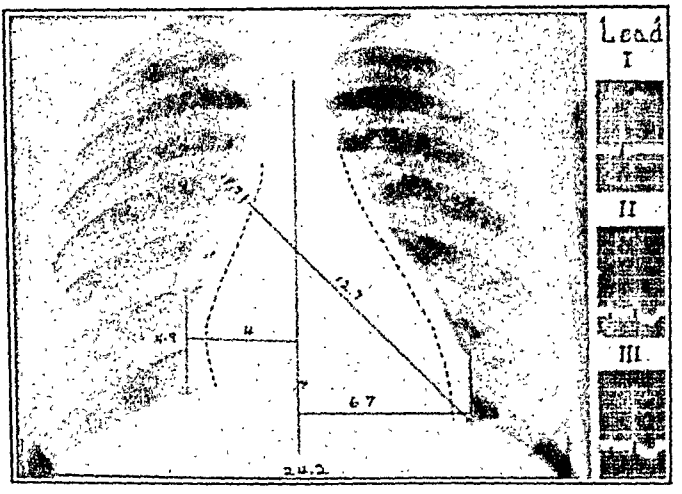

FIG. 6.—CASE 6.

DATE	HEMOGLOBIN, GM. PER 100 C.C.	CARDIO-THORACIC RATIO	PREDICTED TRANSVERSE DIAMETER HODGES & EYSTER	ACTUAL TRANSVERSE DIAMETER
7/4	4.0	50.8%	9.9 cm.	12.4 cm.
7/31	8.9	44.2%	10.1 cm.	10.7 cm.

Electrocardiogram: Sinus tachycardia, rate 100, P-R interval 0.21 sec., T_1 isoelectric, T_2 and T_3 inverted.

was marked pallor of the skin and the mucous membranes. Arteries were normal. Pulse wave had a wide excursion, rate 74 per minute, and arrhythmic. Blood pressure was: systolic 130, diastolic 50. Heart (Fig. 6): The first sound was loud and there was an inconstant systolic murmur at the mitral area. The rhythm was interrupted by "dropped beats" every sixth to eighth cardiac cycle. The clinical evidence of heart-block lasted three days. A_2 and P_2 were normal. The thorax was slightly emphysematous in shape. The lungs gave to a marked degree the phenomena of hyperfunctional inflation. There was no edema.

Laboratory Data.—Hemoglobin in grams per 100 c.c., 4.0; erythrocytes in millions, 2.23; leucocytes in thousands, 5.65. Feces: ova, *Uncinaria americana,* heavy infestation. Serum proteins: albumin 3.2 gm. per cent; globulin, 1.2 gm. per cent; cholesterol, 71 mg. per 100 c.c. Electrocardiogram, Fig. 6; vital capacity, Table III.

CASE 7.—C. A., a native man aged twenty-five years, who complained of vertigo, fatigability, palpitation, and substernal discomfort with effort, was admitted July 1, 1935. He was employed as a laborer on a coffee farm, but had worked not more than half time during the past year.

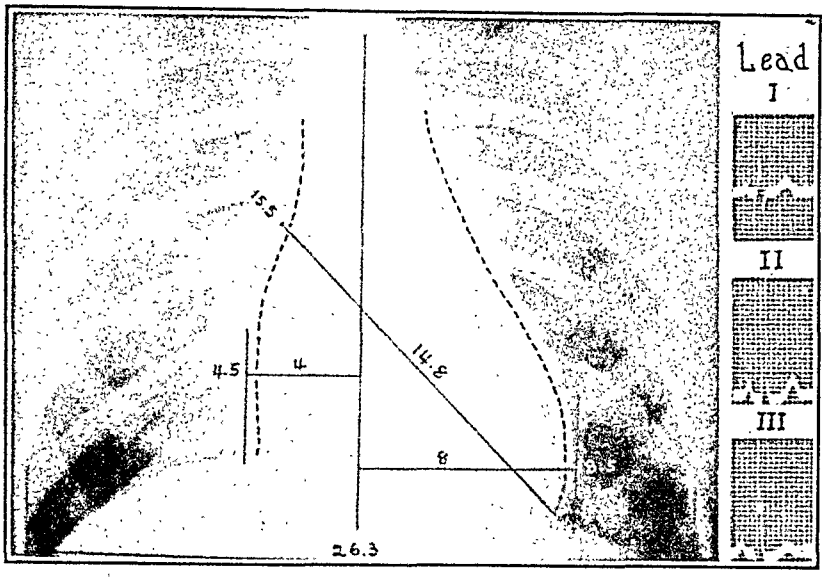

FIG. 7.—CASE 7.

DATE	HEMOGLOBIN, GM. PER 100 C.C.	CARDIO-THORACIC RATIO	PREDICTED TRANSVERSE DIAMETER HODGES & EYSTER	ACTUAL TRANSVERSE DIAMETER
7/2	4.9	49.4%	10.4 cm.	13.0 cm.
8/16	11.1	45.6%	10.6 cm.	12.0 cm.

Electrocardiogram: Sinus tachycardia, rate 100, electrical axis, right preponderance.

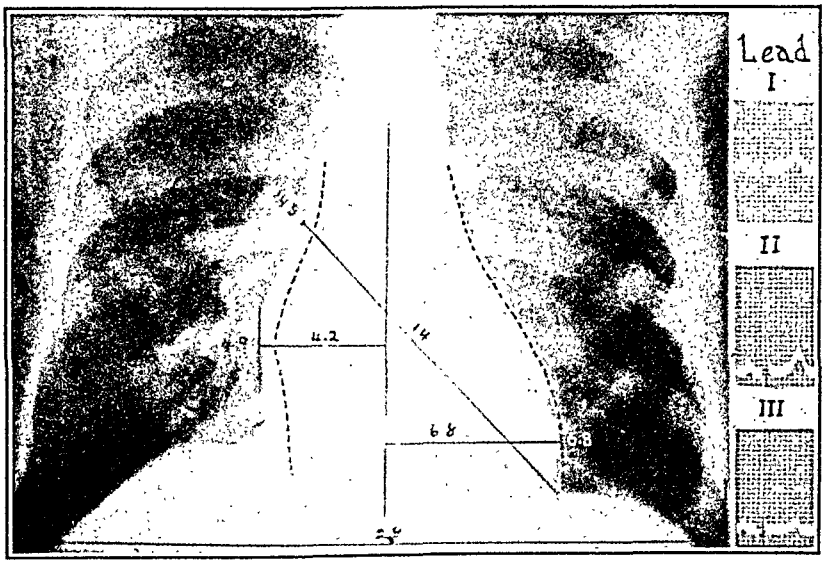

FIG. 8.—CASE 8.

DATE	HEMOGLOBIN, GM. PER 100 C.C.	CARDIO-THORACIC RATIO	PREDICTED TRANSVERSE DIAMETER HODGES & EYSTER	ACTUAL TRANSVERSE DIAMETER
7/11	6.8	41.7%	10.4 cm.	11.7 cm.
8/16	11.6	39.0%	10.5 cm.	11.0 cm.

Electrocardiogram: Sinus rhythm, rate 70, normal electrocardiogram.

Physical examination revealed a reasonably well-nourished man who was very sluggish mentally and physically. His weight was 105 pounds; his height, 66½ inches. The skin and the mucous membranes showed marked pallor. The arteries were normal. Pulse rate was 74 per minute and rhythmic. Pulse wave had a wide

excursion; blood pressure was systolic 124, diastolic 48. The veins were normal. Heart (Fig. 7): The first sound was loud and booming in quality. There was an inconstant systolic murmur at the apex and left second costal cartilage. P_2 and A_2 were normal. The thorax was slightly emphysematous in shape; yet expansion was equal and normal. The lungs gave to a slight degree the phenomena of hyperfunctional inflation.

Laboratory Data.—Hemoglobin in grams per 100 c.c., 4.9; erythrocytes in millions, 2.73; leucocytes in thousands, 9.25. Feces: ova, *Uncinaria americana*, very heavy infestation. Serum proteins: albumin, 3.2 gm. per cent; globulin, 1.3 gm. per cent; cholesterol, 70.4 mg. per 100 c.c. Electrocardiogram, Fig. 7; vital capacity, Table III.

CASE 8.—A. A., a native man, aged twenty-eight years, who complained of vertigo and weakness, was admitted July 10, 1935. He had continued to work regularly as a laborer on a sugar cane farm.

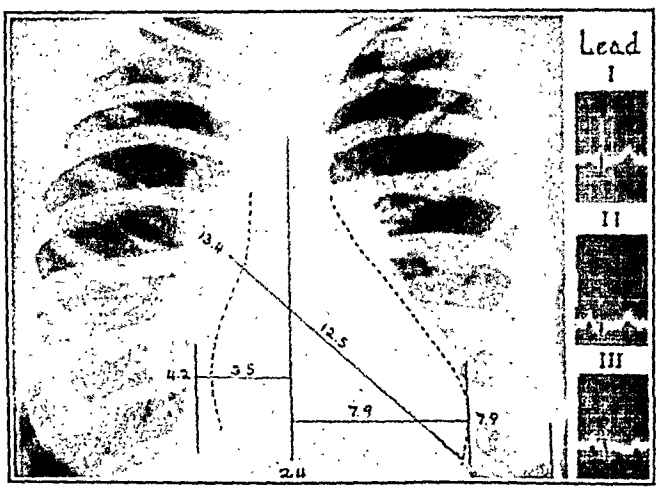

FIG. 9.—CASE 9.

DATE	HEMOGLOBIN, GM. PER 100 C.C.	CARDIO-THORACIC RATIO	PREDICTED TRANSVERSE DIAMETER HODGES & EYSTER	ACTUAL TRANSVERSE DIAMETER
7/4	3.7	50.4%	10.1 cm.	12.1 cm.
8/12	10.7	47.5%	10.5 cm.	11.4 cm.

Electrocardiogram: Sinus rhythm, rate 88, normal electrocardiogram.

Physical Examination.—The patient was a fairly well-nourished man who was physically active but mentally sluggish. His weight was 101 pounds; height, 64 inches. The skin and the mucous membranes showed moderate pallor. Arteries were normal. Pulse rate was 62 per minute and rhythmic; blood pressure was systolic 110, diastolic 60. Veins were full, but the jugulars did not pulsate above a normal level. Heart (Fig. 8): There were no murmurs, and the first and second sounds were normal in quality and intensity. The thorax was slightly emphysematous in shape; yet expansion was equal and normal. The lungs gave to a moderate degree the phenomena of hyperfunctional inflation.

Laboratory Data.—Hemoglobin in grams per 100 c.c., 6.8; erythrocytes in millions, 3.55; leucocytes in thousands, 5.20. Feces: ova, *Uncinaria americana*, and cysts of *Endameba histolytica*. Serum proteins: albumin, 2.2 gm. per cent; globulin, 2.9 gm. per cent; cholesterol, 72 mg. per 100 c.c. Electrocardiogram, Fig. 8; vital capacity, Table III.

CASE 9.—R. A., a native woman, aged thirty years, who complained of fatigability, headache, vertigo, and substernal aching with active physical effort, was admitted July 3, 1935. She did all the domestic work for a family of five and occasionally worked in the field.

Physical Examination.—She was a poorly nourished woman who was mentally and physically sluggish, but active in caring for patients on the ward. Her weight was 86 pounds; height, 58 inches. Skin and mucous membranes showed marked pallor. Arteries were normal. Pulse was full, rate 64 per minute and rhythmic; blood pressure was systolic 110, diastolic 55. Veins were normal. Heart (Fig. 9): The first sound was loud, and there was an inconstant systolic murmur heard at the mitral area. A_2 and P_2 were normal. The thorax was definitely emphysematous in shape; yet expansion was equal and normal.

Laboratory Data.—Hemoglobin in grams per 100 c.c., 3.7; erythrocytes in millions, 2.6; leucocytes in thousands, 3.55. Feces: ova, *Uncinaria americana.* Serum proteins: albumin, 4.1 gm. per cent; globulin, 2.2 gm. per cent; cholesterol, 60 mg. per 100 c.c. Electrocardiogram, Fig. 9; vital capacity, Table III.

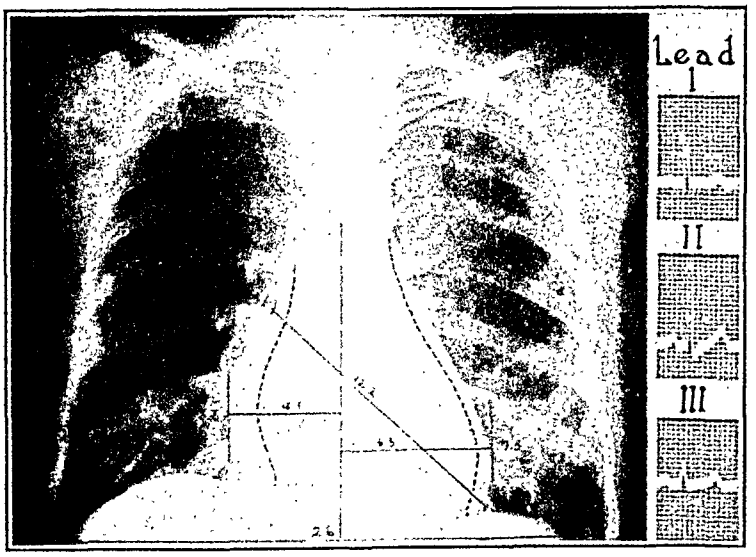

FIG. 10.—CASE 10.

DATE	HEMOGLOBIN, GM. PER 100 C.C.	CARDIO-THORACIC RATIO	PREDICTED TRANSVERSE DIAMETER HODGES & EYSTER	ACTUAL TRANSVERSE DIAMETER
7/13	3.4	50.0%	10.3 cm.	12.8 cm.
8/15	10.1	41.6%	10.6 cm.	10.6 cm.

Electrocardiogram: Sinus rhythm, rate 88, normal electrocardiogram.

CASE 10.—T. D., a native woman, aged thirty-five years, who complained of headache, weakness, blurred vision, and breathlessness with effort, was admitted July 12, 1935. She did all the domestic work for a family of five, but the above symptoms were made sufficiently severe by outside labor to prevent her from helping in the field.

Physical Examination.—The patient was an undernourished woman who assisted patients on the ward but was mentally and physically sluggish. Her weight was 86 pounds; height, 57 inches. Arteries were normal. Pulse rate was 84 per minute and rhythmic; blood pressure was systolic 100, diastolic 65. Veins were full and large, but the jugulars did not pulsate above a normal level. Heart (Fig. 10): The first sound was slightly increased in intensity, but there were no murmurs. A_2 was normal in quality and intensity; P_2 was slightly increased in intensity. The thorax was definitely emphysematous in shape; yet expansion was equal and normal. The lungs gave the phenomena of hyperfunctional inflation.

Laboratory Data.—Hemoglobin in grams per 100 c.c., 3.4; erythrocytes in millions, 2.24; leucocytes in thousands, 4.5. Feces: ova, *Uncinaria americana.* Serum proteins: albumin, 3.8 gm. per cent; globulin, 1.8 gm. per cent; cholesterol, 96 mg. per 100 c.c. Electrocardiogram, Fig. 10; vital capacity, Table III.

CASE 11.—A. D., a native woman aged thirty-five years, who complained of slight vertigo and headache induced by physical labor, was admitted July 22, 1935. Her disabilities were not sufficient to interfere with the domestic duties necessitated by a family consisting of a husband and eight living children. The youngest child was two years old, and the patient was then four months pregnant.

Physical Examination.—The woman was moderately well nourished, physically active, but mentally sluggish. The skin and the mucous membranes were pale, and the skin was prematurely wrinkled. Her weight was 100 pounds; height, 57 inches. Arteries were normal. Pulse rate was 78 per minute and rhythmic; blood pressure was systolic 118, diastolic 60. Veins were normal. Heart (Fig. 11): There was a systolic murmur heard at the mitral area and over the base in the recumbent position. A_2 and P_2 were normal. The vessels of the optic fundi were

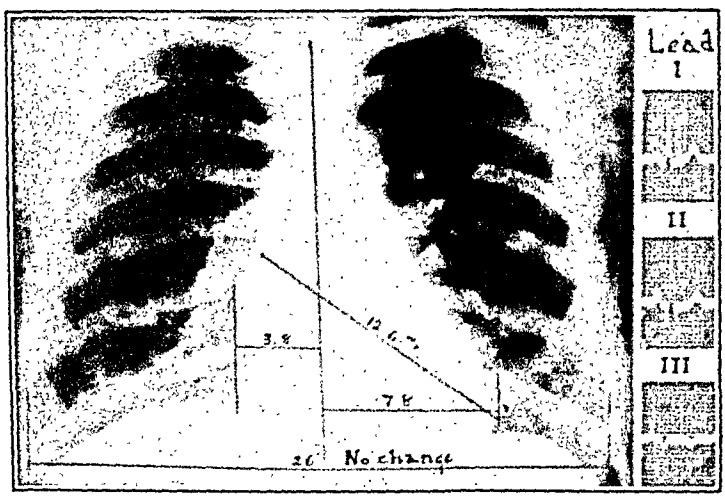

FIG. 11.—CASE 11.

DATE	HEMOGLOBIN, GM. PER 100 C.C.	CARDIO-THORACIC RATIO	PREDICTED TRANSVERSE DIAMETER HODGES & EYSTER	ACTUAL TRANSVERSE DIAMETER
7/22	4.3	44.6%	10.9 cm.	11.6 cm.
8/15	8.7	44.6%	10.9 cm.	11.6 cm.

Electrocardiogram: Sinus tachycardia, rate 115, otherwise normal.

normal. The thorax was emphysematous in shape, yet, expansion was equal and normal. The lungs gave the phenomena of hyperfunctional inflation.

Laboratory Data.—Hemoglobin in grams per 100 c.c., 4.3; erythrocytes in millions, 2.81; leucocytes in thousands, 5.51. Feces: ova, *Uncinaria americana.* Serum proteins: albumin, 3.2 gm. per cent; globulin, 2.1 gm. per cent; cholesterol, 105 mg. per 100 c.c. Electrocardiogram, Fig. 11; vital capacity, Table III.

CASE 12.—S. A., a native man, aged forty years, who complained of fatigability, tinnitus, headache and palpitation with effort was admitted July 10, 1935. He was usually constipated, but one year previously he had had diarrhea for three days. He worked regularly as a laborer on a coffee plantation.

Physical Examination.—He was a poorly nourished but well-developed man who was very sluggish mentally and physically. His weight was 140 pounds; height, 67 inches. The skin and mucous membranes showed marked pallor, and the skin was prematurely aged and wrinkled. The arteries showed slight sclerosis. Pulse wave

had a wide excursion, rate 64 per minute and rhythmic; blood pressure was systolic 105, diastolic 55. The veins were very large and full, but the jugulars did not pulsate above a normal level. Heart (Fig. 12): The first sound was normal in quality and intensity. There was an inconstant systolic murmur heard at the

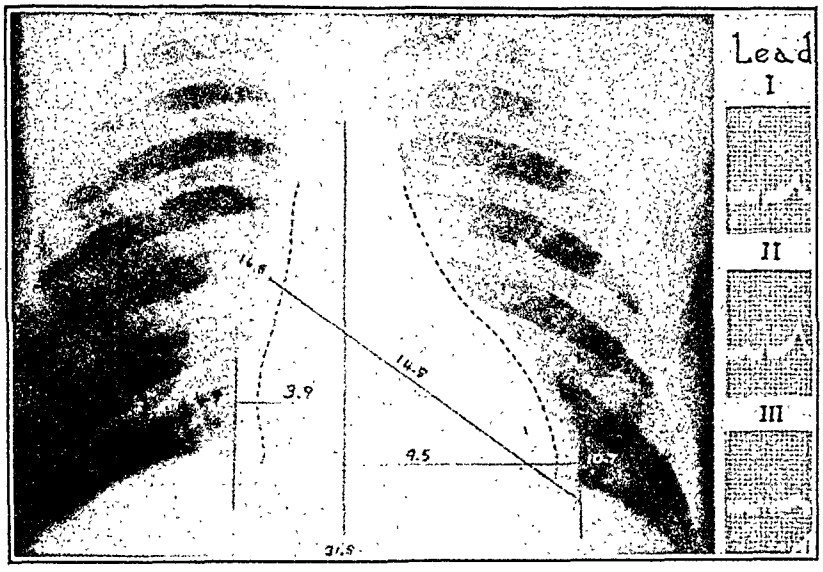

FIG. 12.—CASE 12.

DATE	HEMOGLOBIN, GM. PER 100 C.C.	CARDIO-THORACIC RATIO	PREDICTED TRANSVERSE DIAMETER HODGES & EYSTER	ACTUAL TRANSVERSE DIAMETER
7/10	3.7	49.0%	11.6 cm.	15.6 cm.
8/16	11.2	42.1%	11.8 cm.	13.4 cm.

Electrocardiogram: Sinus rhythm, rate 73, normal electrocardiogram.

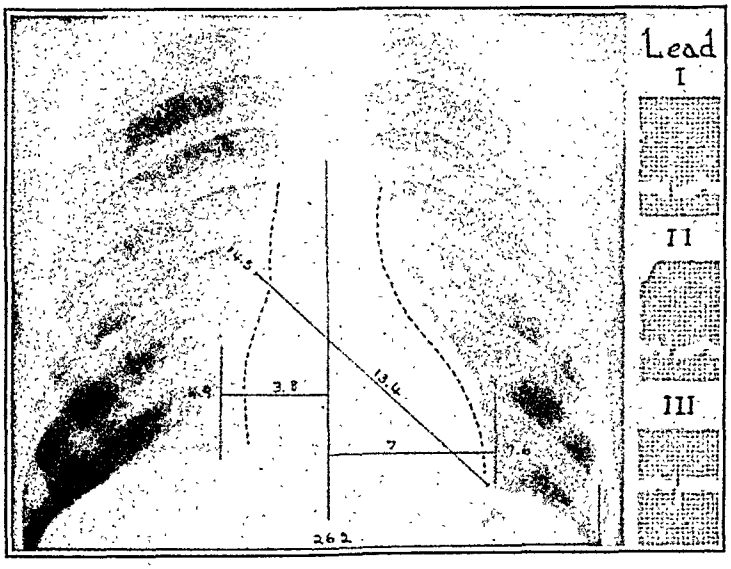

FIG. 13.—CASE 13.

DATE	HEMOGLOBIN, GM. PER 100 C.C.	CARDIO-THORACIC RATIO	PREDICTED TRANSVERSE DIAMETER HODGES & EYSTER	ACTUAL TRANSVERSE DIAMETER
7/10	4.3	47.6%	10.3 cm.	12.5 cm.
8/16	10.8	41.2%	10.5 cm.	10.8 cm.

Electrocardiogram: Sinus rhythm, rate 75, normal electrocardiogram.

mitral area. A_2 and P_2 were normal. The lungs gave to a marked degree the phenomena of hyperfunctional inflation. There was slight pitting edema of the ankles. (There was a weight reduction of 6 pounds during the first week in the hospital due to edema loss.)

Laboratory Data.—Hemoglobin in grams per 100 c.c., 3.7; erythrocytes in millions, 2.19; leucocytes in thousands, 5.85. Feces: ova, *Uncinaria americana, Trichocephalus dispar,* and cysts of *Endameba histolytica.* Serum proteins: albumin, 1.8 gm. per cent; globulin, 1.9 gm. per cent; cholesterol, 90 mg. per 100 c.c. Electrocardiogram, Fig. 12; vital capacity, Table III.

CASE 13.—J. V., a native man, aged forty-two, who complained of headache, vertigo, and edema of the ankles, was admitted July 10, 1935. He had been without work for two weeks, but before this he had worked regularly ten hours a day as a laborer on a coffee plantation.

Physical Examination.—The man was poorly developed and undernourished and mentally and physically very sluggish. There was marked pallor of the skin and mucous membranes. His weight was 90 pounds; height, 61 inches. Arteries showed very slight sclerosis. Pulse had a wide excursion, rate 68 per minute and rhythmic; blood pressure, systolic 110, diastolic 60. The veins were large and full, but the jugulars did not pulsate above a normal level. Heart (Fig. 13): The first sound was increased in intensity at the apex, and there was an inconstant systolic murmur heard at the mitral area. A_2 was slightly amphoric in quality; P_2 was normal in

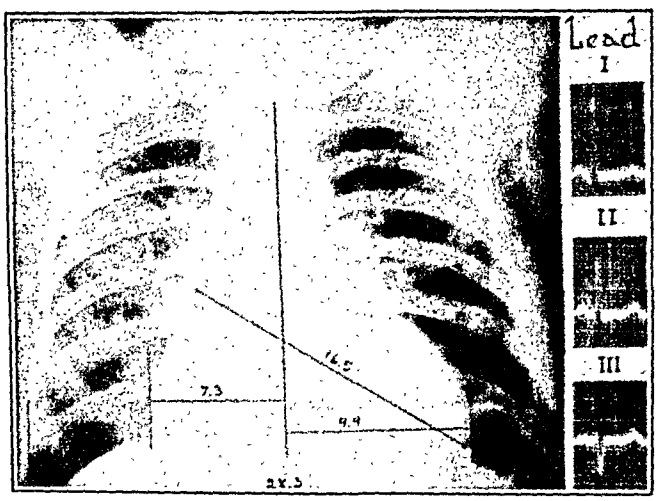

FIG. 14.—CASE 14.

DATE	HEMOGLOBIN, GM. PER 100 C.C.	CARDIO-THORACIC RATIO	PREDICTED TRANSVERSE DIAMETER HODGES & EYSTER	ACTUAL TRANSVERSE DIAMETER
7/3	4.9	60.0%	11.3 cm.	17.2 cm.
7/29	death and autopsy			

Electrocardiogram: Sinus rhythm, rate 70, electrical axis, left preponderance.

quality and intensity. The thorax was markedly emphysematous in shape; yet expansion was equal and normal. The lungs gave to a marked degree the phenomena of hyperfunctional inflation. There was slight pitting edema of the ankles.

Laboratory Data.—Hemoglobin in grams per 100 c.c., 4.3; erythrocytes in millions, 1.86; leucocytes in thousands, 8.3. Feces: ova, *Uncinaria americana.* Serum proteins: albumin, 1.4 gm. per cent; globulin, 2.1 gm. per cent; cholesterol, 83 mg. per 100 c.c. Electrocardiogram, Fig. 13; vital capacity, Table III.

CASE 14.—M. S., a native man, aged forty-five years, who complained of tinnitus, breathlessness with fast walking, and fatigability, was admitted July 2, 1935. He stated that he fainted frequently. He had been regularly at work as a laborer on a farm from 7:00 A.M. until 4:30 P.M. with one hour's rest at midday. He gave no history of any past illness except that at different intervals he had had chills which were promptly relieved by the taking of quinine.

Physical Examination.—The man was undernourished and mentally and physically very sluggish. His weight was 119 pounds; height, 64 inches. There was marked pallor of the skin and mucous membranes, and the skin was wrinkled and old in appearance. The arteries were soft and compressible. The pulse wave had a wide excursion, rate 56 per minute and rhythmic; blood pressure was systolic 118, diastolic 65. The veins were large and full but the jugulars did not pulsate above the normal level. Heart (Fig. 14): There were no thrills, and the sounds were normal. There was heard an inconstant systolic murmur when the patient was recumbent which disappeared when he sat up. A_2 and P_2 were equal and normal in quality and intensity. The thorax was markedly emphysematous in shape; yet expansion was equal and normal. The lungs gave to a marked degree the phenomena of hyperfunctional inflation. There was no edema.

Laboratory Data.—Hemoglobin in grams per 100 c.c., 4.6; erythrocytes in millions, 2.53; leucocytes in thousands, 3.8. Feces: ova, *Uncinaria americana.* Serum proteins: albumin, 4.04 gm. per cent; globulin, 1.4 gm. per cent; cholesterol, 90 mg. per 100 c.c. Electrocardiogram, Fig. 14; vital capacity, Table III.

The patient was put on the usual treatment, and he showed progressive and rapid improvement. His weight increased so that on July 19 it was 133 pounds and on July 23 it was 138¼ pounds without edema. The impression was that the patient was making rapid and satisfactory improvement, for the hemoglobin had increased to 6.3 gm. per 100 c.c. and the erythrocytes to 3.14 millions. The only significant changes noted on July 23 were that his pulse had become increasingly rapid and that the blood pressure had risen to systolic 140 and diastolic 112, even though he was confined to the ward and was spending most of the time recumbent on the bed.

The next day it was noted that overnight he had become orthopneic, having developed marked signs of congestive heart failure, consisting of great distention of all the veins of the neck and extremities; moist râles were heard throughout both lungs; the liver edge was 5 cm. below the costal margin and distinctly tender; and there was pitting edema of the ankles. Examination of the heart showed the rate to be 128 with a normal rhythm. The heart sounds were not unusual, and there was no gallop rhythm. The blood pressure was systolic 146 and diastolic 118. An electrocardiogram was made, and it showed no change in the QRS complex and a sinus tachycardia of 131 and was otherwise normal. It was evident that something had precipitated suddenly a very severe degree of heart failure of the congestive type. From July 24 to 29 he received intravenously six ampules of strophanthin and 0.5 gm. of powdered digitalis. On the night of July 25 a phlebotomy was done and 350 c.c. of blood were removed. On July 26 he showed much clinical improvement, and the phenomena of heart failure had lessened materially so that he could remain reasonably comfortable on a back rest. On the morning of July 29 his clinical improvement was striking. He ate a normal breakfast, but twelve minutes after he finished his breakfast he died suddenly.

Autopsy Report.—Gross: The specimen consisted of a human heart and a piece of the lungs. The fragment of lung measured 6 cm. in length, 3 cm. in width, and 2 cm. in thickness. It was covered by smooth glistening pleura, and the pulmonary parenchyma showed but slight congestion and edema only. The heart weighed 630 gm. The right auricle formed the right upper outer anterior border of the heart. The right ventricle was moderately dilated and formed slightly more than two-thirds of the anterior surface. The epicardium overlying the conus presented an area of thickening 2.5 cm. in diameter. Elsewhere it was smooth and glistening. The epicardial fat was quite abundant. The myocardium was reddish brown and of normal consistence. No evidence of "tigering" was found. There was moderate hypertrophy and slight dilatation of all chambers. The dilatation was more pronounced in the conus portion of the right ventricle and the outflow tract of the

left. The papillary muscles were quite large, hypertrophied, and prominent. The trabeculae carneae were also large and prominent. The foramen ovale was closed. The endocardium of the right auricle was normal. The tricuspid ring was not dilated. The tricuspid valve showed no abnormalities. Hypertrophy of the right ventricle was equally pronounced as in the left. The pulmonic valve showed slight fenestration at the edges. The proximal portion of the pulmonic trunk was included and showed no abnormalities. In the distal portion of the outflow tract of the left ventricle there was slight patchy subendocardial fibrosis. The aortic valve showed pronounced fenestration at the edges. The mitral valve was essentially normal. The endocardium of the left auricle was slightly thickened and opaque. The coronary arteries arose just below the highest level of the aortic commissures; they were quite straight and widely patent. In the proximal portion of the large branches occasional flat atheromatous plaques, which measured from 5 to 8 mm. in the main diameter, were found. Measurements: A 7, P 7, M 10, T 12, LV 1.5, RV 0.5 to 0.8 cm.

Microscopic: Right auricle: The muscle fibers were moderately hypertrophied. The striations of the fibers were considerably blurred, and the lipochrome pigment was not increased. The intervening stroma was slightly edematous. The section included the right coronary artery, the intima of which was slightly and uniformly thickened.

Right ventricle: Conus portion: The epicardium showed a mild sprinkling of round cells. At one point it was slightly thicker and revealed an increased number of vessels surrounded by a small amount of dense connective tissue, the seat of slight to moderate round cell infiltration. The myocardium showed moderate hypertrophy of the muscle fibers, slight fatty infiltration, and slight edema of the stroma in part, as well as several small, widely separated foci of round cells.

Middle of intraventricular septum: The endocardium showed a mild sprinkling of round cells. The descending branch of the left coronary artery showed very slight intimal thickening. Hypertrophy of the muscle fibers was not as pronounced. No changes of significance were found in the stroma. The striations of the fibers were considerably blurred and the lipochrome pigment was not increased.

Left ventricle: Upper portion of the interventricular septum beneath septum lucidum: The changes in the fibers were as before. The hypertrophy was pronounced. At one point there was a small area of replacement fibrosis, in part or completely, of some of the fibers, and at another area there was slight infiltration of the stroma by a small number of polymorphs and eosinophiles.

Apex: Left ventricle: The stroma was slightly edematous and at one point showed infiltration by a few polymorphs, a few mononuclears, and several eosinophiles. The muscle fibers were considerably hypertrophied and showed blurring of the striations but no increase of lipochrome pigment. The epicardium showed a mild sprinkling of round cells.

Anterolateral wall of right ventricle at middle: The epicardium showed a mild sprinkling of round cells. The muscle fibers were as before. In the stroma there were several small foci of round cell infiltration. There were also several small foci of replacement or interstitial fibrosis in the myocardium.

Left auricle: There were several sharply defined foci of interstitial round cell infiltration of the myocardium, very slight hypertrophy of the muscle fibers and slight fatty infiltration of the myocardium. The endocardium was moderately thickened throughout, but showed no cellular infiltration. The stroma of the myocardium was slightly edematous.

Aorta: The intima showed a few small areas of localized thickening. In the deeper portions of the media there were several small, endothelium-lined vessels surrounded by a small group of round cells and a few polymorphs. In the adventitia

there was a large area of diffuse round cell infiltration. A small number of large mononuclear cells were admixed with these cells.

Lungs (two sections): There was slight congestion, slight edema, slight thickening of the wall of some of the alveoli, and a slight to moderate number of scattered "heart failure" cells. Some of the alveoli were collapsed, and a moderate number were slightly dilated. No significant changes were observed in the blood vessels.

Conclusions: Cardiac hypertrophy; fibrosis of myocardium, slight; arteriosclerosis of coronary arteries, slight; and chronic passive congestion of lung.*

CASE 15.—P. S., a native man, aged forty-five years, who complained of weakness and pain of two years' duration located in a postoperative inguinal hernia scar, was admitted July 2, 1935. He had not worked since the operation, but frequently walked five to six miles to visit his sister.

Physical Examination.—He was a fairly well-nourished man who was mentally and physically sluggish. The skin and mucous membranes showed moderate pallor. His weight was 132 pounds; height, 65 inches. Arteries were normal. Pulse rate was 66 per minute and rhythmic; blood pressure was systolic 120, diastolic 66.

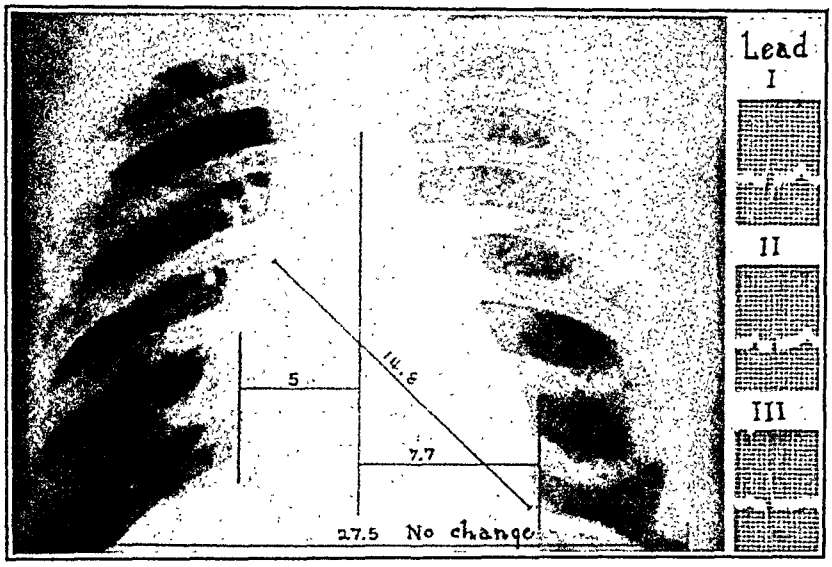

FIG. 15.—CASE 15.

DATE	HEMOGLOBIN, GM. PER 100 C.C.	CARDIO-THORACIC RATIO	PREDICTED TRANSVERSE DIAMETER HODGES & EYSTER	ACTUAL TRANSVERSE DIAMETER
7/2	6.0	46.2%	11.7 cm.	12.7 cm.
8/15	11.6	46.2%	12.1 cm.	12.7 cm.

Electrocardiogram: Sinus rhythm, rate 79, normal electrocardiogram.

Veins were normal. Heart (Fig. 15): There was a systolic murmur heard in recumbency at the mitral area. A_2 and P_2 were normal in quality and intensity. The thorax was slightly emphysematous in shape; yet expansion was equal and normal. The lungs gave to a slight degree the phenomena of hyperfunctional inflation.

Laboratory Data.—Hemoglobin in grams per 100 c.c., 6.0; erythrocytes in millions, 3.21; leucocytes in thousands, 6.6. Feces: ova, *Uncinaria americana*, and whipworm. Serum proteins: albumin, 3.4 gm. per cent; globulin, 1.9 gm. per cent; cholesterol, 111 mg. per 100 c.c. Electrocardiogram, Fig. 15; vital capacity, Table III.

*I wish to acknowledge my indebtedness to Dr. Alberto Rivera, a member of the staff of the Department of Pathology of the School of Tropical Medicine, for his report on the pathological study of the heart, lungs and aorta of Patient 14 who died while under observation.

CASE 16.—A. R., a native woman aged forty-five years, who complained of vertigo, breathlessness, headache, and fatigue, was admitted July 3, 1935. She did all the domestic work for a family of eight. She was the mother of twelve children born at full term; seven were then living.

Physical examination revealed a poorly nourished, physically active woman. The skin and the mucous membranes were pale, and the skin was prematurely wrinkled and aged. Arteries were normal. Pulse rate was 80 per minute and rhythmic; blood pressure was systolic 134, diastolic 80. Veins were normal. Heart (Fig. 16): There were no thrills and the sounds were normal. A_2 and P_2 were normal in quality and intensity. The vessels of the optic fundi were normal. The thorax was markedly emphysematous in shape; yet expansion was normal and equal. The lungs gave to a marked degree the phenomena of hyperfunctional inflation.

Laboratory Data.—Hemoglobin in grams per 100 c.c., 4.4; erythrocytes in millions, 2.91; leucocytes in thousands, 4.1. Feces: ova, *Uncinaria americana*, *Ascaris lumbricoides*, and whipworm. Serum proteins: albumin, 5.2 gm. per cent; globulin, 1.2 gm. per cent; cholesterol, 77 mg. per 100 c.c. Electrocardiogram, Fig. 16; vital capacity, Table III.

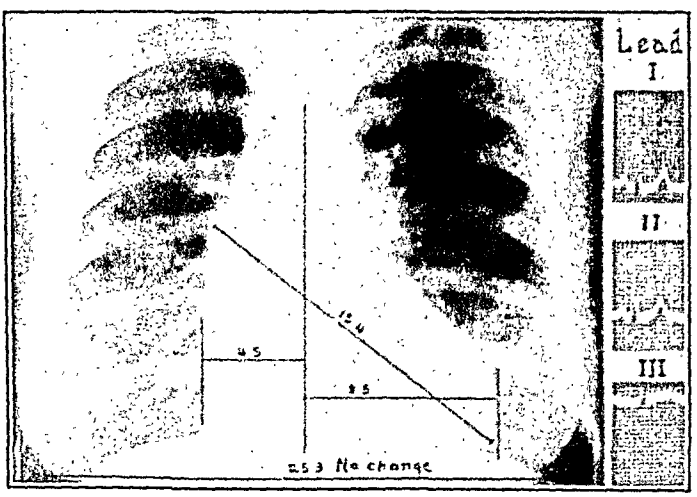

FIG. 16.—CASE 16.

DATE	HEMOGLOBIN, GM. PER 100 C.C.	CARDIO-THORACIC RATIO	PREDICTED TRANSVERSE DIAMETER HODGES & EYSTER	ACTUAL TRANSVERSE DIAMETER
7/3	4.4	51.0%	10.6 cm.	13.0 cm.
8/15	12.1	51.0%	11.2 cm.	13.0 cm.

Electrocardiogram: Sinus rhythm, rate 94, electrical axis, left preponderance.

CASE 17.—S. M., a native man, aged forty-eight years, who complained of vertigo, weakness, epigastric distress, stiff joints, and recurrent diarrhea, was admitted July 2, 1935. His symptoms were of two years' duration but had recently increased in severity. He worked as a laborer approximately half time on a sugar cane farm.

Physical examination showed a poorly nourished, prematurely aged man who was mentally and physically sluggish. The skin and mucous membranes were pale. His weight was 123 pounds; height, 66 inches. Arteries were normal. Pulse rate was 74 per minute and rhythmic; blood pressure was systolic 116, diastolic 54. The veins were normal. Heart (Fig. 17): The first and second sounds were normal, and there were no murmurs. The thorax was slightly emphysematous in shape; yet expansion was normal and equal. The lungs gave to a slight degree the phenomena of hyperfunctional inflation. There was slight pitting edema of the ankles.

Laboratory Data.—Hemoglobin in grams per 100 c.c., 6.5; erythrocytes in millions, 2.47; leucocytes in thousands, 6.4. Feces: ova, *Uncinaria americana*, cysts of *En-*

dameba histolytica. Serum proteins: albumin 4.1 gm. per cent; globulin, 1.3 gm. per cent; cholesterol, 105 mg. per 100 c.c. Electrocardiogram, Fig. 17; vital capacity, Table III.

CASE 18.—J. M., a native man, aged forty-nine years, who complained of pains in the legs, fatigue, and substernal aching induced by physical effort, was admitted

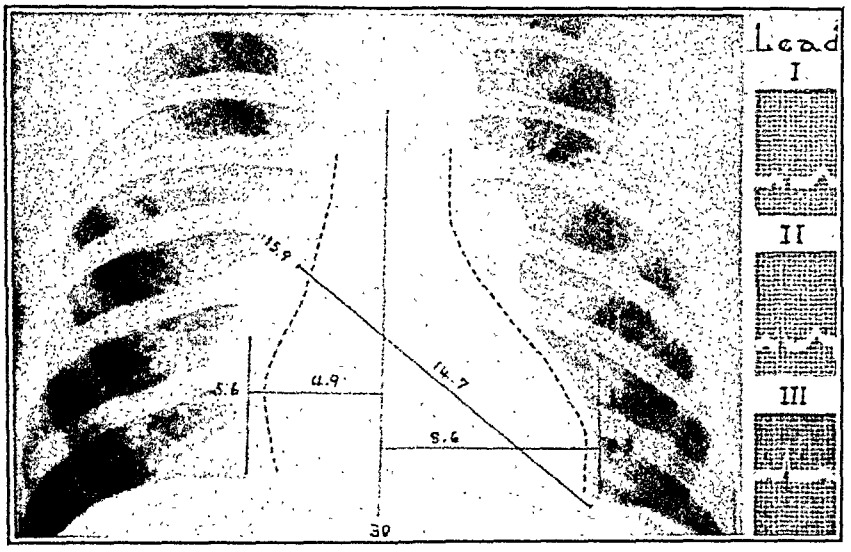

FIG. 17.—CASE 17.

DATE	HEMOGLOBIN, GM. PER 100 C.C.	CARDIO-THORACIC RATIO	PREDICTED TRANSVERSE DIAMETER HODGES & EYSTER	ACTUAL TRANSVERSE DIAMETER
7/2	6.5	49.8%	11.2 cm.	14.9 cm.
8/16	11.8	45.0%	11.5 cm.	13.5 cm.

Electrocardiogram: Sinus rhythm, rate 75, normal electrocardiogram.

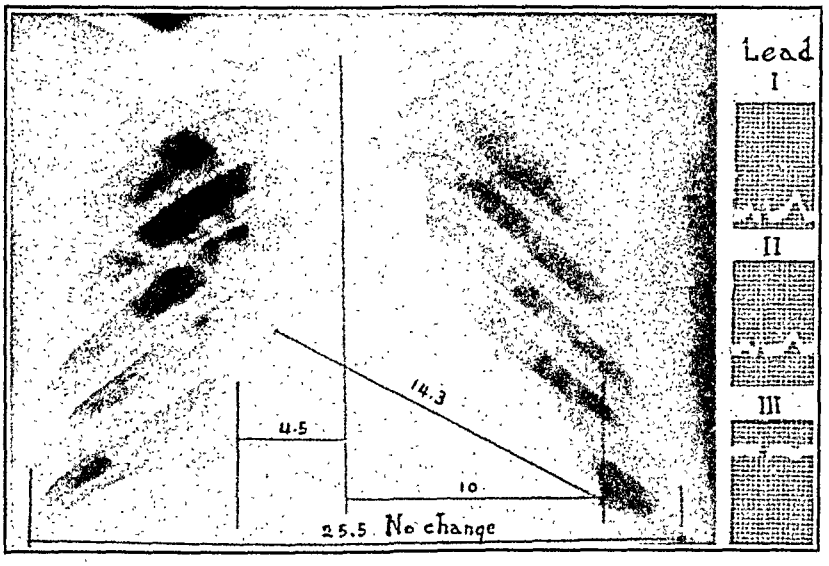

FIG. 18.—CASE 18.

DATE	HEMOGLOBIN, GM. PER 100 C.C.	CARDIO-THORACIC RATIO	PREDICTED TRANSVERSE DIAMETER HODGES & EYSTER	ACTUAL TRANSVERSE DIAMETER
7/4	4.4	56.8%	10.8 cm.	14.5 cm.
8/15	11.8	56.8%	10.9 cm.	14.5 cm.

Electrocardiogram: Sinus rhythm, rate 85, electrical axis, left preponderance.

July 4, 1935. The significance of the subjective complaints can be judged by the fact that he worked regularly ten hours a day as a laborer on a sugar cane farm.

Physical Examination.—The patient was an undernourished prematurely aged man whose mental and physical reactions were sluggish. There was marked pallor

TABLE I

THE VELOCITY OF BLOOD FLOW, ARM-TO-CAROTID, AND CRUDE PULMONARY REACTION TIME

CASE	AGE	DATE	HEART RATE PER MIN.	BLOOD PRESSURE		VENOUS PRESSURE (MM. H_2O)	CYANIDE CIRCULATORY TIME			HEMOGLOBIN (GM. PER 100 C.C.)	MG. PER KG. OF CYANIDE	
				SYSTOLIC (MM. HG)	DIASTOLIC (MM. HG)		ARM-TO-CAROTID (SEC.)	CRUDE PULMONARY (SEC.)	VENOUS (SEC.)		ARM-TO-CAROTID	CRUDE PULMONARY
3	10	7/26	110	110	45	90	10.0	6.0	4.0	3.6	0.103	0.077
		8/15	88	100	55	85	14.2	9.0	5.2	11.3		
4	15	7/ 3	104	105	55	80	12.5	7.2	5.3	2.6	0.165	0.139
		7/15	96	115	60	75	12.2	8.4	3.8	4.9		
		8/13	88	105	58	75	14.2	9.1	5.1	11.8		
5	23	7/10	62	95	45	40	19.0	10.3	8.7	6.9	0.158	0.121
		8/ 1	64	98	60	38	16.0	11.1	4.9	7.3		
		8/16	60	100	58	35	18.0	12.2	5.8	9.5		
6	23	7/ 4	79	130	50	55	13.5	8.1	5.4	4.0	0.126	0.101
		7/15	88	130	65	50	12.5	9.4	3.1	6.0		
		7/31	86	125	65	50	15.4	11.2	4.2	8.9		
7	25	7/ 2	74	124	48	92	12.5	8.5	4.0	4.9	0.084	0.063
		8/ 1	60	120	55	80	16.6	10.8	5.8	8.9		
		8/16	62	122	64	65	17.2	11.0	6.2	11.1		
8	28	7/11	62	110	60	55	15.5	10.5	5.0	6.8	0.200	0.152
		7/29	66	100	65	50	17.0	11.6	5.4	8.7		
		8/16	68	104	65	50	18.4	12.5	5.9	11.6		
9	30	7/ 4	86	110	55	55	16.5	11.3	5.2	3.7	0.152	0.142
		7/17	70	125	65	50	15.8	11.6	4.2	7.5		
		8/12	70	126	70	50	18.2	12.4	5.8	10.7		
10	35	7/13	90	100	65	68	14.6	10.4	4.2	3.4	0.154	0.108
		7/31	76	95	60	70	16.0	11.2	4.8	7.8		
		8/15	68	100	60	70	17.2	11.6	5.6	10.1		

TABLE I—CONT'D

11	35	7/22	78	118	60	35	11.0	7.0	4.0	4.3	0.132	0.114
		7/31	88	110	60	40	12.2	8.6	3.6	7.1		
		8/15	84	120	65	80	14.2	9.4	4.8	8.7		
12	40	7/10	74	105	55	38	19.5	11.4	8.1	3.7	0.127	0.102
		8/ 1	56	118	75	30	18.6	12.0	6.6	7.2		
		8/16	52	146	82	30	19.6	14.2	5.4	11.2		
13	42	7/10	68	110	60	42	16.5	9.1	7.4	4.3	0.224	0.171
		7/25	56	125	78	42	17.6	12.2	5.4	6.4		
		8/16	66	122	70	42	19.5	14.5	5.0	10.2		
14	45	7/ 3	56	118	65	45	22.0	15.0	7.0	4.9	0.155	0.129
		7/17	68	130	80	40	17.2	11.5	5.7	5.5		
		7/29	(Death 7:30 A.M.)									
15	45	7/ 2	66	120	70	36	21.0	13.2	7.8	6.0	0.117	0.100
		7/31	78	105	60	55	16.2	13.0	3.2	8.7		
		8/15	58	118	65	60	19.2	15.4	3.8	11.6		
16	45	7/ 3	82	134	80	45	16.2	11.6	4.6	4.4	0.135	0.117
		7/31	91	160	95	45	16.4	12.8	3.4	10.1		
		8/15	86	165	105	45	18.0	14.2	3.8	12.1		
17	48	7/ 2	66	115	65	72	21.0	12.0	9.0	6.5	0.128	0.107
		8/ 1	62	128	75	72	18.5	12.6	5.9	8.7		
		8/16	68	126	75	65	20.0	13.4	6.6	11.8		
18	49	7/ 4	76	120	65	72	19.1	14.0	5.1	4.4	0.142	0.133
		7/17	62	120	70	60	16.6	13.2	3.4	7.8		
		8/15	64	120	75	50	19.0	14.2	4.8	11.8		

of the skin and mucous membranes. His weight was 99 pounds; height, 60 inches. Arteries were normal. The pulse wave had a wide excursion, rate 76 per minute and rhythmic; blood pressure was systolic 120, diastolic 65. The veins were large, but the jugulars did not pulsate above the normal level. Heart (Fig. 18): There was a loud systolic murmur heard at the mitral area, not influenced by posture, which murmur was transmitted toward the left axilla. A_2 and P_2 were normal. The vessels of the optic fundi were normal. The thorax was markedly emphysematous in shape; yet expansion was equal and normal. The lungs gave to a marked degree the phenomena of hyperfunctional inflation.

Laboratory Data.—Hemoglobin in grams per 100 c.c., 4.4; erythrocytes in millions, 2.3; leucocytes in thousands, 7.3. Feces: ova, *Uncinaria americana.* Serum proteins: albumin, 2.4 gm. per cent; globulin, 2.4 gm. per cent; cholesterol, 76 mg. per 100 c.c. Electrocardiogram, Fig. 18; vital capacity, Table III.

SUMMARY OF OBSERVATIONS

Pulse Rate (Table I).—Patients 1 and 2, aged six and eight years, were heavily infested with the *Necator americanus* parasites which produced an extreme anemia in a comparatively brief period. The average resting pulse rate in each of these children was 127 and 129, respectively, per minute. This rate fell gradually, reaching an average of 102 per minute when the hemoglobin increased to 5 gm. per 100 c.c. and finally reaching a normal rate when the hemoglobin reached a level of 12 gm. per 100 c.c. Patients 3 and 4, aged ten and fifteen years, had moderate tachycardia, 110 and 104 per minute, respectively, before treatment was begun. With these exceptions, one is impressed with the remarkably slow pulse rates in spite of the degree of anemia. The average resting pulse rate before treatment was 73 per minute, and at the conclusion of the period of observation it was 67 per minute.

Venous Pressure (Table I).—Without an exception the venous pressures were normal, and there was no significant change in the height of the pressures at the beginning and at the conclusion of the period of observation. This is in confirmation of the clinical observations, for, though the superficial veins appeared full and in many instances abnormally great in size, they did not pulsate at abnormal levels nor fail to empty when brought to the level of the right auricle.

Arterial Blood Pressure (Table I).—The systolic and diastolic blood pressures were all low normals before treatment was started. The lowest systolic pressure was 95 mm. Hg, and the highest systolic pressure was 130 mm. Hg. The lowest diastolic pressure was 45 mm. Hg, and the highest diastolic pressure was 80 mm. Hg. There was a rise of the systolic blood pressure varying from 11 to 41 mm. in six subjects. The diastolic blood pressure increased more than 5 mm. in eleven and increased 5 mm. or less in five. The most significant change in the blood pressure occurred in Case 14, with a rise of the systolic pressure from 118 to 146 and the diastolic pressure from 65 to 118 mm., and in Case 16, with a rise of the systolic pressure from 130 to 165 and the diastolic pressure from 80 to 105 mm.

Circulation Time (Table I).—Cases 1 and 2 were not recorded. The other sixteen patients were first studied after resting in bed in the hospital for periods varying from twenty-four to thirty-six hours. Each recorded rate of circulation time represents the average result obtained from two or more observations after the effective dose for each patient had been previously determined. The arm-to-carotid reaction time of cyanide in normal subjects recorded by previous observers[2] varied from 9 to 21 sec., the average time being 15.6 sec. The crude pulmonary reaction time in normal subjects averaged 10.6 sec., ranging from 7 to 14 sec. In this study the arm-to-carotid reaction time varied from 10 to 22 sec., the average time being 16.2 sec., and the crude pulmonary reaction time varied from 6 to 15 sec., the average being 10.3 sec. At the completion of the period of observation, when the hemoglobin had increased from an average of 4.6 gm. per 100 c.c. to 10.8 gm. per 100 c.c., the arm-to-carotid reaction time varied from 14.2 sec. to 20 sec., the average being 17.4 sec.; and the crude pulmonary reaction time varied from 9 to 15.4 sec., the average being 12.2 sec.

The optimal dose of cyanide per kilogram of body weight recorded by previous observers[2] for normal subjects, arm-to-carotid route, varied from 0.07 to 0.19 mg., the average being 0.11 mg. The same observers noted that a dose sufficient to produce an abrupt, definite stimulation of respiration was constant in its effect and time of reaction. In this study the dose was increased until the reaction was definite, and the time of reaction constant and within the limits of not more than one second variation. In this group of subjects the optimal dose of cyanide, arm-to-carotid route, varied from 0.084 to 0.224 mg., the average being 0.144 mg. per kilogram. If one omits from the calculations of the average Cases 3 and 7, the figure for the optimal dose of cyanide is 0.151 mg. per kilogram. This omission is desirable to gain a true picture of the situation in chronic anemia because of the age of the patient in Case 3 and the rapid development of anemia in the patient in Case 7, resulting from extreme food deficiency.

Reaction to Exercise (Table II).—The reaction of the rate of blood flow, arterial blood pressure, and pulse rate to exercise was tested in fifteen patients after they had improved sufficiently for them to submit willingly to active physical effort and when the hemoglobin was at an average level of 7.1 gm. per 100 c.c. of blood. The exercise consisted of walking thirty feet on the level and then down and up twenty-six steps and back to the starting point. The pace was standardized by a trained assistant who set the speed at an average walking gait. The significant fact brought out by this observation is that exercise definitely increases the rate of blood flow, the systolic blood pressure, and the pulse rate. The average increase in rate of blood flow was 5.1 sec., or 31 per cent for the systolic blood pressure, 12 mm. Hg; and for the pulse rate, 23 beats per minute.

Pulmonary Apparatus.—In the case reports it is noted that the thoraces were emphysematous in shape and that the lungs presented the phenomena of compensatory inflation in varying degrees in all of the subjects. These were very striking physical findings and were similar in character to the thoracic shape noted in true emphysema; yet the breath sounds were identical in character with those observed over the normal lung in unilateral pneumonia or pleural effusion. The descriptive term "phenomena of compensatory hyperventilation" accurately designates the true significance of these phenomena. The physical findings are of peculiar interest for they are similar in character to those

TABLE II

REACTION TO EXERCISE

CASE	BASILIC BLOOD FLOW RATE		BLOOD PRESSURE				PULSE		HEMOGLOBIN GM. PER 100 C.C.
			SYSTOLIC		DIASTOLIC				
	BEFORE (SEC.)	AFTER (SEC.)	BEFORE	AFTER	BEFORE	AFTER	BEFORE	AFTER	
3	11.4	6.2	105	112	50	55	105	132	6.9
4	12.6	7.4	115	120	60	55	80	110	4.9
5	16.0	13.5	95	110	55	60	64	78	6.8
6	15.4	9.0	130	135	65	75	88	98	6.9
7	16.6	12.5	122	132	60	56	64	88	7.2
8	17.2	12.6	95	115	65	60	60	89	7.8
9	15.2	9.4	125	140	62	65	71	82	7.8
10	16.0	11.4	100	105	65	65	84	106	7.8
11	14.5	8.2	120	145	65	70	88	132	7.1
12	20.0	14.5	146	148	82	80	44	82	7.2
13	17.5	14.6	125	135	78	80	58	100	6.3
15	16.4	11.8	105	120	58	65	78	92	7.5
16	16.4	10.6	160	170	95	100	92	120	7.5
17	18.6	14.5	128	130	75	80	72	81	7.2
18	17.0	12.6	120	155	70	75	62	68	7.8
Average	16.4	11.3	119	131	67	69	74	97	7.1

noted by Barcroft[6] in the Cholos living at high altitudes in the Andes Mountains, where oxygen tension of the atmosphere is markedly lowered. He emphasizes the fact that the chests of these natives are large and deep and markedly emphysematous in appearance. He compares the chest width of the natives with the members of his expedition by dividing the mean chest measurements in centimeters of x-ray films of the thorax by the height of the body in centimeters, and by multiplying the resulting figure by 100. The percentage ratio for the members of the expedition was 15 cm. and for the natives, 16.7 cm. A similar ratio calculated for this group of patients shows the average percentage to be 17.4 cm. (Table III).

Barcroft[6] and his associates did not estimate the vital lung capacity of the Cholo natives; yet he concluded, "That a greater quantity of air ventilates the lung at high altitudes than at low ones seems to be beyond doubt." In this study spirometer estimations of vital capacity were

made routinely on all patients except in Cases 1 and 2. In calculating the normal vital capacity the expired air volume of 2,376 c.c. per square meter of body surface[7] was used, and the same value was chosen for both male and female subjects for the reason that the native Puerto Rican woman engages in a considerable amount of physical labor. In every instance the vital lung capacity (Table III) was greater than the calculated normal, with the exception of Cases 6 and 14. In Case 6 the procedure invariably caused in the patient an emotional disturbance; while in Case 14 the patient had an extreme degree of cardiac hypertrophy (630 gm.), which mechanically lessened vital capacity.

TABLE III

VITAL LUNG CAPACITIES AND CHEST-HEIGHT PERCENTAGE RATIOS

CASE	VITAL CAPACITY		HEIGHT (CM.)	CHEST (CM.)	MEAN CHEST MEASUREMENTS FROM X-RAY FILMS PER 100 CM. OF HEIGHT
	PREDICTED (C.C.)	OBSERVED (C.C.)			
3	1,591	1,680	110.0	19.5	17.77
4	2,352	2,800	125.0	23.8	19.04
5	3,944	4,600	167.5	28.5	17.01
6	3,231	3,120	157.5	24.2	15.36
7	3,611	3,950	166.3	26.3	15.81
8	3,445	4,750	160.0	28.0	17.50
9	2,620	2,740	145.0	24.0	16.55
10	2,970	3,750	142.5	26.0	18.24
11	3,112	3,550	142.5	26.0	18.24
12	4,086	5,100	167.5	31.8	18.98
13	3,183	3,900	152.5	26.2	17.18
14	3,706	3,400	160.0	28.3	17.68
15	3,944	4,400	162.5	27.5	16.92
16	2,580	2,650	147.5	25.3	17.15
17	3,872	4,150	165.0	30.0	18.18
18	3,256	3,460	150.0	25.5	17.00
Average	3,219	3,625	151.3	26.1	17.41

Heart Size.—The size and the contour of the heart were determined with the aid of teleroentgenograms taken with the subject in the erect position. Two or more studies were made on each patient. Each figure is composed of the first and the last teleroentgenograms, the latter being superimposed on the first and being indicated by the dotted line. As some degree of accuracy is sacrificed by the adoption of this technic for illustrative purposes, each figure is accompanied by the actual measurements of the original.

In estimating the size of the heart, the transverse diameter of the cardiac silhouette has been calculated by both Danzer's cardiothoracic ratio,[8] and the prediction formula of Hodges and Eyster.[9]

That the cardiothoracic ratio could not be used with customary confidence because of the increase of the transverse thoracic diameter existing in these subjects became apparent at the beginning of the study; yet the measurements show that 10, or 55.5 per cent, had ratios of 50 per

cent or more. Of the eight subjects having a cardiothoracic ratio of less than 50 per cent, six showed a reduction of the ratio, indicating that the heart had become smaller and confirming the unreliability of this method of estimating normal heart size.

Hodges and Eyster[9] concluded that the chances are three to one favoring pathological increase in heart size when the transverse diameter is wider than the predicted diameter by more than 0.5 cm. Bainton[10] has recently evaluated the prediction formula of Hodges and Eyster[9] and concluded that an increase of the transverse diameter of more than 1 cm. than the predicted normal indicated an enlarged heart.

In three of the patients (Cases 1, 2, and 3) the formula was not applicable because of the age and size of the patients, but in each of these the cardiothoracic ratio was so great—51.3 per cent, 54 per cent, and 58.8 per cent, respectively—that there can be no question of the existence of cardiac enlargement. In the remaining fifteen patients the transverse diameter was more than 1 cm. greater than the predicted normal in 100 per cent, with an average increase of 2.6 cm.

At the completion of the period of observation the transverse diameter remained larger by an average of 1.6 cm. than the predicted normal in 8 patients, larger by 0.5 cm. to 1 cm. in 5, and unchanged in 5. Included in the unchanged group is Case 3 with a cardiothoracic ratio of 51.3 per cent, with the result that a total of nine cases remain with hearts significantly greater in size than the predicted normal.

*Electrocardiograms.**—There occurred significant changes in the electrocardiogram in seven patients, or 38.8 per cent. In Case 3 (Fig. 3) there was an inverted P_3 and a sharply inverted T_3. The electrocardiogram remained unchanged; nevertheless the anemia was promptly relieved, and general clinical improvement was striking. The heart also remained unchanged in size which condition is contrary to the usual reaction noted in the other children studied. The probability of the existence of a congenital factor appears to be the most likely explanation for the persistence of the observed departure from the normal.

The patient in Case 6 (Fig. 6) had a prolonged P-R interval, 0.21 sec., and an inverted T_2 and T_3; "dropped" beats were clinically observed but were not recorded graphically. Through omission the electrocardiogram was not repeated, but the degree of heart-block lessened, for "dropped" beats were not noted clinically after the third day in the hospital. An unexplained fever of three days' duration was probably connected with the occurrence of heart muscle changes which temporarily impaired auriculoventricular conduction.

The patient in Case 7 (Fig. 7) showed an electrical axis indicating a right ventricular preponderance. There were no demonstrable pulmonic or cardiac lesions which might explain the electrocardiographic changes.

*The first electrocardiogram taken is used in the illustrations as no changes occurred with clinical improvement except reduction in heart rate.

The patients in Cases 5 (Fig. 5), 14 (Fig. 14), 16 (Fig. 16) and 18 (Fig. 18) showed electrical axes indicating left ventricular preponderance. These patients had an average increase in heart size of 3.8 cm. above the predicted normal, and in only one case—Case 5—was there a reduction in size following the relief of the anemia and clinical symptoms of hookworm disease.

DISCUSSION

When reserve mechanisms are required to meet average metabolic needs, the perfection of physiological integrity is immediately compromised. Compensation is never perfect, but it most nearly approximates perfection when the whole organism distributes evenly the burden of adjustment so that no one structure is more vulnerable than another.

An analysis of the data collected during this study shows that the ability of individuals having chronic parasitic anemia to accomplish a surprising amount of physical work with reasonable comfort and efficiency is due to many adjustment mechanisms widely distributed over those structures concerned with internal and external respiration.

There was an average increase of 12.7 per cent in the vital lung capacity which made possible efficient and adequate external respiration with a minimum range of respiratory effort and energy requirement. A greater amount of sodium cyanide was required to stimulate respiration than is necessary for normal individuals. This may be interpreted as indicating that the metabolic stimulants of respiration must accumulate in the blood of these individuals in higher concentration before there results an acceleration of and an increased depth in breathing. This lessened sensitivity of the central control of respiration operating in conjunction with an increased ventilating capacity of the lungs represents an especially useful integration of compensatory developments.

The velocity of blood flow in these patients was not increased when observations were done under conditions of rest. This is at variance with the findings of Fahr and Ronzone,[11] for they concluded that an increased rate of blood flow was the outstanding compensatory mechanism in severe anemias. It is to be appreciated that an increase in the velocity of blood flow is only one of the mechanisms available for augmenting the volume of circulating blood to a given area. The opening up of additional capillaries, which increases the effective cross-section of the vascular tubing, is an even more usual mechanism and one which is constantly recurring in the normal person to meet increased local demands for blood. It is brought into operation by chemical stimuli locally formed as a result of changes in local metabolism, the stimulus arising from the physiological need for more oxygen either when metabolism is increased or when oxygen want occurs. The evidence points to the conclusion that, under conditions of rest, the greater blood volume to the

vital areas necessitated by the reduced oxygen-carrying capacity of the blood was in part accomplished in these patients by an increase in the number of functioning capillaries rather than an increase in the velocity of blood flow.

When they were exercised, the mechanisms operating in relatively acute anemias became active in meeting the increased demands of internal respiration. There was an average increase of 31 per cent in the rate of blood flow from the basilic vein to the carotid sinus. There was an average increase of the systolic blood pressure of 12 mm. Hg, without a corresponding increase in the diastolic blood pressure, indicating an augmented stroke volume which, in conjunction with an average increase in the pulse rate of 23 per minute, contributed jointly with the accelerated blood velocity toward bringing about a great increase in circulating blood volume. The fact that the diastolic blood pressures were relatively low and remained so after exercise indicates that the arterioles were dilated, and this explains the vascular mechanism which operated in supplying the necessary blood volume to the increased number of functioning capillaries.

The degree of pallor of the skin and mucous membranes occurring in hookworm anemia is too marked to be accounted for by the reduction in hemoglobin. It suggests that there is a reduction of the number of open capillaries in the surface areas, and a consequent shunting of the blood to the vascular beds of the internal structures. The observations of Stewart,[12] who showed that the peripheral volume flow was diminished, and of Fahr and Ronzone,[11] who showed that there was a lessening in caliber of the skin capillaries in severe anemias, lend support to the concept of a selective distribution of blood as aiding these individuals in solving their metabolic requirements for oxygen in the vital areas.

It was observed that the quantity of sodium cyanide per kilogram of body weight effective in producing respiratory stimulation was increased from the normal average of 0.111 mg. to 0.151 mg. (Cases 3 and 7 not included for obvious reasons). One may conclude from this evidence that in chronic anemia the tissues of the carotid sinus develop increased tolerance to the oxygen want caused by sodium cyanide. If this be true for the highly specialized centers of respiratory control, it is more than probable that less specialized tissues throughout the body are even more completely acclimatized to reduced oxygen supply.

The outstanding anatomical change occurring in parasitic anemia is cardiac enlargement. In this study there was found an increase in heart size in 100 per cent of the patients. The data indicate that the change in heart size was, in a few patients, due to reducible dilatation, in others to dilatation and hypertrophy, and in a third group to definite hypertrophy unassociated with reducible dilatation.

The earliest observations on the heart in anemia deal with cases of chlorotic anemia. Irvine[13] (1877) and Barrs[14] (1891) describe the occurrence of bruits in chlorotic individuals which were attributed to cardiac dilatation. Hersman[15] (1893) described murmurs which disappeared with a cure of the anemia, and Gautier[16] (1899) recorded his observations in 22 cases of chlorosis and found by percussion cardiac enlargement in 20. Cabot and Richardson[17] (1919) found cardiac hypertrophy in patients dying of pernicious anemia, in whom no other factor existed to account for the enlargement.

Goldstein and Boas[18] (1927) noted the occurrence of a functional diastolic murmur and cardiac enlargement in severe anemia. They conclude that cardiac dilatation as well as hypertrophy occurs not only in pernicious anemia, but also in severe secondary anemia.

Ball[19] (1931) was apparently the first to record a case of severe anemia studied with the aid of a teleroentgenogram, recording a reduction in heart size with the relief of anemia. Recently Bouchut and Froment[20] have emphasized the occurrence of cardiac hypertrophy in pernicious anemia. They attribute the changes to an increase in heart work resulting from the increase in the amount of blood passing through the heart per minute. They conclude that the primary compensating mechanism is cardiac dilatation but that hypertrophy supervenes if the anemia is of sufficient duration and severity.

Lunde and Schueller[21] (1910) produced cardiac enlargement in dogs by rendering the animals anemic, and Forman and Daniels[22] (1930), while studying the effect of certain foods on anemia in rats, observed that the hearts of those having low hemoglobin values were considerably larger than the hearts of normal animals. The heart weights of animals with hemoglobin values from 11 gm. to 14 gm. per 100 c.c. of blood were normal. When the hemoglobin values fell to 10 gm., the hearts were slightly hypertrophied; this became more marked as the degree of anemia increased. At the very low hemoglobin levels, from 2 gm. to 3 gm. per 100 c.c., the heart weights averaged approximately three times those of normal animals.

It is evident, therefore, that cardiac enlargement, dilatation, and eventually hypertrophy occur in animals in which anemia has been produced, and in human beings with various clinical types of anemia. In this study of parasitic anemia, one is impressed with the fact that changes in the heart, dilatation, and finally hypertrophy, are of great clinical importance in evaluating the effects of hookworm infestation on man. The primary cardiac dilatation may be classed as a physiological adjustment mechanism which disappears when the anemia is relieved; yet, if those factors which have necessitated the dilatation continue, there occurs hypertrophy of the myocardium which is not reducible and is definitely pathological in character. Since cardiac hypertrophy is rightly placed

in the category of organic heart disease, one is justified in classing chronic parasitic anemia as one of the important etiological factors in the causation of this condition.

CONCLUSIONS

I. In chronic hookworm anemia the following physiological adjustments occur:

a. An augmented vital lung capacity.

b. A diminished sensitivity of the central control of respiration to chemical stimuli.

c. An increased tolerance of the tissue cells to oxygen want.

d. Under conditions of rest no increased velocity of blood flow contributed significantly to the circulatory compensation for a reduced oxygen-carrying capacity of the blood.

e. There was indirect evidence that the demand for a greater circulating blood volume in the vital areas was met by a reduction in the volume of the peripheral blood flow with a corresponding selective shunting of blood to an increased number of functioning capillaries in the internal structures.

II. An irreducible result of prolonged hookworm anemia is cardiac hypertrophy. The heart of one patient who died while under observation weighed 630 gm.

I wish to acknowledge my indebtedness to the director, Dr. George W. Bachman, and the staff of the School of Tropical Medicine, San Juan, Puerto Rico; and to Dr. Ramon Suarez and the staff of the Hospital Mimiya, Santurce, Puerto Rico, for their cooperation and assistance in this study. Without their continued interest the completion of the project would not have been possible.

REFERENCES

1. Moritz, F., and von Tabora, D.: Ueber eine Methode, beim Menschen den Druch in oberflaechlichen Venen exakt zu bestimmen, Deutsches Arch. f. klin. Med. 98: 475, 1910.
2. Robb, George P., and Weiss, Soma: A Method for the Measurement of the Velocity of the Pulmonary and Peripheral Venous Blood Flow in Man, Am. Heart J. 8: 650, 1933.
3. Wintrobe, M. M.: The Erythrocyte in Man, Medicine 9: 195, 1930.
4. Porter, William B.: Liver Feeding in the Anemias Not of the Addisonian Type; Proceedings of the Medical Society of the District of Columbia, Oct. 16, 1929.
5. Rhoads, C. P., Castle, W. B., Payne, G. C., and Lawson, H. A.: Observations on the Etiology and Treatment of Anemia Associated With Hookworm Infection in Puerto Rico, Medicine 13: 317, 1934.
6. Barcroft, Joseph: The Respiratory Function of the Blood, Part I, Lessons Learned at High Altitudes, London, 1929, Cambridge University Press, pp. 43-45.
7. Blumgart, H. L., and Weiss, Soma: The Velocity of Blood Flow and Its Relation to Other Aspects of the Circulation in Patients With Pulmonary Emphysema, J. Clin. Investigation 4: 555, 1927.
8. Danzer, C. S.: The Cardio-Thoracic Ratio; An Index of Cardiac Enlargement, Am. J. M. Sc. 157: 513, 1919.
9. Hodges, F. J., and Eyster, J. A. E.: Estimation of Transverse Cardiac Diameter in Man, Arch. Int. Med. 37: 707, 1926.

10. Bainton, Joseph H.: The Silhouette of the Heart and the Aortic Arch, Orthodiagraphic Measurements, Am. Heart J. 8: 616, 1933.
11. Fahr, Geo., and Ronzone, Ethel: Circulatory Compensation for Deficient Oxygen Carrying Capacity of the Blood in Severe Anemias, Arch. Int. Med. 29: 331, 1922.
12. Stewart, G. N.: Blood Flow in Hands, Normal and Pathological, Harvey Lectures 8: 86, 1912.
13. Irvine, Pearson: On the Clinical Condition of the Heart and Vessels in Chlorosis, Lancet 1: 837, 1877.
14. Barrs, A. G.: Cardiac Bruits of Chlorosis, Am. J. M. Sc. 102: 347, 1891.
15. Hersman, C. F.: Temporary Mitral Insufficiency in Anemic Conditions, Internat. Med. Mag., Phila. 2: 341, 1893.
16. Gautier, E.: Ueber die morphologischen Veränderungen des Herzens bei der Cholorose auf Grunk klinischer Beobachtungen, Deutsches Arch. f. klin. Med. 62: 120, 1899.
17. Cabot, Richard C., and Richardson, Oscar: Cardiac Hypertrophy in Pernicious Anemia; Note on Nineteen Necropsies, J. A. M. A. 72: 991, 1919.
18. Goldstein, B., and Boas, E. P.: Functional Diastolic Murmurs and Cardiac Enlargement in Severe Anemias, Arch. Int. Med. 39: 226, 1927.
19. Ball, D.: Change in Size of Heart in Severe Anemia, Case Report, Am. Heart J. 6: 517, 1931.
20. Bouchut, L., and Froment L.: Les gros coeurs par anoxemie à propos des anemies pernicieuses compliquees d'hypertrophie et d'insuffisance cardiaques, Arch. d. mal. du coeur 27: 325, 1934.
21. Lunde, H., and Schueller, L.: Ueber die Wirkung Experimenteller Anaemien auf die Herzgroesse, Deutsches Arch. f. klin. Med. 101: 512, 1910.
22. Forman, Mary B., and Daniels, Amy L.: Effect of Nutritional Anemia on Size of the Heart, Proc. Soc. Exper. Biol. & Med. 28: 479, 1930-31.

ACUTE PERNICIOUS FORM OF BERIBERI AND ITS TREATMENT BY INTRAVENOUS ADMINISTRATION OF VITAMIN B_1

With Especial Reference to Electrocardiographic Changes*

Hirotoshi Hashimoto, M.D.
Tokyo, Japan

According to Aalsmeer and Wenckebach,[1] there exist a group of heart muscle disturbances with some characteristics common to them, occurring in deficiency diseases, such as beriberi and rickets, or in metabolic disturbances with decreased internal secretions, such as myxedema. Recently Walker[2] has demonstrated that a cardiac enlargement in myxedema is readily amenable to thyroid administration. Wenckebach pointed out that Moll, in Vienna, had observed in the rachitic heart a similar therapeutic effect with vigantol. Among the above cardiac diseases the beriberi heart appears to be the one which has been most extensively studied. However, there still remain some questions not adequately answered, particularly on the mechanism of the cardiac failure.

In beriberi there is cardiac enlargement with dilatation and hypertrophy, predominantly of the right side of the heart, in the absence of any remarkable histopathological changes in the myocardium. Digitalis and other usual cardiac remedies have but little effect upon the beriberi heart, while it responds very promptly to vitamin B. Furthermore, it has been supposed by Aalsmeer and Wenckebach[1] that even in the worst condition of failure the beriberi heart gives a perfectly normal electrocardiogram, which is suggestive of retained normal excitability and stimulus conduction in the absence of satisfactory contractility of the heart muscle.

Various hypotheses have been advanced to explain the mechanism of such a peculiar cardiac failure. Paralysis of the vagus nerve or of the respiratory muscles has been supposed to be responsible for this by various authors. After the vitamin theory had been established in an etiological study of beriberi, there came out another hypothesis, that a deficiency of vitamin B leads to a certain metabolic disturbance with resulting acidosis or water retention in tissues, which affects the cardiac muscle.

The water retention hypothesis, proposed by Aalsmeer and Wenckebach,[1] seems to be the most popular one, accepted and supported by others in recent years. Their opinion that the principal nature of the myocardial affection in beriberi might be water retention in muscle

*From the St. Luke's International Hospital, Tokyo.

cells, was mainly based upon electrocardiographic findings in beriberi of Aalsmeer and experimental data of de Boer, which had shown that the swelling of the heart muscle, caused by the water, reduces mechanically the contractile power of the muscle fibers, but at the same time the electrocardiogram may continue completely unchanged.

Aalsmeer and Wenckebach, therefore, contended that electrocardiograms of patients with beriberi were perfectly normal, except that the P-Q interval was shortened in some cases. There was no change in QRS complexes, except for right ventricular preponderance. The T-waves were perfectly normal. Scott and Herrmann,[3] from their study on patients with beriberi in Louisiana, reported that in their electrocardiograms there were small complexes, negative T-waves in Leads I and III, and some slurring or slight aberrations in the ventricular complexes, which they interpreted as evidences of definite myocardial changes. Keefer,[4] who had studied fifteen cases of beriberi with cardiac insufficiency in China, stated that in them there were no characteristic changes in their electrocardiograms, but there were some evidences of myocardial changes in a few. The rate was usually increased. Arrhythmia was not observed, except in one patient who had extrasystoles and bradycardia during convalescence. Right ventricular preponderance was present in two cases. The height of the ventricular complexes was low in four patients. In these patients, the voltage became higher during convalescence. In others, the waves which were high during the acute stage of the disease became lower as they improved. In three patients the P-R interval decreased during convalescence, and in one patient it increased. In five cases the T-waves were negative in Lead III. In one of these they became positive during the convalescence, and in two, positive waves became negative. In some cases during the acute stage, the T-waves in Lead II were high and became lower during recovery.

My personal experience in electrocardiographic examinations on Japanese patients with beriberi in past years agrees fairly well with the above statement of Keefer. Accelerated rates, some deviation of electric axis, and low or high voltages of auricular or ventricular complexes were often demonstrated. No other electrocardiographic changes, however, were found, even when there were considerable enlargement of the heart, loud abnormal murmurs, enlargement of the liver, and other clinical evidences of cardiac failure. When the administration of vitamin B and other forms of medical treatment resulted in amelioration of the cardiac condition, these electrocardiographic changes usually disappeared during the convalescence. This fact may indicate that there must have been some myocardial changes amenable to treatment. Scott and Herrmann[3] noticed negative T-waves in Lead I. Inverted T-waves in Lead I or in Leads I and II will have to be accepted as evidence of more advanced myocardial involvement than above mentioned changes. Recently I encountered a case of acute pernicious beriberi

from which electrocardiograms with negative T-waves in Lead I were obtained. Patients abruptly seized with acute pernicious beriberi are usually very ill and have difficulty in getting access to heart specialists who would examine them by use of electrocardiographic apparatus. Therefore, it may be worth while to present a report of this case. At the same time I wish to describe how promptly the acute cardiac failure responds to the intravenous administration of pure vitamin B_1. Aalsmeer, Keefer, and some others have already demonstrated that antiberiberi diet, supplemented with yeast, rice bran extracts, and other remedies containing vitamin B, has a remarkable effect upon the beriberi heart, with a resulting improvement of the cardiac condition along with a quick reduction in size of the heart. In cases of acute pernicious beriberi, however, patients usually are not able to take anything by mouth, because of persistent nausea and vomiting. Even when any remedies are given by mouth without vomiting, the patients may often die before any therapeutic effect is obtained from these.

Shimazono[5] was the first in Japan who administered large doses of purified rice bran extracts subcutaneously or intravenously to patients for the treatment of acute and subacute pernicious cardiac form of beriberi, with successful results. Along with vitamin B he also used strychnine for intravenous injections to ameliorate the vasomotor failure, just as Aalsmeer was doing. By the above medication he was able to save eleven of fifteen patients from the death which had generally been supposed to be inevitable in such cases. Local irritation and fever occurring after subcutaneous injections and an abrupt decrease in blood pressure following intravenous injections of so-called raw oryzanin were the untoward reactions he often observed.

After Jansen and Donath had obtained crystals of vitamin B, the pure substance was clinically used by Cohen and Asir in 1932 for the treatment of beriberi. In 1933 Shimazono[6] demonstrated that crystals of oryzanin, vitamin B_1, administered intravenously, exert an excellent therapeutic effect upon the acute pernicious cardiac form of beriberi.* When 1 mg. of oryzanin crystals of Suzuki and Otake was injected in three divided doses, precordial distress, dyspnea, and nausea subsided in two or three hours, and the patient appeared comfortable on the following day, with normal pulse rate and respiration. However, the decrease in the size of the heart and the improvement of paralysis of extremities required further treatment with oral administration of the vitamin. There was no abrupt decrease in blood pressure immediately following the intravenous injection of the substance. Recently Kagawa

*At the meeting for the study of beriberi held on Nov. 21, 1936, at the Tokyo Imperial University, Kagawa stated that, under the supervision of Shimazono, the therapeutic effect upon the beriberi of crystals of vitamin B^1 was studied in 20 cases. And in 3 of them there were symptoms of acute pernicious cardiac form of beriberi. One milligram of crystals of vitamin B^1 was intravenously injected in three divided doses to one patient, while to two others from 1 to 3 mg. of the substance were injected subcutaneously. All of them recovered, responding very promptly to the injections.

and Kato,[7] in their study on experimental human B_1-avitaminosis, have observed that 0.5 mg. of the above substance, intravenously injected twice a day, was sufficient for a prompt amelioration of cardiac symptoms. In the case of acute pernicious cardiac form of beriberi to be presented in this paper, similar doses of the same substance now available for practical clinical purposes were given to the patient by repeated intravenous injections.

REPORT OF CASE

History.—A Japanese boy, aged fifteen years, had had to work hard as an apprentice to a plasterer during the summer and until the beginning of September, when he began to notice excessive fatigue and paresthesia of the legs. On Oct. 10, 1936, complaining of unusually severe lassitude and slight swelling of his face, he

Fig. 1.—Roentgenogram taken during the acute stage of acute pernicious beriberi, on Oct. 14, 1936, previous to administration of vitamin B. Note the enlargement of the cardiac shadow to the right and to the left, and also in the regions of the pulmonary artery and the superior vena cava.

consulted a local physician, who told him that he had beriberi. On October 11 he began to have nausea and vomiting but did not receive any proper medical treatment. On Oct. 14, 1936, he had severe palpitation, shortness of breath and precordial distress even at rest, and was brought to the St. Luke's Hospital on a stretcher. The patient had been perfectly well prior to the onset of the present illness.

Examination.—On admission the patient, fairly well developed and fairly well nourished, appeared to be very ill, in the state of jactitation with dyspnea and precordial distress. There was no fever, and his sensorium was clear. The temperature was 35.6° C., the pulse rate 140, and the respiratory rate 40 per minute. There was slight edema of the face and legs, and definite cyanosis was visible on mouth, lips, and fingers. The pupils were round and regular, with a fair response to light. Vision and hearing were not impaired. The neck was not rigid. Jugular veins were engorged. On examining the chest, the cardiac impulse was pounding and

diffuse in all intercostal spaces of the precordial area, where a systolic thrill was palpable. The area of percussion dullness indicated that the heart was much enlarged, the border extending about 5 cm. to the right and about 11 cm. to the left of the midsternum. The maximum diameter of the thorax was 22 cm. A loud systolic murmur was audible in the whole precordial area, loudest in the left third and fourth intercostal spaces close to the left border of the sternum. There was neither diastolic

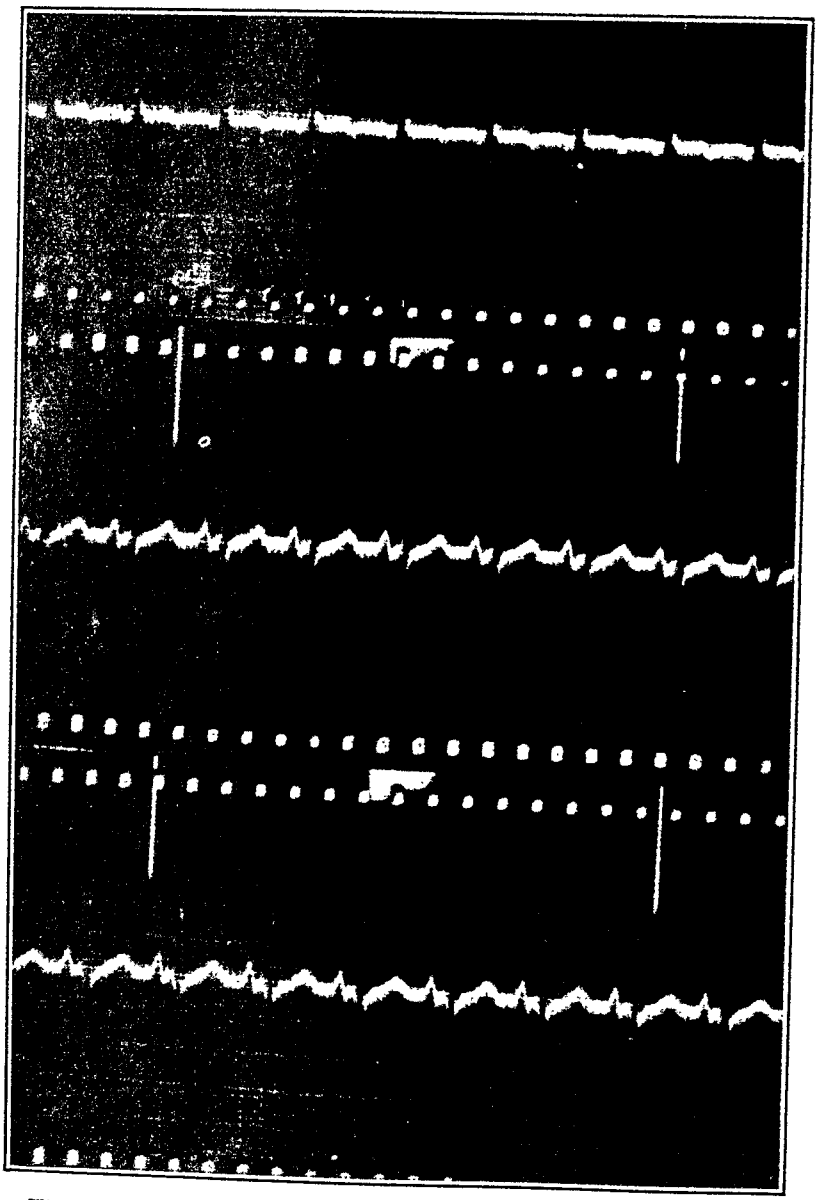

Fig. 2.—Electrocardiogram obtained during the acute stage of acute pernicious beriberi, on Oct. 14, 1936, previous to vitamin B administration. Note negative T-waves in Lead I, besides an accelerated rate and a tendency to the right ventricular preponderance.

nor presystolic murmur. The pulmonary second sound was remarkably accentuated. The cardiac rate was regular, though accelerated. Arterial sounds over the femoral arteries were very loud. The blood pressure measured in millimeters of mercury was 110 systolic and 18 diastolic. The diastolic pressure was very low. The lungs showed no signs of pulmonary congestion on percussion and auscultation, although

there was severe dyspnea. The average value for vital capacity was 49 per cent below the normal value. In the abdomen the liver was not palpable, and there was no evidence of ascites. The knee and ankle jerks were absent. There was no distinct hypesthesia. The urine contained only a trace of albumin, and there were no casts. The value for hemoglobin was 82 per cent, and the erythrocytes numbered

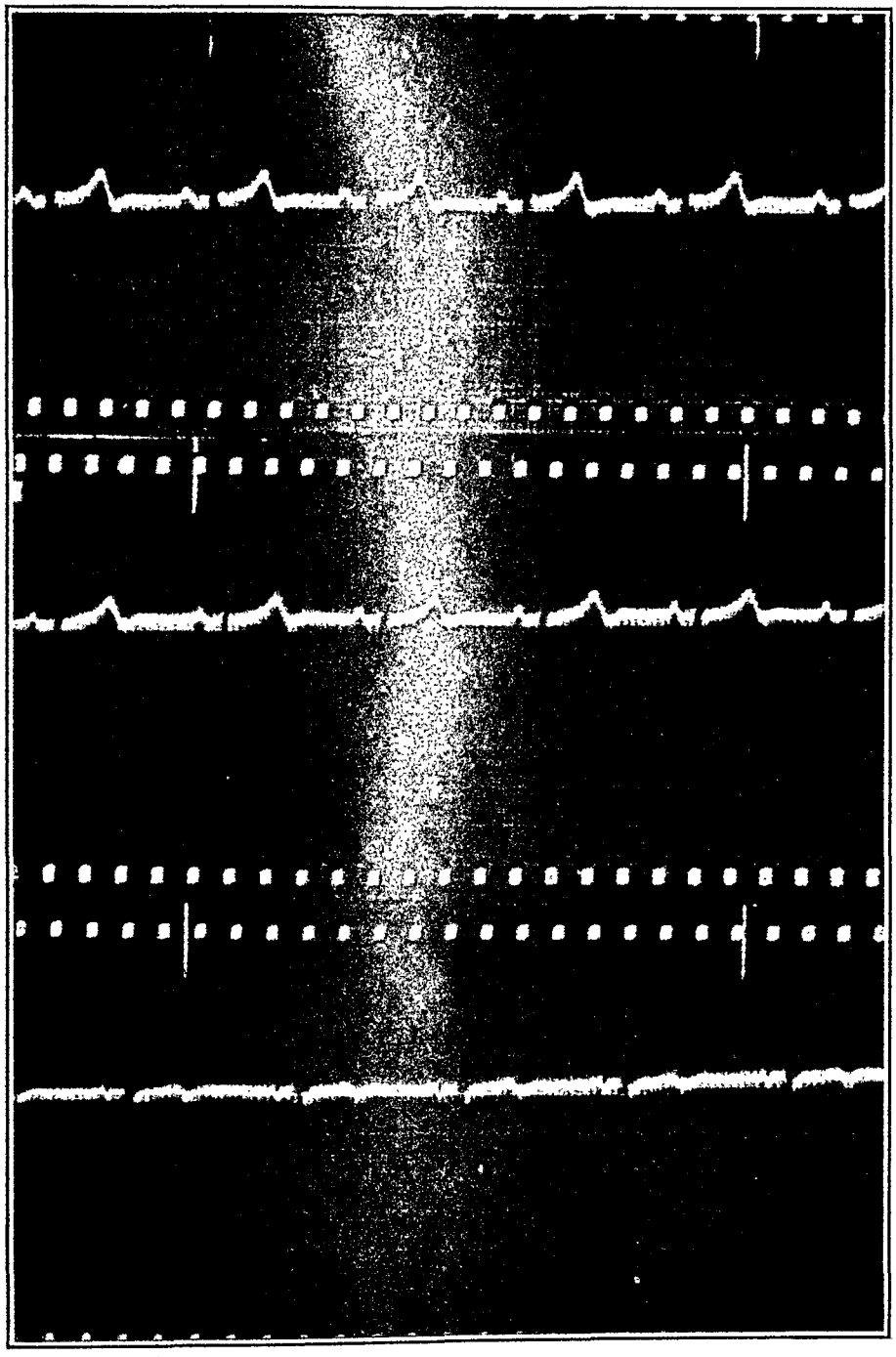

Fig. 3.—Electrocardiogram obtained during the convalescence from acute pernicious beriberi, on Oct. 16, 1936, the patient having received intravenous injections of vitamin B. Note positive T-waves in Lead I.

4,510,000 and leucocytes, 7,500 per cubic millimeter. There was no shifting of the hemogram to the left. In the roentgenogram (Fig. 1) the cardiac silhouette was enlarged to the right and to the left. An enlargement of the shadow was also visible in the region of the pulmonary artery and the superior vena cava. The lungs were clear. The electrocardiogram (Fig. 2) showed an accelerated but regular rate of 110, preponderance of the right ventricle, and T-wave negativity in Lead I.

Course of Illness.—The treatment consisted of rest in bed and the intravenous administration of purified vitamin B_1 and strychnine, following the method proposed by Shimazono[5, 6] for the treatment of the acute pernicious form of beriberi. No other usual cardiac remedies such as digitalis, strophanthin, camphor, or caffeine were used. Within fifteen minutes after 2 c.c. of 0.1 per cent solution of strychnine nitrate had been injected intravenously, the patient appeared as if much relieved of dyspnea, with a resulting decrease of cyanosis. Then 1 c.c. of oryzanin fortior decemplex, Sankyo, was injected into the vein. One cubic centimeter of this clear solution contains 0.5 mg. of purified crystals of vitamin B_1, corresponding in efficacy with 200 gm. of fresh rice bran. On the first day of admission, October 14, injections of above two remedies were made twice each during the day. At night the rectal administration of chloral hydrate enabled the patient to sleep well.

On the second day in the hospital, October 15, combined injections of concentrated oryzanin and strychnine were given in the early morning, and a single injection of concentrated oryzanin at night. A remarkable improvement in the condition of the



Fig. 4.—Roentgenogram taken on Oct. 20, 1936, after recovery from acute pernicious beriberi, due to administration of vitamin B. Note the cardiac shadow normal in size and shape.

patient was already observed on this day. He did not complain of precordial distress. There was neither dyspnea nor cyanosis. The respiratory rate was 20, the pulse rate 80, and the blood pressure 110 systolic and 60 diastolic. The diastolic pressure had been elevated by this time. The urinary output per day was 1,500 c.c. The urine contained no albumin. The vital capacity was still low—43 per cent.

On the third day, October 16, the concentrated oryzanin was injected twice into the vein. Besides this, 30 c.c. of the fluid oryzanin and 3 gm. of rice germ powder were given by mouth, as the patient had already been relieved of nausea and vomiting. The patient appeared very comfortable. The pulse rate was between 60 and 80, and the respiratory rate was 18. There occurred a good diuresis, with the urinary output of 2,050 c.c. per day. The heart was found to have been decreased in size. The cardiac dullness extended about 3 cm. to the right and about 9 cm. to the left. The pulmonary second sound was a little accentuated, being preceded by a weak systolic murmur. The arterial sounds were audible, though much enfeebled. The electrocardiogram (Fig. 3), obtained from the patient about fifty hours after

the institution of the vitamin administrations, revealed normal functioning of the heart. T-waves in Lead I became positive and high and perfectly normal in shape.

On the fourth day, October 17, no more injections of the concentrated oryzanin were made, but an antiberiberi diet was given in addition to the oral administration of 30 c.c. of fluid oryzanin and 3 gm. of rice germ powder. Abnormal murmurs in the heart and arteries had completely disappeared. The pulmonary second sound was not accentuated. The urinary output amounted to 2,600 c.c. per day.

On the fifth and sixth days, October 18 and 19, considerable diuresis continued with the urinary output of 2,500 c.c. and 2,450 c.c., respectively, per day.

On the seventh day, October 20, the patient appeared perfectly well without any cardiovascular or gastrointestinal disturbances. There was no edema. The calves were not tender on firm palpation. Knee jerks, however, were still absent. The vital capacity was -35 per cent. The roentgenographic examination (Fig. 4) revealed that the heart had returned to the normal size and shape. The electrocardiogram was almost normal. The patient left the hospital, completely recovered from cardiac failure.

In summary, it may be stated that a boy who had been seized with an acute pernicious form of beriberi without any complications recovered from the acute cardiac failure within about fifty hours under the intravenous administration of 3 mg. of purified vitamin B_1. There occurred no untoward reaction, such as an abrupt decrease in blood pressure, breathlessness, etc., as used to happen when so-called raw oryzanin had been administered intravenously.

ELECTROCARDIOGRAPHIC EXAMINATION

In the electrocardiogram (Fig. 2), obtained on Oct. 14, 1936, from the patient during the acute stage of pernicious beriberi, the cardiac rate was 110 per minute, with a cycle length of 0.64 sec. P_1 was low, less than 0.5 mm. P_2 and P_3 were both high, 3 mm. P-R interval was 0.14 sec. The main deflection of QRS_1 was directed downward. R_3 was higher than R_2. QRS complexes were neither notched nor slurred in any of the leads. Q-T interval was 0.30 sec., shorter than Fridericia's value by 8 per cent. T_1 was inverted 1.5 mm. below the isoelectric line. T_3 was positive, 3 mm.

In the electrocardiogram (Fig. 3), obtained on Oct. 16, 1936, at the time of remarkable improvement in symptoms, due to intravenous injections of vitamin B_1, the cardiac rate was 70 per minute with a cycle length of 0.88 sec. P_1 and P_2 were normal, 2 mm. P_3 was diphasic. P-R interval was 0.16 sec. QRS complexes were neither slurred nor notched. R_1 was slightly longer than S_1. R_3 was nearly equal in height with R_2. Q-T interval was 0.36 sec. and shorter than Fridericia's value by only 1.5 per cent. T_1 was positive and as high as 4 mm. T_2 was also positive, 3.5 mm. T_3 was diphasic, 1.5 mm. above and below the base line.

During the acute stage the cardiac rate was accelerated, without arrhythmia. The P-waves were low in Lead I and high in Lead III. The QRS complexes indicated a tendency to right ventricular preponderance. T-waves were inverted in Lead I. During the convales-

cence T-waves became positive and high in Lead I. The tendency to right ventricular preponderance was reduced. Along with a decrease in cardiac rate the Q-T interval became longer. P-waves in Lead I became normal in voltage. Diphasic P- and T-waves in Lead III may be of little clinical significance.

Keefer noticed that high T-waves in Lead II during the acute stage became lower during recovery and that negative T-waves in Lead III, without use of digitalis, became positive during the convalescence, and the positive one negative. No doubt these changes indicate that the myocardium underwent some change during the recovery from beriberi of patients treated with rest in bed and by the administration of anti-beriberi diet and yeast. However, there were no electrocardiographic evidences to which any pathological significance can be attached. The T-waves are often inverted in normal individuals in Lead III. On the other hand, when the effect of digitalis medication is excluded and negative T-waves exist in Lead I or in Leads I and II, we may assume serious involvement of the myocardium with a fair accuracy. In the electrocardiogram (Fig. 1), obtained from the patient with acute cardiac failure due to beriberi, the negative T-waves were found in Lead I, when no digitalis had been administered. And these negative T-waves promptly became positive during the recovery, due to the intravenous administration of vitamin B_1. It may be stated that in the acute pernicious form of beriberi there may be an electrocardiographic evidence of more serious myocardial involvement than in the usual cardiac form of beriberi.

SUMMARY

A patient with acute pernicious form of beriberi, showing an electrocardiographic evidence of myocardial damage, recovered very promptly from the cardiac failure under intravenous administration of vitamin B_1, with a resulting return to normal of the electrocardiogram.

REFERENCES

1. Aalsmeer, W. C., and Wenckebach, K. F.: Herz und Kreislauf bei der Beriberi-Krankheit, Urban u. Schwarzenberg, Wien and Berlin, 1929.
   Wien. Arch. f. inn. Med. 16: 193, 1929.
2. Walker, J. E.: Reversible Cardiac Enlargement, J. A. M. A. 106: 1795, 1936.
3. Scott, L. C., and Herrmann, G. R.: Beriberi ("Maladie de Jambes") in Louisiana: With Especial Reference to Cardiac Manifestations, J. A. M. A. 90: 2083, 1928.
4. Keefer, C. S.: The Beriberi Heart, Arch. Int. Med. 45: 1, 1930.
5. Shimazono, J.: Avitaminosen und Verwandte Krankheitszustaende, Julius Springer, Berlin, 1927. "Kakke," Kokuseido, Tokyo, 1929 (in Japanese).
6. Shimazono, J.: The Effect Upon Beriberi of Crystals of Oryzanin, Vitamin B_1: Etiology of Beriberi, Tokio Iji Sinsi. 57: 2835, 1933.
7. Kagawa, S., and Kato, K.: Nährversuch des Menschen mit Verschiedenen Qualitativen Defizienten Kosten. Experimentelle Beriberi und Skorbut, die Appetit Steigernde Wirkung von Vitamin B_1 (Oryzanin Krystall) beim Menschenversuche. Mitteilungen der medizinischen Gesellschaft zu Tokyo 50: 239, 1936.

THE CIRCULATORY DYNAMICS IN TRICUSPID STENOSIS

Their Significance in the Pathogenesis of Edema and Orthopnea*†

Mark D. Altschule, M.D., and Herrman L. Blumgart, M.D.
Boston, Mass.

INTRODUCTION

THE diagnosis of acquired tricuspid stenosis is made very infrequently during life. Zeisler,[1] who reviewed the literature in 1933, reported correct ante-mortem diagnoses in only 31 of 250 autopsied cases. Of these 31 diagnoses, 14 were made by Dressler and Fischer[2] out of a group of 33 cases proved at post-mortem examination.

The clinical criteria for tricuspid valvular disease have been well described by Dressler and Fischer,[2] by Zeisler,[1] and by Friedlander and Kerr.[4] The cardinal signs are cyanosis, subicteric tint, and hepatomegaly, with pulsation of the neck veins and liver, all persisting in the absence of cardiac decompensation. This pulsation is double-phased, with late diastolic (auricular) and systolic (ventricular) components. The presystolic component is absent in the presence of auricular fibrillation and, according to Friedlander and Kerr,[4] also in auricular arrest, nodal rhythm, and nodal tachycardia. The murmurs are typical and are best heard at, or to the right of, the xiphoid process. They may, however, be masked by those of the mitral stenosis which is always present. The most recent work, that of Teufl,[3] using profile illumination to make visible a retrograde venous pulsation, suggests that the correct diagnosis may be made more often in the future through the use of this procedure.

Physiological studies in this disease are exceedingly fragmentary, being limited almost entirely to studies of the venous pressure and the phlebogram. No studies of the dynamics of the circulation are, so far as can be ascertained, available.

REPORT OF CASE

M. R., a thirty-two-year-old white American housewife, entered the Beth Israel Hospital on Jan. 29, 1936, complaining of dyspnea on exertion of ten years' duration. Family history and past history were irrelevant. Eleven years before admission, the patient had migrating polyarthritis, characterized by pain and fever, but no swelling or redness of the joints, over a period of four months, during which time she remained in bed. Following this illness she was advised to curtail her activities because she had a cardiac murmur, but she disregarded this advice. About a year later she began to notice easy fatigability, slight dyspnea, and slight palpita-

*From the Medical Service and Medical Research Laboratories of the Beth Israel Hospital, Boston, and the Department of Medicine, Harvard Medical School.

†Presented in abstract before the American Clinical and Climatological Society, October 26, 1936.

tion on exertion. She also noted slight swelling of the ankles, particularly the left, at the end of the day. Her condition remained stationary until six years before admission, when, because of increase of symptoms, she entered another hospital, where a diagnosis of rheumatic mitral and aortic stenosis and insufficiency, possible tricuspid insufficiency, and auricular fibrillation was made. She was digitalized and discharged improved after an eleven-day stay. About seven months before the present admission she began to experience a dragging sensation and noted the appearance of "a big lump" in the epigastrium. The "lump" seemed to vary in size from time to time. Simultaneously the patient began to experience frequent eructations of gas, with, however, no nausea or vomiting. At about this time her dyspnea became worse. During the four months preceding admission the patient had five or six attacks of severe crampy pain in the right upper quadrant, radiating to the left upper quadrant, requiring morphia for relief. During this period orthopnea appeared, and edema became more persistent, though at no time was it more than moderate in degree. The patient, who formerly had been up and about, now went to bed for a period of three weeks, after which she led a bed-and-chair existence. A

Fig. 1.—Unretouched infra-red photographs showing marked engorgement of face and neck veins.

month before admission the onset of continuous pain in the right shoulder was noted. At no time did the patient have cough, fever, chest pain, or paroxysmal dyspnea.

Examination on admission revealed a fairly well-developed and well-nourished young woman, with a slight icteric tint to the skin and slight cyanosis of the lips. The veins of the neck, face, forehead, arms, and hands were dilated and pulsating synchronously with the heart. The veins over the face and forehead were from 0.5 to 1.0 cm. in diameter (Fig. 1). Ophthalmoscopic examination was negative except for dilatation and pulsation of the retinal veins. The heart was markedly enlarged to both right and left, the borders of dullness being respectively 11 and 12 cm. from the midsternal line. Over the mitral area a diastolic thrill and a faint systolic thrill were felt. A systolic thrill was also palpable over the aortic area. A rough systolic murmur and a rolling diastolic murmur were audible at the apex. A loud, rough systolic murmur and loud whistling decrescendo diastolic murmur were heard over the lower end of the sternum and were transmitted toward the right. A rough systolic murmur and a short early diastolic murmur were also audible over the third left interspace. The second sound over the aortic area was absent. The rhythm was completely irregular. The heart rate was 70, with no pulse deficit. There was some dullness over the right base posteriorly. No râles were heard. The liver

was enlarged to the umbilicus and was tender and pulsating. The pulsations were systolic in time only. No capillary pulsation or Corrigan pulse was present. There was no edema of the ankles, legs, sacrum, or back. Arterial blood pressure was approximately 140 mm. systolic and 84 mm. diastolic.

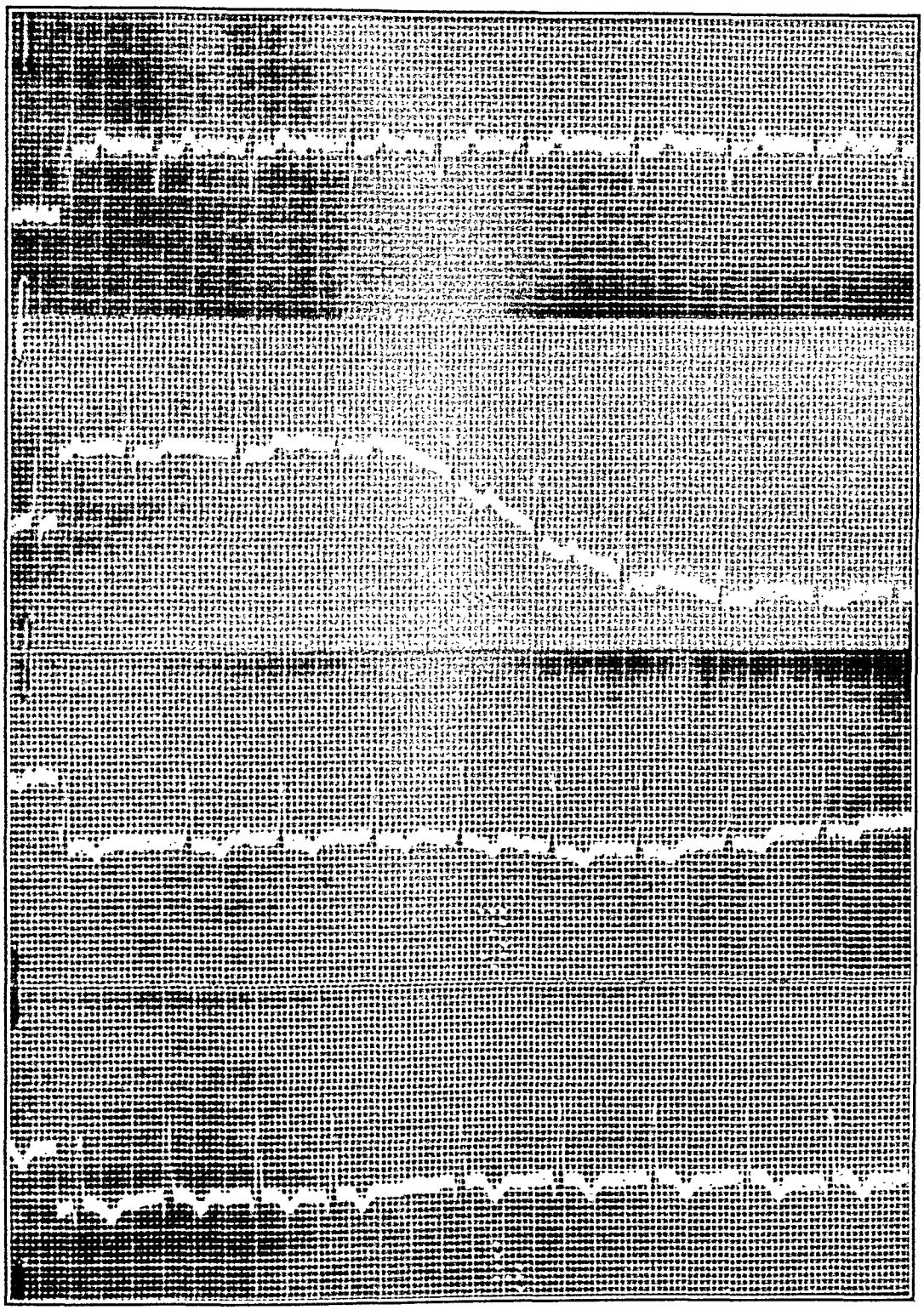

Fig. 2.—Electrocardiogram showing right axis deviation and auricular fibrillation.

The clinical diagnoses were: Rheumatic heart disease; tricuspid, mitral, and aortic stenosis and insufficiency; auricular fibrillation; and cardiac decompensation.

Electrocardiographic tracings showed auricular fibrillation, right axis deviation, diphasic T_2 and inverted T_3 and T_4 (Fig. 2).

Cardiac measurements from a roentgenogram taken at a distance of seven feet were (Fig. 3) as follows:

Midsternum to right	10.0 cm.
Midsternum to left	11.3 cm.
Total transverse diameter	21.3 cm.
Diameter of great vessels	8.5 cm.
Length	19.2 cm.
Base	17.0 cm.
Transverse diameter of chest	24.6 cm.

The report of the roentgenologist also stated that most of the enlargement was to the right, suggesting a right-sided lesion, and that the left auricle was prominent. The contour of the heart was not that of a pericardial effusion. Fluoroscopy in various positions showed no evidence of adhesive pericarditis.

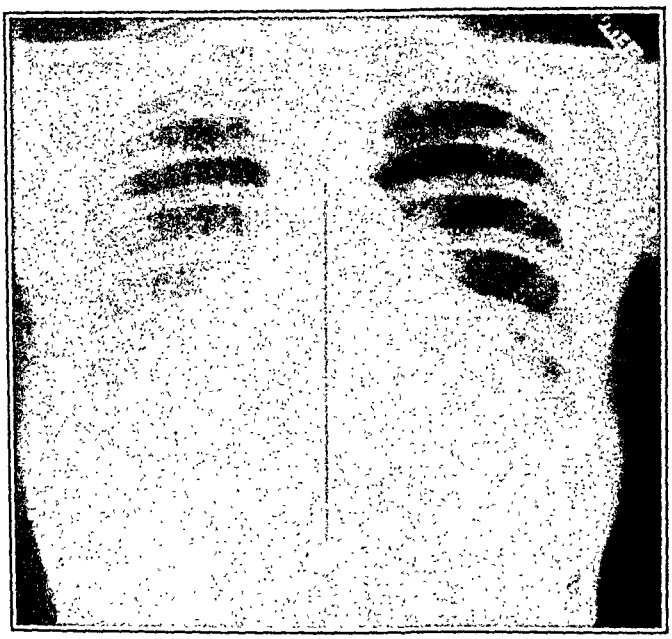

Fig. 3.—Roentgenogram of heart showing marked enlargement to right as well as to left.

Clinical Pathology.—Four urine examinations revealed a specific gravity ranging between 1.020 and 1.030. Examinations of the urine taken without catheterization were negative except for the constant presence of a slightest possible trace to a trace of albumin.

The red blood cell count was 4,350,000 per c.mm.; the hemoglobin, 80 per cent (Sahli). The white blood cell count on three occasions was between 6,100 and 8,000 per c.mm. Differential count and smear were normal. Stool examination revealed no abnormality.

The blood nonprotein nitrogen was 29 mg. per cent; the blood sugar, 92 mg. per cent; the serum total protein, 7.4 gm. per cent; and the serum cholesterol, 189 mg. per cent. The blood Hinton and Kahn reactions were negative. On admission the icteric index was 20, and the quantitative van den Bergh, 2.3. These fell respectively to 12 and 1.3 during the next two weeks. The galactose tolerance test was negative.

Venous Pressure.—The venous pressure as measured in the antecubital veins by the direct method and referred to the level of the right auricle[5] fluctuated between

16.9 and 21.9 cm. of water over a period of a week of observation. The pressure in the right femoral vein with the patient in the recumbent position was 22.3 cm. at a point 6 cm. below the level of the right auricle, giving a pressure of 16.3 cm. when referred to the level of the right auricle. These values were recorded during diastole. During systole the pressures in the antecubital veins were 0.4 to 0.8 cm. of water higher; the pressure in the femoral vein was 0.5 to 2.0 cm. higher. An 18 gauge needle was used in measuring the pressure in the arm veins and a 14 gauge needle in measuring that in the femoral vein. To obviate the inertia of the recording system, the length of the tubing used was reduced as far as possible.

The pressure in the veins of the hand as measured by the indirect method of Hooker and Eyester[6] was 20.8 cm. of water.

Velocity of Blood Flow.—The velocity of blood flow as measured by the decholin method[7] showed an arm-to-tongue circulation time of 25 sec. on two occasions.

Cardiac Output.—The cardiac output as measured on two occasions by the method of Starr and Gamble[8] was 2.9 liters, or 1.9 liters per square meter of body surface, the normal range of values being 1.9 to 2.6 liters per square meter of body surface. The arteriovenous oxygen difference was 6.44 volumes per cent.

Vital Capacity.—The vital capacity of the lungs varied between 1,400 and 1,600 c.c.

Metabolism.—The basal oxygen consumption was 189 c.c. per minute, the basal metabolic rate being -3 per cent.

Respiratory Dynamics.—Under basal conditions the respiratory rate averaged 12.5 per minute. The respiratory minute volume was 4.8 liters per minute or 3.1 liters per minute per square meter of body surface. The tidal air averaged 384 c.c.

Blood Gases.—The femoral venous blood oxygen content was 13.12 volumes per cent, the capacity 19.52 volumes per cent, and saturation 67.2 per cent. These values are normal. Arterial blood was not obtained because of lack of cooperation of the patient.

Blood Vessels of the Skin.—Microscopic examination of the vessels of the nail beds revealed intermittent, pulsatile, or continuous flow in the capillaries, but no reversal of flow. The capillaries were of normal diameter. Many larger pulsatile vessels were seen. It could not be determined which of these were arteries and which veins.

Observations on Orthopnea.—With the patient at an angle of 30 degrees from the horizontal, the veins on the top of the scalp were distended. The respiratory rate was 18 per minute. The patient experienced a choking feeling in the throat and chest. Merely flexing the head, by putting a pillow under it, caused the veins of the scalp to collapse. Simultaneously the choking feeling disappeared. There was no change in respiratory rate.

Elevating the bed to an angle of 60 degrees likewise caused the collapse of the engorged veins on the face and the simultaneous disappearance of orthopnea. These maneuvers were not associated with any change in vital capacity.

DISCUSSION

The findings in this case are of interest from several points of view. In the first place the signs of tricuspid stenosis and insufficiency were adequate to establish the clinical diagnosis of this condition. In common with other reported cases of tricuspid stenosis,[1, 2, 4] this patient showed a persistently elevated venous pressure, with no evidence of edema. In many of the cases described as free of edema, engorgement

of the neck veins, frequently to a striking degree, was noted.[1,2] Friedlander and Kerr[4] measured the venous pressure in their patient and found it to be 26 cm. of water though no edema was present. With each thrust of the heart in the case here reported, the veins showed increased engorgement and conspicuous pulsations. The greatly enlarged liver likewise pulsated markedly. The skin showed a slightly cyanotic and icteric tint. These signs, together with the loud systolic murmur referable to the tricuspid area, signified tricuspid insufficiency. The loud decrescendo diastolic murmur heard over the lower end of the sternum, transmitted toward the right, could be clearly differentiated from the aortic and mitral diastolic murmurs, and established the diagnosis of organic tricuspid stenosis.

The significance of jaundice and cyanosis as a helpful diagnostic sign in tricuspid valvulitis has recently been pointed out by Wearn.[9] In our patient the icteric tint corresponded with the increased icteric index values and slightly elevated serum bilirubin values and was due to hepatic engorgement. The cyanosis which was more bluish and less purplish than that usually observed in cardiac patients was evidently due to the dilatation of veins and venules.

The accuracy of the measurements of venous pressure here reported was not significantly impaired by the movement of the fluid in the manometer tube, by the friction of the fluid in the measuring system, or by the inertia of the fluid itself. Diastole was sufficiently long to permit the fluid in the manometer to come to a standstill at the same point each time. Because of the auricular fibrillation, diastole was of variable duration and was frequently abnormally long. Readings of the venous pressure were not affected by the duration of diastole. Further, measurements made in the arm veins with a needle of medium gauge and in the femoral vein with one of much larger size were the same.

In most patients with congestive failure many factors cooperate in causing the appearance of peripheral edema. The decreased output of the heart in relation to the oxygen consumption combined with deficient oxygen saturation of the arterial blood leads to anoxemia, which in turn leads to vasodilatation of the peripheral capillaries with a marked increase in the number of open capillaries. This greatly increased filtering surface area permits the filtration of considerably increased amounts of fluid. Simultaneously, the elevated venous pressure tends to prevent reabsorption of fluid at the venous ends of the capillaries. Edema fluid, as shown by Gilligan and her associates[10] and others, is a simple plasma filtrate in equilibrium with blood. Anoxemia not only leads to peripheral vasodilatation but also as shown experimentally by Landis[11] may lead to increased capillary permeability. In addition to the factors of anoxemia, peripheral vasodilata-

tion, and elevated venous pressure above enumerated, decreased plasma protein concentration,[10] defective lymphatic drainage, and diminished tissue pressure likewise are frequently of etiological significance in the formation of edema in patients with congestive heart failure.

The patient who is the subject of the present study afforded an unusual opportunity to study the effect of a generally elevated venous pressure uncomplicated by most of the factors usually found in patients with congestive failure due to organic heart disease. Repeated measurements of the minute volume output of the heart showed values at the lower range of normal. The slightly prolonged circulation time may be considered a result of venous engorgement, the test substance, decholin, having been injected into the veins of the arm. The low vital capacity of the lungs suggests that pulmonary congestion might also be in part responsible for the prolonged circulation time although encroachment on the lungs by the greatly enlarged heart might have been sufficient in itself to cause the marked diminution in the vital capacity. The arteriovenous oxygen difference calculated from the minute volume output studies and estimated from direct analysis of the femoral venous blood likewise showed normal values.

These findings therefore indicate that in the absence of other cooperating factors such as anoxemia, lowered cardiac output, and decreased plasma protein, a venous pressure as high as 20 cm. of water which may be observed in cardiac patients with anasarca may still not induce clinical pitting edema. It is significant that Krogh, Landis, and Turner,[12] and Landis and Gibbon[13] demonstrated experimentally that the venous pressure in normal individuals can be elevated to from 15 to 20 cm. of water without a demonstrable increased accumulation of water in the tissue spaces. These experimenters have shown, therefore, that there exists in the normal subjects a margin of safety against the production of edema through increase of venous pressure.

It is extremely important that the osmotic pressure of the plasma proteins in our subject was normal (the total serum protein was 7.4 gm. per cent), for the experiments of many observers (reviewed by Krogh and his associates[12]) leave little doubt that edema would have occurred with a venous pressure of 16 to 22 cm. of water and appreciably lowered plasma protein concentration.

The observations in this patient also have a bearing in regard to the mechanisms which operate in the production of orthopnea. That orthopnea may be produced by various mechanisms is well established. Pulmonary engorgement initiating sensory impulses leading to dyspnea, or encroachment on the vital capacity of the lungs by ascites, hydrothorax, enlarged hearts, and intrathoracic tumors may impel some patients to assume the upright position, for an increased vital capacity and more complete oxygenation of the blood are sometimes observed

under such circumstances. In a previous communication, Ernstene and Blumgart[14] presented evidence which supported the concept that in sitting up, orthopneic patients relieved their respiratory centers of the effects of increased venous pressure and thereby secured increased blood flow and relief from the distress due to partial asphyxia in such areas. In the upright position the pressure in the veins about the respiratory center is kept more nearly normal, and the blood flow in the capillaries feeding these veins is increased to the maximal limit set by the existing myocardial failure. Eighty-two comparisons of the height of venous pressure and the degree of orthopnea in 22 patients with uncomplicated myocardial failure of the congestive type showed a parallelism between the two measurements. When orthopneic patients were placed in the recumbent position with the head flat, simple elevation of the head by flexion of it on the thorax produced, almost without exception, conspicuous diminution of respiratory distress. In performing this maneuver, the chest was not moved, and so intrathoracic factors, which might affect the vital capacity or the oxygenation of the pulmonary blood, were not influenced. Cerebral venous pressure, judging by the collapse of the neck veins, was reduced, however.

The strikingly elevated venous pressure in the patient of the present communication, in the absence of many of the factors commonly present in patients with congestive failure, offered an interesting opportunity to test the applicability of the above theory. Simple flexion of the head with the patient in the recumbent position relieved the patient of respiratory distress. It was of particular significance in this case that respiratory distress was relieved precisely by that degree of elevation which resulted in a collapse of the prominent distended veins over the forehead and face.

The cardiovascular dynamics of adhesive pericarditis are somewhat similar to those of tricuspid stenosis. The venous pressure in both is strikingly elevated. However, the cardiac output in the former is markedly decreased,[15-19] and edema or ascites or both is present in all the patients with adhesive pericarditis reported in the literature.[20] In patients with tricuspid stenosis and insufficiency the cardiac output may be within the limits of normal even though the venous pressure is somewhat elevated; the findings in our patient as well as those reported elsewhere show that edema of the subcutaneous tissues may be absent under such circumstances.

SUMMARY

The cardiovascular dynamics in a patient with tricuspid stenosis and insufficiency were investigated. The clinical diagnosis was made on the basis of the marked generalized venous engorgement, cyanosis,

slight jaundice, pulsation of the veins and of the enlarged liver, and the presence of typical murmurs to the right of the xiphoid.

A high venous pressure was noted in both the arm and leg veins; this observation corroborated the clinical finding of marked generalized venous engorgement. Elevation of the venous pressure is commonly regarded as the chief, if not the only, cause of cardiac edema. It is striking that no edema was present in this case. Of significance in this connection are the observations on the cardiac output, arterio-venous oxygen difference, and venous oxygen content and saturation. All were essentially normal, i.e., no anoxemia was present. The concentration of plasma protein was normal. These findings strongly suggest that factors other than the venous pressure are likewise of importance in the formation of cardiac edema.

The studies on orthopnea in this patient support the theory that elevation of the venous pressure may be a significant factor in the genesis of orthopnea.

REFERENCES

1. Zeisler, E. B.: Tricuspid Stenosis: Review of the Literature and Report of a Case With Antemortem Diagnosis, Am. Heart J. 8: 697, 1933.
2. Dressler, W., and Fischer, R.: Ueber Tricuspidalstenose: Ein Berichte über 30 autoptisch sichergestellte Falle, Klin. Wchnschr. 8: 1269 and 1316, 1929. Zur klinischen Characteristik der Trikuspidalstenose, Ztschr. f. Kreisslaufforsch. 22: 188, 1930.
3. Teufl, R.: Pulsation normaler und varikoser Extremitatenvenen und ihre diagnostische Bedeutung, Wien. med. Wchnschr. 86: 407, 1936.
4. Friedlander, R. D., and Kerr, W. J.: The Clinical Diagnosis of Tricuspid Stenosis, Am. Heart J. 11: 357, 1936.
5. Moritz, F., and von Tabora, D.: Ueber eine Methode, beim Menschen den Druck in oberflachlichen Venen exakt zu bestimmen, Deutsches Arch. f. klin. Med. 98: 475, 1910.
6. Hooker, D. R., and Eyester, J. A. E.: An Instrument for the Determination of the Venous Pressure in Man, Bull. Johns Hopkins Hosp. 19: 274, 1908.
7. Gargill, S. L.: The Use of Sodium Dehydrocholate as a Clinical Test of the Velocity of Blood Flow, New England J. Med. 209: 1089, 1933.
8. Starr, I., and Gamble, J. C.: An Improved Method for the Determination of Cardiac Output in Man by Means of Ethyl Iodide, Am. J. Physiol. 87: 450, 1928.
9. Wearn, J. T.: The Combination of Jaundice and Cyanosis as a Helpful Diagnostic Sign in Tricuspid Valvulitis, Medical Papers Dedicated to Henry Asbury Christian, Baltimore, 1936, Waverly Press, Inc., p. 60.
10. Gilligan, D. R., Volk, M. C., and Blumgart, H. L.: Observations on the Chemical and Physical Relation Between Blood Serum and Body Fluids: I. The Nature of Edema Fluids and Evidence Regarding the Mechanism of Edema Formation, J. Clin. Investigation 13: 369, 1934.
11. Landis, E. M.: Micro-Injection Studies of Capillary Permeability: III. The Effect of Lack of Oxygen on the Permeability of the Capillary Wall to Fluid and to Plasma Proteins, Am. J. Physiol. 83: 528, 1928.
12. Krogh, A., Landis, E. M., and Turner, A. H.: The Movement of Fluid Through the Human Capillary Wall in Relation to Venous Pressure and to the Colloid Osmotic Pressure of the Blood, J. Clin. Investigation 11: 63, 1932.
13. Landis, E. M., and Gibbon, J. H., Jr.: The Effects of Temperature and of Tissue Pressure on the Movement of Fluid Through the Human Capillary Wall, J. Clin. Investigation 12: 105, 1933.
14. Ernstene, A. C., and Blumgart, H. L.: Orthopnea: Its Relation to the Increased Venous Pressure of Myocardial Failure, Arch. Int. Med. 45: 593, 1930.

15. Beck, C. S., and Griswold, R. A.: Pericardiectomy in the Treatment of the Pick Syndrome: Experimental and Clinical Observations, Arch. Surg. **21**: 1064, 1930.
16. Burwell, C. S., and Strayhorn, W. D.: Concretio Cordis: I. A Clinical Study With Observations on the Venous Pressure and Cardiac Output, Arch. Surg. **24**: 106, 1932.
17. Beck, C. S.: Circulatory Stasis of Intrapericardial Origin: The Clinical and Surgical Aspects of the Pick Syndrome, J. A. M. A. **102**: 1543, 1934.
18. Burwell, C. S., and Flickinger, D.: Obstructing Pericarditis. Effect of Resection of the Pericardium on the Circulation of a Patient With Concretio Cordis, Arch. Int. Med. **56**: 251, 1935.
19. Griswold, R. A.: Chronic Cardiac Compression Due to Constricting Pericarditis. Relief by Pericardiectomy, With a Note on the Value of the Roentgenkymogram, J. A. M. A. **106**: 1054, 1936.
20. White, P. D.: Chronic Constrictive Pericarditis (Pick's Disease) Treated by Pericardial Resection, Lancet **1**: 539, 1935.

THE OCCURRENCE AND THE PATHOGENESIS OF CARDIAC HYPERTROPHY IN GRAVES' DISEASE*

CHARLES K. FRIEDBERG, M.D., AND ARTHUR R. SOHVAL, M.D.
NEW YORK, N. Y.

IT HAS long been known that Graves' disease produces marked changes in the dynamics of the circulation. It is generally accepted that in this disease the heart rate and the velocity of circulation are increased, the blood volume is enlarged, the venous return to the heart augmented, and the minute cardiac output considerably elevated. There is still disagreement, however, as to whether the size and the weight of the heart are greater than normal, and if so, what factors produce these alterations.

HISTORICAL

Many of the earliest writers on Graves' disease noted clinically that there was an increase in the size of the heart. Graves,[1] himself, observed cardiac enlargement in one of the three cases on the basis of which he described the clinical picture which bears his name. Marsh[2] and Stokes[3] also reported dilatation of the heart in disease of the thyroid gland. Enlargement of the heart was clinically observed in from one-third to one-half of the cases reported by various writers including Pässler,[4] Kraus,[5] Kocher,[6] Murray,[7] Schultze,[8] Dietlen,[9] and Bickel.[10] Sattler[11] reported that the dilatation of the heart accompanying Graves' disease could disappear if the hyperthyroidism were cured or alleviated and quoted various cases to illustrate this point. In a recent clinical study of 148 cases of Graves' disease, Burnett and Durbin[12] noted cardiac enlargement in 30 per cent.

Clinical studies of the size of the heart in hyperthyroidism have been supplemented by the more accurate methods of x-ray examination. Most of these reports have likewise emphasized the occurrence of cardiac enlargement, as indicated by general widening of the cardiac borders, or by some characteristic alteration in the shape of the heart. Among the reports of large series of cases are those of Meyer-Borstel[13] and of Parkinson and Cookson.[14] Meyer-Borstel presented a summary of the evidence for cardiac enlargement in Graves' disease and reported 59 cases of his own, in 83 per cent of which the heart was enlarged. He described a typical configuration consisting of prominence of the pulmonary conus similar to that in mitral stenosis. This observation had been made previously by Rösler[15] and by Assmann.[16] Parkinson and Cookson found slight or moderate enlargement in 45 per cent of 130 cases

*From the Medical Services of Dr. George Baehr and Dr. B. S. Oppenheimer, the Mount Sinai Hospital.

which were studied clinically and by the x-ray. They likewise emphasized a characteristic early alteration in the shape of the heart, particularly the prominence of the pulmonary arch.

Certain experimental evidence has been presented to support the occurrence of cardiac hypertrophy in Graves' disease. Hashimoto,[17] Cameron and Carmichael,[18] Simonds and Brandes,[19] and Smith and MacKay[61] frequently observed the presence of cardiac hypertrophy in animals following the administration of thyroid extract. Boas and Landauer[62] noted the occurrence of hypertrophied hearts in the frizzle fowl as compared with those of the normal chicken. They ascribed this to the scanty plumage with improper conservation of heat in the former, resulting in increased basal metabolism and tachycardia. They drew an analogy between the cardiac hypertrophy in patients with hyperthyroidism and that in the frizzle fowl, both of which were explained as due to increased metabolism and work of the heart. An evaluation of these experimental studies requires a consideration of the large doses of thyroid extract usually employed, of the general failure to allow for the disproportionate total body weight lost during thyroid administration, resulting in an increased ratio of heart weight to body weight, of the possible differences of induced pharmacological hyperthyroidism in animals and Graves' disease in humans, and especially of differences in cardiac adjustments to alterations of blood flow in humans and lower animals. For these reasons, one may question whether the above mentioned experimental observations are applicable to the pathology of Graves' disease in humans.

There are few observers who disagree with the vast array of reports indicating the presence of cardiac enlargement in Graves' disease. It should be emphasized, however, that even in these reports of cardiac enlargement the occurrence of hearts of normal size is at least as frequent as those that show enlargement. One can, therefore, say that cardiac enlargement is not a necessary sequel to hyperthyroidism. No adequate explanation is presented in these various studies for the occurrence of enlargement in some cases and not in others.

Recently, a number of writers, without denying the occasional presence of cardiac enlargement, have maintained that this was neither of marked degree nor a significant feature of Graves' disease. Rösler,[15] on the basis of x-ray observations, emphasized that the great majority of hearts in Graves' disease are not enlarged. He found no diminution in the size of the heart after thyroidectomy. Yater,[20] in discussing the dynamics of the circulation in hyperthyroidism, also maintained that there was no significant degree of cardiac hypertrophy. Thomas,[21] after pointing out that there was no agreement as to the occurrence of hypertrophy and dilatation, adopted a middle course and suggested that enlargement occurred only late in the disease and with intense and prolonged hyperthyroidism. Hurxthal[22] and his coworkers,[23] and Lahey,[24]

on the basis of x-ray and clinical studies of an unusually large series of cases, concluded that cardiac hypertrophy was rare except with coexisting heart disease. They maintained that hypertrophy does not occur as a result of pure hyperthyroidism but that a slight degree of dilatation is frequent. The evidence obtained from various post-mortem studies will be discussed after the presentation of certain general considerations and definitions.

GENERAL CONSIDERATIONS

In evaluating the numerous studies which bear on the size and weight of the heart, there are certain fundamental difficulties. There is a lack of adequate distinction in the use of the terms hypertrophy, dilatation, and enlargement. It is difficult to evaluate and compare the results obtained from x-ray, clinical, experimental, and post-mortem studies. The confusion in the use of terms is due in part to the fact that observations based on these varied types of investigation necessarily yield different kinds of information. Thus, clinical and x-ray observations afford no measure of the weight of the heart, while post-mortem studies cannot give an accurate picture of the size of cardiac chambers during life.

Dilatation of the heart indicates an enlarged capacity of the cardiac chambers. This can sometimes be determined clinically by palpation and percussion, and, unless very slight, should generally be observable by x-ray films. *Cardiac hypertrophy* indicates an increased weight of the heart. This may be visible grossly in a greater thickness of the cardiac wall and microscopically by an enlargement of the cardiac muscle fibers and by various nuclear changes. Such increase in the thickness of the cardiac walls may produce a widening of the cardiac borders which might or might not be noted clinically or by the x-ray. On the other hand, dilatation itself (without alteration in the thickness of the cardiac walls) can produce a widening of the cardiac borders. Sometimes it is possible by a consideration of the clinical course or by certain x-ray observations to surmise a distinction between cardiac hypertrophy and cardiac dilatation. Generally, however, it is difficult or impossible to distinguish the two conditions. For this reason, since the heart cannot actually be weighed, clinical and x-ray observations should lead only to the diagnosis of *cardiac enlargement,* denoting an increased width of the cardiac borders. No attempt should be made to state specifically how much of the altered size is due to hypertrophy and how much to dilatation.

In this report we shall confine ourselves essentially to a consideration of cardiac *hypertrophy* in Graves' disease. This necessarily involves the study of hearts which have come to post-mortem examination. The advantages of thus limiting the problem appear obvious. Post-mortem study affords uniform, absolute measurements which can be compared

with the findings of various observers. It also makes more certain the accuracy of the clinical diagnosis and the absence of other forms of circulatory or cardiac disease which might lead to cardiac hypertrophy. On the other hand, x-ray observations may give fairly accurate measurements as to the size of the heart, but the standards of normal variation on x-ray examination are less clearly defined than the standards for normal heart weights. Furthermore, since x-ray observations involve two-dimensional configurations, slight cardiac enlargement can easily be overlooked. The difficulties of evaluating accurately the size of the heart by percussion and palpation are obviously even more marked. For these reasons clinical and x-ray studies will not be included in our consideration of heart size, which is based only on post-mortem observations.

This study is not only confined to post-mortem observations, but is further limited to a consideration of cardiac hypertrophy. This can be determined in terms of specific numerical values which can be compared with the findings of other authors. Dilatation, on the other hand, is variously evaluated by different observers even where the hearts are available for direct inspection. Dilatation, as determined by post-mortem examination, depends in large measure on whether the heart stopped in systole or diastole. Mild grades of dilatation may be obscured when thick, hypertrophied chamber walls encroach upon the cardiac lumina.

Even in evaluating hypertrophy, unless it be considerable, one falls upon the stumblingblock of normal values for heart weights. The wide variation of numerous investigators (Table I) is indicated by the values given by Tandler,[25] Gray,[26] Piersol[27] and by Walmsley.[28] It is agreed that heart weights bear a fairly definite relationship to body weight. But these ratios have been variously stated to be between 0.8 per cent as

TABLE I

WEIGHTS OF NORMAL HEARTS GIVEN BY VARIOUS AUTHORS

AUTHOR	AVERAGE (GM.)		RANGE (GM.)		RATIO TO BODY WEIGHT (%)		
	MALE	FEMALE	MALE	FEMALE	AVERAGE	MALE	FEMALE
Aschoff[1]	321		299-355				
Walmsley	325	300	310-340	280-320			
Gray	310	255	280-340	230-280			
Piersol	306	285	266-346	230-340		0.59	0.62
Boyd					0.60-0.80		
Greenwood and Brown[2]					0.45-0.70		
Weber[3]					0.66		
Müller[4]					0.55		
Robinson					0.42		
Smith	294	250	155-400	110-367		0.43	0.40

1. Aschoff, L.: Lectures on Pathology, New York, 1924, Paul B. Hoeber, P. 135.
2. Greenwood, M., and Brown, J. W.: A Second Study of the Weight, Variability and Correlation of the Human Viscera, Biometrika 9: 473-485, 1913.
3. Weber, E. H.: In Friedr. Hildebrandt's Handb. der Anatomie des Menschen, 4 Ausgabe, Braunschweig, 1831, Bd. 3, Pp. 125, 159, 161.
4. Müller, W.: Die Massenverhältnisse des menschlichen Herzens, Hamburg and Leipzig, 1883, Leopold Voss, Pp. 56, 57.

given by Boyd[29] and 0.42 per cent by Robinson.[30] Recently, H. L. Smith[31] has stated the heart weight to average 0.40 per cent of body weight for women and 0.43 per cent for men. This percentage is somewhat less in large individuals and higher in small individuals. According to Aschoff,[32] in conditions of wasting, the heart loses a smaller proportion than the body and therefore increases in relative weight.

In terms of absolute values, the reported normal heart weights also show considerable variation. Walmsley gives the average heart weight for males as from 310 to 340 gm., but the range is from 255 to 420. The average for females is stated as from 280 to 320 and the range from 200 to 400. Gray's values are from 280 to 340 gm. for males and from 230 to 280 for females. Smith's ranges for various body weights indicate normal heart weights varying between 155 and 400 gm. for men and between 110 and 367 for women, the averages being 294 and 250, respectively. The values of earlier investigators were probably too high because various pathological conditions leading to cardiac hypertrophy were inadequately eliminated from the so-called normal series upon which normal heart weights were based. Recent considerations of cardiac hypertrophy have employed as normal standards the figures given by Walmsley and H. L. Smith. The latter's figures would tend to be too low because, in his careful elimination of patients dying from some cardiac disorder, he necessarily included an unspecified but considerable percentage of patients dying from neoplastic and other cachectic diseases, so that many of the hearts had undoubtedly undergone some degree of atrophy. It is important to emphasize the rather wide range of normal heart weights in all the series stated. It is obviously possible that slight but significant degrees of hypertrophy could occur without affecting the heart weight sufficiently to take it out of the range of the normal.

There appears to be agreement in the literature that cardiac enlargement is associated with Graves' disease in a variable percentage of cases, which White[33] estimates as being between 0 and 40 per cent. These variations are due in part to the strictness with which the different observers eliminated causes of cardiac hypertrophy other than Graves' disease itself. Recent investigators have in general been careful to eliminate from their statistics cases with essential hypertension, rheumatic heart disease, and other associated cardiopathies. It is equally important, we believe, to set aside those cases in which auricular fibrillation and cardiac failure have developed, even though these complications are themselves part of the Graves' disease. There can be no difference of opinion as to the development of dilatation and hypertrophy when cardiac failure supervenes, no matter what its etiology. This is, therefore, also to be expected when cardiac failure develops in Graves' disease. The significance of auricular fibrillation and its relationship to cardiac hypertrophy will be considered later. At present it may be

stated that fibrillation is a new factor added to the Graves' disease per se, and in our consideration cases with established auricular fibrillation will be segregated from those that are entirely uncomplicated.

This report will deal with an attempt to answer the following questions: (1) Does cardiac hypertrophy occur in Graves' disease? (2) Under what circumstances does such hypertrophy occur? (3) What is the effect of the altered circulatory dynamics in determining whether the hyperthyroid heart will respond by hypertrophy?

Our considerations will be based on the results of various post-mortem examinations reported in the literature and upon our personal observations of autopsied cases of Graves' disease.

POST-MORTEM OBSERVATIONS OF HEARTS IN HYPERTHYROIDISM

The observations based on post-mortem studies of the hyperthyroid heart appear uniformly to support the occurrence of hypertrophy in a considerable percentage of cases. Weller and his coworkers[34] are almost alone in their opposition to this conclusion, but it may be justly objected that this opposition is based essentially on the microscopic evaluation of the presence of hypertrophy. They support their conclusions, however, by pointing out that the mean weight of thirty-five hearts of patients with Graves' disease was 393 ± 46 gm., while the controls averaged 323 ± 75 gm. The authors do not lay much stress on the difference of 70 gm. in the mean cardiac weights because of the great variability in both series. The average heart in Graves' disease exceeded the average control by 47 ± 94 gm., which fact indicates that this excess is not statistically significant. It should be noted that an average weight of 393 gm. would ordinarily indicate hypertrophy of the heart, but the authors' data present no information as to the body weights or the occurrence of associated hypertension, cardiac failure, or auricular fibrillation.

Fahr and Kühle[35] report the presence of hypertrophy and dilatation in 23 of 27 cases of what they term *Kropfherz*. Of their 27 cases, only 18 include patients with Graves' disease. The other 9 are cases of colloid goiter in patients who clinically showed evidence of cardiac disease. While the hearts in 23 of the total number of patients were supposed to be hypertrophied, this judgment was based on the pathologist's gross description together with the clinical evaluation of the heart's size. An actual study of the heart weights given in some of the case protocols indicates that the significantly large hearts were present in the group of 9 cases which are not examples of Graves' disease. Furthermore, in at least 7 of these 9 it is clear that the cardiac symptoms were due to rheumatic fever, severe coronary sclerosis or thrombosis, marked hypertension, or cardiac failure.

Of their 18 cases of Graves' disease, only 2 of the hearts weighed more than 350 gm. (and less than 400), while 3 others weighed between 300

and 350, and the average for 14 of these cases in which the heart weight was available was 279 gm. This compares with Smith's average of 250 gm. for females and 294 for males and Walmsley's average of 300 for females and 325 for males. Thus this group of cases shows a normal average cardiac weight although there was at least one case of cardiac failure.

Willius, Boothby, and Wilson[36] reported cardiac hypertrophy at autopsy in 16 of 21 cases. In this report, individual cases are not available for analysis. Only 2 have definitely hypertrophied hearts. The others are said to show a 5 to 10 per cent increase in weight. In this study, patients with hypertension, rheumatic fever, and cardiac failure are not excluded, and more than half of the patients were beyond the age of forty-five years.

Lang[37] reported partial or generalized hypertrophy of the heart in all of his eighteen cases. Inasmuch as he does not present individual case reports, one cannot comment on the significance of his findings.

Barker, Bohning, and Wilson[38] noted the presence of cardiac hypertrophy, seldom pronounced, in thirteen thyroid hearts, as indicated by an average weight of 438 gm. While the individual heart weights are not available, it is clear that some of these patients suffered from hypertension and that in 63 per cent of these cases there was some degree of cardiac failure.

Kepler and Barnes[39] in a series of eighty-six cases of hyperthyroidism without hypertension or other forms of heart disease found 49 per cent of the hearts to exceed the maximum normal weight as given by Smith,[31] and in 35 per cent of the cases to exceed this maximum normal weight by more than 20 gm. Detailed case reports and individual heart weights are not presented. However, in view of the disagreement as to the range of normal weights, too much importance cannot be attached to the cases that just exceeded Smith's maximum weight. No information is available in this report as to the exact amount by which these hearts exceeded Smith's maximum. There is no statement as to how many of the patients were suffering from auricular fibrillation or slight or moderate degrees of failure. It is clear, however, that nine of the cases included in the series showed *severe* failure. Since only sixteen of the eighty-six hearts weighed more than 400 gm. and only one of these weighed more than 500 gm., there was apparently no general occurrence of marked cardiac hypertrophy. In at least nine, and perhaps in all of them, the hypertrophy could be explained on the basis of cardiac failure.

Parkinson and Cookson[14] reported studies of the size and shape of the heart in toxic goiter and included observations on forty-three autopsied cases. They noted cardiac hypertrophy in twenty-two of these. As their report contains considerable detail with respect to individual cases, it lends itself to analysis more readily than those just discussed. Smith's values for normal hearts cannot be applied because the series does not

include the patient's usual body weight. Comparison of the given heart weights may be made with Walmsley's figures[28] for normal heart weights which are accepted by these authors. While Parkinson and Cookson's protocols contain heart weights, their conclusion as to the existence of hypertrophy is based on the personal opinion of the pathologist who described the hearts, and not on the actual weights themselves as compared with normal hearts.

Analysis of the individual cases reveals the following: Only 11 of the 43 cases exceeded Walmsley's maximum average weight of 320 to 340 gm. Five of these 11 patients suffered from auricular fibrillation, cardiac failure, or both. None of the remaining 6 hearts weighed more than 400 gm.; i.e., the hypertrophy was slight. One case showed rheumatic endocarditis. Some of these 6 patients may have suffered from hypertension which was said by the authors to exist in certain unspecified cases.

If the 5 patients suffering from cardiac failure or fibrillation are excluded from the series of 22 so-called hypertrophied hearts, the average weight of the remaining 17 hearts is 298 gm., as compared with 274 gm. for the group of 21 "nonhypertrophied" hearts. The average weight of the "hypertrophied" group, therefore, exceeded that of the "nonhypertrophied" group by less than 10 per cent, and was well within the mean normal range given by Walmsley (310 to 340 gm. for males, and 280 to 320 gm. for females). Thus on the basis of heart weight, 11 of the 43 hearts at most could be considered hypertrophied. Five of these 11 were hearts of patients with Graves' disease, complicated by auricular fibrillation or failure, and some or all of the remaining 6 were associated with hypertension. None of the latter 6 showed any marked degree of hypertrophy.

The review of these post-mortem studies reveals a high incidence of cardiac hypertrophy in Graves' disease. This incidence is greatly diminished if the diagnosis of hypertrophy is based on cardiac weights rather than on the pathologist's gross or microscopic description. The incidence is further diminished if dubious cases of Graves' disease are omitted, and if cases with associated hypertension or inflammatory or arteriosclerotic heart disease are eliminated. The remaining hypertrophied hearts frequently occurred in patients with cardiac failure or auricular fibrillation or both. If these cases are segregated, an indefinite, but quite small, percentage of cases remains in which cardiac hypertrophy of slight degree may be ascribed to the uncomplicated Graves' disease itself.

PERSONAL OBSERVATIONS

Because of the disagreement in the literature as to the incidence and degree of cardiac hypertrophy in Graves' disease, and because the published material does not adequately permit the necessary detailed case analysis, we have carefully studied the clinical histories and hearts of

twenty-seven cases of Graves' disease which have come to post-mortem examination at the Mount Sinai Hospital in the past eleven years. An additional group of cases in which the diagnosis was not absolutely certain or in which the data were inadequate was not utilized. No case of rheumatic heart disease was included. The hearts were studied anatomically both grossly and microscopically for the presence of associated cardiac abnormalities. In almost all cases the usual body weights (i.e., before the patient's illness reached the degree of severity requiring hospitalization) as well as those on admission were recorded. Several blood pressure readings were generally available. Careful evaluation was made as to the presence of hypertension and cardiac failure as well as of auricular fibrillation. The diagnosis of hypertension was made when the diastolic blood pressure was above 90 mm. or the systolic above 160 mm. The diagnosis of heart failure in these cases was based on the presence of symptoms and signs of left and right heart failure including orthopnea, cyanosis, peripheral edema, hepatic enlargement, ascites, increased venous pressure and circulation time, and pathological evidence of chronic passive congestion. While clinical and electrocardiographic data were studied, the diagnosis of coronary artery disease was based essentially on anatomical study of the vessels post mortem.

The hearts of these patients were studied with respect to weight and associated cardiac disease. The clinical history was studied with reference to the patient's weight, the existence and duration of auricular fibrillation, the presence of hypertension and of cardiac failure, the latter being confirmed by the evidence obtained at necropsy. These data are presented in Table II.

Fourteen of the 27 cases were considered as showing hypertrophy and thirteen as being within the range of normal heart weights (Table III). Both groups had an average age of forty-five years. Smith's figures for the normal range of heart weights for any given body weight were utilized as the basis for comparison. The patient's usual body weight was used to compute the expected normal cardiac weight. In a few cases in which the patient's exact weight was not available, the heart was considered hypertrophied if it exceeded Walmsley's maximum value for the mean range of normal cardiac weights. One heart (Case 4), included in the nonhypertrophied group, slightly exceeded the maximum normal weight as calculated from the body weight. However, this heart, weighing only 250 gm., could hardly be considered hypertrophied. Furthermore, it is probable the patient had lost considerable weight so that the body weight used as a basis for calculation was much below her usual body weight.

Six of the fourteen hypertrophied hearts occurred in patients who were suffering from definite symptoms of right heart failure. These hearts showed the highest percentage of hypertrophy of any in the series (40 per cent to 122 per cent beyond the maximum normal). Three

TABLE II

ANALYSIS OF 27 AUTOPSIED CASES OF GRAVES' DISEASE

CASE	AGE	SEX	BODY WEIGHT (LB.)		HEART WEIGHT (GM.)	BLOOD PRESSURE**	AURICULAR FIBRILLATION	CARDIAC* FAILURE	ASSOCIATED CARDIOPATHY
			USUAL	ADMISSION					
1	41	M	80	69	300	178/95; 138/68; 176/96	0	0	
2	45	F	147	124	675	118/78	0	+++	
3	38	F	120	87	200	140/50	0	0	
4	34	F	103	97	250	120/64	0	0	
5	35	F	118	112	340	148/66	0	0	
6	48	F	130	90	250	144/68	+	0	
7	65	F	87	75	150	150/90; 180/90; 148/60	0	0	Occlusion of marginal branch
8	64	F	-	-†	375	120/52	+	0	Narrowing of coronary arteries
9	40	F	150	136	490	100/70	+	+++	Old and recent coronary thrombosis
10	60	F	-	-‡	350	98/60	0	+++	
11	60	F	119	emaciated	360	170/80; 180/100	+	+++	
12	43	M	121	91	350	120/58	0	0	Marked coronary sclerosis
13	45	F	195	135	518	205/90; 154/88; 170/84	+	0	Moderate coronary sclerosis
14	47	M	127	95	300	130/64	0	0	Marked coronary sclerosis
15	32	F	149	131	250	110/58	0	0§	
16	30	F	140	126	415	160/60; 146/66; 166/0	0	++	
17	44	F	175	126	310	160/56; 112/50	0	0	
18	47	M	160	120	450	128/64	+	0	
19	42	F	-	140	270	128/70	0	0	
20	36	M	-	-	280	130/60	0	0	
21	50	M	145	105	740	184/70; 168/86	+	++	Marked coronary sclerosis
22	25	F	-	-†	360	150/68	0	0	
23	35	F	140	96	"small heart"	122/52	0	0	
24	56	F	175	141	300	165/70; 180/90	0	0	
25	46	M	152	122	280	160/120; 130/60; 180/50	0	±‖	
26	40	F	215	200	290	140/90; 105/70	0	0	
27	64	F	131	108	260	130/70; 150/60	0	0	

*++ indicates slight heart failure. +++ indicates moderate dyspnea at rest, moderate edema, cyanosis, orthopnea, enlarged liver, hydrothorax, or ascites.

†"Well developed and well nourished" (autopsy protocol).

‡"Short, slight stature, fairly well developed and nourished" (autopsy protocol).

§Terminal elevation of venous pressure. Hepatic cirrhosis found at autopsy.

‖No clinical evidence of cardiac failure. Passive congestion of viscera found at autopsy.

**Single readings are given when representative; multiple readings, when blood pressure was variable.

TABLE III

COMPARATIVE ANALYSIS OF HYPERTROPHIED AND NONHYPERTROPHIED HEARTS

CASE	HEART WEIGHT (GM.)	EXPECTED MAX. WEIGHT FROM SMITH'S STANDARDS (GM.)	PER CENT INCREASE	HYPERTENSION‖	AURICULAR FIBRILLATION	CARDIAC FAILURE	ASSOCIATED CARDIOPATHY
Group With Hypertrophied Hearts (14)							
21	740	333	122	+	+	+	Severe coronary narrowing
2	675	308	119	0	0	+	
13	518	371	39	+	+	0	Moderate sclerosis; left axis deviation
9	490	313	57	0	+	+	Coronary thrombosis
18	450	368	22	0	+	0	
16	415	295	41	+	0	+	
8	375*	-	-	0	+	0	Coronary narrowing
11	360	257	40	+	+	+	
22	360*	-	-	0	0	0	
12	350	278	26	0	0	0	Marked coronary sclerosis
10	350*	-	-	0	0	+	
5	340	255	33	0	0	0	
1	300	241	25	+	0	0	
14	300	292	3	0	0	0	Marked coronary sclerosis
Group With Nonhypertrophied Hearts (13)							
7	150	190	0	0	0	0	Occlusion left marginal branch
3	200	259	0	0	0	0	
4	250†	222	12†	0	0	0	
6	250	277	0	0	+	0	
15	250	313	0	0	0	terminal	
27	260	282	0	0	0	0	
19	270	295+	0	0	0	0	
20	280‡	-	-	0	0	0	
25	280	350	0	+	0	±§	
26	290	462	0	0	0	0	
24	300	366	0	+	0	0	
17	310	350	0	0	0	0	
23	"small"	295	0	0	0	0	

*Exceeds Walmsley's maximum heart weight.

†Even though the heart weight exceeds the expected maximum weight, the actual weight of 250 gm. is too low for this heart to be considered hypertrophied. Furthermore, the usual body weight was undoubtedly higher than the given weight used for calculation in view of the relatively small weight loss. (See Case 4 in Table II, and also text.)

‡The heart weight is within Walmsley's range for normal hearts.

§No clinical evidence of cardiac failure although passive congestion of viscera was found at necropsy.

‖See Table II for exact readings. Hypertension generally of the systolic and not always sustained.

of the six patients with heart failure also suffered from auricular fibrillation, and there were three additional cases with established fibrillation in patients who did not show significant symptoms of heart failure. Five patients were suffering from hypertension, three of these being included in the six cases with heart failure. Thus, eight of the fourteen hypertrophied hearts occurred in patients suffering either from cardiac failure or hypertension or both.

Of the six remaining hearts (and in these the hypertrophy was least marked) two (Cases 8 and 18) were in patients with auricular fibrillation; one of these and two additional cases (Cases 12 and 14) also showed severe coronary narrowing. There thus remained only two cases (Cases 5 and 22) of hyperthyroidism which showed cardiac hypertrophy (and that only of relatively slight degree) which did not suffer from cardiac failure, hypertension, auricular fibrillation, severe coronary sclerosis, or combinations of these conditions. Auricular fibrillation appeared to be a less significant factor as regards the degree of hypertrophy produced than hypertension or cardiac failure, except so far as it, itself, helped to produce the cardiac failure. It is also noteworthy that, in two (Cases 8 and 22) of the six apparently hypertrophied hearts without cardiac failure or hypertension, the presence of cardiac hypertrophy was uncertain, in view of the lack of data as to the patient's usual weight. Also three of these six cases showed severe coronary narrowing. In summary, only six of the total number of twenty-seven hearts (22.2 per cent) showed cardiac hypertrophy which could not readily be explained as being due to severe cardiac failure or hypertension. Only two of the twenty-seven (7 per cent) showed hypertrophy independent of the above conditions and of severe coronary narrowing and of auricular fibrillation, and these were among the cases showing the slightest degree of hypertrophy.

In this series of cases, therefore, we seem to substantiate more clearly the implications of our analysis of post-mortem cases in the literature, that cardiac hypertrophy occurs infrequently and only to a slight degree in Graves' disease uncomplicated by cardiac failure, auricular fibrillation, hypertension, or some associated cardiopathy. Only when these complications are not carefully excluded, do the figures for hypertrophy reach 50 per cent in cases of Graves' disease.

Considering the cases with nonhypertrophied hearts, it might be said that almost invariably the converse of the above is true, namely, that in the absence of cardiac failure, hypertension, associated cardiopathy or auricular fibrillation, cardiac hypertrophy does not occur in Graves' disease. Only occasional exceptions to this statement are presented. In one case (Case 7) there was a labile blood pressure, occasionally reaching the range which we would term hypertension. In another case (Case 24) the systolic pressure was high, while the diastolic pressure was within normal limits. In one case without hypertrophy there was

auricular fibrillation of unknown duration, and in one (Case 17) fibrillation only shortly before death. In none of the patients of this group was there definite clinical evidence of moderate or severe cardiac failure. In one of these cases (Case 15) there appeared to be terminal clinical evidence of cardiac failure (edema, elevated venous pressure, and enlarged liver), but this was complicated by the finding of hepatic cirrhosis at autopsy. In another case (Case 25), while there was no clinical evidence of cardiac failure, post-mortem examination showed some evidences of passive congestion of the viscera. While there were many small hearts in this nonhypertrophied group, none of them could be truly said to have shown atrophy, as measured by Smith's normal standards. *In summarizing the entire group*, it appears that there is an almost perfect correlation between uncomplicated Graves' disease and normal cardiac size and likewise an almost perfect correlation between the occurrence of hypertrophy and the presence of hypertension, cardiac failure, cardiopathy, and auricular fibrillation.

CIRCULATORY DYNAMICS OF GRAVES' DISEASE AS RELATED TO CARDIAC SIZE

The various observers who have accepted the existence of cardiac hypertrophy in Graves' disease have attempted to explain its occurrence either on the basis of myocardial damage or on the mechanical effects of altered circulatory dynamics. The studies of Means and Richardson,[40] McEachern and Rake,[41] Rake and McEachern,[42] Weller and his coworkers,[34] Thomas,[21] and others indicate clearly that the amount of demonstrable myocardial damage is inadequate to explain the development of cardiac hypertrophy. In our detailed macroscopic and microscopic study of the above cases we were likewise unable to find any constant significant pathological alterations which could be ascribed to Graves' disease. Of course these findings do not preclude the possibility that the excessive or abnormal thyroid secretion may have caused sufficient functional damage to lead to fibrillation and cardiac failure. In the latter event, cardiac dilatation and hypertrophy could occur secondarily as a result of failure.

The most significant changes in circulatory dynamics generally accepted as occurring in Graves' disease include tachycardia, increased pulse pressure, widening of the peripheral vascular bed, increased speed of the circulation, increased blood volume, increased venous return to the heart, and increased minute cardiac output. These factors have been invoked singly and jointly to explain cardiac hypertrophy in Graves' disease. Boas[43] pointed out that the vessels in the thyroid gland may become so enlarged that an arteriovenous fistula is simulated in this organ. He believed that this may play a part in overloading the heart by producing an increase in the minute output. This in turn may contribute to dilatation and hypertrophy and ultimately to failure. Many authors have explained the development of cardiac hyper-

trophy as the result of increased cardiac work. This point of view indicates essentially that the increase in cardiac weight occurs in Graves' disease as the result of work hypertrophy.

There is considerable evidence that work hypertrophy in this sense of the term does not occur. (Horvath,[44] von Frey,[45] Hasebrock,[46] von Weiszäcker,[47] etc.) According to Wiggers,[48] an increased minute volume or a tachycardia does not in itself result in cardiac hypertrophy. Without reviewing the varied experimental, clinical, and pathological evidence supporting these conclusions, it need merely be emphasized that all observers, even those reporting the occurrence of hypertrophy in Graves' disease, admit that normal cardiac size is at least as frequent. Since tachycardia and increased minute output are practically invariable in Graves' disease, one would expect few or no exceptions to the occurrence of hypertrophy if these factors in themselves were capable of producing it.

The best available evidence indicates that cardiac dilatation and hypertrophy are, in general, responses to an increased diastolic tension or lengthening of the cardiac muscle fibers. Such increase in tension results from any factor which increases the diastolic volume of blood in the cardiac chambers. When this occurs, the effect of the dilatation with the consequent increase in diastolic tension results in a more forceful contraction and increased systolic output, thus enabling the heart to eject the larger quantity of blood (the law of the heart). Hypertrophy is apparently the result of the same stimulus as dilatation but requires time for its development. If the cardiac rate is constant, dilatation and eventually hypertrophy occur as a result of factors which (1) either increase the resistance to outflow from the heart, (2) increase the inflow to the heart, or (3) produce severe myocardial weakness. The first two are mechanical factors which explain the occurrence of hypertrophy in valvular disease, essential hypertension, and arteriovenous aneurysm, as well as the cases of Graves' disease with hypertension. In the third group the cardiac muscle suffers intense damage so that it is unable to expel its normal diastolic content of blood, and it undergoes dilatation and hypertrophy in an attempt to compensate for the increasing residuum of blood. This is the explanation for dilatation and hypertrophy in various forms of infectious myocarditis, in occasional cases of severe coronary sclerosis and thrombosis, and with intense toxic damage to the myocardium, such as probably occurs in Graves' disease when the heart is injured sufficiently to cause failure. This explanation could apply to the cases in the above series in which cardiac hypertrophy was present in cases of Graves' disease associated with right and left heart failure.

In the cases of Graves' disease unassociated with cardiac failure or hypertension, there is neither adequate myocardial damage nor increased resistance to outflow to lead to cardiac hypertrophy. However, the

various changes in circulatory dynamics all tend to produce a marked increase in the venous return to the heart and increase in cardiac output per minute. There are two compensatory mechanisms for handling the increased venous return; namely, by an increased rate of cardiac contraction with the same output per beat, or by a constant rate with increased ejection per beat. Both of these may be increased in varying degree.

As stated above, the tachycardia in itself will not result in dilatation and hypertrophy. These will occur only to the extent that the increase in cardiac output results from an increased diastolic volume and consequent increased systolic output. In cases of true arteriovenous aneurysm, the increased return to the heart is essentially handled by an increased systolic output since there is no significant tachycardia. Thus, cardiac hypertrophy of marked degree is generally present. In Graves' disease, however, a significant tachycardia is an essential feature of the disease. *The occurrence of hypertrophy depends on the extent to which the increased cardiac output per minute is due to an increased output per beat.* In other words, systolic output rather than minute volume is important in the production of cardiac hypertrophy.

The importance of the systolic output rather than of the minute output in determining cardiac hypertrophy in Graves' disease has hardly been considered except in a brief comment by Harrison.[49] There is, furthermore, no uniform agreement as to whether the output per beat is actually increased in Graves' disease. In some of the reports indicating a marked increase in the minute cardiac output, there is no statement as to the stroke output nor are there adequate data from which this can be computed. The findings of Field, Bock, Gildea, and Lathrop,[50] of Davies, Meakins, and Sands,[51] showing an increased stroke output, and of Rabinowitch and Bazin[52] and of Plesch[53] showing a slight diminution in systolic output have been subjected to criticism because of the questionable accuracy of their methods. The more recent statements that the systolic output is increased in Graves' disease depend on the observations of Fullerton and Harrop.[54] These authors studied the cardiac output in eight cases of Graves' disease before and after lugolization and thyroidectomy. Both the minute volume and the systolic output diminished after thyroidectomy. They, therefore, concluded that the systolic output had been elevated in these cases before treatment. An analysis of their figures, however, shows that the average systolic output before operation was 57 c.c. which is slightly less than Grollman's[55] average of 62 c.c. and well within the range of 38 to 84 c.c. for normal individuals. Since their average minute cardiac output of 5.5 l. is considerably higher than Grollman's average of 3.87 l. per minute for normal persons; it is clear that, while the minute volume was definitely elevated in their cases of Graves' disease, this elevation was

entirely due to tachycardia. The reduction in systolic output from an average normal figure to a low normal one following treatment cannot be taken to indicate that the original value was abnormally high. Thus the experiments of Blalock and Harrison[56] on normal dogs indicate that thyroidectomy can cause a reduction in systolic output even when this is originally normal. Furthermore, they found that on feeding thyroid to animals, the cardiac output could be increased purely as a result of tachycardia, the systolic output in fact being diminished. Bansi[57] and Bansi and Groscurth[58] found that the stroke volume tended to be diminished in Graves' disease. Finally in eleven cases of uncomplicated, fully developed Graves' disease, Liljestrand and Stenström[60] found a marked increase in cardiac output, but the systolic output was within normal limits. The average systolic output was 63 c.c. and the range was between 49 and 83 c.c. This corresponds to Grollman's average of 62 c.c. and range of 38 to 84 c.c. for normal individuals.

Thus there is no convincing proof that the systolic output is increased in Graves' disease. The considerable increase in minute output is brought about entirely or almost entirely by means of an increased pulse rate, the diastolic volume of the heart remaining constant. On this basis one would expect that hypertrophy would be either entirely absent or very slight in Graves' disease. An analysis of actual cardiac weights such as we have presented supports these theoretical considerations. The occasional instance in which hypertrophy is present (independent of cardiac failure, associated cardiopathy, fibrillation or hypertension) may be explained either by the uncertainty as to the exact range of normal cardiac weights or by the fact that patients may differ somewhat in the extent to which the tachycardia will completely compensate for the increased venous return to the heart. Thus, occasionally, as seen in the figures of Fullerton and Harrop,[54] in addition to the tachycardia a patient may show a slight absolute increase in his systolic output. In such a case there will be a slight degree of cardiac hypertrophy.

Our observations indicate that, so far as hypertension is a factor in the production of hypertrophy, this may be only of the systolic variety. Furthermore, a high pulse pressure in the absence of either systolic or diastolic hypertension did not cause hypertrophy.

The relationship of established auricular fibrillation to the development of cardiac hypertrophy is not entirely clear. There are no adequate studies on the effect of established auricular fibrillation on heart size in the absence of organic heart disease. When auricular fibrillation is present, it is almost invariably associated with clinical evidence of organic heart disease, as indicated by the recent report of Maher and Sittler.[59] The very presence of this arrhythmia is indicative of a rather marked toxic effect on the heart. Almost always the fibrillation, if prolonged, is associated with cardiac failure. The failure probably results

from the same toxic injury to the myocardium that produced the auricular fibrillation, but the development of fibrillation may hasten or precipitate the onset of failure.

In two of our cases included among the hypertrophied hearts, there was auricular fibrillation without hypertension or cardiac failure. One of these (Case 18) showed the next to the least degree of hypertrophy in the series. In the other (Case 8) the presence and degree of hypertrophy were uncertain because the patient's body weight was unknown. Since in a third case with established fibrillation (Case 6) there was no hypertrophy at all, hypertrophy is not an invariable consequence of this arrhythmia. When hypertrophy did result, it could be postulated that the fibrillation was already associated with early cardiac failure insufficient to show overt clinical signs. On the other hand, these two cases, as well as the other two of uncomplicated Graves' disease showing cardiac hypertrophy, might be interpreted as forming that small percentage in which the increased minute cardiac output is partly effected by a minor increase in stroke output with consequent development of hypertrophy.

SUMMARY

1. A study was made of the occurrence and pathogenesis of cardiac hypertrophy in 27 fatal cases of Graves' disease, in which the hearts were studied anatomically. A heart was considered hypertrophied if its weight exceeded Smith's standard of maximum normal heart weight for a given body weight and sex. In a few cases in which body weights were not available, a heart was considered hypertrophied if it exceeded Walmsley's maximum for the mean range of normal heart weights.

2. Among these twenty-seven cases cardiac hypertrophy was found present in fourteen (52 per cent) and absent in thirteen.

3. The six hearts showing the greatest degree of hypertrophy (40 to 122 per cent increase in heart weight) occurred in patients with well-marked right heart failure, associated in some cases with hypertension, severe coronary sclerosis and narrowing, or established auricular fibrillation. In two other cases with moderate cardiac hypertrophy there was essential hypertension without cardiac failure. Two other patients with slight or uncertain hypertrophy had suffered from established auricular fibrillation and in one of these there was also severe coronary sclerosis.

4. Only four of the twenty-seven cases of Graves' disease (14 per cent) showed cardiac hypertrophy independent of cardiac failure, essential hypertension or auricular fibrillation. In two of these there was marked coronary sclerosis. These cases showed the mildest degree of cardiac hypertrophy. Thus only two cases (7 per cent) showed cardiac hypertrophy (of very slight degree) independent of the various pathological states just mentioned.

5. A study of the literature reveals an almost general agreement that cardiac enlargement or hypertrophy occurs in from 30 to 50 per cent of the cases. The implication in these reports is that the cardiac enlargement is a direct consequence of Graves' disease, but no adequate explanation is provided as to why cardiac enlargement is not invariably present, or what specific factors determine the occurrence of enlargement in some cases but not in others. Considering only the autopsied cases, it is evident that where specific case reports are available, such hypertrophy occurred almost invariably in association with cardiac failure, essential hypertension, auricular fibrillation or severe coronary artery disease.

6. The commonest explanation of cardiac hypertrophy in Graves' disease is that it results from the increased work of the heart as indicated by increased cardiac output. It is pointed out, however, that increased cardiac output in Graves' disease is almost always due to tachycardia alone, while the systolic output almost invariably is not elevated. Since dilatation and hypertrophy depend on the increased diastolic tension which would be translated into increased systolic output, there should theoretically be no significant hypertrophy in uncomplicated cases of Graves' disease.

7. The relationship of cardiac failure, hypertension, and auricular fibrillation to cardiac hypertrophy is discussed.

8. It is concluded that cardiac hypertrophy in uncomplicated Graves' disease is quite uncommon and is of slight degree. When present in a given case it indicates that the increased cardiac output in that case was effected not only by tachycardia but also by an increased systolic output.

The authors wish to thank Dr. R. Lewisohn and Dr. Edwin Beer for the use of the cases on their services.

REFERENCES

1. Graves, R. J.: Clinical Lectures Delivered During the Sessions of 1834-35 and 1836-37, Adam Waldie, Philadelphia, 1838, p. 134.
2. Marsh, Sir H.: Dilatation of the Cavities of the Heart: Enlargement of the Thyroid Gland, Dublin J. M. Sc. 20: 471, 1842.
3. Stokes, W.: The Diseases of the Heart and the Aorta, Philadelphia, 1854, Lindsay and Blakiston, p. 278.
4. Pässler, H.: Erfahrungen über die Basedow'sche Krankheit, Deutsche Ztschr. f. Nervenheilk. 6: 210, 1895.
5. Kraus, F.: Über das Kropfherz: Beziehungen zwischen Struma und Morbus Basedowii, Wien. klin. Wchnschr. 12: 416, 1899.
6. Kocher, A.: Ueber Morbus Basedowi, Mitt. a. d. Grenzgeb. d. Med. u. Chir. 9: 1, 1902.
7. Murray, G. R.: Exophthalmic Goitre and Its Treatment, Brit. M. J. 2: 1245, 1905.
8. Schultze, K.: Zur Chirurgie des Morbus Basedow, Mitt. a.d. Grenzgeb. d. Med. u. Chir. 16: 161, 1906.
9. Dietlen, H.: Herz und Gefässe im Röntgenbild, Leipzig, 1923, J. A. Barth, pp. 257, 258.
10. Bickel, G.: La mort subite par arrêt primitif du coeur dans la maladie de Basedow, Ann. de méd. 13: 593, 1923.

11. Sattler, H.: Basedow'sche Krankheit in Graefe-Saemisch Handb. d. ges. Augenheilk. Leipzig, 1909, W. Engelmann, ed. 2, Vol. 9, Pt. 2, p. 13.
12. Burnett, C. T., and Durbin, E.: The Signs and Symptoms of Heart Changes in Toxic Goiter, Am. Heart J. 8: 29, 1932.
13. Meyer-Borstel, H.: Über Form- und Grössenveränderungen des Herzens bei Struma, Fortschr. a. d. Geb. d. Röntgenstrahlen 41: 695, 1930.
14. Parkinson, J., and Cookson, H.: The Size and Shape of the Heart in Goitre, Quart. J. Med. 24: 499, 1931.
15. Rösler, H.: Das Röntgenbild des Herzens beim Hyperthyreoidismus, Wien. Arch. f. inn. Med. 15: 539, 1928.
16. Assmann, H.: Die klinische Röntgendiagnostik der inneren Erkrankungen. ed. 5, Pt. 1, F. C. W. Vogel, Berlin, 1934, p. 46.
17. Hashimoto, H.: The Heart in the Experimental Hyperthyroidism With Special Reference to Its Histology, Endocrinol. 5: 579, 1921.
18. Cameron, A. T., and Carmichael, J.: Contributions to the Biochemistry of Iodine: III. The Comparative Effects of Thyroid and Iodide Feeding on Growth in White Rats and in Rabbits, J. Biol. Chem. 45: 69, 1920.
19. Simonds, J. P., and Brandes, W. W.: The Size of the Heart in Experimental Hyperthyroidism, Arch. Int. Med. 45: 503, 1930.
20. Yater, W. M.: The Mechanism of Adjustment of the Circulation in Hyperthyroidism (Thyrotoxicosis), Am. Heart J. 8: 1, 1932.
21. Thomas, H. M., Jr.: The Heart in Hyperthyroidism, Ann. Int. Med. 5: 184, 1931. Idem: Heart in Hyperthyroidism, The Cyclopedia of Medicine, Philadelphia, 1932, F. A. Davis Co., Vol. 3, pp. 197-203.
22. Hurxthal, L. M.: Heart Failure and Hyperthyroidism With Special Reference to Etiology, Am. Heart J. 4: 103, 1928.
23. Hurxthal, L. M., Menard, O. J., and Bogan, M. E.: The Size of the Heart in Goiter: A Teleroentgenographic Study, Am. J. M. Sc. 180: 772, 1930.
24. Lahey, F. H.: Hyperthyroidism Associated With Cardiac Disorders, Surg., Gynec. & Obst. 50: 139, 1930.
25. Tandler, J.: Anatomie des Herzens, Bardeleben's Handbuch der Anatomie des Menschen, Jena, 1913, Gustav Fischer, Vol. 3, pt. 1.
26. Gray, H.: Anatomy, ed. 25, New York, 1932, Longmans, Green and Co., p. 620.
27. Piersol, G. A.: Human Anatomy, ed. 9, revised by G. C. Huber, Philadelphia, 1930, J. B. Lippincott Co., p. 693.
28. Walmsley, T.: Quain's Elements of Anatomy, London, 1929, Longmans, Green and Co., Vol. 4, Pt. 3, pp. 119-121.
29. Boyd, R.: Table of the Weights of the Human Body and Internal Organs, Arranged from 2,614 Post Mortem Examinations, Phil. Trans. Roy. Soc. Lond. 151: 241, 1861. (Quoted by Bardeen, C. R.: Am. J. Anat. 23: 423, 1918.)
30. Robinson, A.: Quoted by Walmsley.[28]
31. Smith, H. L.: The Relation of the Weight of the Heart to the Weight of the Body and of the Weight of the Heart to Age, Am. Heart J. 4: 79, 1928.
32. Aschoff, L.: Pathologische Anatomie, ed. 7, Jena, 1928, Gustav Fischer, Vol. 1, p. 63.
33. White, P. D.: Heart Disease, New York, 1932, The Macmillan Co., p. 379.
34. Weller, C. V., Wanstrom, R. C., Gordon, H., and Bugher, J. C.: Cardiac Histopathology in Thyroid Disease. Preliminary Report, Am. Heart J. 8: 8, 1932.
35. Fahr, T., and Kühle, J.: Zur Frage des Kropfherzens und der Herzveränderungen bei Status Thymicolymphaticus, Virchows Arch. f. path. Anat. 233: 286, 1921.
36. Willius, F. A., Boothby, W. M., and Wilson, L. B.: The Heart in Exophthalmic Goiter and Adenoma With Hyperthyroidism, M. Clin. North America 7: 189, 1923.
37. Lang, W.: Zur Frage der Basedowschilddrüse und der basedowifizierten Struma, Mitt. a. d. Grenzgeb. d. Med. u. Chir. 41: 536, 1929.
38. Barker, P. S., Bolning, A. L., and Wilson, F. N.: Auricular Fibrillation in Graves' Disease, Am. Heart J. 8: 121, 1932.
39. Kepler, E. J., and Barnes, A. R.: Congestive Heart Failure and Hypertrophy in Hyperthyroidism: A Clinical and Pathological Study of 178 Fatal Cases, Am. Heart J. 8: 102, 1932.
40. Means, J. H., and Richardson, E. P.: The Diagnosis and Treatment of Diseases of the Thyroid, New York, 1929, Oxford University Press, Vol. IV, p. 138.

41. McEachern, D., and Rake, G.: A Study of the Morbid Anatomy of Hearts From Patients Dying With Hyperthyroidism, Bull. Johns Hopkins Hosp. 48: 273, 1931.
42. Rake, G., and McEachern, D.: A Study of the Heart in Hyperthyroidism, Am. Heart J. 8: 19, 1932.
43. Boas, E. P.: Cardiac Disorders Accompanying Exophthalmic Goiter: Some Factors in Their Pathogenesis, J. A. M. A. 80: 1683, 1923.
44. Horvath, A.: Über die Hypertrophie des Herzens, Wien und Leipzig, 1897, W. Braumüller.
45. Von Frey, M.: Physiologische Bemerkungen über die Hypertrophie und Dilatation des Herzens, Deutsches Arch. f. klin. Med. 46: 398, 1890.
46. Hasebroek, K.: Die Entwicklungsmechanik des Herzwachstums, sowie der Hypertrophie und Dilatation des Herzens und das Problem des extrakardialen Blutkreislaufes, Arch. f. Physiol. 168: 247, 1917.
47. Von Weiszäcker, Fr.: Die Entstehung der Herzhypertrophie, Ergbn. d. inn. Med. u. Kinderh. 19: 377, 1921.
48. Wiggers, C. J.: Modern Aspects of the Circulation in Health and Disease, ed. 2, Philadelphia and New York, 1923, Lea and Febiger, p. 570.
49. Harrison, T. R.: In discussion of Kepler and Barnes.[39]
50. Field, H., Jr., Bock, A. V., Gildea, E. F., and Lathrop, F. L.: The Rate of the Circulation of the Blood in Normal Resting Individuals, J. Clin. Investigation 1: 65, 1924.
51. Davies, H. W., Meakins, J., and Sands, J.: The Influence of Circulatory Disturbances on the Gaseous Exchange of the Blood: V. The Blood Gases and Circulation Rate in Hyperthyroidism, Heart 11: 299, 1924.
52. Rabinowitch, I. M., and Bazin, E. V.: The Output of the Heart Per Beat in Hyperthyroidism, Arch. Int. Med. 38: 566, 1926.
53. Plesch, J.: Hämodynamische Studien, Ztschr. f. exper. Path. u. Therap. 6: 380, 1909.
54. Fullerton, C. W., and Harrop, G. A., Jr.: The Cardiac Output in Hyperthyroidism, Bull. Johns Hopkins Hosp. 46: 203, 1930.
55. Grollman, A.: The Cardiac Output of Man in Health and Disease, London, 1932, Baillière, Tindall and Cox, p. 87.
56. Blalock, A., and Harrison, T. R.: The Effects of Thyroidectomy and Thyroid Feeding on the Cardiac Output, IV. Regulation of the Circulation, Surg., Gynec. & Obst. 44: 617, 1927.
57. Bansi, H. W.: Kreislaufstudien beim Basedow u. bei der Herzneurose, Ztschr. f. klin. Med. 110: 633, 1929.
58. Bansi, H. W., and Groscurth, G.: Die Kreislaufleistung beim Basedow und Myxödem, Ztschr. f. klin. Med. 116: 583, 1931.
59. Maher, C. C., and Sittler, W. W.: The Cardiovascular State in Thyrotoxicosis, J. A. M. A. 106: 1546, 1936.
60. Liljestrand, G., and Stenström, N.: Blood Flow and Blood Pressure in Exophthalmic Goiter, Acta. med. Scandinav. 63: 99, 1925.
61. Smith, F. M., and MacKay, E. M.: The Relation of Heart Weight to the Basal Metabolism as Varied by Thyroid Administration, J. Exper. Med. 55: 903, 1932.
62. Boas, E. P., and Landauer, W.: The Effect of Elevated Metabolism on the Heart of Frizzle Fowl: II. Increased Ratio of Heart to Body Weight, Am. J. M. Sc. 188: 359, 1934.

Department of Clinical Reports

SUBACUTE *STREPTOCOCCUS VIRIDANS* ENDOCARDITIS —FAILURE OF HUMAN IMMUNE TRANSFUSION AND SERUM THERAPY*

EUGENE S. KILGORE, M.D.
SAN FRANCISCO, CALIF.

THREE therapeutic failures are here put on record because in them the trials of human immune transfusion and serum therapy were carried farther than would be possible ordinarily, and farther than in most of the hitherto reported like attempts.

Similar treatment of this disease in amounts comparable to those here employed has been described in satisfactory detail for only three or four previous cases. Lamb[1] gave 2,600 c.c. immune blood in the course of several transfusions and later gave serum from an immunized horse. His patient died and apparently received no more benefit from the immune blood than he would have from nonimmune transfusion. A patient of Howell, Portis, and Beverley[2] died after receiving 3,100 c.c. whole immune blood in twelve transfusions. Kurtz and White,[3] after withdrawing 1,000 c.c. blood from their patient, transfused 1,800 c.c. at once from three immunized donors, and in the next fifteen weeks gave five 500 c.c. immune transfusions. Their patient died after a seventeen months' illness, and they recognized no appreciable beneficial effects of the treatment.

Kurtz and White analyze the literature on the immune hemotherapy of this disease, and refer to the reports of Wordley,[4] Robertson,[5] Dick,[6] and of Howell, Portis, and Beverley[2] as encouraging. As already stated, the patient of the last named authors died—one week after the last transfusion—and the encouragement was derived merely from the apparent clinical improvement for a few days following each transfusion and from some increase in the patient's agglutinins for the infecting organisms. Wordley's patient recovered after three "immunotransfusions" (amounts not stated), and Dr. Wordley now kindly writes to me that the man is still well, ten years after treatment. The donors were immunized with stock vaccine, not the patient's organism. Unfortunately I cannot feel with Kurtz and White that this was a typical case of subacute bacterial endocarditis. Blood cultures were sterile; the fever apparently was more violent than most

*From the Department of Medicine, University of California Medical School.

commonly occurs in this disease; there were petechiae and sudden enlargement and tenderness of the spleen but not the so common small tender cutaneous nodules; and the diagnosis of valvulitis rested only on reduplication of the first heart sound at one time, a soft apical systolic murmur at the height of the fever, and a "blurring of the first cardiac sound on exertion" after recovery.

Robertson reports no case of his own, but refers to one published by Heyd.[7] This patient was given "about six transfusions of from 200 to 350 c.c." from a donor previously immunized to the *Streptococcus viridans* obtained from the patient's blood; and "at the end of three months the blood culture was negative and clinically the patient was cured." No diagnostic details are given other than the designation "a case of endocarditis"; and Dr. Heyd writes me that he has no knowledge of the patient's later history. In view of the frequency of remissions, this report would be unacceptable evidence of a cure even if satisfactory diagnostic data were supplied. Dick's patient received within a few days four transfusions of 25 c.c. each from an immunized donor, was thought to feel better after each, but died suddenly two days after the last. Since the paper by Kurtz and White, Sinek[8] has described two further trials of immune transfusions for this disease, apparently in small amounts. Both were failures.

CASE REPORTS

CASE 1.—(Referred by Dr. J. L. Mudd of Merced, Calif., and treatment carried out by him.) A rancher, aged twenty-five years, came from Italy to California ten years ago. He denied having had rheumatism previously and all other infectious diseases except "influenza" for a few days in 1928 and nondisabling pain in fingers, wrists, and ankles for a few weeks in 1930. In August, 1932, there were vague, bilateral chest pain, albuminuria with a few casts and many bacteria, 13,000 white cells, and 3,500,000 red cells; he continued work. In early December, 1932, he had sore throat, headache, and anorexia. A week later he quit work because of a swollen, painful wrist; in a few days the wrist improved, and an ankle swelled and hurt; and from then on he suffered migrating pain without swelling in various joints and muscles, with malaise, anorexia, constipation, loss of weight, low fever, frequent night sweats, and an occasional chill. Twice in January, 1933, he had rather severe pain for one day—once in the left flank, once in the right flank. Hospital observation in San Francisco, January 23-30, revealed a rather thin and pale man, with a small, tender, slightly elevated, but not discolored, spot the size of a pinhead on one finger pad, another on one palm—both spots disappearing in two or three days. The apex impulse and dullness were 2 cm. outside nipple line with soft blowing systolic murmur at apex; blood pressure was 110/85; liver and spleen were not enlarged; and remainder of physical examination was not remarkable. Some albuminuria was present with a few hyaline and granular casts and leucocytes; hemoglobin, 62 per cent, red cells, 3,480,000; white cells, 12,150 (90 per cent neutrophiles); Wassermann test, negative; electrocardiogram, normal. *Streptococcus viridans* in two blood cultures.

Irregular fever, usually 38° to 39° C. and occasionally 40° C. in the afternoon, continued during hospitalization and thereafter. Small, tender, reddish, indurated spots appeared repeatedly on various parts of the body, and several times deeper

pain lasting for a day or two was interpreted as embolism to the spleen and elsewhere. A third blood culture in March and a fourth in April remained sterile after ten days' incubation; a fifth in May produced the same organism. Before beginning the transfusions in March the hemoglobin had declined to 42 per cent and the red cells to 2,820,000.

Treatment.—In addition to symptomatic measures, immunotherapy was attempted with the cooperation of six of the patient's relatives—all robust men, with negative Wassermann tests, aged about twenty-five to forty-five years. Under the direction of Dr. Karl Meyer, vaccine was prepared from the patient's organism *(Streptococcus viridans alpha)* without heat, the organisms being killed by merthiolate 1:5,000 and used in a dilution of 1,000,000 to the cubic centimeter in normal salt solution. In rotation each of the subjects was given vaccine subcutaneously about as follows: 0.1 c.c. (in some 0.2) every other day for three doses; four or five days' rest; three doses of 0.4 c.c. at forty-eight-hour intervals; then a similar rest period followed by three doses of 0.6 c.c.; another rest; and finally three doses of 1.5 c.c., the whole initial period of immunization lasting about thirty-three days. Following this their serums all showed a moderate agglutinin response (3- or 4-plus reaction in 1:40 dilution), whereas it had been weak or absent in a 1:20 dilution in the early stage of immunization; and they were then used to contribute whole blood or serum. Two or three of them who served in the later treatments were given several more 1.5 c.c. doses of vaccine. By direct matching of bloods, four were reported satisfactory for blood donors. With the use of two of these, however, reactions occurred, and thereafter their blood as well as that of the two who did not match was used for the production of serum. Two served repeatedly for transfusions, the citrate method being used. Over a period of sixty-five days, seven transfusions and seven intramuscular serum injections were given the patient, the last one a week before his death. The dates and amounts were as follows (B indicates transfusion of citrated blood, S indicates serum, and the numerals indicate quantities in c.c.): March 25, 1933, B 200 (chill interrupted transfusion); March 31, B 250; April 8, B 300; April 17, B 50 (transfusion again interrupted by reaction); April 20, S 140; April 24, B 270; April 28, S 93; May 2, B 300; May 4, S 130; May 8, S 125; May 13, S 90; May 19, B 290; May 24, S 115; May 29, S 55. Total whole blood, 1,660 c.c.; total serum, 748 c.c.

It was thought at times that the temperature was lower and that the patient felt better for two or three days after the transfusions or serum injections. A review of the chart, however, shows no consistent effect of the treatments; and the temperature was so irregular before treatment began that the few apparent remissions after treatments may be attributed to chance variations. Streptococci were found in the blood stream after six weeks of the treatment. The patient gradually lost strength and died June 6, 1933. Necropsy permit was refused.

CASE 2.—Housewife, aged forty-five years, was born and brought up in Hungary. She had always been strong and well, and denied having had rheumatism and all other infectious diseases. In mid-July, 1935, she complained for three or four days of pain in the right flank and lower back. A few days later there was pain for a day or two in the right leg. Examination then showed slight paleness, a rather "bumpy" first heart sound with blowing systolic murmur at the apex, a little tenderness but no swelling in the right calf, and on the palmar surface of one fingertip a tender, slightly elevated, pink spot the size of a pinhead. Two or three similar spots had been observed in the preceding week, each lasting a day or two. Otherwise physical examination was not remarkable—no evidence of cardiac or splenic enlargement, no suggestion of focal infection in mouth or throat. There were a slight trace of albumin, a few hyaline and granular casts and leucocytes in the urine. Hemoglobin was 56 per cent; red cells, 3,390,000; white cells, 10,500; neutrophiles, 80 per cent;

small lymphocytes, 16 per cent; eosinophiles, 1 per cent; transitionals, 3 per cent. Wassermann test negative. From Aug. 5, 1935, to her death January 8, 1936, the patient was observed in hospital. *Streptococcus viridans* was obtained in the first blood culture. There was continuous low grade fever.

Treatment.—On the advice of Dr. Karl Meyer, the prospective donors for this patient were immunized with the patient's organism prepared and administered according to the technic of Dr. A. P. Krueger.[9] The "undenatured" vaccine (organisms killed mechanically without heat or chemicals) was prepared through Dr. Krueger's courtesy in his laboratory, 1 c.c. of the vaccine containing 1,000,000 organisms. Each donor was immunized by hypodermic injections as follows: First day, 0.2 c.c.; second day, 0.2 c.c.; third day, 0.2 c.c.; fourth day, 0.3 c.c.; sixth day, 0.3 c.c.; eighth day, 0.4 c.c. On or soon after the tenth day he was bled. Thereafter, to maintain immunity, he was given 0.3 c.c. twice a week; or, if he had not received this sustaining immunization regularly, he was given 0.3 c.c. three times on alternate days before his next blood donation.

The immune donors consisted of the patient's husband, son, and five other healthy young men, all Wassermann negative. Three were utilized for direct transfusions; the other four contributed blood, the serum from which was injected intramuscularly. In the following treatment record B indicates direct blood transfusion, S indicates serum injection, and the numerals indicate quantities in c.c.: August 28, B 380; September 1, S 23; September 3, S 35; September 4, S 32; September 5, S 40; September 7, S 50; September 8, S 51; September 9, S 53; September 10, S 40; September 11, B 420; September 20, S 10; September 21, S 50; September 24, S 7; September 25, S 40; October 10, B 450; October 29, S 50; October 30, S 50; November 2, S 45; November 7, B 450; November 23, S 50; November 25, S 50; November 28, S 50; December 11, S 45; December 13, B 510; December 14, S 50; December 16, S 32; December 20, S 50; December 24, S 55; December 26, S 42; December 28, B 510; December 30, S 50; January 2, S 50. In the four months' treatment a total of 2,720 c.c. whole blood and 1,100 c.c. serum was administered.

One of the transfusions was followed by a mild chill and a fever peak, then lower temperature for a few days; but on the whole the low, irregular fever characteristic of the disease remained as it had been before treatment. Embolic phenomena continued to appear on the fingers and elsewhere, and on December 11 a second blood culture produced *Streptococcus viridans*. Except for atrial fibrillation for a day or two near the end, the heart signs were unchanged. The patient died by gradual exhaustion. Necropsy was not permitted.

CASE 3.—(Seen in consultation with Dr. Albert C. Daniels of San Rafael, Calif., who made the diagnosis and conducted the treatment.) A man aged twenty-two years, who had had rheumatic fever at the age of fourteen years, began to lose weight and strength in January, 1936. In March he had several chills, and from then on was hospitalized and had continuous irregular but usually high fever. The fingers were slightly clubbed; the heart was enlarged, with loud systolic murmur and later a faint early diastolic murmur. There was a moderate secondary anemia and leucocytosis. Small petechiae appeared on the skin and conjunctivae at times. The spleen was not demonstrably enlarged. Several blood cultures yielded *Streptococcus viridans*.

Pending immunization of six donors with his own organism (by the method described for Case 2), the patient was given several nonimmune transfusions. In the fifteen-day period April 13-28 he received eight transfusions and four intramuscular injections of blood from the immunized donors—a total of 2,450 c.c. The citrate method was used; there were no reactions. A blood culture taken three days after the last dose of immune blood produced five colonies of *Streptococcus viridans* per cubic centimeter (before treatment one culture had shown 8 and another 6 colonies per cubic centimeter).

Later the patient was given three injections of gentian violet: 5, 8, and 10 milligrams per kilogram of body weight, respectively. Blood culture taken on the day following each injection showed respectively one, four, and five colonies per cubic centimeter.

After some of the transfusions, and after the first gentian violet injection, the patient professed to feel a little better; but throughout the treatment there was no consistent amelioration of the fever and general decline. He died in mid-June. Necropsy was refused.

SUMMARY

In three cases of subacute *Streptococcus viridans* endocarditis, groups of volunteers, immunized with the patients' organisms, contributed blood by direct transfusion or (when incompatible) blood serum or blood for intramuscular injection. One patient, in a two-month period, received 1660 c.c. blood and 748 c.c. serum; another, in four months, 2720 c.c. of blood and 1100 c.c. of serum; and the third in fifteen days received 2450 c.c. blood. All three were "improved" in their own and their families' opinion, but in none could I see any beneficial effect other than temporary relief of anemia and the psychic uplift to be expected from any strange and elaborate treatment. Blood cultures remained positive; embolic phenomena and irregular fever continued; and the patients gradually failed and died in the usual course of the disease.

In the meager literature of intensive immune hemotherapy for this disease and in the more numerous reports of less serious efforts I find no unequivocal record of success.

REFERENCES

1. Lamb: M. Clin. North America 2: 1027, 1919.
2. Howell, Portis, and Beverley: J. Infect. Dis. 39: 1, 1926.
3. Kurtz and White: New England J. Med. 200: 479, 1929.
4. Wordley: Lancet 2: 219, 1924.
5. Robertson: Lancet 1: 759, 1918.
6. Dick: J. A. M. A. 78: 1192, 1922.
7. Heyd: New York. M. J. 106: 57, 1917.
8. Sinek: Med. Klin. 30: 368, 1934.
9. Krueger: J. Infect. Dis. 53: 237, 1933.

PERSISTENT HICCOUGHS AS THE SOLE SYMPTOM OF THORACIC ANEURYSM*

Report of a Case

S. A. Loewenberg, M.D., and H. C. March, M.D.
Philadelphia, Pa.

THIS case is being reported to call attention to the variability of symptoms in lower thoracic aneurysm. The only temporary discomfort noted by this patient was persistent and continuous hiccoughs. In spite of the intrathoracic crowding and the erosion of four dorsal vertebrae, neither chest pain nor circulatory or respiratory embarrassment was present.

B. R., male, colored, aged fifty-four years, was admitted to the Philadelphia General Hospital on Nov. 18, 1935, with the chief complaint of persistent hiccoughs. He stated that he had been perfectly well until four days before admission to the hospital, when he developed a sense of "giddiness in the head" and a dull ache in his right loin, which did not radiate. These sensations gradually disappeared within two days and were followed by hiccoughing, which was present constantly day and night up until admission to the hospital four days later.

His past history was negative except for typhoid fever at the age of twenty-seven years. No history suggestive of syphilitic infection could be obtained from him. His family history was negative. He was a stevedore by trade and worked steadily until he developed dizziness and pain in his right loin, that is, until four days before he came to the hospital. He denied the use of alcohol.

On examination the patient appeared to be a well-developed and moderately well-nourished male negro, looking considerably younger than his stated age. He was hiccoughing continually and appeared somewhat fatigued by this ordeal.

There was a slight bilateral arcus senilis; the tonsils and pharynx were injected but caused no symptoms. The lung findings were negative except for restricted diaphragmatic excursions at the right base. Examination of the heart showed a diffuse precordial impulse, and a pulsation was visible in the first and second interspaces to the right of the sternum, over which area a thrill was palpable. There was also a slight pulsation over the lower portion of the sternum. The apex beat was palpable about 8 cm. to the left of the midsternal line in the fifth intercostal space. On percussion, the left border of the heart approximated the position of the apex beat, while the right border of the heart extended to about 8 cm. to the right of the right sternal line. The supracardiac area of dullness was definitely enlarged, measuring about 10 cm., the enlargement being chiefly to the right. The heart sounds were of fairly good muscular quality. A loud, harsh, systolic murmur was heard over the entire precordium. This murmur was of greater intensity and appeared somewhat more deep seated to the right of the sternum, while to the left of the sternum it gave the impression of being superficial and resembled, in quality, a pleuropericardial friction sound. The heart rate was somewhat rapid though

*From the Medical Service of the Jefferson Medical College and Philadelphia General Hospital.

the rhythm was regular. The blood pressure in both arms was 130/75. With the exception of an atrophied left testis and a fairly rigid spine, no other abnormal physical signs were found.

Fig. 1. Fig. 2.

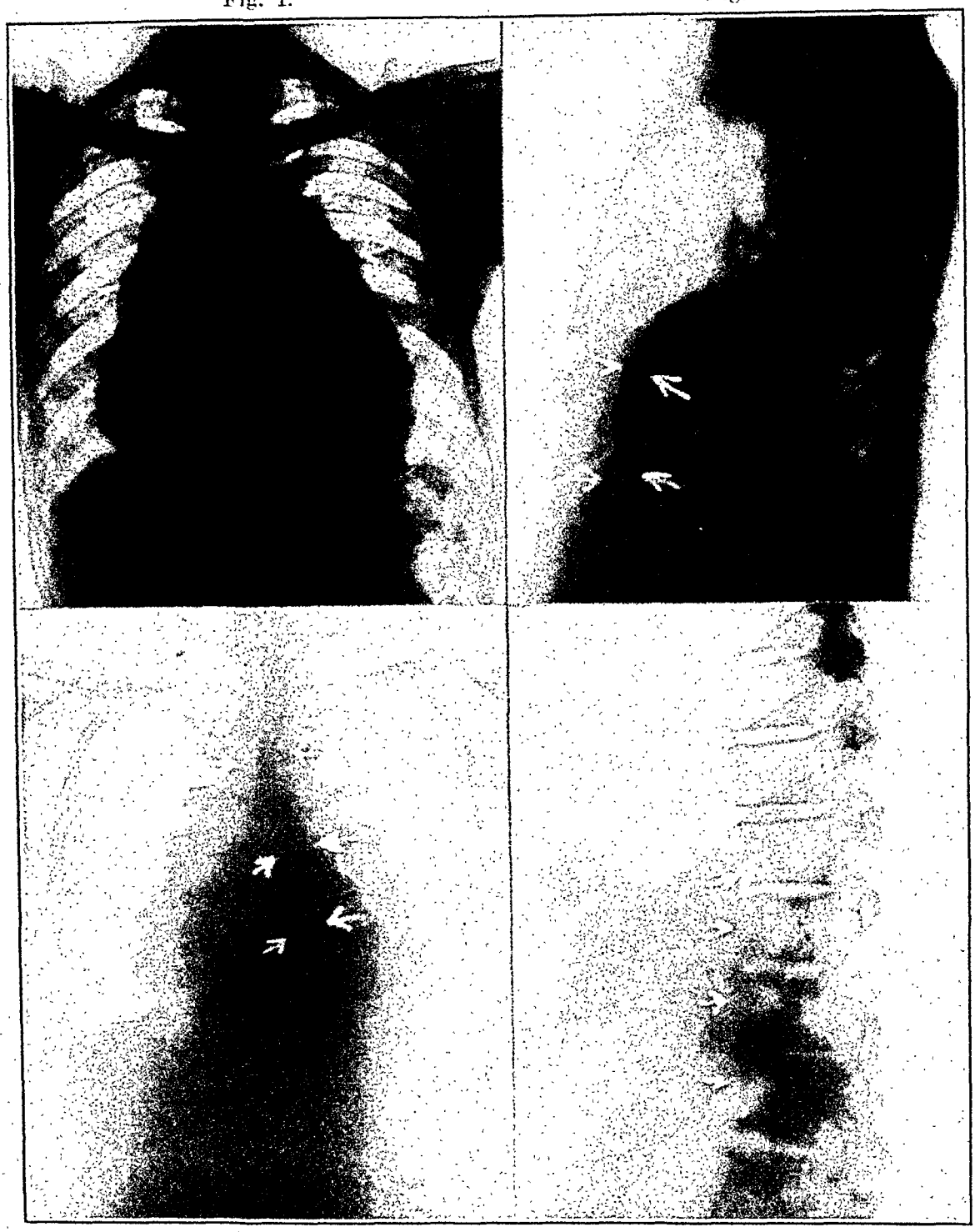

Fig. 3. Fig. 4.

Fig. 1.—Showing size of heart and aortic shadows.
Fig. 2.—Showing displacement and partial compression of esophagus (lateral view).
Fig. 3.—Showing displacement and partial compression of esophagus (anterior view).
Fig. 4.—Showing erosion of ninth, tenth, eleventh, and twelfth dorsal vertebrae.

Laboratory Examination.—Urinalysis showed nothing abnormal. Blood sugar was 102. The blood count was within normal limits. Blood urea nitrogen was 11 mg. Blood Wassermann reaction was four-plus.

Roentgenological Examination.—An x-ray film of the chest revealed a large, fairly homogeneous dense shadow occupying the area of the heart and the great vessels; the increase in size of this shadow above the normal appeared to be due chiefly to an aorta, markedly and diffusely dilated (Fig. 1). This finding was confirmed by fluoroscopic examination. The left border of the cardiac and the supracardiac dullness obtained by percussion did not extend as far to the left as the film indicates, because the descending aorta produces the left border of the roentgen shadow and it is not readily brought out by percussion. A lateral view of the chest showed the sweep of the dilated aorta. Fluoroscopic examination was made with barium in the esophagus, and the films were taken. These are shown in Figs. 2 and 3. It is seen that the esophagus is displaced to the left and markedly anteriorly by a rounded mass, the size of a small grapefruit, behind and below the heart, at the level of the diaphragm. Figure 4 shows a lateral view of the lower dorsal vertebrae and shows erosion and destruction of the anterior parts of the bodies of the ninth, tenth, eleventh, and twelfth dorsal vertebrae by the pulsations of the aneurysmal mass.

The electrocardiogram, with the exception of flattening of the T-waves in Lead I, showed nothing abnormal.

While he was in the hospital, various methods such as gagging, the induction of emesis, sedation, rebreathing into a bag, CO_2 inhalations, and ethyl chloride freezing of the area overlying the phrenic nerve in the neck were employed in an effort to stop his hiccoughs. All these methods appeared effective for only a short time; the hiccoughs soon returned. However, they disappeared spontaneously on the patient's ninth day in the hospital. Another attack of hiccoughing occurred three months after his discharge from the hospital and was brought about by an unusual amount of strain while working as a stevedore. The attack lasted six days and disappeared spontaneously after a complete rest in bed. During the intervals when the hiccoughs were stopped, the patient felt well, and he claims that at no time had he any pain in his chest, back, or abdomen. This is rather remarkable in view of the vertebral destruction.

SUMMARY

This case is of interest because it illustrates the fact that aneurysm of the thoracic aorta, while presenting definite physical signs, may not cause any pressure symptoms or other subjective signs usually found in this condition, particularly when associated with erosion of the bodies of some of the vertebrae. Hiccoughing was the only sign. It occurred only following severe strain, and disappeared after a period of complete rest. The patient also has an extensive fusiform dilatation of the ascending, tranverse, and descending aorta as the result of syphilitic involvement of these structures. The lack of pain, while not very unusual, is noteworthy.

Department of Reviews and Abstracts

Selected Abstracts

Gottdenker, F., and Rothberger, C. J.: Lactic Acid Metabolism of the Spontaneously Failing Heart and in the Heart Poisoned With NaF, Monoiodoacetic Acid and With Euphylin. Pflüger's Arch. f. d. ges. Physiol. 237: 59, 1936.

Experiments were made on the heart-lung preparation of the dog. In failure the lactic acid consumption decreased, and the heart even gave up lactic acid. NaF, monoiodoacetic acid, and euphylin inhibited lactic acid metabolism; the latter two at first, however, increased its metabolism.

L. N. K.

Strauss, L. H.: Inhibition of Experimental Atherosclerosis by Potassium Iodide and Colloidal Silicic Acid. Ztschr. f. exper. Med. 98: 603, 1936.

Inorganic iodine alone had no effect, but when combined with silicic acid, it inhibited experimental epinephrine sclerosis in 60 per cent of all instances and cholesterin atherosclerosis in 70 per cent of all instances.

L. N. K.

Schneyer, K.: Clinical Observations Upon the Question of Hypertension Following Extirpation of the Cardiac Pressor-Receptive Nerves. Klin. Wchnschr. 16: 192, 1937.

After reviewing the development of the experimental production of hypertension by excising or severing the nerves of the carotid sinus and aortic arch, the author proceeds to draw clear distinctions between hypertension produced in animals in this way and that seen to occur naturally in man. He studied 224 individuals with systolic arterial pressures above 150 mm. Hg (only 50 were over 200; and diastolic pressure is not mentioned) and 90 with pressures below 150 mm. Hg. Observations of (1) pulse rate, (2) effect of carotid pressure, and (3) closure of both carotid arteries by pressure were made. The findings and conclusions follow.

1. Cardiac rate is essentially normal and falls, in 80 per cent of cases, between 60 and 80 beats per minute. Departure of rate from normal along with blood pressure does not then occur as in hypertension induced by extirpation of the cardiac pressor-receptor nerves. 2. Carotid pressure tests are positive in 75 per cent of cases of hypertension. 3. Closure of the carotid arteries gives rise to increase, reopening to decrease, in pulse rate. The author is, however, quick to point out that the value of these methods of study is doubtful because anatomical and pathological situations may be unwittingly encountered which either prevent or enhance stimulation of the carotid sinus and because pain due to manual pressure may alter the reaction. In general he favors the use of closure of the carotid arteries. 4. Bradycardia was not observed in cases of coarctation of the aorta. Since he believes hypertension in this condition to be purely mechanical,

he concludes that, whatever the immediate reaction to acute carotid sinus stimulation, prolonged stimulation is in some way compensated for. 5. Clinical observation does not adduce any evidence of forms of neurogenic hypertension which corresponds to that seen after extirpation of the cardiac pressor-receptor nerves.

J. M. S.

Hermann, H., Jourdain, F., Morin, G., and Vial, J.: Intensification by Eserine of the Action of Acetylcholine Upon the Secretion of Adrenalin. Compt. rend. Soc. de biol. 124: 317, 1937.

Although the action of eserine in increasing and prolonging the action of acetylcholine is well known, the demonstration that the drug also calls forth a greater secretion of adrenalin following the injection of acetylcholine has not been demonstrated. By the ingenious device of connecting the adrenal vein of a dog whose adrenal gland has been denervated to the jugular vein of a dog sensitized to the effect of adrenalin by destruction of the thoracic, lumbar, and sacral spinal cord, it was easy to demonstrate this fact. When acetylcholine is injected into the dog with denervated adrenals (donor) arterial pressure falls promptly, but no change occurs in the second (transfused) dog due to liberation of adrenalin which counteracts the fall in pressure. If eserine is now given to the donor dog before acetylcholine, not only is the fall of the arterial pressure in donor (dog with denervated adrenals) sharper and longer, but the transfused dog (sensitized to adrenalin) shows a marked rise of pressure. Evidently, then, the secretion of adrenalin as well as that of acetylcholine has been markedly increased.

J. M. S.

Battro, A., Braun-Menendez, E., and Orias, O.: Asynchronism of Ventricular Contraction in Bundle-Branch Block. Rev. argent. de cardiol. 3: 325, 1936.

By optically recording in the same person the apex beat, the venous pulse, the central arterial pulse, and the heart sounds, two records at a time, it is possible to recognize whether or not both ventricles beat synchronously. Applying these procedures in twenty patients showing electrocardiograms considered as characteristic of the so-called bundle-branch block, the following conclusions were drawn:

Of seventeen patients with electrocardiograms belonging to the so-called "common type" (right bundle-branch block, according to the old nomenclature), in fifteen there were obvious signs showing that the right ventricle contracted first, thereby indicating really a left bundle-branch block. In the other two cases no signs of asynchronism could be detected.

From three cases with electrocardiograms characteristic, according to Wilson and his associates, of a right bundle branch, in one, a clear precedence of the left ventricle was actually found, but in the remaining two cases all signs of asynchronism were lacking.

The electrocardiogram by itself, therefore, is not a reliable means for establishing a diagnosis of complete bundle-branch block with its mechanical consequences. It is the adequate recording of the mechanical events due to the heart action which affords the only means to determine the existence of a ventricular asynchronism, thereby allowing the recognition of a delayed excitation through one of the bundle branches, with possibility of ascertaining the location and the degree of the functional disturbance.

AUTHOR.

Gilson, A. S., and Bishop, G. H.: The Effect of Remote Leads Upon the Form of the Recorded Electrocardiogram. Am. J. Physiol. 118: 743, 1937.

The material which has been presented deals with the distribution of potentials in a conducting medium surrounding hearts or inorganic models.

It has been shown that the so-called dipole theory of tissue potentials as expounded by its proponents is not adequate because:

a. The nature of the spread and duration of the activity in a tissue such as the heart, in which the duration of the sustained activity is greater than the time required for the spread of the impulse through the chamber under consideration, is such as to preclude the assumption of a moving, constant dipole.

b. When the entire heart surface has changed from a condition of rest to a condition of activity, any change of potential involved must be accompanied by a change in the potential of the whole medium with which the heart is in contact, since no difference of potential exists, either during rest or during the completely active state, between this surface and any point in the medium. The assumption that a distant point in this medium does not change in potential with change from passive to active state of the heart is therefore misleading and physiologically is beside the point, since such an assumption is derived from the erroneous notion that the active process in heart tissue can be adequately treated as a simple dipole moving in space.

A lead in contact with the moist surface of the heart in air tends to record with considerable localization the potential changes occurring at the heart surface immediately beneath it. On the other hand, any electrode in the bath and removed from the heart surface tends to record an averaged potential from the entire heart surface. The actual record obtained with leads in whatever position is, of course, a record of the potential differences between the two electrodes.

It is urged that, although expediency often demands, as for the case of the clinical electrocardiogram, the use of remote leads, nevertheless, records obtained by use of such leads should not be considered as offering valid a priori or complete evidence concerning the nature of the local potential changes at the heart surface. It should be obvious that despite this, the electrocardiogram offers a valuable aid in studies of the heart, but it has this value only because of the accumulation of empirical clinical data and the correlation of this material with data obtained by direct experimentation.

It is not considered that the arguments offered in support of the so-called dipole theory are such as to warrant abandonment of the classical or so-called negativity hypothesis as fundamental in the analysis and interpretation of electrograms from active tissues.

AUTHOR.

Molz, B.: Experiments With Models in Investigating the Electrical Field of the Heart (The Problem of the Null Potential Electrode and the Einthoven Equilateral Triangle). Pflüger's Arch. f. d. ges. Physiol. 237: 251, 1936.

The investigation showed that Einthoven's equilateral triangle equations did not hold in the triangular field. These results do not support the view that Wilson's null potential electrode has a zero potential under all conditions.

L. N. K.

Golder, W.: Concerning Notching in the Main Deflection of the Electrocardiogram. Ztschr. f. Kreislaufforsch. 28: 881, 1936.

Changes in the respiratory position of the chest and distention of the abdomen can alter the notchings of QRS or make them disappear. It is possible in this

way, and by changing the position of the electrodes, to demonstrate the transformation of Q-, R-, or S-waves into notches. These notches, therefore, are due to differences in the summation of the action currents of the two ventricles.

L. N. K.

Goldberg, M., and Rothberger, C. J.: The Electrocardiogram of the Specialized Heart Muscle. Pflüger's Arch. f. d. ges. Physiol. 237: 295, 1936.

The electrogram and optically registered mechanogram of Purkinje fibers were recorded. The former resembled the electrocardiogram of the whole heart. This electrogram has upright waves when the septal end of Purkinje fibers are connected to the right arm and the other end to the left arm electrode of the galvanometer, indicating that in the isolated fiber the impulse spreads outwardly from the septal end. The electrogram lasts much longer than the mechanogram and the absolute refractory phase. The second phase of the electrogram is, therefore, an afterpotential and not equivalent to the S-T and T segments of the electrocardiogram of the whole heart.

L. N. K.

Palmer, J. H.: The Size of the Heart After Coronary Thrombosis. Canad. M. A. J. 36: 387, 1937.

Enlargement of the heart was found by radiological methods in 64 per cent of a series of 200 patients who had survived an attack of coronary thrombosis. Those with doubtful enlargement, 16 per cent of the series, were, for the purpose of this paper, added to the normal group, but the high incidence of enlargement in published necropsies favors the view that these doubtfully enlarged hearts are in reality enlarged.

The factors causing enlargement after coronary thrombosis are discussed. By far the most important proved to be hypertension, which was held to be the single or predominant cause in more than 80 per cent of all cases with enlargement.

Disease of the coronary arteries, either the actual thrombosis with its resulting infarction or the underlying arteriosclerosis, led to increase in the size of the heart in a total of 11 cases (8.6 per cent). Of these, 4 (3.1 per cent) had cardiac aneurysm, 3 (2.4 per cent) had a bundle-branch lesion, and the remaining 4 (3.1 per cent) had enlargement, apparently due to chronic myocardial ischemia alone.

No example of so-called acute dilatation of the heart was discovered among 27 patients examined radiologically within a month of the attack. Congestive failure, which was not seen in hearts of normal size, seldom led to an appreciable increase in the degree of enlargement.

About a third of the patients (36 per cent) failed to show or to develop enlargement, though watched over periods averaging more than three years following the first attack of coronary thrombosis, and this number included several with recurrent attacks.

AUTHOR.

Kirch, E.: Increase in Power and Hypertrophy of the Heart Following Athletics (Based on New Autopsy Material). Ztschr. f. Kreislaufforsch. 28: 893, 1936.

This report is based on nine necropsies of athletes from fifteen to twenty-five years of age at the time of death. Death in all these cases was sudden or acute, and all were in good health up to that time. In three of these there was a definite hypertrophy for which no cause other than athletics could be found. A summary table of data is given, and photographs of gross specimens are shown. These

individuals were long distance swimmers or runners [as were cases previously reported by him]. The hypertrophy was greatest in the right ventricle. Three of the nine athletes had hearts at the upper limits of normal, and these the author considers as "powerful" hearts.

L. N. K.

Dicker, E.: The Presence of a Prolanlike Substance in the Urine of Patients With Essential Hypertension. Compt. rend. Soc. de biol. 124: 303, 1937.

Samples of urine of twenty patients with hypertension and of twenty normal individuals (ten old, ten young) were, after proper preparation, injected into young impuberal virgin mice. The mice were then killed and examined. The uteri, tubes, and ovaries of those mice which were injected with urine from hypertensive patients showed, in most instances, well-marked hypertrophy. The injection of normal urine was not followed by hypertrophy. The urine from twelve of the twenty hypertensive patients whose blood pressure was constantly and markedly elevated was in each instance followed by hypertrophy but in eight, whose pressure was labile (maximal 230, minimal 100 mm. Hg) hypertrophy was inconstantly present and not so marked in degree.

The reaction in the mice suggested the presence of a prolanlike substance, and the author admits this finding as evidence of stimulation of the diencephalic or mesencephalic centers in hypertensive individuals. He concludes that the observation reenforces the hypothesis that essential hypertension is of central nervous origin.

J. M. S.

Barto, A., and Lanari, A.: The Action of Acetylcholine Injected Intraarterially Into Sympathectomized Subjects. Compt. rend. Soc. de biol. 124: 386, 1937.

This short note states that a few days after sympathectomy, reaction to the intraarterial injection of acetylcholine is normal; increase in vascular oscillations, pain, redness, and sweating occur. A few months afterward the reaction may, however, differ considerably. In a certain number of cases decrease in the amplitude of oscillations, i.e., vasoconstriction, no sweating and only a faint redness are observed, and in the same individual this reaction is subsequently reproducible. Sweating is, therefore, believed to depend upon the integrity of the sympathetic nervous system. Although the authors do not mention the fact, it seems likely that the failure of intraarterial injections of acetylcholine to give rise to marked vasodilatation in sympathectomized individuals might depend upon the development of sensitivity to adrenalin which is thought to be liberated in response to injections of acetylcholine.

J. M. S.

Bruck, H.: The Action of Histamine Upon the Blood Vessels of the Brain. Klin. Wchnschr. 16: 236, 1937.

The observations recorded were made possible by a persistent opening in the temporal bone of a patient with fracture of the skull and hemiplegia. Unfortunately, the author does not state how the cerebral pulse was recorded and fails also to mention what the ordinates of time were in the two smoked drum records reproduced. The cerebral pulse appears to have been recorded plethysmographically. Quantitation of the observed changes is, however, impossible since the instrument was apparently not calibrated.

In spite of these defects the observations are, if substantiated, of considerable interest. In the first curve a decrease in brain volume and in amplitude of pulsa-

tion during assumption of the erect posture is shown. The second figure shows simultaneous records of cerebral and arm volume and pulse during injection of histamine. The cerebral pulse becomes somewhat greater in amplitude before the volume of the arm increases. From this it is concluded that dilatation of the cerebral vessels by histamine is not dependent upon changes in systemic circulation.

J. M. S.

Errata

In the article, "Electrocardiographic Changes in Normal Adults Following Digitalis Administration" by Kaj Larsen, Fritz Neukirch, and Niels A. Nielsen, which appeared in the February issue, certain inaccuracies appear in Table I on page 166. In the column headed "T_1" the figure on the fourth line from the top should be preceded by a negative sign (-), and in the column headed "T_2" the figures on the first, second, tenth, fourteenth, eighteenth, nineteenth, twentieth, twenty-first, twenty-second, and twenty-fourth lines should have in front of them a negative sign (-) instead of a positive sign (+).

The American Heart Journal

Vol. 13 June, 1937 No. 6

Original Communications

CONGENITAL STENOSIS OF THE ABDOMINAL AORTA*

W. d'A. Maycock, M.D., C.M.
London, England

STENOSIS and thrombotic obliteration of the descending aorta is a relatively common autopsy finding which is frequently diagnosed during life because there is usually associated a definite clinical picture. Congenital narrowing (with or without occlusion) of the aorta below the isthmus is a rare occurrence, however, and, on account of indefinite symptoms, is seldom diagnosed. This case is recorded because it presents a most unusual picture of narrowing and complete occlusion in the midabdominal aortic segment and extensive compensatory arterial hypertrophy and dilatation. There is added a brief review of the few available recorded cases of stenosis in this region. As the clinical history in this case is also of unusual pathological functional interest, it is included here in greater detail.

CASE HISTORY

M. B., female, aged eighteen years, was first admitted to the Royal Victoria Hospital on June 3, 1929, complaining of palpitation, dyspnea, and precordial pain which resembled pinpricks and radiated occasionally to the left shoulder. These complaints had been present for three months and were aggravated by exertion. She also complained of epigastric distress and nausea without relation to meals for about six months.

Family history was irrelevant.

Personal History.—She gave a history of measles, mumps, diphtheria in childhood, but no history of rheumatic fever. Nocturia (1-2) for past few years. Menses: 13 × 28 × 2 to 3; no dysmenorrhea, menorrhagia, or metrorrhagia. Apart from the diseases mentioned, the patient had always been well and had been able to join in all activities with other children without any difficulty.

Physical Examination.—Temperature was 99.4° F.; respiration, 20; pulse, 95, regular, full volume, high tension. The cheeks were flushed; nutrition, fair. The lungs were normal. The heart extended 9 cm. to the left of the midline at the apex.

*From the Pathological Institute, McGill University, Montreal (Professor Horst Oertel, director), and the Department of Medicine, Royal Victoria Hospital, Montreal (Prof. J. C. Meakins, director).

There were an apical systolic murmur conducted to the axilla, and a soft systolic murmur over the base. Both pulmonary and aortic second sounds were accentuated. Blood pressure in arms was systolic, 200 mm. Hg, diastolic, 89 mm. Hg. There was some tenderness in right lower quadrant of abdomen. Urine was negative. Red blood cells numbered 3,880,000; white blood cells, 10,000; hemoglobin, 75 per cent. Electrocardiogram showed slight right-sided preponderance. Blood Wassermann reaction was negative. X-ray films of the arms and legs showed no calcification of the arteries. Special examinations of the eyes, ears, nose, and throat revealed no abnormalities. The clinical diagnosis was essential hypertension.

She was discharged on July 13, 1929, little improved, and attended regularly at the Medical Out-Patient's Department until her second admission to the wards on March 16, 1932.

During this period it was found that the blood pressure in the arms remained as before, while in the legs it was definitely lower, the systolic pressure being about 130 mm. Hg, and the diastolic about 110 mm. Hg. Sometimes the pressures could not be read in the legs. Sometimes the pulse could be detected only in the femoral arteries (usually better in the left one), while at other times it was palpable in both femoral, popliteal, posterior tibial, and dorsalis pedis arteries. There was no edema of the lower limbs, but they were occasionally colder than normal. There was persistent tachycardia (120), and the heart was enlarged to the right and left. A harsh systolic murmur was heard at the tricuspid area and at the base, which murmur was conducted out to the left axilla and up into the arteries of the neck; it was also audible posteriorly at the inferior angle of the left scapula and on each side of the spine from the tenth thoracic vertebra to the midlumbar region, becoming fainter in the lower part of this area. She complained of dyspnea on exertion, palpitation, and occasional indefinite precordial pain radiating to the left arm and the upper part of the back. On several occasions during this period she complained of alternating diarrhea and constipation; blood was found in the stools. Her weight fluctuated between 85 and 95 pounds. Her general health was poor, and she slept badly. The clinical diagnosis was coarctation of the aorta.

The patient was readmitted on March 16, 1932, complaining of palpitation, dyspnea and choking sensations, precordial pain radiating to the left arm, pain in the back over the fifth to the tenth thoracic vertebrae, headache, weakness, nocturia, sore throat with pain beneath the sternum on swallowing, and loss of 3½ pounds in three weeks. The precordial pain and pain in the back had been present for three weeks, the sore throat and dysphagia for one week, while the other complaints had been present periodically since her first admission.

Physical Examination.—Temperature was 100° F.; pulse, 130; respiration, 22. A thin, pale, asthenic, nervous patient, with marked pulsation of the left side of the chest. There was slight infection of the left middle turbinate, and congestion of the nasal mucosa. The teeth were carious. The chest was thin and narrow with prominent ribs; the expansion was good and equal; no abnormalities were found in the lungs.

Cardiovascular System.—There was a pronounced pulsation of the left side of the chest. The pulse was regular, collapsing; the volume, moderate; and the tension, greatly increased. The carotid and brachial arteries pulsated strongly. No pulsation was felt over the abdominal aorta or femoral arteries, but a pulse was detected in both dorsalis pedis arteries. A capillary pulse was observed in the nail beds and lips. Blood pressure in the right and left arms was systolic, 210, diastolic, 60; right leg—systolic, 118, diastolic, not obtained (measured in dorsalis pedis artery).

The apex beat was sharp, the point of maximum impulse being in the fifth left interspace, 9.5 cm. from the midline. The left border of the heart reached to the axilla. The sounds were loud and clearly audible. At the apex the first sound was increased and accompanied by a systolic murmur; the second sound was loud and

harsh. A systolic murmur was heard over the right border of the sternum, being loudest at the level of the xiphisternum, where the tortuous internal mammary artery could be palpated. This murmur was propagated along the seventh, eighth, and ninth right intercostal spaces; it continued downward over the abdomen to the umbilicus where it branched and was lost. A similar softer systolic murmur was audible over the left sternal border, but the left internal mammary was not palpable; this murmur could also be traced along the seventh, eighth and ninth left intercostal spaces. At the base the second aortic sound was ringing and accentuated. Posteriorly a harsh systolic murmur was heard over the fifth to the tenth thoracic vertebrae, and along the twelfth rib, and at the inferior angle of each scapula. There was some tenderness over the fifth to tenth thoracic vertebrae and over their attached ribs.

The fundi showed arterial pulsation. The electrocardiogram was normal. Blood Wassermann reaction was negative. Red blood cells numbered 3,880,000; white blood cells, 11,350 (two hours after eating); hemoglobin, 55 per cent (Sahli). The urine was normal. Blood culture was negative.

A collateral circulation was thought at this time to exist and to be as follows: (1) Between the seventh, eighth, and ninth intercostal arteries and the internal mammary arteries (indicated by the systolic murmurs and palpable right internal mammary artery); (2) between the internal mammary and the epigastric arteries (not conclusively demonstrated, thought to be hidden by recti muscles); (3) between the subscapular and intercostal arteries, as indicated by the systolic murmurs at the inferior angles of the scapulae.

X-ray examination of the chest showed an enlarged heart with a widened aortic arch. The left border of the descending aorta could be followed to the diaphragm; on each side of the vertebrae was a white line, extending on the left from the fifth to the twelfth thoracic vertebrae. It was thought that the right-hand line might be due to ligaments, while that on the left was considered most unusual. Focusing on the ribs with the Bucky diaphragm showed no erosion and suggested a constriction of the aorta just above the diaphragm.

The patient was discharged on April 3, 1932, with some improvement in the rhinitis, but otherwise unchanged. She attended the out-patient department until April 24, 1933. During this period a visible pulsation was seen in the left superior epigastric artery and in the region of the right supraspinatus muscle. She then developed periodic attacks of diarrhea and crampy abdominal pains for which she was again admitted to hospital on April 24, 1933.

Physical Examination.—Temperature was 99.8° F.; pulse, 112; respiration, 22. She was fairly well nourished, alert, and cooperative.

Cardiovascular System.—Slight cyanosis of the fingers, but no clubbing, was noted. A capillary pulse was detected, and the radial pulse was collapsing in character. A slight pulsation was felt in the femoral arteries but none in the popliteal, dorsalis pedis, or posterior tibial arteries. A visible arterial pulsation was seen in the epigastrium, and a large artery was palpable at the inferior angle of each scapula. No visible or palpable arterial pulsation was seen in the supraspinous area.

Blood pressure in the right arm was systolic, 215; diastolic, 70; in the left arm systolic, 204; diastolic, 70.

The apex beat was palpable in the left fifth interspace, 9.5 cm. from the midline and was strong and forcible. There was a questionable apical presystolic thrill, a short fine systolic thrill over the pulmonary area, and a soft systolic thrill over the carotid arteries. The closure of the pulmonary valves was distinctly felt.

The relative cardiac dullness measured 7 cm. at the second rib, 3.5 cm. to the right of the midline, and 9.5 cm. to the left of the midline, in the fifth interspace. The sounds were clearly audible, the pulmonary second sound being accentuated. A loud systolic murmur preceded by a short presystolic murmur was heard over the xiphoid process, the systolic element being propagated up the sternum with diminishing intensity and into the left axilla, and less so to the right of the sternum. Posteriorly on both sides of the spine a systolic murmur was heard faintly from the second to the fourth thoracic spines, more loudly from the fourth to the tenth thoracic spines, and quite loudly from here to the base of the spine. The second sound was accentuated in this area. The electrocardiogram showed a slurring of the QRS complex in all three leads and large T-waves, with abrupt take-offs in Leads II and III.

Cysts of *Endameba histolytica* and *Chilomastix mesnili* were found in the stools.

Blood examination revealed red blood cells, 3,950,000; white blood cells, 10,000; hemoglobin, 75 per cent. The blood Wassermann reaction was negative. The blood Kahn reaction was one-plus.

Courses of emetine were administered, and the patient was discharged on June 6 with improvement in her diarrhea and with disappearance of animal parasites from the stools, but her circulatory condition was unchanged.

Her out-patient record until Nov. 9, 1933, records frequent complaints of diarrhea and the presence of *Endameba histolytica* and *Chilomastix mesnili* in small numbers in the feces. Occasionally the patient complained of weakness of the legs.

She was readmitted on Nov. 9, 1933, with complaints of watery stools with occasional blood for five months, pain on defecation, dysuria and pruritis ani for two weeks, and complaints referable to the circulatory system, similar to those on the previous admissions. In addition, she stated that her feet were continually cold and that she had crampy pains around the knees after walking. She denied any edema of the feet or legs. Her general health for the past two months had been poor.

Physical Examination.—Temperature was 99.4° F.; pulse, 80 (Nov. 9, 1933). She was a poorly nourished, asthenic, nervous female with a marked malar flush.

A capillary pulse was noted in the lips and nail beds. The radial pulse was collapsing, and accentuated pulsation was seen in the brachial and carotid arteries. A weak pulsation was felt in the abdominal aorta and the femoral, dorsalis pedis and posterior tibial arteries. The blood pressure in the arms was systolic, 225; diastolic, 40; left leg, systolic, 80; diastolic, not obtained. The whole precordium exhibited a marked pulsation. A systolic thrill was palpable at the base and in the upper seven intercostal spaces pulsating vessels could be felt.

The apex beat was situated 12 cm. to the left of the midline. The sounds were loud in all areas. At the apex a systolic murmur was heard, and the second sound was harsh and accentuated. A harsh systolic murmur was audible over the pulmonary area and over the fifth thoracic spine.

There was generalized tenderness over the abdomen. The legs and feet were cold. Motile and encysted amebas were found in the stools, together with mucus and blood and occasionally pus. The blood Wassermann reaction was negative. The blood culture was negative. The x-ray film of the chest showed the heart to be enlarged, with accentuated shadows of the great cervical vessels. There was slight irregularity along the lower borders of the ribs. Blood examination revealed red blood cells, 4,380,000; white blood cells, 14,200; hemoglobin, 80 per cent.

In spite of treatment with emetine and carbazone, the patient lost weight, and the diarrhea failed to improve. On January 11, there was an exacerbation of the intestinal condition. The temperature rose to 102° to 104° F., and the pulse to about 140; the frequency of the stools became greater with larger quantities of gross blood.

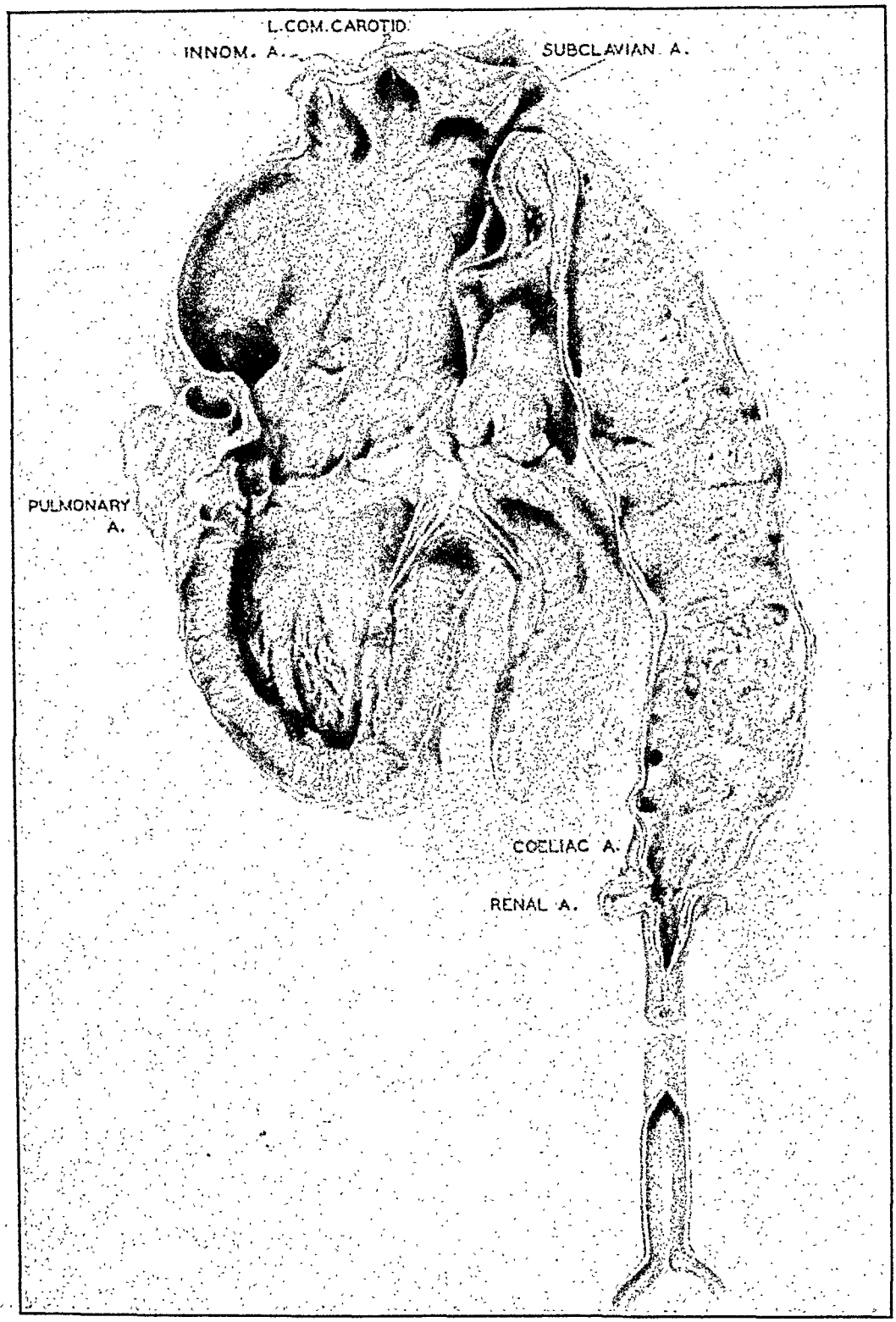

Fig. 1.—Congenital stenosis of midabdominal aorta.

On January 13 the red blood cells numbered 4,034,000; white blood cells, 15,500; hemoglobin was 48 per cent. On January 25 she was transferred to the surgical side for the performance of an ileostomy. At operation it was found that the cecum had ruptured, and an abscess had formed. The abdomen was drained through a gridiron

incision, but the patient gradually failed. The temperature was intermittent, the pulse 150, and she passed numerous watery stools and suffered severe abdominal pain. She sometimes vomited feculent material. She died on Jan. 30, 1934, three days after operation.

SUMMARY OF AUTOPSY FINDINGS

Gross Examination (eighteen hours after death).—The body was small and poorly nourished, 150 cm. long. The abdomen was rounded and tense and showed a linear incision 12 cm. long in the right lower quadrant through which protruded two rubber drains.

The thoracic viscera appeared in normal relation to each other, and the lungs were slightly emphysematous. The right heart was slightly dilated with chicken-fat and cruor clot, and the left ventricle was firmly contracted. There was slight thickening of the left ventricular wall including its papillary muscles. There was no valvular lesion, however, except some irregular thickening at the free margin of aortic cusps. Both ductus arteriosus and foramen ovale were closed. The organ weighed 360 gm. after having been opened.

Aorta.—Three centimeters above the valve, the ascending portion bulged to the right, forming a saccular aneurysm, 8.5 cm. at its greatest circumference. This ended at the beginning of the transverse arch where the circumference was 5.5 cm. There was a calcified plaque at the isthmus but no definite narrowing at this level; 1.5 cm. below the renal branches, however, there was an abrupt diminution in size, with the formation of a firm cord 3 cm. long and about 8 mm. in diameter. The lumen here was completely occluded by a firm gray laminated mass which fused with the vessel wall. It became patent again 4.5 cm. above the bifurcation where the circumference was 1.5 cm. In marked contrast to the gross changes in the aorta proximal to the stenosis, the portion below the occlusion and the iliac branches were very delicate and well preserved. These changes are well illustrated in Fig. 1. The proximal aorta showed a marked uniform thickening to about 5 mm. except in the stretched aneurysmal sac where a firmly attached, reddish gray mural thrombus filled its deeper parts. The intima of the ascending and transverse segments had many linear puckerings, mostly parallel to the long axis of the vessel, between which were smooth, slightly elevated, gray and yellow patches. Beyond the isthmus these puckerings disappeared while the yellow patches became more numerous between scattered calcified plaques and small irregular atheromatous ulcerations.

The inferior mesenteric and ovarian arteries were completely occluded at their origin in the thrombosed aortic segment. Branches of the celiac axis as well as innominate, left common carotid, and left subclavian arteries were thick-walled and dilated. The internal mammary arteries were widely dilated, thickened, and slightly tortuous, especially on the right side.

The abdominal cavity contained coils of bowel dilated with gas and fluid feces. There was a diffuse fibrinopurulent peritonitis with small pockets of creamy pus between loosely adherent loops. This peritonitis was apparently an extension from a perforated ulcer in the cecum. There were multiple irregular undermined deep and superficial ulcers throughout the colon having the characteristic appearance of amebic dysentery infection. The left kidney contained a well-organized infarct, and all parenchymatous organs showed the gross features of marked cloudy swelling. The intracranial contents were not examined.

Microscopic Examination.—For the purpose of this report, the description will be confined to pathological changes in the circulatory system.

Aorta: Sections from various parts proximal to occlusion showed quite a similar picture. There was marked irregular swelling (increase) and fusion of the intima with poorly defined fragmented internal elastic lamina. The adjacent inner half of

the media contained markedly swollen and fused fibers between patches of typical atheroma. This did not take the van Gieson stain. Elastic fibrils were here also

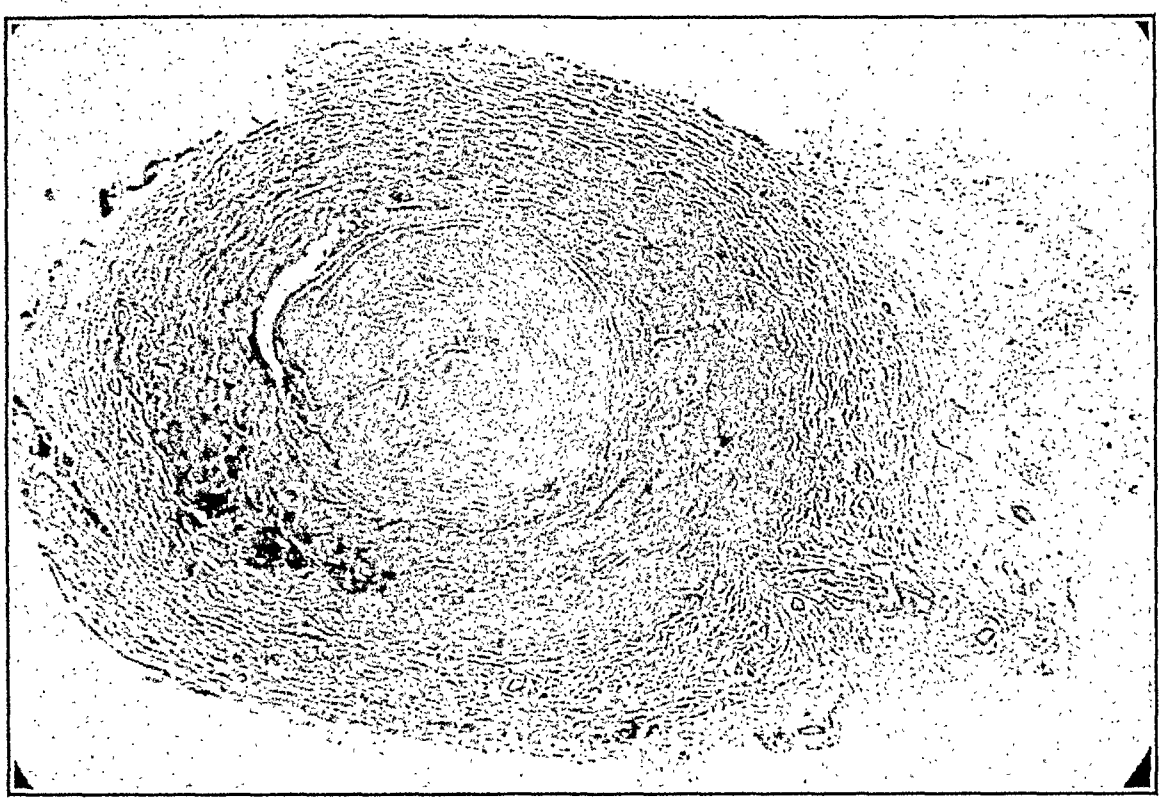

Fig. 2.—Transverse section of stenosed segment of abdominal aorta. There is complete fusion of the coats and dense hyaline fusion of the inner half of the wall. Organized laminated clot with limited recanalization fills the small lumen. (×20.)

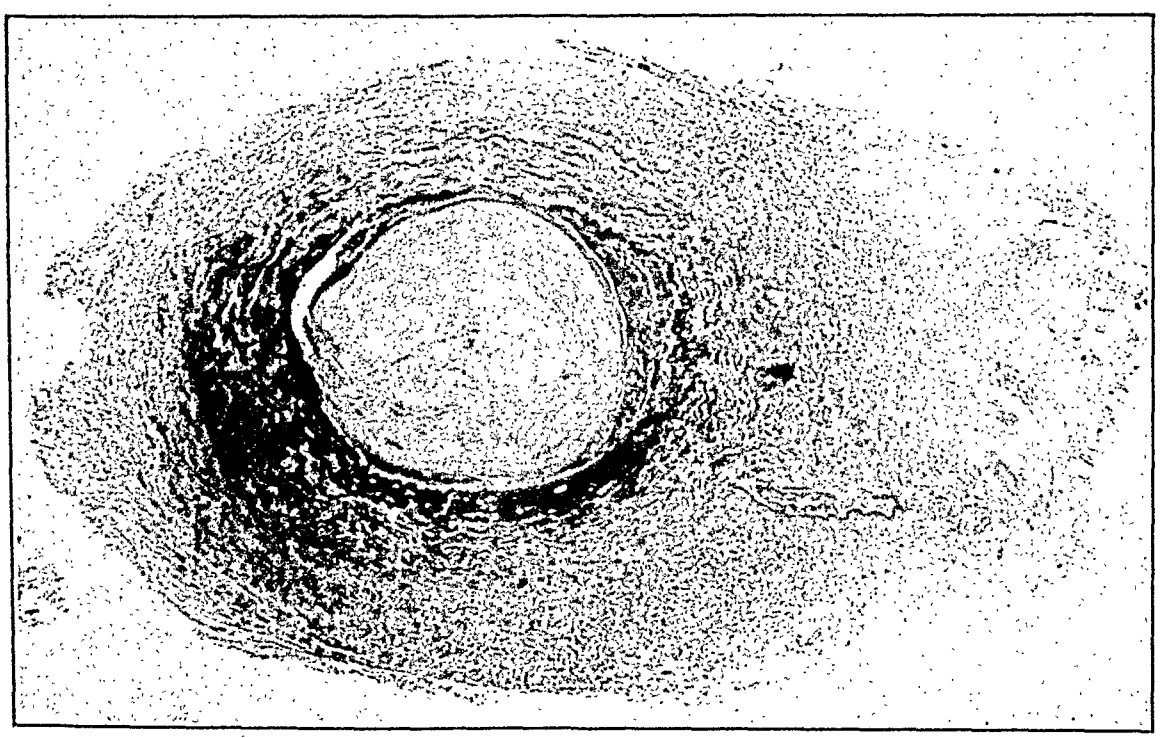

Fig. 3.—Orcein-van Gieson preparation of same section as Fig. 2. Increased fragmented elastic fibrils stain black, and collagen appears dark gray. (×20.)

abundant and extensively fragmented. The adventitia showed marked increase in fibrous tissue, throughout which were many vasa vasorum having uniformly thickened walls. Some were surrounded by small round cells which extended throughout

Fig. 4.—Descending thoracic aortic wall. Some of the thick vasa vasorum are surrounded by small round cells. There is marked gelatinous swelling and hyaline fusion of inner half of media. (×35.)

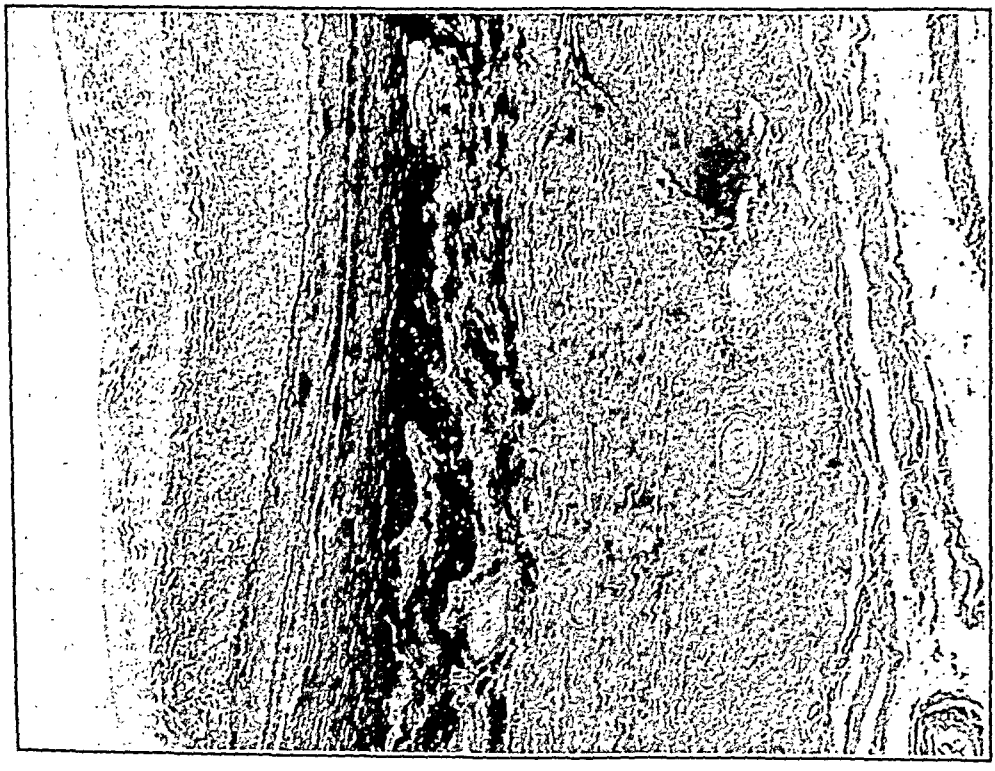

Fig. 5.—Orcein-van Gieson preparation of same section as Fig. 4, showing condensation and marked fragmentation of abundant elastic lamellae. (×35.)

the adjacent outer half of the aortic media, but there was no definite fibrous tissue scarring. There was no definite endarteritis of the vasa vasorum. The thick adventitia also contained many large medullated nerves. In the sections from the aneurysmal dilatation there was an irregular mass of fibrin which fused with the adjacent intima by scattered proliferating fibroblasts. In places this recent thrombus fused with a deeper zone of more mature fibrous connective tissue. Except for stretching of the coats and extreme fragmentation of elastic fibrils, the histological picture was similar to that of other parts. Immediately above the occluded segment the intimal and medial thickening and hyaline fusion became more extensive. In the media, only small fragments of muscle fibers and elastic fibrils remained, while well-preserved dense fibrous tissue persisted in the adventitia.

At the area of occlusion the lumen was completely filled with a homogeneous, pale red, hyaline mass, with a few small recanalized endothelial spaces containing scattered red blood cells. At the periphery this mass fused with dense fibrous tissue having small nuclei and abundant fibrils. This fibrous connective tissue extended throughout the fused aortic coats with variable degree of hyaline fusion. Orcein and Weigert's elastic tissue stains showed extensive fragmentation of elastic fibrils throughout the inner half of the vessel, while the outer half contained small arteries (vasa vasorum) having thickened mediae. There was no conclusive evidence of a syphilitic process. Below the occluded area and in the iliac arteries all coats were very well preserved.

DISCUSSION

This is apparently a case of *congenital stenosis* of the lower part of the abdominal aorta with subsequent thrombosis and recanalization. This opinion is arrived at, however, only after inflammatory and regressive lesions have been carefully considered and excluded. The distribution of hypertrophy and arteriosclerosis in this aorta is important anatomical evidence of a long-continued stenosis. These changes are entirely proximal to the obstruction and indicate a prolonged hypertension. Thus the hypertrophy of these coats is compensatory to a prolonged high aortic pressure. On the other hand, the lower segment and common iliacs below the stenosis (where there was a diminished pressure effect) remain extremely delicate and well preserved. To produce such an anatomical picture, we must assume a marked obstruction to blood movement (due to the narrowed lumen) for years before thrombosis occurred. It is well recognized that advanced atheroma may be associated with complete thrombus formation, but this is nearly always confined to muscular arteries. In the aorta, pedunculated mural thrombi, which only partly occlude the lumen, are far more common unless retrograde extension from adjacent branches has occurred. An isolated complete thrombus in this segment of the aorta suggests that there was a predisposition because of an unusually narrow lumen. The dense scar tissue throughout the fused coats, in the histological sections, adds further support to this opinion.

It is perhaps more difficult to exclude syphilis as the primary causal factor for the aortic lesions above the obstruction. Aneurysmal dilatations due to syphilis are, of course, extremely common, and stenosis

has also been described. The histological picture, however, is not typical of a specific inflammation. The absence of medial scarring and of endarteritis of the vasa vasorum is noteworthy. There was no familial or personal history of syphilis, no clinical signs, and the serological reactions were negative. Gsell[9] and later Erdheim[7, 8] have described cases of hypertension with aneurysms in the ascending aorta which were associated with diffuse medial gelatinous swelling and sometimes cystic degeneration. Since their observations at least fourteen similar cases have been reported, all having negative serum Wassermann reactions and no clinical or anatomical evidence of syphilis. Such a case has recently been observed at this Institute.[4] The constant dilatation of the ascending aorta may be partly attributed to a purely mechanical effect. This is its greatest diameter and therefore is the situation of greatest expansive pressure (Oppenheim).[17] It is the favored situation for permanent dilatation of the aortic wall. Although the histological picture in this case is not that of diffuse aortic medial necrosis, the extreme patchy intimal and medial degeneration (associated with prolonged hypertension) must be considered the important factor in the aneurysmal dilatation.

The hypertrophy and the dilatation of arteries concerned with collateral circulation are the final and conclusive evidence of the long duration of the stenosis. This was most marked in the intercostal and internal mammary arteries. Although the inferior mesenteric and ovarian branches could not be differentiated in the stenosed segment, there was no infarction of the colon or ovaries. This indicates that sufficient collateral circulation had been slowly established to these tissues to allow maintenance of function. Adequate circulation to the lower extremities was provided through anastomoses with the superior and inferior epigastric arteries.

It is impossible to do more than assume any relation between the thrombus in the aneurysm and that in the stenosed aortic segment because both vary greatly in age in different locations. If the thrombus at the site of stenosis was formed about an embolus, we must still assume a slowly progressive block in order to explain the absence of infarcts and the presence of marked compensatory hypertrophy and dilatation of those arteries concerned with collateral circulation.

Reference has already been made to syphilitic stenosis of the aorta. This is extremely rare. Hickl[12] found only two recorded cases up to 1931, and these were described by Stadler[20] as limited constrictions at the isthmus less than 1 cm. in diameter. Nonspecific mesaortitis may produce a constriction, but instead of an extreme abrupt stenosis there usually occurs a long funnel-shaped narrowing of the lumen, as demonstrated in Hickl's case of diffuse mesaortitis following rheumatic fever.

It has been noted that congenital stenosis at the aortic isthmus (coarctation) is quite frequent and this subject has been extensively reviewed by Abbott.[1] On the other hand, congenital stenosis of the aorta below the insertion of the ductus arteriosus has been rarely described during the past century. The first case was apparently reported by Schlesinger[22] in 1835. It concerned a girl aged fifteen years who had severe dyspneic attacks accompanied by tonic and clonic convulsions for two years. The thoracic aorta was almost completely obliterated to a thin cord for two inches above the diaphragm so that a fine sound could be passed through it only with difficulty. Above the stenosis the aorta was widely dilated and gave rise to many abnormal branches; the internal mammary and subclavian arteries were also much enlarged.

Duncan,[6] describing a case of thrombosis of the abdominal aorta in 1843, writes "many cases are now on record in which the aorta has been found obliterated, some of them at the same point as in this specimen, some with gangrene, others not. Many of these have evidently been congenital. . . ." He gives no references. Power[18] in 1861, described a youth aged seventeen years, who suffered from palpitation and epileptiform attacks following a "fever" and exhibited marked pulsation of the carotid, temporal and subclavian, internal mammary, and epigastric arteries. At autopsy there was found stenosis of the aortic valve and hypertrophy of the left heart. The internal mammary and epigastric arteries were dilated and very tortuous, and the aortic arch was enlarged. The abdominal aorta, after giving off its visceral branches, was found greatly diminished in size, and the iliac branches were correspondingly small. Power refers to the stenosis of the abdominal aorta as "an arrest of development" but does not discuss it further. Barié[2] states that Kriegk could find no other cases of congenital aortic stenosis below the isthmus prior to 1878, but couples Schlesinger's name with that of P. L. A. Nicod, who apparently described an analogous case in 1818. Bonnet[3] states that there were no similar cases reported between 1878 and 1903.

In 1911, Hasler[10] reported the findings in a man who had always been in good health till he died of lobar pneumonia at the age of forty-nine years. The heart was slightly dilated and greatly hypertrophied. Just above the aortic valve the aortic circumference was 7 cm.; distal to the origin of the left subclavian it narrowed, rather abruptly, to 3.5 cm., and then widened to 4.5 cm. in circumference. At 3 cm. above the diaphragm it suddenly became completely obliterated to form an impervious fibrous cord, 7 mm. in diameter and 2.5 cm. long. There was a well-developed collateral circulation through the intercostal, internal mammary, and epigastric arteries. Hasler believed that this stenosis was due to some acquired disease, whether intrauterine or postnatal, but could find no evidence on

histological examination of scar tissue, newgrowth or syphilis, and concluded that the narrowing was the result of an autochthonous organized thrombus of unknown origin.

Costa[5] in 1930 described the case of a female, aged forty-nine years, who died suddenly in the street. At autopsy there was found a rupture of the first left intercostal artery and extensive hemorrhage into the mediastinum and prevertebral connective tissue. Between the first and second pairs of intercostal arteries a pronounced annular constriction of the aorta was found. The aortic coats above and below this stenosed area appeared grossly normal, and the caliber of the proximal part of the aorta was not larger than usual. On histological examination the intima proximal to the stenosis was thickened and fibrous but showed no degenerative changes. The other coats were essentially normal. At the site of narrowing, however, the intima and the inner half of the media appeared to be separated and partly invaginated, thus encroaching on the lumen to form a narrow diaphragm. The outer half of the media and adventitia at the level were slightly indented. Below this stenosis the intima, extending into the iliac and femoral arteries, was thickened and fibrous. In the muscular arteries there was an increase of fibrous tissue throughout the media with patchy fatty degeneration and calcification. Costa suggests that the aorta had maintained its embryonic caliber due to the presence in its wall of residual tissue from the primitive right aorta which normally joins the left one at about this level.

The most recently reported case is by Schleckat[21] in 1933. A man, forty-four years old, complained of a feeling of fullness and pressure in the chest, occasional eructation of gas, poor appetite, and distressing thirst for four years. He died of bronchopneumonia. There was found at autopsy a constriction in the aorta at the level of the diaphragm which just admitted a 3 mm. probe. The aorta above the narrowed part was uniformly dilated, and the heart was described as "three times the size of the fist." Below the stenosis the aorta was of normal size. Throughout its length, the intima showed many atheromatous plaques. Microscopically there was a patchy diffuse and circumscribed thickening of the intima with deposits of "lipoid." The media was everywhere intact, and the adventitia showed focal collections of small round cells, which did not penetrate the media. The serum Wassermann reaction was three-plus; the Meinecke test was negative. Schleckat believes, like Costa, that the stricture was due to some irregularity in the development of the system of aortic arches.

It is impossible to state exactly the causal mechanism of the stenosis of the abdominal aorta in the case reported here. None of the authorities consulted (Herxheimer,[11] Hochstetter[13] Keibel and Mall,[14] Keith,[15] von Kölliker,[16] Rückert and Mollier[19]) mention such an

anomaly, and any explanation can only be hypothetical. It is known that the two dorsal aortas (omphalomesenteries) are partly fused in the human embryo of 23 paired somites, i.e., about the fourth week of fetal life (Thompson[23]). Shortly after this they fuse completely, forming a single blood channel. Faulty fusion is known in rare cases to result in an aorta which is divided longitudinally into two by a thin partition (von Kölliker). It is therefore possible that stenosis of the abdominal aorta, as found in this instance, was due to (1) lack of, or unequal fusion of, the two dorsal aortas at one point with obliteration and loss of one of them; (2) kinking of the fused aortas with consequent localized increased longitudinal tension producing a permanent narrowing. Of these it would seem that the first is the more probable and thus fits into the general category of developmental inhibitory faults which result from imperfect, or lack of proper, fusion of originally dual embryonic parts with reduction or loss of one of them. The exact causes of this inhibition remain obscure. No evidence was discovered which would make it likely that this lesion resulted from an acquired intrauterine disease.

SUMMARY

An unusual instance of congenital narrowing and complete occlusion of the midabdominal segment of the aorta, immediately below the renal branches, in a woman aged eighteen years, is described. The case was clinically under observation for nearly five years, and the circulatory changes and the collateral circulation were followed and studied. During the last year of her life she developed an infection of amebic dysentery to which she succumbed, in spite of active treatment, with a perforated cecal abscess.

Autopsy disclosed the midaortic narrowing and thrombotic obstruction with a tremendous aortic widening above it. Below it the aorta and the iliac branches were delicate and well preserved. The collaterals were prominent and thick walled. A careful anatomical study of the case led to the conclusion of a congenital anomaly from lack of proper fusion of the original two dorsal aortas, with regression and loss of one of them. This, judging from the literature and the number of reported cases, which are briefly reviewed, must be an extremely rare occurrence.

REFERENCES

1. Abbott, M. E.: A Statistical Study and Historical Retrospect of 200 Recorded Cases of Stenosis or Obliteration of the Descending Arch in Subjects Above the Age of Two Years, Am. Heart J. 3: 574, 1928.
2. Barié, E.: Du rétrécissement congénital de l'aorte descendante, Rev. de méd. 6: 343, 1886.
3. Bonnet, L. M.: Sur la lesion dite sténose congénitale de l'aorte dans la region de l'isthme, Rev. de méd. 23: 108, 1903.
4. Chase, W. H., and Johnston, G. C.: Medionecrosis of the Aorta in Its Neurovascular Relations. (To be published.)

5. Costa, A.: Obliterazione dell'aorta all'imbocco dell'aorta destra: rottura della prima intercostale aortica. Classificazione e patogenesi delle atresia e stretture dell'aorta, Arch. di pat. e clin. med. 9: 305, 1930.
6. Duncan, J.: Case of Spontaneous Obliteration of the Aorta, London and Edinburgh Monthly J. M. Sc. 3: 781, 1843.
7. Erdheim, J.: Medionecrosis aortae idiopathica, Virchows Arch. f. path. Anat. 273: 454, 1929.
8. Idem: Medionecrosis aortae idiopathica cystica, Ibid. 276: 187, 1930.
9. Gsell, O.: Wandnekrosen der Aorta als selbständige Erkrankungen und ihre Beziehungen zur Spontanruptur, Ibid. 270: 1, 1928.
10. Hasler, L. H.: Ueber ein Fall von Verschluss der Aorta in ungewohnter Stelle, Borna-Leipzig, 1911, R. Noske.
11. Herxheimer, G.: Die Morphologie der Missbildungen der Menschen und der Tiere, by E. Schwalbe, Jena, 1906, Gustav Fischer.
12. Hickl, W.: Ueber zylindrische Aortenverengerung im absteigenden Brustteil infolge von Mesaortitis, Frankfurt. Ztschr. f. Path. 41: 176, 1931.
13. Hochstetter, F.: Handbuch der vergleichenden und experimentellen Entwickelungslehre der Wirbeltiere, Edited by O. Hertwig, Vol. 3, Jena, 1906, Gustav Fischer.
14. Keibel, F., and Mall, F. B.: Manual of Human Embryology, Vol. 2, Philadelphia and London, 1912, J. B. Lippincott Company.
15. Keith, A.: Human Embryology and Morphology, ed. 3, Baltimore, 1933, William Wood & Company.
16. Von Kölliker, A.: Entwickelungsgeschichte des Menschen und der höheren Thiere, Leipzig, 1880, Wilhelm Engelmann.
17. Oppenheim, F.: Gibt es eine Spontanruptur der gesunden Aorta und wie kommt es zustande? München. med. Wchnschr. 65: 1234, 1918.
18. Power, J. H.: Observations on Disease of the Aortic Valves Producing Both Constriction of the Aortic Orifice and Regurgitation Through It Into the Left Ventricle, Accompanied With Abnormal Enlargement of the Two Internal Mammary Arteries, and Atrophy of the Abdominal Aorta and Its Iliac Branches, Dublin Quart. J. Med. 32: 314, 1861.
19. Rückert, J., and Mollier, S.: Handbuch der vergleichenden und experimentellen Entwickelungslehre der Wirbeltiere, Edited by O. Hertwig, Vol. 1, Jena, 1906, Gustav Fischer.
20. Stadler, E.: Quoted by Hickl.[12]
21. Schleckat, O.: Angeborene ringförmige Stenose der Aorta descendens in Zwerchfellhöhe, Ztschr. f. Kreislaufforsch. 25: 417, 1933.
22. Schlesinger: Merkwürdige Verschliessung der Aorta, Wchnschr. f. d. ges. Heilkunde, No. 31, 489, 1835.
23. Thompson, P.: Description of a Human Embryo of 23 Paired Somites, J. Anat. & Physiol. 41: 159, 1907.

HEMODYNAMIC STUDIES IN EXPERIMENTAL CORONARY OCCLUSION*

I. Open Chest Experiments

Louis Gross, M.D., Milton Mendlowitz, M.D.,†
and Gerhard Schauer, M.D.
New York, N. Y.

FOLLOWING acute occlusion of a main coronary branch in the human or in an experimental animal there occur a series of events which lead to death in a high percentage of the cases. Although it is generally recognized that death under these conditions is attributable to changes in the circulation as a whole as well as to local changes within the heart, there are available relatively few objective contributions to the hemodynamics of the circulation as a whole following acute coronary branch occlusion. This is largely due to the fact that until recently there were no accurate means for studying the various factors which reflect the status of the entire circulatory system.

In recent years, however, several important contributions have been made in this field. Orias[1] ligated the anterior descending branch of the left coronary artery in dogs and noted the effects on the circulation by means of strategically placed sensitive manometers. The contractions of the left ventricle immediately became markedly hypodynamic. There was a similar but less marked effect on the right ventricle. Although the cardiac output was not measured as such, Orias believed that it was probably profoundly diminished. In many of his cases the pressure rose within several minutes to normal or above normal. Orias concluded that in these cases the ventricle reacted to the increased stretch. He did not take into account the possibility that the output might still be reduced, the normal or elevated pressure being due to a compensatory peripheral vasoconstriction.

Fishberg, Hitzig and King[2] studied the hemodynamic effects of coronary occlusion in man and believed the shock to be probably "peripheral." They measured the blood volume in twenty-nine of their cases and interpreted their results as indicating a tendency toward diminution. Study of these cases reveals only one in which the blood volume was unequivocally subnormal. What collateral factors were present in this case, or whether an error in technic could have been made, is conjectural.

---

*From the Laboratories of The Mount Sinai Hospital, New York, N. Y.
Aided by grants from the Lucius N. Littauer and Walter W. Naumburg Funds.
†George Blumenthal, Jr., Fellow.
Aided by a grant from the Emanuel Libman Fellowship Fund.

On clinical grounds, T. R. Harrison[3] states: "Aside from the pain, the most striking clinical phenomena in persons with coronary thrombosis are those referable to the acute alterations in the dynamics of the circulation. These phenomena are of two types: one group, such as weakness, dizziness, faintness, syncope, unconsciousness, feeble heart sounds, diminution in blood pressure and especially the pulse pressure, alternation and feebleness of the pulse, pallor, dusky cyanosis, and subnormal temperature being due to diminished cardiac output because of sudden damage to the heart. The second group of circulatory phenomena are those of congestive heart failure dependent on acute dilatation of heart."

The present report* deals with an investigation on the hemodynamics of the circulation in dogs following sudden ligation of the left anterior descending branch 2 cm. below the left coronary ostium. Inasmuch as the numerous experimental procedures produce considerable pain, all studies were carried out with the animals under anesthesia. We confined our control studies to (a) the effect of anesthesia alone and (b) the effect of anesthesia followed by thoracotomy and coronary artery dissection without ligation. In the latter series, as well as in the coronary ligation group, the tests were made after closing the chest. The changes which will be described are to be considered only in relation to the conditions under which the experiments were carried out. In order to eliminate the immediate effects of thoracotomy, similar studies were carried out in ten additional dogs following left anterior descending branch ligation in the closed chest. This was accomplished by a special procedure which, together with the results obtained, will form the subject of a separate communication.

With the object of obtaining a relatively complete picture of the circulatory changes which follow these procedures, the following factors were investigated in thirty dogs (10 dogs in each group):

1. Cardiac output.
   (a) Minute volume; (b) stroke volume.
2. Circulation time.
   (a) Ether method; (b) cyanide method.
3. Arterial blood pressure.
4. Venous blood pressure.
5. Blood volume.
   (a) Cell volume; (b) plasma volume; (c) total volume.
6. Serum proteins.
   (a) Albumin; (b) globulin; (c) total.
7. Hemoglobin per cent and erythrocyte count.
8. Temperature.

*For a preliminary report of these findings see Proc. Soc. Exper. Biol. & Med. 35: 446, 1936.

METHODS

Suitable methods for carrying out the numerous tests rapidly and efficiently were developed in a series of preliminary experiments. It may be of value, therefore, to describe the procedures in their proper order. The dog, usually weighing from 10 to 20 kg., was not fed for twenty-four hours. The animal was strapped on its back to an operating table, the straps holding down the four paws and upper teeth. Enough nembutal (pentobarbital sodium) was given via an ear vein to produce satisfactory anesthesia. Between 5 and 10 grains were usually needed, i.e., ½ grain per kilogram of body weight. A tracheal catheter was inserted and oxygen consumption measured by the method to be described. The femoral artery was then punctured and the mean arterial blood pressure measured. Five cubic centimeters of blood was withdrawn from the other femoral artery for arterial blood oxygen determination. Then the right heart was punctured to obtain 5 c.c. of mixed venous blood for oxygen determination. The first blood volume sample was withdrawn from the right external jugular vein. With the needle in place, the venous pressure was measured with an L-tube (observing the precautions to be described), following which 5 c.c. of Congo red dye solution was injected. Five minutes later the second blood volume sample was withdrawn from the left external jugular vein. Again leaving the needle in place, ether was injected and the ether time measured. Several minutes later, cyanide solution was injected for the cyanide time. The temperature was taken per rectum, and the dog weighed. The hemoglobin, erythrocyte, and serum protein determinations were done from the first blood volume sample. For any one series of experiments, usually carried out in from 20 to 30 minutes, about 30 c.c. of blood in all were withdrawn.

The cardiac output* was determined by means of the Fick principle,[4] viz.:

$$\text{Minute volume} = \frac{\text{oxygen consumption per minute}}{\text{volume \% arterial blood oxygen} - \text{volume \% mixed venous blood oxygen}} \times 100;$$

$$\text{Stroke volume} = \frac{\text{minute volume}}{\text{heart rate}}.$$

The oxygen consumption was measured with a 1935 Sanborn basal metabolism apparatus. It was attached to a tracheal catheter at the end of which a rubber cuff was inflated to prevent leakage. As an additional precaution, the throat and mouth were packed with wet gauze. The slope of the kymographic tracing was usually quite straight, and a leak was very easily detected. While the oxygen consumption was being measured, the pulse rate was determined twice. The arterial blood was collected in an oiled syringe by puncturing a femoral artery. The blood was then quickly introduced under oil into a test tube, the bottom of which had been coated with enough oxalate to make a 0.3 per cent solution. It was then kept on ice until the determination was made. The venous blood was obtained with a lumbar puncture needle. If the needle was inserted in the third interspace to the right of the sternum pointing posteriorly, inferiorly, and only slightly mesially, the right ventricle was usually punctured with ease. The color of the blood and the pressure in the syringe were usually good indices of whether the needle was in the right or left ventricle. If there was any doubt, another sample was obtained. This mixed venous blood was treated like the arterial sample. The oxygen determinations were made within a few hours by the Van Slyke method,[5] each determination being checked within a fraction of a millimeter of mercury. These procedures were found to be of sufficient refinement for our purposes.

*Our results (Tables I, II and III) are tabulated in the traditional manner. The cardiac output refers only to that of one ventricle. To estimate the total output, the volume is multiplied by 2.

The blood volume was measured by a modification of the Keith, Rowntree and Geraghty[6] dye injection method. This unpublished modification was introduced at the Mount Sinai Hospital by Dr. Nathan Rosenthal. Two large drops of 20 per cent potassium oxalate solution were put into two graduated 15 c.c. centrifuge tubes. Ten cubic centimeters of blood was withdrawn from the external jugular vein, avoiding mechanical passive congestion. The blood was run slowly down the sides of the centrifuge tube to prevent the formation of bubbles, and was then mixed with the oxalate solution by inverting the tube several times. Five minutes after the injection of 5 c.c. of 1 per cent solution of Congo red dye, another sample was withdrawn from the other external jugular vein and treated like the first sample. The tubes were then capped and centrifuged at high speed for forty-five minutes. The hematocrit readings taken directly from these two large graduated centrifuge tubes were averaged. The differences were always slight. The supernatant plasma was then removed with a pipette, and the colors were matched with the standard in the usual way. When a second determination was done within a short time after the first, the remaining dye in the plasma, being incorporated in the standard, did not interfere with the results. The question of hemolysis arose as a possible factor of error in our determinations. We found the qualitative and quantitative spectroscopic methods for its detection too complicated and refined for our purposes. We, therefore, employed a simple guaiac ring test on the plasma which was found adequate to detect any significant amount of hemolysis.* Except for occasional traces which were readily discovered, there was rarely any gross error from this source.

The arterial blood pressure was measured by puncturing the femoral artery with a 19-gauge needle which was attached by a three-way stopcock to a syringe and mercury manometer. We found the mean blood pressure to be very labile. Variations in the depth of anesthesia and therefore in the sensitivity of the aortic depressor and carotid sinus mechanisms[7] might account in part for this lability. It was also thought that the sluice mechanism in the hepatic veins,[8] so active in the dog, might introduce an additional variable in the measurement of systemic arterial blood pressure.

The venous pressure was measured by the direct method.[9] A graduated L-tube washed with 3 per cent citrate solution was attached to a 16-gauge needle which had been inserted into the external jugular vein. The pressure was measured in centimeters of water. Inasmuch as the relation between the level of the external jugular vein and the level of the heart varied in different animals, no absolute values could be established by this method. The relative changes, however, could be fairly accurately determined. The precaution of loosening the upper paws had to be taken since excessive traction occasionally mechanically constricted the veins and gave a high reading. In preoperative and postoperative measurements there was an unavoidable source of error. Despite all efforts to "blow off" the residual pneumothorax when closing the chest, some air was frequently left. With the animal on its back the lungs and mediastinal structures sank toward the back. This made the level of the heart lower with respect to that of the jugular vein than it had been before the operation. This was evident by the greater depth to which the needle had to be inserted in order to reach the heart. Another variable factor was the partial residual pneumothorax due to the thoracotomy. Venous pressure readings in the open chest experiments were, therefore, of questionable significance. In the closed chest experiments these sources of error were eliminated.

*Sunderman and Austin have recently reported a benzidine test for the detection of hemolysis in serum volume determinations (Am. J. Physiol. 117: 474, 1936).

The ether circulation time[10] was measured by injecting 0.5 to 1 c.c. of ether, plus an equivalent amount of physiological saline solution, depending on the size of the dog, into the external jugular vein. The time elapsing between the injection and the detection of the ether in the exhaled air was measured with a stop watch. The chief source of error was a slow respiratory rate. If it was very slow, several seconds might elapse before the alveolar air containing the ether was exhaled. This happened only occasionally, and the error was always noted. Another source of error was infiltration of the fluid outside the vein, a rare accident.

The cyanide circulation time[11] was measured several minutes after the general effects of the ether had been permitted to wear off. One-half to one cubic centimeter of 1 per cent solution of sodium cyanide was used. The time elapsing between the injection of the solution and the onset of deep rapid breathing was recorded with a stop watch. Slowing of the pulse was found to be a less reliable end point. When freshly prepared solutions of this concentration were used, there were rarely any ill effects, even in animals already very sick. The effects of the poison were usually transient, subsiding apparently completely in from five to fifteen minutes, so that subsequently another circulation time could be done without risk. Occasionally the end point was not sharp. These instances were always recorded as such.

The other measurements served as additional checks on our method. The percentage of hemoglobin was read on an ordinary Sahli hemoglobinometer and the erythrocyte count done on a standard hemocytometer. These usually checked with variations in cell volume and arterial blood oxygen. Oxygen saturation was not determined because its estimated value did not seem commensurate with the additional time required. The serum protein determinations were made by the colorimetric method.[12] They served as a rough check on the character and the amount of fluid lost. Temperatures were taken per rectum.

EXPERIMENTAL

A heterogeneous group of mongrel dogs weighing from 10 to 20 kg. were used for these experiments. They varied in age, sex, and nutrition. They were quarantined for two weeks to eliminate those with distemper. One week prior to operation some of the animals were subjected to a series of studies as outlined above. In all dogs similar studies were done before and after operation, and if the animal survived, one day and one week later. At the end of this period the surviving animals were killed.

In order to occlude the anterior descending branch of the left coronary artery, we employed the operative technic described by Gross, Blum, and Silverman.[13] After adequate anesthetization with nembutal (pentobarbital sodium), artificial pulmonary insufflation with a Starling pump was instituted. The chest was opened in the third interspace on the left. The lung was packed down out of the way; the pericardium was incised parallel and anterior to the phrenic nerve; and the anterior descending branch of the left coronary artery was identified. This was carefully dissected as near to its source as possible. It was then ligated in two places with a No. 4 silk thread and severed between ligatures. The pericardium and chest were closed

TABLE I

ANESTHESIA CONTROL EXPERIMENTS

DOG NO.	SEX	PROCEDURE	DATE	WEIGHT IN KG.	TEMPERATURE (F.)	PULSE RATE PER MINUTE	OXYGEN CONSUMPTION IN C.C. PER MINUTE	ARTERIOVENOUS OXYGEN DIFFERENCE, VOLUMES PER CENT	CARDIAC OUTPUT MINUTE VOLUME PER SQ. METER IN C.C.‡	TOTAL BLOOD VOLUME PER SQ. METER IN C.C.‡	HEMOGLOBIN PER CENT	TOTAL SERUM PROTEINS-GRAMS PER CENT	BLOOD PRESSURE: ARTERIAL IN MM. OF MERCURY	BLOOD PRESSURE: VENOUS IN CM. OF WATER	CIRCULATION TIME: ETHER IN SEC.	CIRCULATION TIME: CYANIDE IN SEC.	REMARKS
63E	♂	Before*	7/14/36	17.3	102.6	196	121.0	2.69	6000	-	87	5.98	135	6.0	4.0	8.0	7/15 Dog died several hours after procedure. Autopsy: Gas gangrene right thigh at site of arterial puncture.
		After†		17.3	103.2	164	156.0	5.07	4108	2280	93	5.79	130	5.5	3.0	8.0	
64E	♂	Before	7/15/36	13.2	105.0	136	125.0	10.28	1945	2220	95	7.06	90	0	6.0	indefinite	7/16 Dog died several hours after procedure. Autopsy: Pneumonia in both lower lobes.
		After		13.2	104.8	140	118.0	6.98	2708	2465	108	7.31	115	3.5	4.5	indefinite	
67E	♂	Before	7/17/36	11.2	100.4	174	93.0	2.07	7915	2243	63	4.94	150	2.5	5.0	6.5	7/18 Dog died several hours after procedure. Autopsy: Pneumonia in left lower lobe.
		After		11.2	100.0	180	92.0	3.25	5000	2020	63	5.08	145	3.0	7.0?	7.5	
70E	♀	Before	7/18/36	12.0	101.9	208	111.0	2.81	6732	2600	89	5.44	145	2.5	6.0	7.5	7/28 Dog apparently well.
		After		12.0	101.6	180	102.0	2.50	6960	2555	84	6.22	130	1.5	3.0	6.0	
		Retested	7/19/36	11.2	102.2	192	96.0	3.10	5460	2459	71	6.15	132	1.0	11.0?	15.0?	
		Retested	7/28/36	11.6	100.6	216	95.0	2.79	5930	2722	92	-	165	4.5	5.0	9.0	

TABLE I—CONT'D

73E	♀	Before	7/20/36	10.2	101.2	168	71.5	2.17	6225	1995	63	5.69	85	3.0	4.0	10.0	7/24	Dog died four days after procedure.
		After		10.2	98.0	168	83.5	2.59	6105	2050	70	5.72	78	–	6.0?	7.0		Autopsy: Atelectatic pneumonic patches both lower lobes.
		Retested	7/21/36	9.9	99.4	132	79.0	3.25	4700	2266	63	8.31	75	2.5	–	–		
74E	♂	Before	7/21/36	9.4	100.3	156	79.0	2.01	7860	2530	69	5.21	95	0	–	7.0	7/29	Dog apparently well.
		After		9.4	99.4	192	77.5	2.00	6750	2436	75	5.09	135	0	3.0	8.0		
		Retested	7/22/36	8.9	99.8	144	59.0	1.58	7782	2488	74	4.03	95	0	3.0	8.0		
		Retested	7/29/36	8.9	100.4	208	79.0	2.15	7500	2185	82	4.36	145	1.5	5.0?	5.0		
80E	♂	Before	7/23/36	11.2	99.8	158	93.0	2.91	5634	2164	59	5.56	145	2.0	4.5	8.0	7/30	Dog apparently well.
		After		11.2	98.4	160	89.0	4.32	3642	1879	63	5.11	150	2.0	4.0	9.0		
		Retested	7/24/36	10.5	101.2	224	104.0	6.47	2973	1574	61	5.10	125	1.0	5.0	9.0		
		Retested	7/30/36	10.2	99.8	214	84.0	5.22	3040	1595	55	5.09	118	–	–	–		
81E	♀	Before	7/24/36	15.0	102.4	200	93.0	2.01	6788	–	91	4.83	125	5.5	4.5	7.0	7/25	Dog died several hours after procedure.
		After		15.0	101.7	164	92.0	2.57	5260	–	95	4.82	120	6.0	4.5	8.0		Autopsy: Atelectatic pneumonia left lung.
82E	♂	Before	7/25/36	16.9	100.6	216	134.0	3.74	4838	2273	65	4.13	123	3.0	3.5	6.0	8/1	Dog apparently well.
		After		16.9	100.0	144	124.0	4.84	3460	2380	65	4.06	118	1.0	5.0	8.0		
		Retested	7/27/36	16.7	101.1	208	114.0	4.14	3754	2387	61	3.85	115	5.0	5.0	8.0		
		Retested	8/ 1/36	15.5	101.9	200	115.0	2.72	6065	2728	68	3.92	125	5.5	6.0?	6.5		
10F	♀	Before	8/12/36	21.1	103.0	196	166.0	3.19	6060	3662	91	7.66	140	2.5	4.0	9.0	8/14	Dog died two days after procedure.
		After		21.1	102.8	180	167.0	3.88	5030	3735	91	7.10	130	2.5	4.5	10.5		
		Retested	8/13/36	20.2	103.6	200	173.0	5.99	3473	3643	97	7.26	130	2.0	5.0	12.0		Autopsy: Small hemorrhagic pericardial effusion, atelectatic pneumonia left upper lobe.

*Fifteen minutes after induction of anesthesia.

†Forty-five minutes after induction of anesthesia.

‡Using the Rubner constant for the dog, these values were computed from the Vierordt-Meeh formula, surface area in sq. m. = $0.112 \times \sqrt{(\text{weight in kg.})^2}$

with silk sutures and the residual pneumothorax "blown off." In the thoracotomy control group, exactly the same operative procedure, including dissection of the coronary branch, was carried out. In these animals, however, the vessel was not ligated.

Complete autopsies were done on all the animals that died or were killed. Each heart was examined, and, if an infarct was found, its size and character were noted. The left anterior descending branch was always probed to determine its patency. If an infarct was present, the heart was injected by the method of Gross[14] to determine its ex-

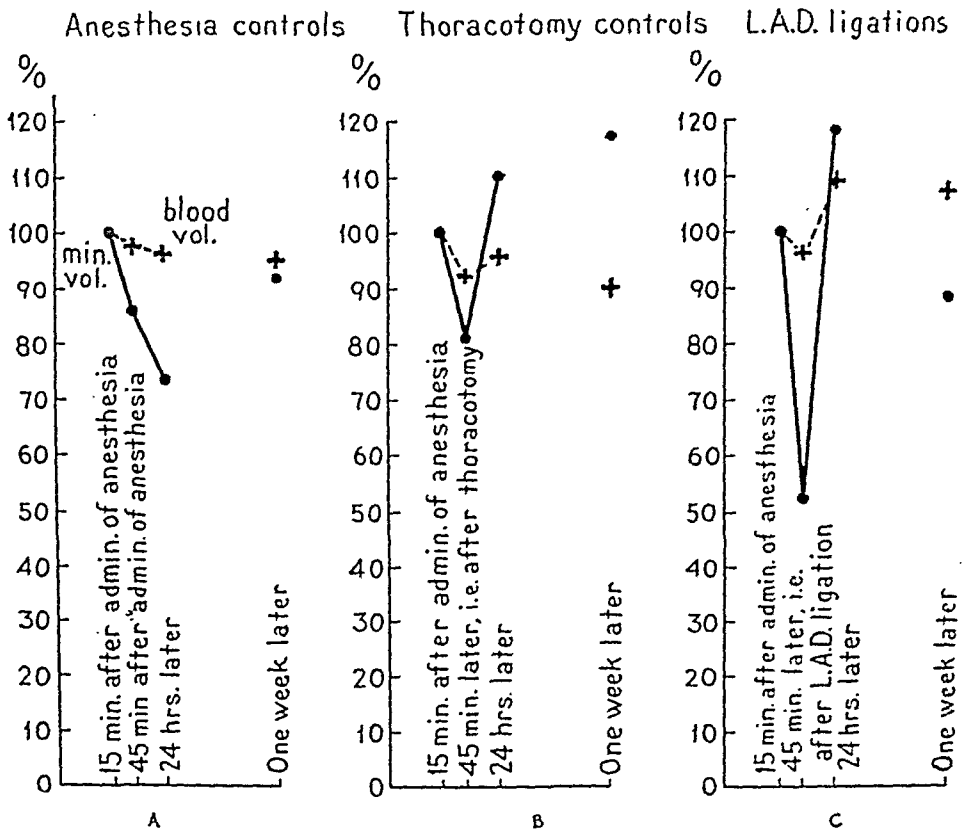

Fig. 1.—Average per cent changes in cardiac output (continuous black line) and in blood volume (dotted line) per square meter of surface area.

tent more exactly. Several of the animals in which the arteries were ligated died of ventricular fibrillation. Others died presumably of shock and pulmonary congestion. The most frequent cause of death in all dogs was pneumonia. Pneumothorax due to lung injury was a less common complication. Wound infection, hemopericardium, pericarditis, empyema, and lung abscess were rare. There was an occasional death following the injection of cyanide.

Table I lists the findings following the administration of anesthesia and therefore serves as a base line for the experiments to be described. Apart from the not inconsiderable fluctuations as between the differ-

ent animals, the only point worthy of note was a moderate immediate fall in average cardiac output. The decrease in average cardiac output became somewhat greater within twenty-four hours (Fig. 1*A*). A week later the average cardiac output was again measured and found to have returned to the original level. The exact time when this return took place was not studied. Figure 2 illustrates the case distribution as to immediate changes in cardiac output in this and in the subsequent experimental groups.

Table II lists the findings in the thoracotomy control group. In these animals, thoracotomy and left anterior descending branch dis-

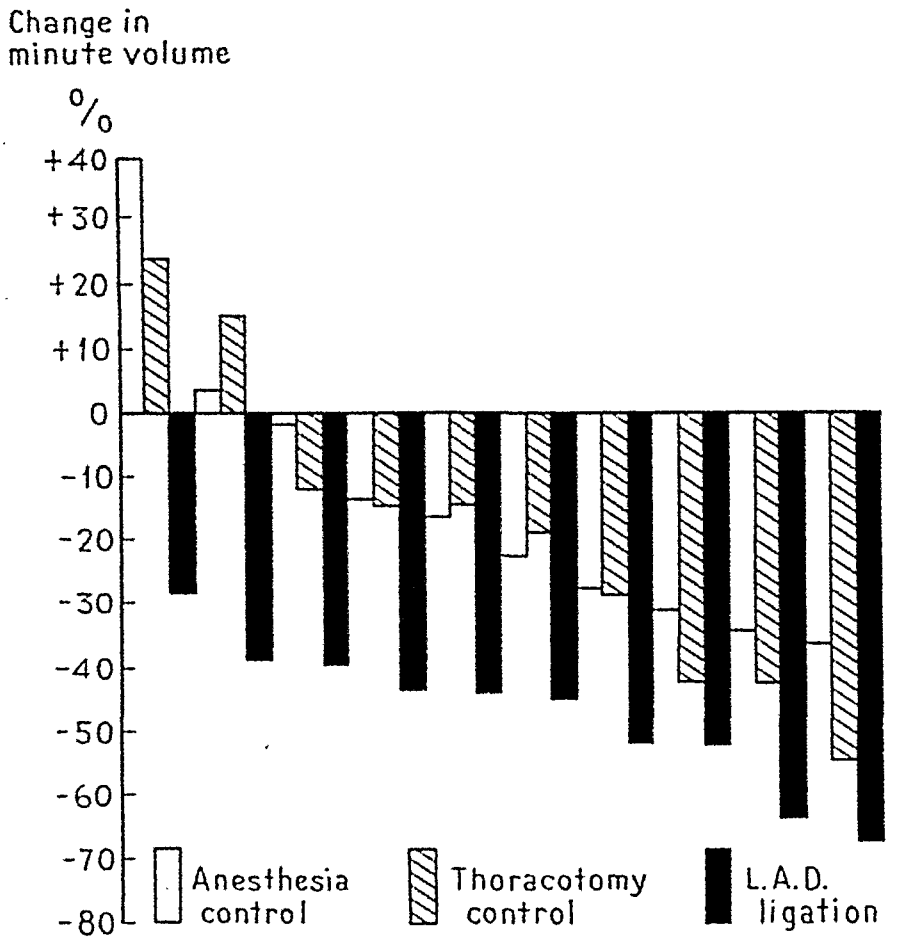

Fig. 2.—Individual case distribution with reference to the changes in cardiac output directly after the procedure.

section (without ligation) were carried out under anesthesia. Hemodynamic studies were made before opening and after closing the chest. As is seen, there was a somewhat greater immediate fall in average cardiac output which, however, tended to rise above the preoperative level within twenty-four hours (Fig. 1*B*). We are inclined to believe that the rise in some dogs in this group (Fig. 2) as well as in the coronary ligation group is* attributable to the partial pneumothorax following the thoracotomy.

*This rise above the preligation level is more apparent than real. Study of a larger series of animals (manuscript in preparation) discloses a twenty-four-hour rise in average cardiac output to almost preligation levels.

TABLE II

THORACOTOMY CONTROL EXPERIMENTS

DOG NO.	SEX	PROCEDURE	DATE	WEIGHT IN KG.	TEMPERATURE (F.)	PULSE RATE PER MINUTE	OXYGEN CONSUMPTION IN C.C. PER MINUTE	ARTERIOVENOUS OXYGEN DIFFERENCE, VOLUMES PER CENT	CARDIAC OUTPUT: MINUTE VOLUME PER SQ. METER IN C.C.	CARDIAC OUTPUT: TOTAL BLOOD VOLUME PER SQ. METER IN C.C.	HEMOGLOBIN PER CENT	TOTAL SERUM PROTEINS—GRAMS PER CENT	BLOOD PRESSURE: ARTERIAL IN MM. OF MERCURY	BLOOD PRESSURE: VENOUS IN CM. OF WATER	CIRCULATION TIME: ETHER IN SEC.	CIRCULATION TIME: CYANIDE IN SEC.		REMARKS
60D	♀	Preop.	4/ 1/36	17.0	101.0	172	114.0	2.52	6090	2331	91	6.36	135	4.5	4.0	7.0	4/2	Dog died several hours later. Autopsy: Bilateral lower lobe pneumonia. L.A.D. patent. No infarct.
		Postop.		17.0	98.0	138	104.5	3.25	4325	2311	104	7.77	130	5.0	5.5	11.0		
63D	♀	Prelim.	4/ 2/36	12.8	99.6	196	99.0	5.00	3231	2165	104	–	125	0	4.5	8.0	5/5	Dog died several hours postoperatively. Pneumonia found at operation. Autopsy: Pneumonic patches both lungs. L.A.D. patent. No infarct.
		Preop.	5/ 4/36	12.7	100.6	192	104.5	4.38	3918	2058	90	6.83	125	0	8.0?	10.0		
		Postop.		12.7	100.8	160	102.5	5.05	3334	2008	100	6.97	–	0	9.0?	12.0		
64D	♂	Prelim.	4/ 6/36	21.0	99.0	172	166.0	5.75	3386	2808	98?	7.61	110	7.5?	4.5	9.5	5/4	Dog sacrificed. Moderate hemopericardium found at operation. Autopsy: L.A.D. patent. No infarct. No other abnormalities.
		Preop.	4/22/36	21.9	101.2	194	158.0	9.18	1936	2640	98	6.75	210	9.5?	3.0	15.0?		
		Postop.		21.9	101.0	154	148.0	9.92	1704	2320	93	6.28	170	3.5	5.0	16.5		
		Retested	4/23/36	21.9	100.0	172	156.0	6.34	2810	2233	85	6.82	160	2.5	3.0	10.0		
		Retested	5/ 1/36	19.5	100.8	158	134.0	6.68	2480	2370	75	6.75	145	2.0	7.0?	9.0		
66D	♂	Prelim.	4/ 7/36	21.2	100.0	156	150.5	4.34	4041	2424	88	6.80	163	1.0	4.0	13.0?	5/11	Dog died. Wound ruptured two days before. Autopsy: Gangrenous wound infection. Atelectasis of both lungs. L.A.D. patent. No infarct.
		Preop.	5/ 2/36	21.0	–	220	188.5	3.15	7008	2612	60	6.12	175	3.5	4.0	6.5		
		Postop.		21.0	102.2	206	185.0	5.61	3868	2310	63	6.06	148	3.5	4.0	7.0		

TABLE II—CONT'D

67D	♂	Prelim.	4/ 8/36	12.2	101.4	206	109.0	2.01?	9175?	2620	84	6.74	157	2.0	3.5	8.5	4/24	Dog died one hour post-operatively probably from the combined effect of anesthesia, pneumothorax and the cyanide test. Autopsy: L.A.D. patent. No infarct. No abnormalities.
		Preop.	4/24/36	12.3	-	176	88.0	2.82	5230	2320	80	6.72	135	1.0	4.0	10.0		
		Postop.		12.3	98.0	146	77.5	5.48	2370	2165	83	7.07	118	1.0	6.0	11.0		
86D	♂	Preop.	6/ 3/36	19.8	101.5	185	143.0	4.63	3765	3108	89	6.20	128	1.0	2.5	7.0	6/8	Dog well.
		Postop.		19.8	102.0	164	153.0	6.16	3030	2548	92	6.38	110	3.5	4.0	10.0		
		Retested	6/ 8/36	18.2	-	168	124.0	4.33	3706	2486	82	5.69	110	1.0	4.0	9.0		
		Retested	6/ 8/36	18.2	98.2	136	113.0	3.58	4084	2410	85	5.33	90	3.0	7.0	indefinite		
5E	♂	Prelim.	5/14/36	13.0	99.0	172	106.8	4.36	3950	3300	106	-	148	3.5	13.0?	12.0	5/26	Dog well.
		Preop.	5/21/36	17.9	-	166	103.0	3.52	3790	2680	91	6.09	125	6.5	4.0	9.0		
		Postop.		17.9	95.8	120	101.0	4.08	3220	2430	87	6.12	60	0	18.5?	14.0		
		Retested	5/26/36	16.0	100.0	184	123.0	3.88	4460	2840	97	5.81	118	4.0	9.0?	9.0		
9E	♀	Prelim.	5/16/36	16.1	99.0	196	117.0	2.30	7095	2476	88	-	165	2.5	4.5	9.0	5/25	Dog died four hours post-operatively. Autopsy: Atelectatic pneumonia. L.A.D. patent. No infarct.
		Preop.	5/25/36	16.5	99.8	212	118.0	3.42	4740	2238	91	8.33	150	1.0	3.0	8.0		
		Postop.		16.5	99.0	156	104.0	5.23	2735	2080	93	9.68	112	0	indefinite	11.0		
11F	♂	Preop.	8/12/36	13.3	102.4	180	83.0	5.14	2563	2690	93	-	75	0	5.0	13.0	8/12	Dog died several hours postoperatively. Marked preoperative arterial anoxemia. Autopsy: Pneumonia right lung, probably more than one day old. L.A.D. patent. No infarct.
		Postop.		13.3	101.6	204	93.5	4.67	3175	2436	93	-	115	0	indefinite	13.5		
83F	♂	Preop.	9/29/36	19.0	99.5	172	151.0	3.76	5050	2710	89	6.03	145	3.0	3.0	8.5	9/30	Dog killed because of distemper. Autopsy: Bilateral lower lobe pneumonia. L.A.D. patent. No infarct.
		Postop.		19.0	98.1	140	130.5	2.82	5810	2620	89	5.47	130	3.5	5.0	10.5		
		Retested	9/30/36	18.0	101.7	166	151.0	4.97	3950	3060	99	5.29	100	1.5	4.0	12.0		

TABLE III

LEFT ANTERIOR DESCENDING BRANCH LIGATION EXPERIMENTS

DOG NO.	SEX	PROCEDURE	DATE	WEIGHT IN KG.	TEMPERATURE (F.)	PULSE RATE PER MINUTE	OXYGEN CONSUMPTION IN C.C. PER MINUTE	ARTERIOVENOUS OXYGEN DIFFERENCE, VOLUMES PER CENT	CARDIAC OUTPUT: MINUTE VOLUME PER SQ. METER IN C.C.	TOTAL BLOOD VOLUME PER SQ. METER IN C.C.	HEMOGLOBIN PER CENT	TOTAL SERUM PROTEINS—GRAMS PER CENT	BLOOD PRESSURE: ARTERIAL IN MM. OF MERCURY	BLOOD PRESSURE: VENOUS IN CM. OF WATER	CIRCULATION TIME: ETHER IN SEC.	CIRCULATION TIME: CYANIDE IN SEC.	REMARKS
58D	♂	Preop.	3/28/36	16.0	-	172	112.0	5.75	2738	2358	87	7.00	178	-	3.0	9.5	3/28 Dog died ½ hour post-operatively, apparently from the cyanide test. Autopsy: L.A.D. not patent. No apparent infarct.
		Postop.		16.0	-	154	114.0	10.35	1548	2202	91	6.31	140	-	6.5	15.0	
61D	♀	Prelim.	4/ 2/36	17.5	98.6	174	143.0	4.30	4406	2364	101	7.34	130	-	4.0	8.0	4/16 Dog died several hours postoperatively. Autopsy: Pneumonic patches in left lung. L.A.D. not patent. No apparent infarct.
		Preop.	4/16/36	17.3	-	176	130.5	3.17	5490	2100	93	5.53	155	1.0	4.0	8.0	
		Postop.		17.3	95.8	143	106.0	7.09	1995	2008	72	5.83	120	0	8.0	21.0	
71D	♂	Prelim.	4/10/36	19.2	102.1	130	147.0	3.29	5570	2350	119	7.57	187	-	3.0	7.0	5/11 Dog killed. Autopsy: L.A.D. not patent. Infarct present.
		Preop.	4/25/36	18.7	98.0	192	112.5	3.40	4200	-	88	5.91	170	1.5	4.0	7.0	
		Postop.		18.7	98.0	-	161.0	7.95	2570	-	94	7.34	155	1.0	4.0	8.0	
		Retested	4/27/36	17.8	101.8	215	135.0	2.20	8025	2443	86	6.99	165	3.5	3.0	8.0	
		Retested	5/ 4/36	16.5	99.8	200	108.0	3.01	4940	2312	89	6.75	153	2.5	4.0	7.5	
78D	♂	Prelim.	4/14/36	25.0	100.3	160	147.0	1.72	8920	2520	95	-	145	-	5.0	12.0	5/8 Dog died. Autopsy: Empyema and pericarditis. L.A.D. not patent. Infarct present.
		Preop.	4/28/36	24.0	99.6	180	161.5	2.39	7250	2439	71	7.48	145	3.5	5.0	indefinite	
		Postop.		24.0	98.2	148	152.5	4.03	4060	2458	76	7.09	140	0	3.5	11.0	
		Retested	4/29/36	23.2	101.2	188	157.0	2.81	6450	3100	76	5.85	130	2.5	3.0	indefinite	
		Retested	5/ 7/36	22.0	101.6	162	127.0	3.06	4725	2895	70	4.86	130	8.0	3.5	12.0	

TABLE III—CONT'D

94D	♂	Prelim.	5/11/36	13.6	-	184	103.0	2.18	7380	2870	88	8.00	165	3.0	4.0	7.5	6/2	Dog killed.
		Preop.	5/19/36	12.4	99.0	186	93.0	2.23	6950	2910	80	5.96	155	0	4.0	9.0		Autopsy: Fibrinous pericarditis, partially organized. L.A.D. not patent. Infarct present.
		Postop.		12.4	99.0	156	84.5	6.27	2240	2430	77	5.71	118	2.0	5.5	14.0		
		Retested	5/20/36	12.2	99.0	144	84.0	2.84	5010	2790	71	6.16	-	2.5	-	-		
		Retested	6/ 2/36	10.6	99.0	139	80.0	2.59	5720	3070	64	-	50	10.0	-	-		
1E	♂	Prelim.	5/18/36	19.0	100.6	180	126.0	4.04	3890	2920	85	5.72	135	6.0	4.5	16.0	5/29	Dog died several hours postoperatively.
		Preop.	5/28/36	19.0	99.4	160	114.0	2.17	6570	2650	84	5.55	148	2.0	4.0	10.0		Autopsy: Atelectatic pneumonic patches both lungs. L.A.D. not patent. No apparent infarct.
		Postop.		19.0	98.0	132	97.0	3.87	3140	2420	89	5.81	115	0.5	15.0	20.0		
7E	♂	Prelim.	5/15/36	17.2	101.2	156	112.0	2.63	5760	2519	87	-	143	4.0	7.0	9.5	5/22	Dog died 4 hours postoperatively.
		Preop.	5/22/36	16.2	101.4	168	97.0	2.27	5930	3041	92	-	125	4.0	4.0	9.0		Autopsy: Partial atelectasis left lung. L.A.D. not patent. No apparent infarct.
		Postop.		16.2	98.0	120	92.0	3.94	3240	2663	90	-	80	4.5	5.0	22.0		
8E	♂	Prelim.	5/16/36	16.0	100.6	152	109.0	4.67	3290	3120	92	-	95	0	4.5	10.0	5/23	Dog died several hours postoperatively.
		Preop.	5/23/36	17.0	100.0	160	123.0	3.51	4740	2370	75	5.76	125	7.5	4.0	9.0		Autopsy: Lungs congested. L.A.D. not patent. No apparent infarct.
		Postop.		17.0	99.0	180	108.0	5.14	2840	2390	76	6.93	105	4.0	5.0	11.5		
80E	♂	Preop.	8/10/36	10.5	99.6	184	92.0	4.33	3780	1843	68	5.56	130	1.0	3.5	6.0	8/11	Dog died several hours postoperatively.
		Postop.		10.5	98.0	154	80.2	5.30	2710	1885	68	5.10	100	2.5	-	-		Autopsy: Moderate atelectasis left lung. L.A.D. not patent. Infarct present.
4F	♀	Preop.	8/ 7/36	16.9	101.6	200	118.0	4.48	3553	2144	73	4.47	133	3.5	5.5	12.0	8/8	Dog died several hours postoperatively.
		Postop.		16.9	101.4	180	121.0	9.52	1718	1900	76	5.47	100	3.5	4.0	14.0		Autopsy: Congestion and scattered pneumonic patches in both lungs. Worms in right auricle and ventricle. L.A.D. not patent. No apparent infarct.

Those animals in which the anterior descending branch of the left coronary artery had been ligated presented an immediate decrease in average cardiac output more profound than in either series of controls (Table III). The findings in the individual dogs (Fig. 2) suggest that the diminution in cardiac output occurred consistently. Within twenty-four hours, the average cardiac output rose above* the preoperative level (Fig. 1*C*). Determinations made one week later on two surviving dogs showed a return of the average minute volume to the preoperative level. The immediate decrease in cardiac output was not accompanied by any marked diminution in oxygen consumption. A peripheral effect on metabolism could, therefore, not be held accountable for the diminished minute volume. It was the increase in arteriovenous blood oxygen difference that was usually the important factor. Since the pulse rate showed no consistent variations (a slight average acceleration in the anesthesia control group, as against a moderate average retardation in both of the other two groups) the changes in stroke volume, except for occasional deviations, usually followed those of minute volume. The changes in temperature were frequently directly proportionate to those in cardiac output and oxygen consumption, and inversely proportionate to those in the arteriovenous blood oxygen differences.

The diminution in blood volume was no greater in those dogs whose left anterior descending branch had been ligated than in the control groups. The small decrease often observed was usually at the expense of the plasma volume, there being a corresponding concentration of cells. The relatively slight changes in the percentage of hemoglobin and in the erythrocyte count usually agreed with the changes in cell volume and in arterial blood oxygen. There was rarely any significant change in serum proteins.

Recording of venous pressure, as previously mentioned, was subject to appreciable error. No significant changes were observed. Although fluctuations in mean arterial blood pressure were sometimes extreme, the anesthesia control group on the whole showed negligible changes. The thoracotomy control group, as well as the group with coronary branch ligation, showed an immediate fall in mean arterial blood pressure which averaged 28 mm. of mercury for each group. Inasmuch as both groups showed the same immediate fall, this cannot be attributed to the ligation alone, as was assumed by previous observers. However, the observations on blood pressure recorded here refer, with few exceptions, to preoperative and immediate postoperative levels. These, therefore, do not indicate the possible changes in blood pressure

*This rise above the preligation level is more apparent than real. Study of a larger series of animals (manuscript in preparation) discloses a twenty-four-hour rise in average cardiac output to almost preligation levels.

which may occur twenty-four hours and over after the experimental procedures. Such studies are being conducted at present and will form the basis of a subsequent report.

Ether circulation time also remained relatively unchanged, whereas the cyanide circulation time was moderately prolonged in the thoracotomy control group, but considerably more prolonged following left anterior descending branch ligation. This could be regarded as evidence of congestion in the pulmonary veins. The electrocardiograms were helpful adjuncts to our procedures. The changes that occurred following occlusion of the left anterior descending branch were so characteristic and constant (Gross and Calef[15]) that they were of help in determining the status of the animal in doubtful cases.

DISCUSSION

For reasons mentioned above, no figures are available on the hemodynamic findings in the normal unanesthetized animal. However, if one takes as a base line the changes as observed under anesthesia without operation, it is seen that the only appreciable alterations which follow thoracotomy alone are a tendency for the blood pressure to fall and for the moderately decreased average cardiac output to return to preoperative levels somewhat more rapidly. The additional factor of left anterior descending branch ligation is associated with a moderate immediate fall in average blood pressure. This is similar to that observed in the thoracotomy controls. No definite relation can therefore be established in our experiments between the vascular occlusion and the immediate decrease observed in the mean arterial blood pressure. As mentioned before, these observations on arterial blood pressure refer only to the period immediately following the operative procedures. The average cardiac output, in contrast to the arterial blood pressure changes, showed a definite immediate decrease considerably greater than that observed in either control group. This decrease was also associated with a moderate prolongation of cyanide circulation time. The twenty-four-hour and one-week average values for cardiac output are based on less reliable statistics since the determinations were done on the surviving dogs which represented considerably smaller groups of animals (5 in the anesthesia group, 4 in the thoracotomy group and 3 in the coronary ligation group). The relatively slight differences in average cardiac output between the two control groups is contrary to the reported marked effect of thoracotomy on cardiac output.[16] It was, nevertheless, deemed advisable to eliminate completely the factors introduced by thoracotomy. The results of left anterior descending branch occlusion produced in the closed chest will be subsequently reported.

SUMMARY

1. Methods are described for the study of the hemodynamic changes following left anterior descending coronary branch occlusion.

2. Anesthesia (nembutal) alone, anesthesia and thoracotomy, and left anterior descending coronary branch ligation carried out under anesthesia are accompanied by minimal immediate changes in pulse rate, venous blood pressure, hemoglobin, erythrocyte count, blood volume, and serum proteins. These changes are similar in all three groups. Left anterior descending branch ligation is associated with a moderate immediate fall in mean arterial blood pressure which, however, is no greater than that observed in the thoracotomy control group. Studies on arterial blood pressure twenty-four hours and over after these experimental procedures will be reported subsequently.

3. There is a somewhat greater immediate fall in temperature in the left anterior descending coronary branch ligation group.

4. Ether circulation time remains relatively unchanged, whereas cyanide circulation time is somewhat lengthened following left anterior descending coronary branch ligation.

5. Under anesthesia there occurs a moderate immediate decrease in average cardiac output.

6. After thoracotomy under anesthesia, the immediate decrease in average cardiac output is not significantly different from that under anesthesia alone. Within twenty-four hours the average cardiac output tends to rise to or above preoperative levels.

7. Following ligation of the left anterior descending coronary branch under anesthesia, there is a consistently greater immediate diminution in cardiac output. This also tends to rise to or above preoperative levels within twenty-four hours.

REFERENCES

1. Orias, O.: The Dynamic Changes in the Ventricles Following Ligation of the Ramus Descendus Anterior, Am. J. Physiol. 100: 629, 1932.
2. Fishberg, A. M., Hitzig, W. M., and King, F. H.: Circulatory Dynamics in Myocardial Infarction, Arch. Int. Med. 54: 997, 1934.
3. Harrison, T. R.: Failure of the Circulation, Baltimore, 1935, The Williams and Wilkins Co., page 328.
4. Fick, A.: Ueber die Messung des Blutquantums in den Herzventrikeln, Verh. d. Physikalisch-Medizinischen Gesellschaft zu Wurzburg 2: 16, 1870.
5. Van Slyke, D. D., and Neill, J. M.: The Determination of Gases in Blood and Other Solutions by Vacuum Extraction and Manometric Measurement, I., J. Biol. Chem. 61: 523, 1924.
6. Keith, N. M., Rowntree, L. G., and Geraghty, G. T.: A Method for the Determination of Plasma or Blood Volume, Arch. Int. Med. 16: 547, 1915.
7. Vercauteren, E.: Recherches sur la pharmacologie des réflèxes vasomoteurs du sinus carotidien, Arch. internat. de Pharmacodyn. et de thérap. 42: 339, 1932.
8. Bauer, W., Dale, H. H., Poulsson, L. T., and Richards, D. W.: The Control of Circulation Through the Liver, J. Physiol. 74: 343, 1932.

9. Moritz, F., and Von Tabora, D.: Ueber eine Methode beim Menschen den Druck in Oberflächlichen Venen Exact zu Bestimmen, Deutsches Arch. f. klin. Med. 98: 475, 1910.
10. Hitzig, W. M.: The Use of Ether in Measuring the Circulation Time From the Antecubital Veins to the Pulmonary Capillaries, AM. HEART J. 10: 1080, 1935.
11. Loevenhart, A. S., Schlomovitz, B. H., and Seybold, E. G.: The Determination of the Circulation Time in Rabbits and Dogs and Its Relation to the Reaction Time of the Respiration to Sodium Cyanide, J. Pharmacol. and Exper. Therap. 19: 221, 1922.
12. Wu, J.: A New Colorimetric Method for the Determination of Plasma Proteins, J. Biol. Chem. 51: 33, 1922.
13. Gross, Louis, Blum, L., and Silverman, G.: Experimental Attempts to Increase the Blood Supply to the Dog's Heart by Means of Coronary Sinus Occlusion, J. Exper. Med. 65: 91, 1937.
14. Gross, Louis: The Blood Supply to the Heart, New York, 1921, Paul B. Hoeber, page 4.
15. Gross, Louis, and Calef, Bension: Electrocardiographic Changes in the Dog Following Sudden Occlusion of the Left Anterior Descending Coronary Branch Under Various Experimental Conditions (In Manuscript).
16. Moore, R. L., Humphreys, G. H., and Wreggit, W. R.: Studies on the Volume Output of Blood From the Heart in Anesthetized Dogs Before Thoracotomy and After Thoracotomy and Intermittent or Continuous Inflation of the Lungs, J. Thoracic Surg. 5: 195, 1935.

HEMODYNAMIC STUDIES IN EXPERIMENTAL CORONARY OCCLUSION*

II. Closed Chest Experiments

Milton Mendlowitz, M.D.,† Gerhard Schauer, M.D., and Louis Gross, M.D.
New York, N. Y.

IN PREVIOUS reports[1, 2] we have recorded the effects of ligation of the anterior descending branch of the left coronary artery on cardiac output, blood pressure, circulation time, blood volume, and related functions, in the dog. Control observations on the changes in these functions under anesthesia alone and under anesthesia plus thoracotomy revealed a moderate immediate diminution in average cardiac output in both of these series of animals. In spite of the fact that there was no significant difference in immediate average cardiac output as between these two control groups, it was deemed advisable to eliminate the thoracotomy factor at the time of ligation in order to make possible a less complicated appraisal of the circulatory changes after coronary occlusion.

In order to establish a satisfactory technic for acute occlusion of the left anterior descending coronary branch in the closed chest, we experimented with various procedures. The glass cannula of Sutton and Lueth[3] was found to be unsatisfactory because it necessitated the introduction of a rigid tube into the chest with possible limitation of cardiac movement after ligation and with the danger of infection and pneumopericardium. Metal clamps were a possible source of local irritation. It was thought, however, that ligation of the artery from the exterior of the chest could be made feasible by the use of a suitable slipknot. An important feature in the selection of the knot was to have one in which the ends of the threads emerge at opposite points on the chest in order to avoid pulling or rotating the heart by traction on the thread. An adaptation of a double slipknot (the double carrick bend used for reefing) seemed to answer the requirements. Figure 1 illustrates diagrammatically the arrangement of this knot around the coronary vessel.

EXPERIMENTAL

The application of the knot is carried out in the following manner: The chest and pericardium are opened in the usual way. A portion of the anterior descending branch of the left coronary artery near its

*From the Laboratories of The Mount Sinai Hospital, New York, N. Y.
Aided by grants from the Lucius N. Littauer and Walter W. Naumburg Funds.
†George Blumenthal, Jr., Fellow.
Aided by a grant from the Emanuel Libman Fellowship Fund.

origin is freed by careful dissection. A double thread (No. 2 Pagenstecher linen) is then passed under the vessel with a blunt half curved needle. The knot is made as shown in Fig. 1 and drawn loosely around the vessel by traction of both upper threads against both lower threads. With a straight Hagedorn needle the upper threads are then passed through the anterior pericardium and chest wall to the left of the sternum beyond the edge of the wound. Leaving sufficient slack, the emerging threads are sutured to the skin with one stitch and tied securely. The two posterior threads are passed through the posterolateral pericardium well below the phrenic nerve.

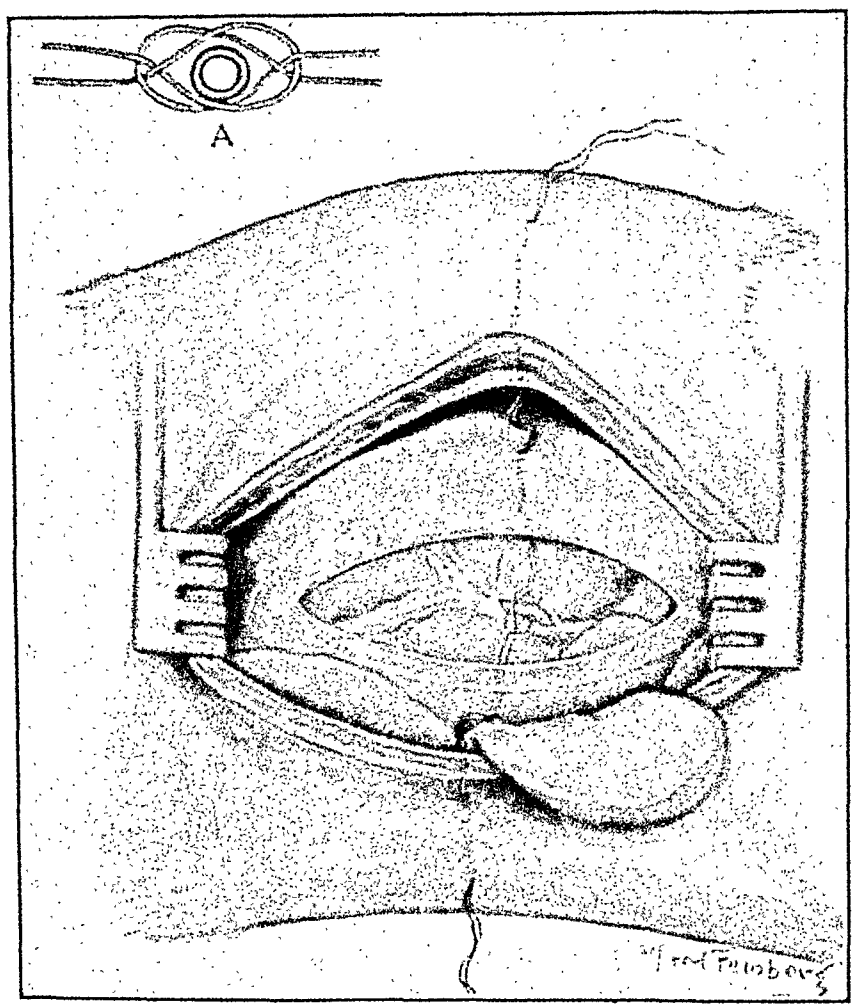

Fig. 1.—The double carrick bend in place on the left anterior descending coronary branch. *A*, Detail of the knot around the artery in cross-section.

They are then passed between the lower and middle lobes of the left lung, and with a long straight Hagedorn needle, brought through the posterolateral chest wall in the fourth or fifth interspace. The emerging threads are sutured to the skin and tied. The pericardium and chest are closed in the usual manner, and a dry gauze dressing is applied and kept in place by a wide adhesive bandage and a dog-jacket made of a towel and safety pins. The artery is ligated one to two weeks after the operation in those dogs which survive this procedure.

The ligation is done under sterile conditions. The slack is eliminated by traction of the anterior two threads against the posterior

two. Any adhesions that have formed are broken in this way. One of the anterior threads is then drawn taut by traction against one of the posterior, following which action the other anterior thread is pulled against the other posterior one. This serves to tighten the double noose gradually and, with several alternations, completely.

The completeness of the vessel occlusion produced in this manner was confirmed by many observations. In only one of the dogs which died before the knot was tied, was the artery found occluded. In one other experiment there was electrocardiographic as well as physiological evidence that the vessel had been occluded by the ligature before the actual manipulation of the threads. In these earlier experiments, insufficient slack had been left. In one animal in which the artery had presumably been ligated, the vessel was found to be patent at autopsy. There was a small pericardial abscess at the site of the knot, causing dissolution of the thread, which in this early experiment was silk and not linen. With these exceptions, the vessel was found to be patent in all animals which died before the knot was tied, and in those dogs in which the artery was ligated there was always electrocardiographic evidence of occlusion. Furthermore, when the latter animals came to autopsy a probe could not be passed beyond the ligature, and if the dog had survived for more than several hours, an infarct could be seen grossly and demonstrated by injection.

The electrocardiogram was usually of considerable aid in determining the cardiac status. As emphasized by Harris and Hussey[4] and recently confirmed by Gross and Calef,[5] the characteristic change after left anterior descending branch occlusion was elevation of the R-T segment in Lead I with or without depression of this segment in Lead III. In one dog, for example, in which the electrocardiogram showed no change and the physiological studies were atypical for occlusion, autopsy disclosed that the noose had accidentally been placed around some muscle fibers and not around the artery, which was patent.

In our control experiments exactly the same procedure was carried out, except that the ligature was placed around some relatively avascular left ventricular muscle near the vessel. Electrocardiographic changes considered characteristic of anterior ventricular wall infarction were never found in these cases.

Ten dogs were used for the control experiments and ten dogs for the left anterior descending branch ligation. In both groups a series of studies was carried out on the hemodynamics of the circulation similar to those described in the previous report. These studies were made under anesthesia before and after traction on the external sutures, one day later and one week later.

As shown in Table I, the results following ligation of a small portion of myocardium by traction on the sutures outside the chest were not appreciably different from those described in the previous report[2] following anesthesia alone or anesthesia plus thoracotomy. There was a moderate immediate decrease in the average cardiac output which remained at approximately the same level at the end of twenty-four hours (Fig. 2*A*). No further studies were made until one week later, when the average minute volume was found to be considerably above the preligation level, due, presumably, to the associated relative anemia which these animals developed.

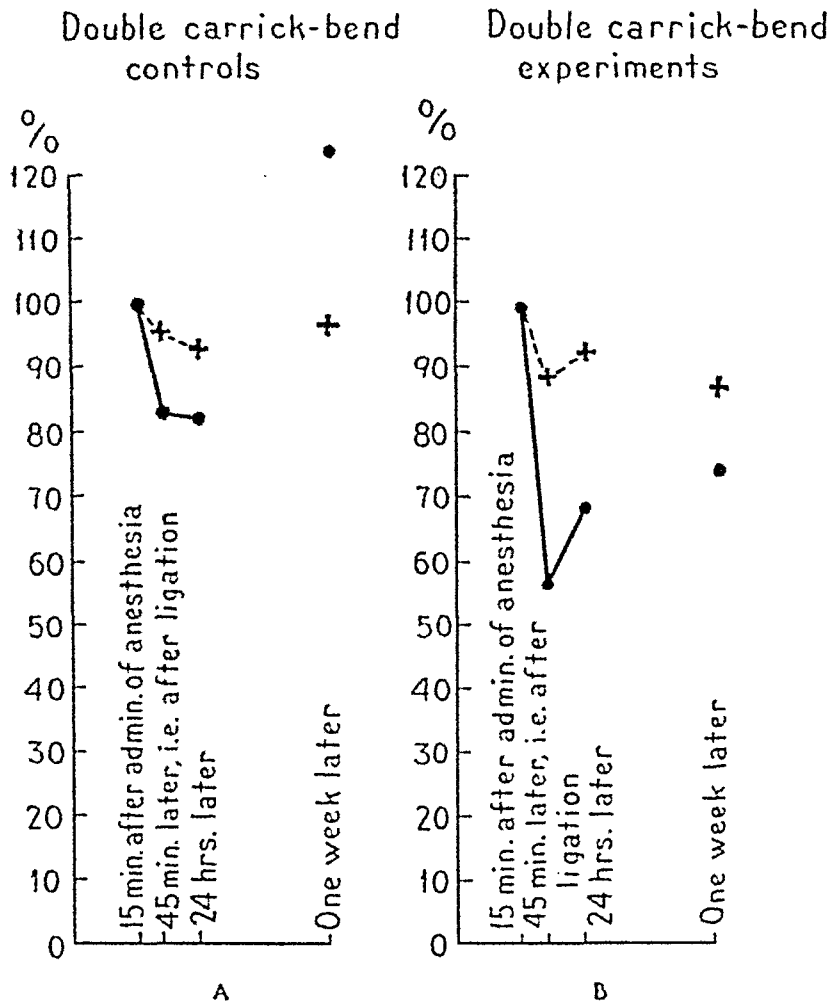

Fig. 2.—Average per cent changes in cardiac output (continuous black line) and in blood volume (dotted line) per square meter of surface area.

Similarly (Table II), ligation of the left anterior descending branch by traction on the sutures outside the chest was followed by essentially the same immediate changes in cardiac output (Fig. 2*B*) as occurred in the dogs in which ligation was performed in the open chest.[2] Immediately after ligation of the vessel there was a decrease in average cardiac output more profound than in the control group. The cardiac output of individual dogs showed this decrease consistently (Fig. 3). Twenty-four hours later, the average output had risen somewhat but had not yet reached preoperative levels. One

TABLE I

DOUBLE CARRICK-BEND CONTROL EXPERIMENTS

DOG NO.	SEX	PROCEDURE	DATE	WEIGHT IN KG.	TEMPERATURE (F.)	PULSE RATE PER MINUTE	OXYGEN CONSUMPTION IN C.C. PER MINUTE	ARTERIOVENOUS OXYGEN DIFFERENCE, VOLUMES PER CENT	CARDIAC OUTPUT: MINUTE VOLUME PER SQ. METER IN C.C.	TOTAL BLOOD VOLUME PER SQ. METER IN C.C.	HEMOGLOBIN PER CENT	TOTAL SERUM PROTEINS—GRAMS PER CENT	BLOOD PRESSURE: ARTERIAL IN MM. OF MERCURY	BLOOD PRESSURE: VENOUS IN CM. OF WATER	CIRCULATION TIME: ETHER IN SEC.	CIRCULATION TIME: CYANIDE IN SEC.		REMARKS
86D	♂	Prelig.*	6/ 8/36	18.2	-	168	124.0	4.33	3706	2486	82	5.69	110	1.0	4.0	9.0	6/8	Dog died 2½ hours after ligation. Autopsy: hemorrhagic effusion in both pleural cavities; L.A.D. patent; no infarct.
		Postlig.		18.2	98.2	136	113.0	3.58	4084	2410	85	5.33	90	3.0	7.0	-		
84E	♂	Prelig.	8/ 3/36	11.9	101.0	196	87.0	4.66	3200	2256	94	4.38	125	1.5	4.0	9.0	8/3	Dog died ½ hour after ligation. Autopsy: L.A.D. patent; no infarct.
		Postlig.		11.9	99.6	200	83.0	6.97	2040	2118	99	4.48	130	2.5	5.0	15.0		
88E	♀	Prelig.	8/ 4/36	12.4	103.4	160	95.0	3.96	4000	2078	84	4.88	95	2.0	6.0	8.0	8/4	Dog died 2 hours after ligation. Autopsy: atelectatic pneumonia both lungs; L.A.D. patent; no infarct.
		Postlig.		12.4	103.4	166	91.0	4.94	3070	2330	84	4.69	95	1.0	3.5	9.5		
89E	♂	Prelig.	8/ 5/36	15.0	101.4	178	99.0	5.30	2740	2515	86	3.98	150	-	5.0	12.0	8/20	Dog apparently well.
		Postlig.		15.0	102.0	182	104.0	8.60	1776	1910	88	4.04	155	1.0	7.0	-		
		Retested	8/ 6/36	15.0	102.0	168	101.5	-	-	2322	86	4.43	90	-	5.0	8.0		
		Retested	8/14/36	15.0	102.1	176	105.0	4.18	3690	2193	72	4.30	130	2.5	5.0	12.0		

*Ligation of left ventricular muscle.

TABLE I—CONT'D

90E	♀	Prelig.	8/ 6/36	11.4	99.6	152	91.0	4.39	3633	1705	80	6.31	95	3.0	4.0	7.0	8/7	Dog died 1 day after ligation. Autopsy: pneumonic patches both lungs; L.A.D. patent; no infarct.
		Postlig.		11.4	98.2	158	77.0	5.18	2608	1648	85	5.66	115	2.5	-	8.0		
96E	♂	Prelig.	8/13/36	12.4	102.6	200	94.0	3.74	4192	2272	90	5.65	135	0	6.0	8.5	8/24	Dog died several hours after second retesting. Autopsy: small pneumonic patches in right lung; L.A.D. patent; no infarct.
		Postlig.		12.4	102.6	184	98.0	4.13	3957	2040	87	5.42	140	0	5.0	12.0		
		Retested	8/15/36	11.8	103.6	210	109.0	4.33	4340	2060	70	5.51	145	0	-	12.0		
		Retested	8/22/36	12.2	101.0	186	80.0	3.31	4073	1965	66	-	125	2.5	4.0	12.0		
97E	♂	Prelig.	8/14/36	10.8	102.2	180	108.0	3.51	5560	2070	72	4.54	135	0	3.5	10.0	8/15	Dog died of overanesthesia 1 day after ligation before first retesting could be completed. Autopsy: L.A.D. patent; no infarct.
		Postlig.		10.8	102.6	180	101.0	4.32	4220	2052	70	4.74	118	0	4.0	12.0		
98E	♂	Prelig.	8/17/36	15.7	103.1	162	122.0	1.87	9290	2545	70	4.34	165	4.5	4.0	14.0	8/20	Dog died 1 day after last retesting, at which time there was a marked arterial anoxemia. Autopsy: pneumonic patches both lungs; L.A.D. patent; no infarct.
		Postlig.		15.7	102.8	214	117.0	2.13	7825	2156	70	4.52	155	4.5	4.0	14.0		
		Retested	8/18/36	14.9	102.1	162	106.0	-	-	1850	70	4.52	115	3.5	3.5	14.0		
		Retested	8/19/36	14.9	102.2	130	104.0	5.21	2940	2042	68	4.03	58	2.5	4.0	11.5		
100E	♂	Prelig.	8/17/36	11.2	102.4	138	85.5	3.39	4495	2054	72	4.80	103	3.0	-	11.5	8/24	Dog apparently well.
		Postlig.		11.2	101.7	120	87.0	4.56	3400	2256	72	5.37	88	2.5	5.0	10.5		
		Retested	8/19/36	11.4	101.7	130	86.0	2.98	5080	2340	63	5.45	78	1.5	4.0	12.0		
		Retested	8/24/36	11.0	102.1	106	86.0	2.98	5200	2253	57	-	108	9.0	-	-		
1F	♂	Prelig.	7/18/36	12.0	100.4	142	97.5	3.72	4465	2168	88	6.12	110	2.5	4.0	11.0	8/24	Dog apparently well.
		Postlig.		12.0	99.2	136	92.0	3.14	4995	2225	90	5.63	110	2.5	6.0	19.5		
		Retested	8/19/36	11.7	100.8	144	89.5	4.30	3600	1950	87	5.43	68	2.5	6.5	11.0		
		Retested	8/24/36	11.7	101.6	164	117.0	3.08	6550	2270	66	-	125	2.5	3.5	6.5		

TABLE II

DOUBLE CARRICK-BEND EXPERIMENTS

DOG NO.	SEX	PROCEDURE	DATE	WEIGHT IN KG.	TEMPERATURE (F.)	PULSE RATE PER MINUTE	OXYGEN CONSUMPTION IN C.C. PER MINUTE	ARTERIOVENOUS OXYGEN DIFFERENCE, VOLUMES PER CENT	CARDIAC OUTPUT: MINUTE VOLUME PER SQ. METER IN C.C.	CARDIAC OUTPUT: TOTAL BLOOD VOLUME PER SQ. METER IN C.C.	HEMOGLOBIN PER CENT	TOTAL SERUM PROTEINS—GRAMS PER CENT	BLOOD PRESSURE: ARTERIAL IN MM. OF MERCURY	BLOOD PRESSURE: VENOUS IN CM. OF WATER	CIRCULATION TIME: ETHER IN SEC.	CIRCULATION TIME: CYANIDE IN SEC.	REMARKS
15E	♂	Prelig.*	6/17/36	10.8	99.0	155	69.0	3.66	3412	2452	70	5.81	93	2.0	-	13.0	6/19 Dog died after first retesting. Autopsy: lungs congested; scattered atelectatic pneumonic patches; L.A.D. not patent; infarct 4 × 4 cm.
		Postlig.		10.8	97.2	138	69.0	5.77	2165	1854	70	6.04	120	1.0	-	18.0	
		Retested	6/18/36	10.5	100.4	140	85.0	6.13	2563	1916	58	5.31	60	1.0	4.0	30.0	
81D	♂	Prelig.	6/22/36	15.7	99.0	168	113.5	4.44	3645	2957	75	-	113	1.0	6.0	9.5	6/23 Dog died several hours after ligation. Autopsy: slight wound infection; lungs congested; L.A.D. not patent; no apparent infarct.
		Postlig.		15.7	97.0	152	109.0	5.90	2634	2735	75	5.56	133	0.5	5.5	10.0	
84D	♂	Prelig.	6/23/36	11.2	97.2	196	99.0	3.82	4569	2283	75	4.38	135	0	3.5	8.0	6/30 Dog died of overanesthesia after second retesting. Autopsy: several atelectatic patches both lower lobes; L.A.D. not patent; infarct 2 × 3 cm. with aneurysmal dilatation.
		Postlig.		11.2	95.0	168	75.0	3.80	3479	2458	75	4.48	100	1.0	5.0	10.0	
		Retested	6/24/36	10.8	100.2	152	96.0	3.08	5645	2175	60	-	65	1.0	4.0	13.0	
		Retested	6/30/36	11.1	-	180	102.5	2.41	7540	-	61	-	105	7.0	-	-	
85D	♂	Prelig.	6/24/36	15.9	100.4	170	116.5	2.48	6620	-	72	-	135	3.0	6.0	10.0	6/24 Dog died of ventricular fibrillation before 2nd series of tests could be completed. Autopsy: L.A.D. not patent; no apparent infarct.
		Postlig.		15.9	-	152	114.0	3.94	4078	-	-	-	147	-	-	-	

*Ligation of L.A.D. coronary branch.

TABLE II—CONT'D

35E	♂	Prelig.	6/25/36	14.0	98.5	188	106.0	1.75	9268	2605	62	5.00	135	2.5	4.0	8.5	7/1	Dog killed. Autopsy: lungs congested; L.A.D. not patent; infarct present; roundworms in right auricle and ventricle.
		Postlig.		14.0	96.8	88	99.0	5.64	2683	1908	57	5.12	115	0	5.5	12.0		
		Retested	6/26/36	13.8	100.2	166	127.0	4.05	4845	2308	49	5.77	75	2.0	6.0	16.0		
		Retested	6/30/36	12.0	102.1	172	121.0	3.20	6405	2148	59	4.43	99	0	5.0	9.0		
39E	♂	Prelig.	6/26/36	12.4	99.0	168	95.5	4.81	3308	2658	64	5.82	120	0	4.0	8.5	6/27	Dog died of overanesthesia before 1st retesting could be done. Autopsy: L.A.D. not patent; infarct present.
		Postlig.		12.4	97.4	130	79.0	8.82	1490	2300	74	6.50	95	3.5	7.0	17.0		
38E	♂	Prelig.	6/29/36	-	99.4	168	106.0	2.07	-	-	76	6.52	110	3.5	3.0	10.0	6/29	Dog died one-half hour after ligation. Autopsy: preexisting pneumonia with small empyema; L.A.D. not patent; no apparent infarct.
		Postlig.		-	97.0	160	90.0	4.20	-	-	82	6.82	100	3.5	-	9.0		
22F	♂	Prelig.	8/26/36	18.4	102.6	202	151.0	3.00	6450	2810	76	4.36	120	0	4.5	9.5	8/27	Dog died 3 hr. after 1st retesting. Autopsy: pneumonic patches both lungs; L.A.D. not patent; no apparent infarct.
		Postlig.		18.4	102.0	208	133.0	3.98	4280	2730	76	4.46	118	1.0	4.0	13.0		
		Retested	8/27/36	17.6	103.6	170	165.5	6.20	3515	3000	77	3.93	85	2.5	10.0	15.0		
58F	♂	Prelig.	9/23/36	11.6	99.8	166	94.0	1.88	8700	2450	65	3.82	90	0	4.0	10.0	10/2	Dog killed. Autopsy: L.A.D. not patent; infarct present.
		Postlig.		11.6	98.2	189	79.5	3.30	4180	2026	74	4.12	125	1.0	4.0	10.5		
		Retested	9/24/36	10.9	100.4	142	95.0	5.17	3330	2420	67	3.63	70	1.0	4.5	14.0		
		Retested	10/ 1/36	11.2	100.8	144	111.0	2.84	6975	2253	60	2.56?	95	3.5	7.5?	11.5		
26G	♀	Prelig.	10/24/36	12.0	101.4	215	114.0	4.69	4140	2426	81	6.23	130	3.0	6.0	10.5	10/25	Dog died 24 hr. after ligation. Autopsy: moderate bilateral hemorrhagic pleural effusion; pneumonia left lower lung; L.A.D. not patent; infarct present.
		Postlig.		12.0	99.0	166	104.0	7.33	2420	2240	84	5.79	143	0.5	-	14.5		

week later, the average minute volume was closer to the preligation level. The twenty-four-hour and the one-week average values represented fewer animals and were therefore considered less reliable.

The changes in the other functions were also similar to those observed in our previous experiments.[2] The temperature, usually in direct ratio to the minute volume, was lower after ligation of the artery than in the control dogs. The arteriovenous oxygen difference, usually in inverse ratio to the cardiac output, was greater after ligation of the vessel than after ligation of ventricular muscle. Although there was a moderate prolongation of cyanide circulation time in some

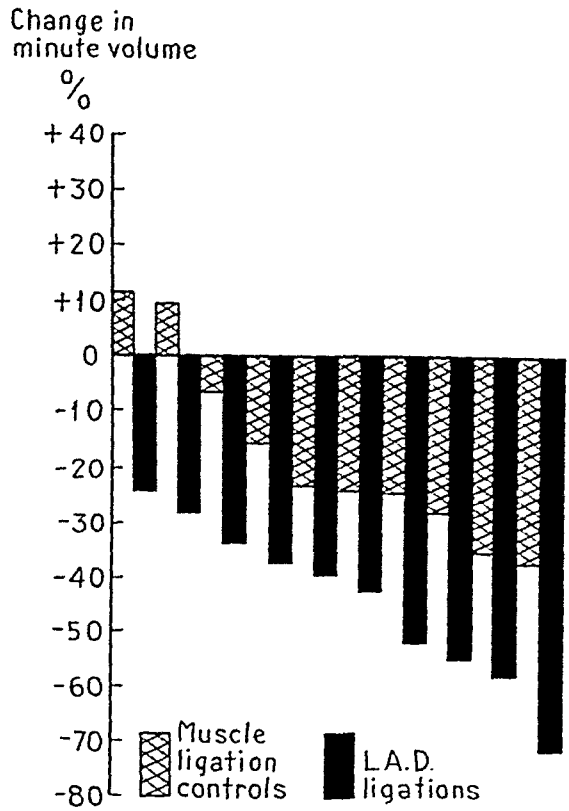

Fig. 3.—Individual case distribution with reference to the changes in cardiac output directly after the procedure.

of the control animals, this was usually more marked in those dogs in which the vessel was ligated. There was no significant change in ether circulation time. The blood volume was usually slightly diminished in both groups, and the changes in hemoglobin percentage and in erythrocyte count usually coincided with those in cell volume. The serum proteins remained relatively unchanged. The average pulse rate was moderately retarded in the animals in which the vessel was ligated. The average immediate changes in blood pressure were approximately the same as in the anesthesia controls previously described.[2] There was no immediate decrease in the average mean arterial blood pressure in either group such as was observed in our thoracotomy controls or after

ligation in the open chest. The observations on arterial blood pressure made twenty-four hours and over after ligation of the artery or of myocardial fibers (control) suggest a fall in blood pressure in both groups of experiments which exceeded that found in the anesthesia and thoracotomy controls. The number of animals on which these blood pressure readings were made was too small to warrant definite conclusions. A more extended series of such studies will be reported elsewhere.

Although the venous pressure was not subject to the errors introduced by thoracotomy, i.e., alteration in the position of the heart and increased intrathoracic pressure because of residual pneumothorax, it did not change consistently with coronary artery ligation. It must be remembered that the venous pressure, like the arterial pressure, represents a balance of two opposite forces. One is the head of pressure remaining after the blood has traversed the capillaries, plus any additional pressure afforded by the tone of the venous vessel walls and of the surrounding muscles. The other is the resistance encountered in the chest and heart, plus or minus the hydrostatic pressure, depending upon the level at which the venous pressure is measured in relation to the heart. Since the hydrostatic factor is constant in our experiments, it can be considered eliminated for comparative purposes. The competence of the venous valves is another factor which, for our purposes, can be neglected. In our experiments, then, the diminution in cardiac output would tend to reduce the residual head of pressure in the veins. The congestion in the pulmonary circuit would, however, tend to increase the pressure in the right heart and therefore offer resistance to venous inflow. The venous pressure reflecting the balance of these forces could, therefore, reasonably be expected to be variable.

DISCUSSION

From the above mentioned findings, it is apparent that the effect of thoracotomy on the factors studied was negligible. The principal changes after experimental occlusion of the anterior descending branch of the left coronary artery in the closed chest experiments were similar to those in the open chest experiments. They consisted of an immediate diminution in cardiac output and an increase in cyanide circulation time. The diminution in cardiac output, in our opinion, represents what Harrison[6] terms hypokinetic circulatory failure despite the inconsistent variations in arterial and venous blood pressure. The prolonged cyanide circulation time, in the absence of significant changes in ether circulation time and venous pressure, is evidence of congestion in the pulmonary veins. The relatively insignificant immediate changes in the arterial blood pressure suggest that, for at least a short period following coronary occlusion, a peripheral vasoconstriction in the dog compensates for the diminution in cardiac output. Experiments subsequently to be described afford evidence to support this view. A limited

number of figures available suggest that twenty-four hours after the coronary ligation (possibly also after muscle ligation) there occurs a fall in blood pressure. This point will be reported elsewhere on a more extensive series.

The observations on cardiac output following experimental coronary occlusion suggest that we are dealing with a combination of left ventricular congestive failure and hypokinetic circulatory failure. Whether the latter represents true "forward failure," that is, whether it is entirely cardiogenic, is still open to question. The absence of blood volume changes rules out the possibility that the diminished output is hematogenic, i.e., caused by loss of blood or plasma in or about the injured myocardium, or that it is vasogenic, i.e., due to a similar loss because of a deleterious effect on peripheral capillaries in general. The neurogenic hypothesis still remains to be considered. The occurrence of a consistent diminution in cardiac output as well as the fact that this diminution occurred while the animal was under anesthesia affords some evidence against this possibility.[7] In order to rule it out completely, a similar series of studies was carried out in dogs with denervated hearts. This will form the subject of a subsequent report.

SUMMARY

1. A method for ligating the anterior descending branch of the left coronary artery from the exterior of the chest is described.

2. The changes in circulation following this procedure were:

   a. Hypokinetic circulatory failure (diminished cardiac output).
   b. Left ventricular congestive failure (increased cyanide circulation time).

3. Because of the absence of any corresponding decrease in blood volume the diminished cardiac output could not be considered to be either hematogenic or vasogenic.

4. Indirect evidence against the neurogenic hypothesis is also presented.

REFERENCES

1. Gross, Louis, Mendlowitz, M., and Schauer, G.: Hemodynamics Following Experimental Coronary Occlusion in Dogs, Proc. Soc. Exper. Biol. & Med. 35: 446, 1936.
2. Gross, Louis, Mendlowitz, M., and Schauer, G.: Hemodynamic Studies in Experimental Coronary Occlusion: I. Open Chest Experiments, Am. Heart J. 13: 647, 1937.
3. Sutton, D. C., and Lueth, H. C.: Pain, Arch. Int. Med. 45: 827, 1930.
4. Harris, Benedict R., and Hussey, Raymond: Electrocardiographic Changes Following Coronary Artery Ligation in Dogs, Am. Heart J. 12: 724, 1936.
5. Gross, Louis, and Calef, Bension: Electrocardiographic Changes in the Dog Following Sudden Occlusion of the Left Anterior Descending Coronary Branch Under Various Experimental Conditions. (In Manuscript.)
6. Harrison, T. R.: Failure of the Circulation, Baltimore, 1935, Williams and Wilkins Co., page 11.
7. Blalock, A.: Effects of Primary Shock on Cardiac Output and Blood Pressure, Proc. Soc. Exper. Biol. & Med. 31: 36, 1933.

THE DIAGNOSIS OF IMPENDING ACUTE CORONARY ARTERY OCCLUSION*

JOHN J. SAMPSON, M.D., AND MAURICE ELIASER, JR., M.D.
SAN FRANCISCO, CALIF.

IT IS well recognized that acute coronary artery occlusion is often preceded for months or years by attacks of characteristic angina pectoris. Even prior to the time that Herrick,[1] Dock,[2] and others defined the syndrome of acute coronary artery occlusion, the diagnosis of angina pectoris carried with it the grave possibility of sudden death especially as a sequel to "angina pectoris decubitus."

In contrast to the occurrence of progressive angina pectoris, it has been apparent to us, on observation of a series of cases extending over two and one-half years, that a single spontaneous attack of prolonged anginal pain strongly suggests the approach of a typical coronary thrombosis. Certain characteristics of these attacks of pain seemed to be so well defined that several individuals were put to bed either at home or in a hospital from one to fourteen days prior to the development of the typical symptoms and signs of the arterial block.

Levine[3] summarized those elements in the patients' history that commonly seemed to precede the attack, especially emphasizing mild general discomfort and fatigue. Conner and Holt[4] and Parkinson and Bedford[5] describe the occurrence of transitory pains in the chest of a nature different from previous anginal attacks. These pains occasionally precede the typical coronary artery occlusion. Herrick[1] mentions in one of his case histories a premonitory attack of pain of unusual nature arising three days prior to the occlusion. Feil[6] in a recent personal communication stated that he had assembled a group of cases similar to those we are presenting which indicated to him the importance of this premonitory symptom.

An interesting clinical comparison may be drawn between the diagnosis of impending coronary artery occlusion and impending occlusion of an intestinal artery. Dunphy[7] defined the typical features of the latter condition and quoted a case history of premonitory pain occurring two months prior to death from the acute block of gradually thrombosing celiac axis and inferior mesenteric arteries.

Benson[8] and others have described sclerotic coronary arteries which, though narrowed to a minute anatomical pathway, still carry a stream of blood. Such small channels can carry conceivably only inadequate supplies. Because of varying dynamic factors, this reduced flow may

*From the Mount Zion Hospital and the University of California Medical Service of the San Francisco Hospital, Department of Public Health.

be temporarily insufficient to maintain normal myocardial function and may thus produce pain. It is the prevalent opinion that blockage occurs less frequently in arteries of good aperture than those that have been gradually narrowed to an extreme degree. Special importance is placed on this process in encouraging the development of collateral coronary circulation by Beck,[9] Wearn and his associates,[10] and Gross and Kugel.[11] Therefore it is unnecessary to assume that pain of a more prolonged and possibly different character than earlier angina pectoris must be produced by an anatomically closed arterial lumen. It may be expected that a vessel narrow enough to produce this warning would shortly become completely thrombosed. With a rich col-

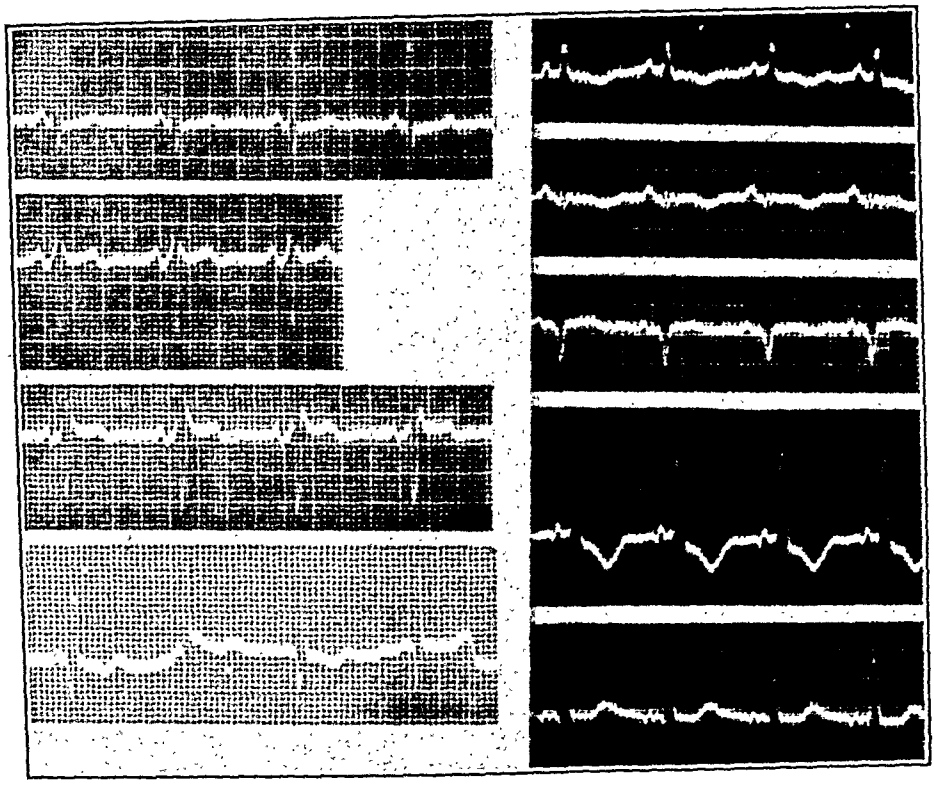

Fig. 1.—Mr. S. (Case 25). First record, April 13, 1936, prior to coronary artery occlusion. Second record, Aug. 31, 1936, two days after coronary artery occlusion. Two Lead IV strips are illustrated in the second record: the first was made with the anterior chest electrode immediately to the left of the sternum in the fifth interspace, the second record, immediately medial to the cardiac apex impulse.

lateral blood supply, acute symptoms and signs of the blockage may never develop. This may account for the rare "silent coronary occlusion" seen at autopsy.

CASE REPORTS

To illustrate the type of cases summarized in Table I and which will be discussed later, the histories and findings of two of the twenty-nine cases reviewed, are outlined:

CASE 25.—Mr. S., aged sixty-five years, first developed squeezing central substernal pain radiating into the left arm on strenuous exertion, i.e., hill climbing, two years

prior to the present illness. This pain gradually increased in severity, duration, and ease of onset over a period of four months until he would have a paroxysm radiating into his left upper arm on walking one block on level ground.

His activity was then restricted to short walks, and he was troubled by pain on such effort only after a moderately large meal. This state remained fairly constant, and with rest ordered after meals and small frequent feedings, he was maintained almost free of pain attacks.

For two weeks prior to admission to the hospital he complained of sudden recurrence of mild attacks of pain of similar distribution, on the effort of walking 30 to 50 feet in his home. These lasted only a minute or less and were relieved by nitroglycerin, gr. 1/200. Three days before admission, while at rest in bed at night, he suddenly developed a similar but severe attack that lasted forty-five minutes

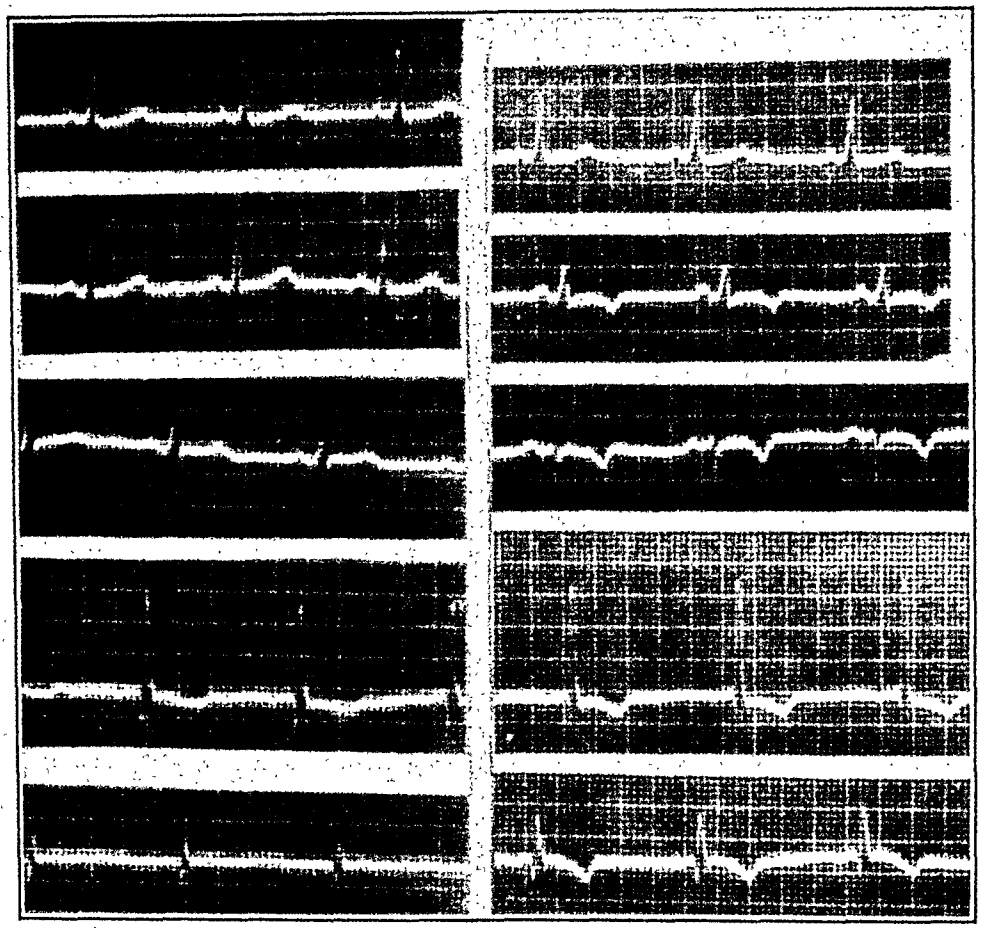

Fig. 2.—Mr. V. (Case 28). First record, Sept. 8, 1936, twenty-four hours prior to the attack during the premonitory phase. Second record, Sept. 14, 1936, five days after onset of acute coronary artery occlusion.

and was only partially relieved by two doses of nitroglycerin. He was kept at complete rest but the next day had four paroxysms of milder nature lasting from two to five minutes, and the succeeding day had absolutely no pain. At 11:00 P.M. the night before admission he developed a violent crushing central substernal pain that was not relieved by nitroglycerin and persisted for sixteen hours with varying intensity until relieved by subcutaneous morphine administration after admission into the hospital. The subsequent course of this patient was characteristic of acute coronary artery occlusion. His blood pressure, which had been 164/108 on the day prior to hospital admission, fell to 94/90 on the day after admission. His leucocyte count two days after admission was 14,850. For four days after entry into the hospital, his temperature was elevated, with a maximum of 38.2° C. registered on the second day after admission. His electrocardiograms taken one month prior to and ten days after admission are shown in Fig. 1.

CASE 28.—Mr. V., aged fifty-one years, a tailor, had been observed, seven years prior to his present illness, in a characteristic attack of acute coronary occlusion. His recovery had been complete, with the exception of lingering but transient albuminuria.

Forty-eight hours before entry to the hospital, he had a severe attack of precordial pain lasting between ten and fifteen minutes, occurring while at work (sedentary). The pain was squeezing in nature and was located across the anterior chest from the second to the fourth ribs, and it did not radiate. There was no pain during the remainder of that day or during the next, even on climbing stairs and walking fairly rapidly.

On the morning of admission he awoke at 7:00 A.M. with a mild sense of precordial distress which decreased after he had dressed himself, but did not entirely clear. When he had reached his tailor shop, the pain suddenly became violent, and he was sent to the hospital. The pain lasted about forty-five minutes, but on arrival at the hospital it had cleared completely. He had no fever, leucocytosis or further pain for forty-eight hours following. His erythrocyte sedimentation rate was three and one-half hours for 18 mm. (technic of Linzenmeier) on the day of admission, and his electrocardiogram was not strikingly abnormal (Fig. 2). Forty-eight hours after admission, while at complete rest in bed, he developed severe precordial pain of similar nature and distribution as before. The pain persisted for ten hours, requiring three doses of morphine sulphate, gr. ¼, administered subcutaneously, to control it.

His course for the next week was marked by a febrile temperature range, a definite leucocytosis of 18,000, a gradual shortening of the sedimentation rate to 35 minutes for 18 mm. on the fifth day after the prolonged pain attack (Rabinowitz and his coworkers,[12] Wood[13]) and on the seventh day, definite changes of the Q_3-T_3 type in the electrocardiogram (Parkinson and Bedford[14]).

OBSERVATIONS AND DISCUSSION

Table I summarizes certain features of twenty-nine cases presenting what we believe to be evidence of impending coronary artery occlusion. As will be seen from this table, these cases were distributed, with regard to age and the particular coronary artery branches involved, in about the same frequency as noted in the reported summaries of other authors. The diagnosis of the location of the block in the coronary arterial system was made in four cases by autopsy, and otherwise presumptively from the electrocardiogram.

Thirteen of the twenty-nine cases were observed in the Mount Zion Hospital during a period when, in this same hospital, fourteen other cases of acute coronary artery occlusion not presenting recognized premonitory pain were diagnosed. The percentile incidence of the thirteen cases with premonitory pain, in the total hospital series of twenty-seven cases of acute coronary occlusion, was 48.1 per cent; thus approximately half of all the cases had premonitory attacks of pain.

In the twenty-nine cases reviewed in this paper (Table I), long-standing angina pectoris was scarcely more common than it was in the twenty-seven cases of coronary occlusion studied at the Mount Zion Hospital. In the former series the percentile frequency of prolonged anginal attacks was 44.8 per cent; in the latter series, 48.1 per

cent. These percentages vary little from those given in other statistics on this subject; Conner and Holt[4] found a 38 per cent incidence of angina pectoris in their series of cases of acute coronary artery occlusion. In the patients in our series (Table I) presenting a history of angina pectoris, the average duration was thirteen and one-half months, the longest being four years.

The character of the premonitory attack of precordial pain observed in those patients who had had angina pectoris previously rarely differed from their former pain either in its nature—i.e., squeezing, crushing, etc.—or in radiation. However, there were at least two cases presenting a definite change in the nature and radiation of the pain. The effect of nitroglycerin on the premonitory attack was definitely transient, with failure of complete relief even on repeated doses although opportunity to observe this effect did not arise frequently.

As summarized from column 8 of Table I, the duration of the warning attack varied from 2 minutes to 2 hours, averaging 63 minutes in individuals without a history of angina pectoris; and from 15 minutes to 14 hours, averaging 2 hours and 40 minutes in patients with that history. However, in the whole series of 29, there were only 7 patients who had pain of less than 20 minutes' duration. Of these, three were individuals who had had progressively severe anginal attacks occurring after shorter interludes and with decreasing amount of effort, but who had not had pain when at rest. In this series no premonitory attacks occurred during sleep, and strenuous exertion occasionally preceded the pain. The attacks generally subsided suddenly and spontaneously without the use of opiates.

Two patients (Cases 16 and 23), aged forty-five and fifty-one years, both males, had precordial pain which sometimes did and sometimes did not occur on effort. Onset of the pain occurred three weeks and five weeks, respectively, prior to the prolonged spontaneous attack that is indicated in the table as the characteristic premonitory symptom of occlusion of the artery. Such cases of inconstant pain, especially when accompanied by normal electrocardiograms, present serious diagnostic problems. Perhaps this clinical picture should be recognized as an equally important precursor to coronary thrombosis as single prolonged spontaneous attacks of pain. The influence of absolute bed rest on prognosis will be mentioned later, but is interesting to consider in respect to these two cases. Patient 16 was allowed to attend to his ordinary business affairs, and Patient 23 was put to bed. However, each died within a few hours after the development of the actual arterial occlusion.

The interval between the premonitory attacks and the major attacks of patients in the entire series, varied between 1 day and 21 days; and

TABLE I

ANALYSIS OF 29 CASES PRESENTING THE PREMONITORY SYNDROME OF ACUTE CORONARY ARTERY OCCLUSION

CASE NO.	AGE	SEX	BEFORE PREMONITORY ATTACK			INTERVAL BETWEEN PREM. AND ACTUAL OCCLUSION	APPROXIMATE DURATION OF PREMONITORY ATTACK	CONDITION PREMONITORY BEFORE OCCLUSION	ELECTROCARDIOGRAMS	OUTCOME
			NO ANGINA	PROGRESSIVE ANGINA	ANGINA PECTORIS DURATION					
1	62	M	-	-	6 mo.	2 wk.	3 hr.	Asymptomatic	After occlusion: Inversion T_1 and T_2.	Alive
2	45	M	+	-	-	3 wk.	20 min.	Asymptomatic	After occlusion: A-V block; complete left bundle-branch block.	Dead (L. ant. desc. art. occluded)
3	60	F	+	-	-	3 days	Vomited once ± 10 min.	Slight dyspnea	After occlusion: Left bundle-branch block.	Dead (L. ant. desc. art. occluded)
4	63	M	+	-	-	4 days	Burning in chest ± 15 min.	Asymptomatic	After occlusion: Q_1-T with inverted T_3 (anterior lesion).	Alive
5	48	M	+	-	-	2 wk.	1½ hr.	Asymptomatic	After occlusion: Depressed S-T_1 and S-T_3; absent Q_4.	Dead (no autopsy)
6	38	M	-	-	3 yr.	3 days	14 hr.	Asymptomatic	After occlusion: Fusion S-T_1, S-T_2 and S-T_3.	Alive
7	58	M	+	-	-	3 days	2 hr.	Asymptomatic	After occlusion: Q_1-T type.	Alive
8	59	M	-	-	1 yr.	1 wk.	10 min.	10 min. anginal attacks	After occlusion: S-T_2, S-T_3 fused.	Alive
9	71	M	+	-	-	2 days	Not known	Asymptomatic	After occlusion: Auricular fibrillation; flat T_1, T_2 and T_3; absent Q_4.	Alive
10	65	M	-	-	3 mo.	6 days	15 min.	15 min. anginal attacks	After occlusion: Absent Q_4; slurred R_4.	Alive
11	38	F	+	-	-	1½ days	2 min.	Asymptomatic	After occlusion: Elevated S-T_1, S-T_2 and S-T_3.	Alive
12	59	M	-	2 yr. on exertion	-	1 day	Angina at rest ± 15 min.	Angina 1+ 15 min. at rest.	After occlusion: Fused S-T all leads.	Dead (no autopsy)
13	60	F	-	-	4 mo.	2 wk.	Not known	Slight angina	After occlusion: i-v conduction defect; S-T fused in all leads. Absent Q_4.	Alive

TABLE I—CONT'D

14	53	M	-	1½ mo. with effort	-	Progressed gradually	20 min. angina at rest	Increased angina	Before premon.: Slurred R_2 and R_3; deep Q_3; T_4 slightly shallow. After premon.: No significant change.	Alive
15	69	M	-	4 wk. with effort	-	Progressed gradually	10 min. angina at rest	Increased angina	After occlusion: Left bundle-branch block.	Alive
16	45	M	-	-	3 wk.	1 wk.	½ hr.	Angina at rest	Before occlusion after premonitory: within normal limits—left axis dev. Died after occlusion. No electrocardiogram.	Dead (no autopsy)
17	64	F	-	-	4 yr.	1 wk.	5 hr.	Asymptomatic	Before premon. attack: Deep S_2, inverted T_3. After premon. attack: No significant change.	Dead (no autopsy)
18	58	M	+	-	-	4 days	20 min.	Asymptomatic	After occlusion: Left bundle-branch block.	Alive
19	63	M	+	-	-	1 wk.	2 hr.	Asymptomatic	After occlusion: Sl. inverted T-waves; S-T_1 elevated.	Alive
20	55	M	-	4 mo.	-	Progressed gradually	30 sec. more often than before	Anginal attacks as before	After occlusion: Elevated S-T intervals.	Alive
21	54	M	+	-	-	2 days	½ hr.	Asymptomatic	No electrocardiogram.	Dead (L. and R. occ.)
22	45	M	+	-	-	2 wk.	½ hr.	Recurrent angina ½ hr.	18 mo. before premon.: Deep S_2; diphasic T_4. After premon.: No significant change except in T_2 and T_4. After occlusion: Inverted T_1 and T_2; depressed T_4.	Alive
23	51	M	-	-	5 wk.	4 days	1 hr.	Asymptomatic	Before premon.: Prominent Q_1 and Q_2. High S-T_2; Q_4 present. Inverted T_4. After premon.: No change. After occlusion: No record.	Dead

TABLE I—CONT'D

CASE NO.	AGE	SEX	BEFORE PREMONITORY ATTACK			INTERVAL BETWEEN PREM. AND ACTUAL OCCLUSION	APPROXIMATE DURATION OF PREMONITORY ATTACK	CONDITION PREMONITORY BEFORE OCCLUSION	ELECTROCARDIOGRAMS	OUTCOME
			NO ANGINA	PROGRESSIVE ANGINA	ANGINA PECTORIS DURATION					
24	53	F	+	-	-	5 days	1½ hr.	Pulmonary edema after premon.; well after	After occlusion: Left axis deviation; T_1 flat; deep S_2.	Alive
25	65	M	-	-	2 yr.	1 day	1 hr.	Asymptomatic	Before premon.: Left axis deviation; $S\text{-}T_2$ and $S\text{-}T_3$ slightly elevated; T_1 flat. After occlusion: Slurred R_1 and R_4; absent Q_4; inverted T_2.	Alive
26	39	M	+	-	-	10 days	1 hr.	Anginal pain at rest 1 hr.	After premon.: Left bundle-branch block; T_1 inverted; T_4 upright. After occlusion: As above 2 wk.; T_1 isoelectric 2 mo.	Alive
27	65	F	+	-	-	2½ wk.	1 hr.	Asymptomatic	Before premon.: Left axis dev.; inverted T_2; diphasic T_4. After occlusion: Left bundle-branch block; deep Q_3.	Dead
28	51	M	+	-	-	2 days	40 min.	Asymptomatic	After premon.: S-T slightly depressed in Lead I and elevated in Lead III. After occlusion: Inverted T_2; absent Q_4; T_4 inverted.	Alive
29	54	M	+	-	-	2 wk.	20 min.	Asymptomatic	After occlusion: Left axis dev.; inverted T_1; low Q_{1a}; slurred R_1.	Dead (R. & L. ant. lesion)

averaged 7.1 days. During this period, of 16 patients who had not had previous anginal pain, only 2 had recurrent minor attacks. Of the remaining 14 patients, 2 had dyspnea, and the others were entirely asymptomatic. Most of these individuals not only were free from pain and dyspnea, but felt so nearly normal that it was difficult to enforce bed rest upon them. They were afebrile and had no changes in blood pressure. Such an individual was Patient 21, a fifty-four-year-old male, who had an attack of severe precordial pain lasting half an hour during an evening, and then returned to his heavy physical labor of pushing wheelbarrow loads of sand in road repair work. For the succeeding two days he did his work without distress in any form.

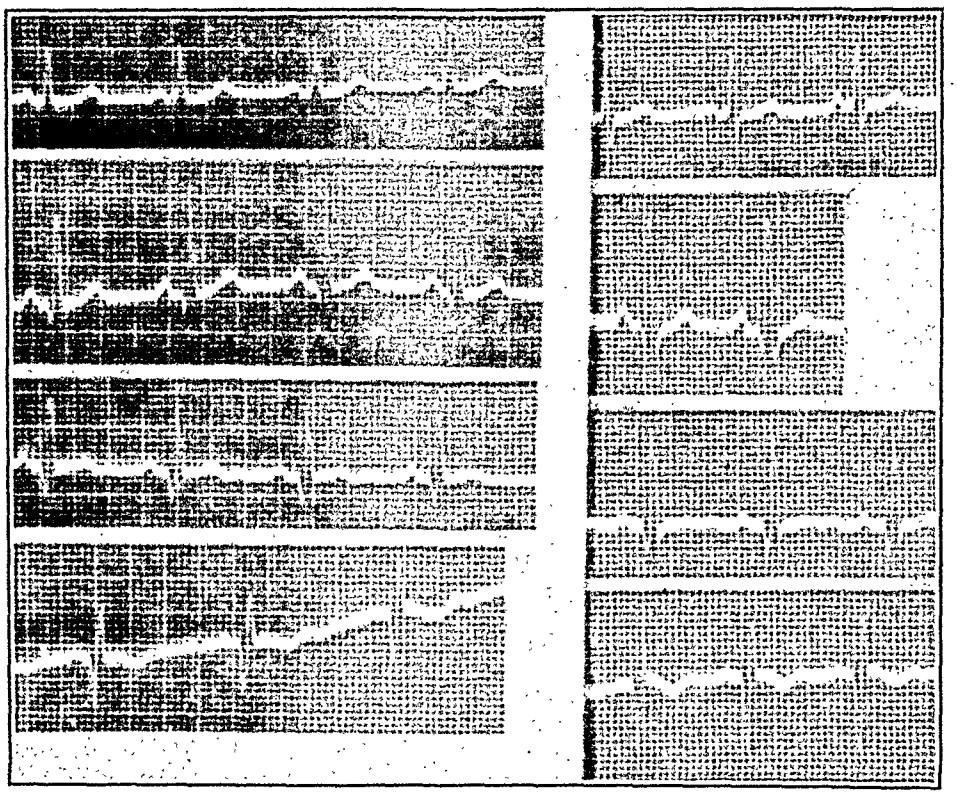

Fig. 3.—Mr. S. C. (Case 14). First record Feb. 13, 1936, ten days prior to premonitory pain of acute coronary artery occlusion. Second record, Feb. 24, 1936, one and one-half days after the premonitory pain but prior to the actual acute coronary artery occlusion. See legend of Fig. 1 for explanation of Leads IV *A* and IV *B*.

On the second night he experienced the pain and had the objective evidences of acute coronary occlusion, which proved fatal within forty-eight hours.

Patients 16 and 23 have been discussed previously relative to recurrent pain occurring prior to their fatal attacks.

The electrocardiograms taken were chiefly notable in that they offered no demonstrable assistance in making a diagnosis of impending thrombosis. Eight patients had electrocardiographic records taken in the interval between the premonitory and the final attacks; and of these, five had had previous records. In the tracings of these five

patients, no significant change was found after the heralding attack (Fig. 3). Of the records of the remaining three cases, one was normal; and one was not of diagnostic consequence because a coronary artery occlusion had occurred two years previously. Patient 26 presented the only instance of possible electrocardiographic changes prior to the occlusive attack. No previous record had been taken because this man was apparently well, and yet his electrocardiogram exhibited evidence of a left bundle-branch block (by recent terminology) when he was in the hospital during the premonitory period. The record changed very little during the two weeks after the occlusive attack but then gradually altered toward normal with less slurring of the QRS and isoelectric elevation of the inverted T_1. Such electrocardiographic alteration suggests that coronary artery changes had recently produced the original left bundle-branch block although, as stated, there is no positive evidence of the existence of this lesion prior to the origin of any cardiac symptoms.

As would be expected, the electrocardiograms of all patients having records taken after their occlusive attacks showed characteristic pathological changes.

Without taking into account histories of previous coronary occlusion, there was found to be a fatality of 34.5 per cent in the patients with the premonitory syndrome in our whole series of twenty-nine cases, as contrasted with a fatality of 50 per cent in the patients of the Mount Zion Hospital series who did not present the preocclusive picture. These figures are considerably higher than those presented by Conner and Holt,[4] who observed a mortality of 16.2 per cent in first attacks, and Master, Jaffe and Dack,[15] in whose series a mortality of 14 per cent for all attacks was found. Our small series includes all cases without relation to the number of attacks and the mortality corresponds more nearly with that of Levine's earlier group[16] in which there was a mortality of 53 per cent. The difference in fatality in the two groups mentioned here may be partially accounted for by the difficulty in obtaining a history of premonitory pain in those patients who were very ill when first observed, and in whom therefore the fatality rate obviously would be very high. Further explanation of the relatively lower mortality of patients with the warning syndrome is that when more gradual occlusion occurs, there is better opportunity for an effective collateral circulation to be established. Most observers of this entity have commented on the particularly grave outlook for the patient when severe shock suddenly develops early in the course of clinical arterial occlusion and on the more favorable prognosis of those patients in whom symptoms and signs develop more slowly. The preliminary stage described herein may well occur, however, only in

patients who under any circumstances would have a favorable outlook, either because small arterial branches are involved or for other reasons which are not known.

Only seven patients were kept in bed after the premonitory attack, and the fatality rate of this group was 29 per cent (two cases). This figure approximates the general fatality rate of the entire group, 34.5 per cent, and only study of a larger series of cases will answer the question as to whether bed rest may increase the chances of survival in such cases, when promptly diagnosed.

The diagnosis of the premonitory syndrome is made difficult because certain patients seem to present some of the characteristics mentioned previously but fail to develop the typical signs of a coronary artery occlusion within a period of weeks afterward. In patients with progressive angina pectoris, the attacks of pain may occur spontaneously and last for even an hour, with only transient relief from nitrite drug administration. In the event that these patients do not develop definitely the signs of coronary occlusion, one may predicate that either a silent small arterial block occurred or that the symptoms were really of no special significance.

In those individuals who have never had anginal pain, a severe attack of such pain may occur spontaneously without serious sequel. We have recently observed six such patients who were placed at complete rest, and within one to three weeks their attacks subsided and failed to recur after gradual convalescence. Whether this type of case represents an impending occlusion which was forestalled and in which collateral arterial supply was permitted to develop or whether it represents well-controlled ordinary angina pectoris is impossible to state.

SUMMARY AND CONCLUSIONS

Twenty-nine cases are presented exhibiting attacks of precordial pain of prolonged duration, which seem to represent a precursor phenomenon of characteristic acute coronary artery occlusion.

The nature of these attacks is discussed in relation to duration, distribution of pain, interval between the initial attack and the occlusion, association with previous history of angina pectoris, and eventual mortality.

The electrocardiograms in eight cases and the erythrocyte sedimentation rate in a single instance gave no indication of an active cardiac lesion or of the impending arterial occlusion.

The possible diagnostic importance of the impending occlusion with particular regard to outcome when complete bed rest is enforced was considered, but no conclusion was reached.

NOTE.—Since this paper was written, the work by Feil, mentioned previously as a personal communication, has been published (Preliminary Pain in Coronary Thrombosis, Am. J. M. Sc. 193: 42, 1937).

The publication of this work calls for certain brief comments. Feil estimated that 50 per cent of all cases of coronary thrombosis present preliminary pain without physical signs or other symptoms and this estimate is in close agreement with our figure. He states that the pain varied in duration from twelve hours to four weeks in the fifteen cases presented, but it is assumed that what is meant by duration was the interval between the first preliminary pain and the final complete occlusion. He comments on the spontaneity of the pain and the failure of nitrites to influence it, which factors we also have noted, but he fails to state the unusually long duration of the majority of individual attacks. He states that the electrocardiogram during the premonitory period may be normal or unchanged from records taken before the current illness. However, the records of three out of the five patients so studied exhibited abnormal forms or changes chiefly in the height and contour of the T-waves. We found only one instance of alteration of the electrocardiogram which probably took place during the premonitory period.

No comment is made by Feil on the existence of a difference in this pain in character or distribution from that of earlier attacks of true angina pectoris as was infrequently observed by us.

REFERENCES

1. Herrick, James B.: Clinical Features of Sudden Obstruction of the Coronary Arteries, J. A. M. A. 59: 2015, 1912.
2. Dock, Geo.: Some Notes on the Coronary Arteries, M. & S. Reporter 75: 1, 1896.
3. Levine, Samuel A.: Clinical Heart Disease, Philadelphia, 1936, W. B. Saunders Company, p. 137.
4. Conner, Lewis A., and Holt, Evelyn: The Subsequent Course and Prognosis in Coronary Thrombosis, Am. Heart J. 5: 705, 1930.
5. Parkinson, John, and Bedford, D. E.: Cardiac Infarction and Coronary Thrombosis, Lancet 1: 4, 1928.
6. Feil, H. S.: Personal communication to the authors.
7. Dunphy, V. E.: Abdominal Pain of Vascular Origin, Am. J. M. Sc. 192: 109, 1936.
8. Benson, Robert L.: The Present Status of Coronary Arterial Disease, Arch. Path. & Lab. Med. 2: 876, 1926.
9. Beck, Claude S., and Ticky, V. L.: The Production of a Collateral Circulation to the Heart, Am. Heart J. 10: 849, 1935.
10. Wearn, J. T., Mettier, S. R., Klumpp, T. G., and Zschiesche, L. G.: Nature of Vascular Communications Between the Coronary Arteries and the Chambers of the Heart, Am. Heart J. 9: 143, 1933.
11. Gross, L., and Kugel, M. A.: Arterial Blood Vascular Distribution to the Left and Right Ventricles of the Human Heart, Am. Heart J. 9: 165, 1933.
12. Rabinowitz, M. A., Shookoff, C., and Douglas, A. H.: Red Cell Sedimentation Time in Coronary Occlusion, Am. Heart J. 7: 52, 1931.
13. Wood, Paul: Erythrocyte Sedimentation Rate in Diseases of the Heart, Quart. J. Med. 5: (New ser. No. 17) 1, 1936.
14. Parkinson, John, and Bedford, D. E.: Successive Changes in the Electrocardiogram After Coronary Infarction, Heart 14: 195, 1928.
15. Master, A. M., Jaffe, H. L., Dack, S.: Multiple Attacks of Coronary Artery Thrombosis, Am. Heart J. 12: 244, 1936.
16. Levine, Samuel A.: Coronary Thrombosis—Its Various Clinical Features, Medicine 8: 245, 1929.

THE WORK OF THE HYPERTHYROID HEART*

C. H. McDonald, D.Sc.
Little Rock, Ark.

THE majority of workers seem in agreement that no structural changes are characteristic of the "thyroid heart" as a result of the hyperthyroidism itself. Such changes as histiocyte infiltration, parenchymatous and fatty degeneration, fibrosis, and fraying of bundles which are commonly found in the heart of the hyperthyroid subject either accompany or follow other conditions also present which are damaging to the vascular system. Whatever increase in size occurs appears to be due to dilatation rather than to true hypertrophy.

While it appears to be generally admitted that whatever changes take place in the heart as the result of hyperthyroidism are functional, no clear-cut picture of these functional changes has yet been presented. A tachycardia is produced and, unlike that due to most agencies, is maintained long after isolation of the heart. It continues after removal of the sino-auricular node;[1] after crushing of the bundle of His;[1] and after complete denervation of the heart;[2] it appears in tissue cultures of embryonic chick hearts before any nervous elements are present, if the culture is subjected to the action of thyroxine.[3] Evidently the action of thyroid substance or of thyroxine is directly on cardiac musculature rather than upon nervous structures.

Evidence relative to the utilization of oxygen by the hyperthyroid heart is conflicting. Dock and Lewis,[4] using a heart-lung technique, conclude that the increased oxygen consumption of the hyperthyroid heart may be accounted for purely upon the basis of increased mass. McEachern,[5] by direct volumetric measurements upon the isolated hearts of thyroxinized guinea pigs, under conditions in which no appreciable work was done, found that such auricles utilized more oxygen than did the auricles of normal guinea pigs. McDonald[6] found that the hearts of terrapins heavily dosed with thyroid extract consumed more oxygen per gram of tissue than did the hearts of non-treated terrapins. These hearts appeared to pump a greater volume and to do more work than did the normal hearts, but no measurements were attempted to discover whether the hyperthyroid hearts really did more work. Clark and White[7] state that, provided no work is done, the rate of beat does not significantly influence the oxygen consumption of the auricles of cold-blooded animals.

*From the Department of Physiology and Pharmacology, The University of Arkansas School of Medicine, Little Rock.

Research Paper No. 510, Journal Series, University of Arkansas.

While increased work is generally admitted for the hyperthyroid heart, apparently little work has been done in demonstrating the actuality of such increase; no report of an attempt to analyze such increased work or to correlate it with oxygen consumption has been found. The study recorded below was planned in an effort to find whether increased oxygen consumption by the thyroid heart was represented in increased work. Because of the low glycogen content described for hyperthyroid hearts[8] and the somewhat uncertain state of our knowledge concerning the source of energy for the heart in pathological states,[9] I wished to observe the behavior of the hyperthyroid heart when subjected to a sudden strain such as is imposed upon it through treatment with epinephrine.

The method selected permitted me to measure rate of beat, amplitude, and volume output from which data I computed the work done by the heart under the various conditions imposed; it permitted me to measure the oxygen consumption and to correlate this function with the work done so far as correlation exists. The terrapin was the experimental animal used. Since animals in a previous study had shown evidence of extreme hyperthyroidism (grave muscular weakness, diarrhea, and emaciation) the treatment with thyroid substance was lessened in an effort to secure a degree of hyperthyroidism comparable to that commonly encountered clinically.

METHODS AND APPARATUS

Desiccated thyroid substance in suspension was administered by means of a stomach tube in dosage of 0.5 mg. per gram of body weight every eight days for a period of four weeks. The percentage of deaths among these animals did not differ from that of the control group. A definite tachycardia was noted in every case when the terrapins were opened.

The apparatus employed, similar to that previously described,[6] measured the oxygen required to resaturate at atmospheric pressure a previously saturated fluid after its passage through the isolated heart. Briefly, it consisted of: (a) A perfusion reservoir, a 150 c.c. Marriott flask which communicated by means of pure gum tubing and a glass "T" tube with a cannula inserted into the right precaval vein of the isolated heart (all other veins being ligated). The right-angle arm of this "T" tube was open and directed upward as a trap for any air bubbles that might enter the circulating system; (b) an oxygen chamber, a 50 c.c. Exax buret, cut off at 0.0 calibration and inverted into a 2.5 by 20 cm. sidearm test tube. The perfusion medium was pumped by the heart through a cannula inserted into the brachiocephalic artery (all other divisions of the aorta being ligated) through an "S" trap with a liquid seal into the oxygen chamber where it trickled through an atmosphere of pure oxygen down a thermometer suspended in the chamber; (c) an overflow reservoir identical with (a) from which the solution was pumped back to the perfusion reservoir by means of a 100 c.c. Luer type syringe and a 3-way glass stopcock. Each reservoir and the sidearm test tube were open to atmospheric pressure; (d) a light heart lever arranged to write upon a kymograph drum. This lever was weighted with 5 grams and attached by a thread and fine wire hook to the heart suspended by the two cannulas between the perfusion reservoir and the oxygen

chamber. In all records a downward excursion occurs during systole. During an experimental period the surface of the heart was kept constantly moistened by spraying or dropping Ringer's solution upon it.

The circulating medium in all experiments consisted of:

	PER CENT
Sodium chloride	0.650
Potassium chloride	0.014
Calcium chloride	0.012
Sodium bicarbonate	0.020
Sodium dihydrogen phosphate	0.001

This fluid was oxygenated by bubbling oxygen through it freely for a period of one hour. Because of marked changes which often occur in the response of the hyperthyroid terrapin heart some twenty to thirty minutes after administration of the drug, observations were made for a preliminary fifteen minutes to establish a normal for the particular heart, after which epinephrine-HCl was added to the perfusing fluid to the concentration of 1:500,000 and a second fifteen-minute observation made.

Oxygen consumption was read from the buret and reduced to standard conditions for temperature and barometric pressure; the volume pumped by the heart during each fifteen-minute period was measured with the calibrated syringe used to return the fluid to the perfusion reservoir; rate, amplitude, and variations in tone were obtained from the graphic records. On the expiration of an experimental period the heart was incised in all its chambers, blotted dry, and weighed. From the data secured was computed: the oxygen consumed per minute per gram of tissue; the work done in gm.-cm. per minute per gram of tissue; and, following the administration of epinephrine, the percentage increase in rate, amplitude, work done, and oxygen consumption. These data are set forth in averages in Tables I and II.

TABLE I

A COMPARISON OF THE BEHAVIOR OF THE NORMAL AND THE HYPERTHYROID HEART WITH RESPECT TO RATE, AMPLITUDE, WORK DONE, AND OXYGEN CONSUMPTION EXPRESSED IN AVERAGES

TYPE	RATE PER MIN.	AMPLITUDE CM.	WORK DONE PER GRAM TISSUE GM./CM./MIN.	OXYGEN CONSUMPTION PER GRAM TISSUE C.C./MIN.
Normal	31.1	2.2	140	0.026
Hyperthyroid	38.0	2.4	196	0.039

TABLE II

A COMPARISON OF THE RESPONSE TO EPINEPHRINE OF NORMAL AND HYPERTHYROID HEARTS WITH RESPECT TO RATE, AMPLITUDE, WORK DONE, AND OXYGEN CONSUMPTION EXPRESSED AS AVERAGES

TYPE	INITIAL	AFTER EPIN.	INITIAL	AFTER EPIN.
	Rate per minute		*Amplitude in cm.*	
Normal	31.1	42.8	2.2	2.65
Hyperthyroid	38.0	49.8	2.4	3.10
	Work done per gram tissue gm./cm./min.		*Oxygen consumption per gram tissue. cm./min.*	
Normal	140	233.4	0.026	0.033
Hyperthyroid	196	293.4	0.039	0.051

The volume pumped by each heart was noted but such wide variations appeared under comparable conditions that averages were rather meaningless. These variations

were due apparently to differences in auricular filling. In most hyperthyroid hearts ejection was quick and forcible; relaxation in many cases was prompt and auricular filling good. As a result of these facts increased rate was attended by a greater minute volume. In many cases, however, regardless of the nature of contraction, relaxation was much slower and the increased rate prevented good auricular filling between beats. In such cases the minute volume often fell markedly. We established our perfusion time at fifteen minutes because a majority of our hyperthyroid hearts showed a greatly decreased amplitude of beat some twenty to twenty-five minutes after treatment with epinephrine; unlike the normal hearts they do not respond to an increase in the concentration of epinephrine.

DISCUSSION

From this study the following salient facts seem to me worthy of consideration:

1. There is increased work per gram of tissue per minute done by the hyperthyroid heart. A definite tachycardia and a definite increase in amplitude combine to accomplish more work.

2. There is a greater consumption of oxygen per gram of tissue by the hyperthyroid heart as compared with the normal heart. A fair parallelism exists between the work done and the oxygen consumed by the two hearts. Whatever relationships may be shown finally to exist between oxygen consumption and work done by cardiac tissue, hearts exhibiting the degree of hyperthyroidism described for these animals succeed, under the conditions of excision and perfusion with Ringer's solution, in working close to the dynamic energy level of normal hearts under the same conditions. This work does not indicate the reason for the slightly greater oxygen consumption by the hyperthyroid hearts. Starling and Visscher[10] have shown that oxygen consumption by normal hearts is directly proportional to diastolic volume. Whether the hyperthyroid hearts used in this study underwent greater dilatation than did the normal hearts, or whether they possessed greater resting metabolism, or whether some unknown defect of contraction and recovery therefrom accounts for the slightly greater oxygen consumption are matters for further study.

3. Following the administration of epinephrine the normal and the hyperthyroid hearts show an average increase in rate of the same number of beats. The rhythmic apparatus of the heart is apparently uninjured through the action of the thyroid substance.

4. Both types of hearts show an increase in amplitude of contraction as a response to epinephrine. The increase shown by the hyperthyroid hearts is notably greater than that shown by the normal hearts. Furthermore, the increase in amplitude is achieved in a different manner by the two hearts. Normal hearts show greater systolic shortening and less diastolic relaxation. The lessened diastolic relaxation is in the

nature of increased tonus. The hyperthyroid hearts, however, show greater diastolic relaxation as well as greater systolic shortening as is demonstrated in Fig. 1. Approximately the same increase in work measured in gram per centimeter per minute per gram of tissue is accomplished by the normal and the hyperthyroid hearts in response to epinephrine.

5. The hyperthyroid hearts are able to maintain the additional work induced by epinephrine for a much shorter time than are the normal hearts. In from twenty to twenty-five minutes there is generally a marked falling off in amplitude without much, if any, change in rate. Further treatment with epinephrine does not call out renewed activity in these hearts as it does in the normal hearts.

6. The fair parallelism which existed between oxygen consumption and work done when we compare the hyperthyroid and the normal hearts under the conditions of excision and perfusion with a Ringer's



Fig. 1.—Showing the increased diastolic relaxation in the hyperthyroid heart following the administration of epinephrine. The upstroke occurs during diastole and the downstroke during systole.

solution disappears following the administration of epinephrine. The hyperthyroid heart uses much more oxygen and accomplishes, only for a little while, essentially the same additional work after which its work falls off rapidly. This observation is in harmony with that of Starling and Visscher[10] to the effect that the heart pushed to the level of its reserve utilized far more oxygen than when working at its normal level. Furthermore, the oxygen consumption which is unrepresented in work done under the conditions of our experiment is directly proportional to the degree of the hyperthyroidism present.

SUMMARY

In brief, may I say, this analysis of the work of the hyperthyroid heart indicates, I believe, that exhaustion of the cardiac reserve is the functional damage done to such hearts by hyperthyroidism and that the dilatation, far from being compensatory, is distinctly nonphysiological.

REFERENCES

1. Yater, W. M.: The Tachycardia, Time Factor, Survival Period, and Seat of Action of Thyroxine in the Perfused Heart of Thyroxinized Rabbits, Am. J. Physiol. 98: 338, 1931.
2. McIntyre, M.: The Effects of Thyroid Feeding on the Heart Rate in Normal Dogs and in Dogs With Completely Denervated Hearts, Am. J. Physiol. 99: 261, 1931.
3. Markowitz, C., and Yater, W. M.: Response of Explanted Cardiac Muscle to Thyroxine, Am. J. Physiol. 100: 152, 1932.
4. Dock, W., and Lewis, J. K.: The Effect of Thyroid Feeding on the Oxygen Consumption of the Heart and of Other Tissues, Am. J. Physiol. 74: 401, 1932.
5. McEachern, D.: Direct Measurements of the Oxygen Consumption of Isolated, Beating Auricles From Normal and Thyrotoxic Guinea Pigs, Bull. Johns Hopkins Hosp. 50: 287, 1932.
6. McDonald, C. H., et al.: Response of the Hyperthyroid Heart to Epinephrine, Am. J. Physiol. 112: 227, 1935.
7. Clark, A. J., and White, R. C.: The Oxygen Consumption of the Frog's Heart, Am. J. Physiol. 66: 185, 1928.
8. Andrus, E. C.: The Heart in Hyperthyroidism, Am. Heart J. 8: 66, 1932.
9. Cruickshank, E. W. H.: Cardiac Metabolism, Physiol. Rev. 16: 597, 1936.
10. Starling, E. H., and Visscher, M. B.: The Regulation of the Energy Output of the Heart, Am. J. Physiol. 62: 243, 1927.

THE DYNAMIC EFFECT OF ACUTE EXPERIMENTAL POISONING OF THE HEART WITH DIPHTHERIA TOXIN*

D. B. Witt, M.D., E. Lindner, and L. N. Katz, M.D.†
Chicago, Ill.

AN ASSAY of the evidence in the literature leaves one in doubt as to the mechanism of action of diphtheria toxin on the circulation. There is evidence of peripheral circulatory failure, and there is evidence of cardiac failure, but which is primary is still a matter of controversy. The mere demonstration of a decreased blood volume (Harding[1]) and a drop of arterial blood pressure (Rolly,[2] Romberg and his coworkers[3]) does not preclude a cardiac origin for the diphtheritic circulatory collapse since it is well known that even acute coronary occlusion often leads to secondary circulatory failure. On the other hand, the demonstration of conduction disturbances (Stecher,[4] Marvin,[5] McCulloch,[6] Smith[7]), arrhythmias (Smith,[7] Shookhoff and Taran[8]), abnormalities in the contour of the electrocardiogram (Nathanson,[9] Marvin,[5] McCulloch[6]), and even the presence, post mortem, of degenerative changes in the muscle and interstitial exudations (Karsner,[10] Warthin[11]) does not necessarily mean primary cardiac failure. It is possible that such changes might follow peripheral circulatory failure, although this is not likely. This whole matter is of importance in dealing with the management of diphtheria poisoning because, in addition to specific therapy and the treatment of particular disturbances, the question comes up whether or not to institute supportive treatment for the heart. While the general practice recently has been in this direction, we felt that it might be worth while to investigate the actual dynamic changes following diphtheria poisoning.

The methods available made it necessary to use acute experiments. While, clinically, diphtheria is usually a protracted affair, fulminating acute poisoning does occur, and sudden death is not uncommon. We felt that our study would not only determine whether or not cardiac failure does occur, but would help to decide what relation the loss of cardiac power had to the conduction and rhythm disturbances with which the clinical studies have been primarily concerned. Such an analysis might help to decide, for example, whether or not heart failure, whatever its cause, always goes hand in hand with the electrocardiographic changes.

---

*From the Cardiovascular Department, Michael Reese Hospital, Chicago, Ill.
Presented at a meeting of The American Heart Association held in Kansas City, Mo., on May 12, 1936.
†Aided by the A. D. Nast Fund for Cardiac Research.

METHOD

The study was based upon infusing a highly concentrated diphtheria toxin* (kindly supplied by Eli Lilly & Co. through the courtesy of Dr. K. K. Chen) intravenously over an average period of thirty-one minutes (range twenty-five to ninety minutes) into eighteen dogs anesthetized with morphine and sodium barbital.

The following variables were determined simultaneously in different combinations:

1. Heart rate (from various types of records).
2. Mean arterial pressure (from smoked drum records).
3. Venous pressure in the superior vena cava (with saline manometer).
4. Diastolic volume and stroke volume of the ventricles (from calibrated smoked drum records).
5. Systolic, diastolic and pulse pressures (and the contour of the pressure curves) in the right and left ventricles and in the aorta and pulmonary artery (with calibrated Wiggers' manometers). These records were recorded in pairs of various combinations.

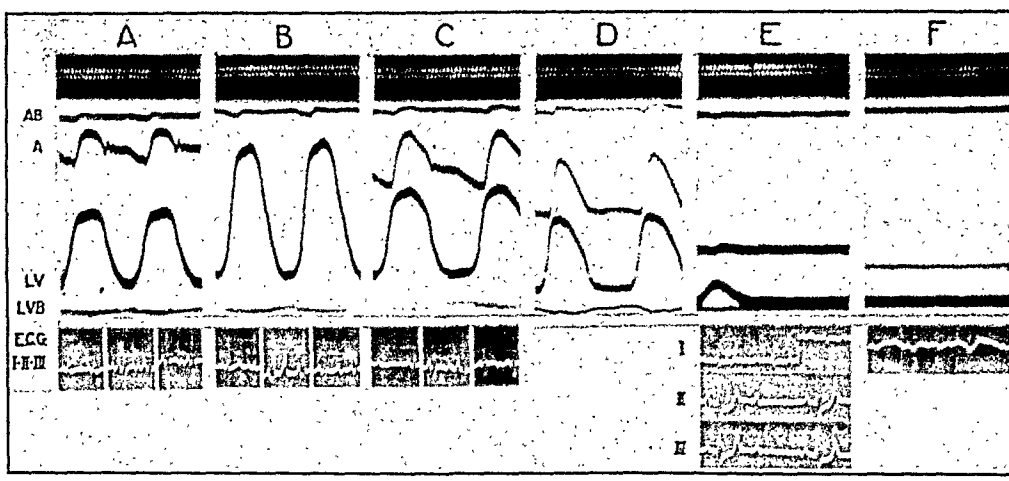

Fig. 1.—Series of curves to show the effect of diphtheria toxin on the aortic and left ventricular pressure curves and electrocardiogram. Time at top; each double vibration equal to 1/50 sec. *A* is aortic pressure curve; *LV* is left ventricular pressure curve. *AB* and *LVB* are base lines for the above. *ECG* is the three-lead limb electrocardiogram (time in 0.04 and 0.2 sec.). Segment *A* is control. *B*, taken during infusion of 50 c.c. of toxin. *C*, shortly after infusion. *D*, 5 minutes after *B*, during third injection of 50 c.c. of toxin. *E*, 6 minutes after *D*, 5 minutes after another 50 c.c. of toxin. *F* is ventricular fibrillation occurring soon after *E*. Discussion in text.

6. Changes in rhythm, in conduction in the heart, and in the contour of the standard limb lead electrocardiograms.
7. Changes in heart muscle tone from the ratio of diastolic size of the ventricles to their diastolic pressures (according to the principle recently outlined by Johnson and Katz[12]).
8. Asynchronism in the phase relations of the two ventricles (from their simultaneous optical pressure curves).
9. Minute volume of flow, calculated as the product of one-half the stroke volume and the heart rate.
10. The nature of the terminal fibrillation of the ventricles by means of high speed cinematography of the exposed heart which when projected gave slow motion. (In this, we were assisted by Mr. E. Sigman of this department.)

*L+ = 0.055 to 0.07 and an equivalent M.L.D. = 1/1200 to 1/1400.

DISCUSSION OF RESULTS

These changes were determined, tabulated, summarized, and then correlated. The chief findings are given briefly below. Typical records are shown in Figs. 1 and 2, and several consecutive frames of one cinematograph, in Fig. 3. The electrocardiographic findings are correlated in Table I.

The heart rate slowed in all experiments. This was due to a sinus bradycardia, usually with a sinus arrhythmia (Fig. 2, segment *E*),

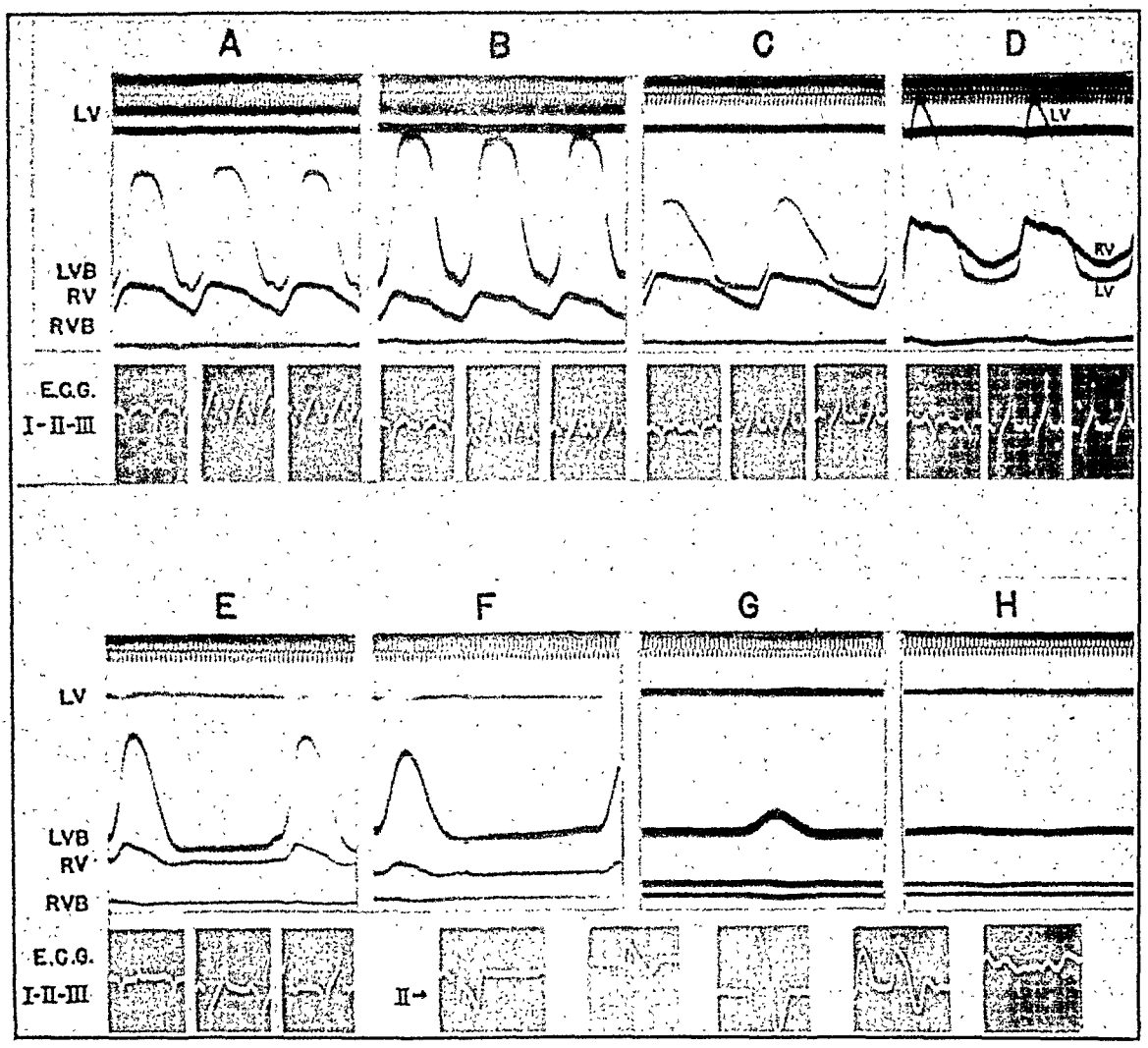

Fig. 2.—Series of curves to show the effect of diphtheria toxin on the left and right ventricular pressure curves. *RV* is right ventricular pressure curve and *RVB* its base line. Other conventions as in Fig. 1. Segment *A* is control. *B*, taken shortly after start of continuous injection of 50 c.c. of toxin. *C*, 5 minutes after *B*, during injection of second dose of toxin (50 c.c.). *D*, 4 minutes after *C*, during infusion of fifth 50 c.c. of toxin. *E*, 6 minutes after *D* and 1 minute after giving of ninth dose of 50 c.c. of toxin. *F*, 5 minutes after *E*, during injection of tenth 50 c.c. of toxin. *G*, 7 minutes after *F*, 5 minutes after eleventh 50 c.c. of toxin. *H* is terminal fibrillation occurring soon after *G*. Discussion in text.

or to an A-V block, either incomplete (Fig. 1, segment *E*) or complete. Apparently, the toxin acted both on the sinus node and on the A-V conducting system. In some instances the sinus slowing was extreme, and even the idioventricular rhythm was slower than usual. Our experiments do not reveal to what extent these changes might have

TABLE I

CORRELATION OF ELECTROCARDIOGRAPHIC DEVIATIONS FOLLOWING DIPHTHERIA TOXIN INJECTION

	EFFECT ON ELECTRO-CARDIO-GRAM	CAUSED DEPRES-SION OF S-T SEGMENT	CAUSED INVER-SION OF T-WAVE	CAUSED INTRAVEN-TRICULAR BLOCK	CAUSED PROLONGA-TION OF P-R INTERVAL	CAUSED HIGHER DEGREES OF A-V BLOCK	CAUSED APPEAR-ANCE OF PRE-MATURE SYSTOLES
1	N						+
2	P	+	+*	+	+	+	
3	P		+	+		+	
4	P			+			
5	P	+	+	+			
6	N						+
7	P		+*	+		+	+
8	P	+		+		+	
9	P	+		+	+	+	+
10	N						
11	P	+	+	+	+		
12	P		+		+	+	
13	N						
14	P	+	+*				
15	P	+	+*			+	
16	P			+		+	

*Toward end, T became positive again.
N, none.
P, produced a change.

been due to a vagus action, but there is no doubt that they were due to a large extent to a direct action on the cardiac conducting system, since intraventricular block occurred with a tremendous slowing of the invasion of the ventricles, at times the entire QRST complex becoming a smooth diphasic curve (Fig. 2, segment *G*). In five out of eighteen experiments, a preliminary acceleration was observed.

Premature systoles of various origins were frequently present, and it was not unusual to find them arising from multiple foci in a single experiment. Paroxysmal tachycardia, more often ventricular than auricular, also occurred, and "asystole" eventually resulted from standstill of the heart or, more frequently, from ventricular fibrillation. In most instances, this fibrillation was peculiar and different from the tumultuous fragmentary contractions seen in the ordinary type of fibrillation. As Fig. 3 shows, the heart was quiescent for the most part with ripples sweeping slowly over the ventricles. Probably this peculiar type of impulse-spread results from the markedly depressed conduction rate existing at this time. We have seen similar fibrillation on occasion following potassium or digitalis poisoning.

Usually before the conduction disturbances appeared, the contour of all the waves of the electrocardiogram changed (Figs. 1 and 2). Our results support the viewpoint expressed by Nathanson[9] that changes in electrocardiographic contour, when present, are an early sign of

diphtheritic myocardial poisoning. In four instances, however, terminal fibrillation of the ventricles occurred without any preceding alterations in the electrocardiogram.

The arterial blood pressure fell in both the systemic and pulmonary vessels, but this fall could not be related in time to any of the foregoing changes. At times a temporary preliminary rise in these pressures was seen, but was always associated with an increased minute volume output of the heart. It is impossible to determine from this study what the causal relationship is. The fall in pressure was due to vasodilatation since it occurred in three instances in spite of the

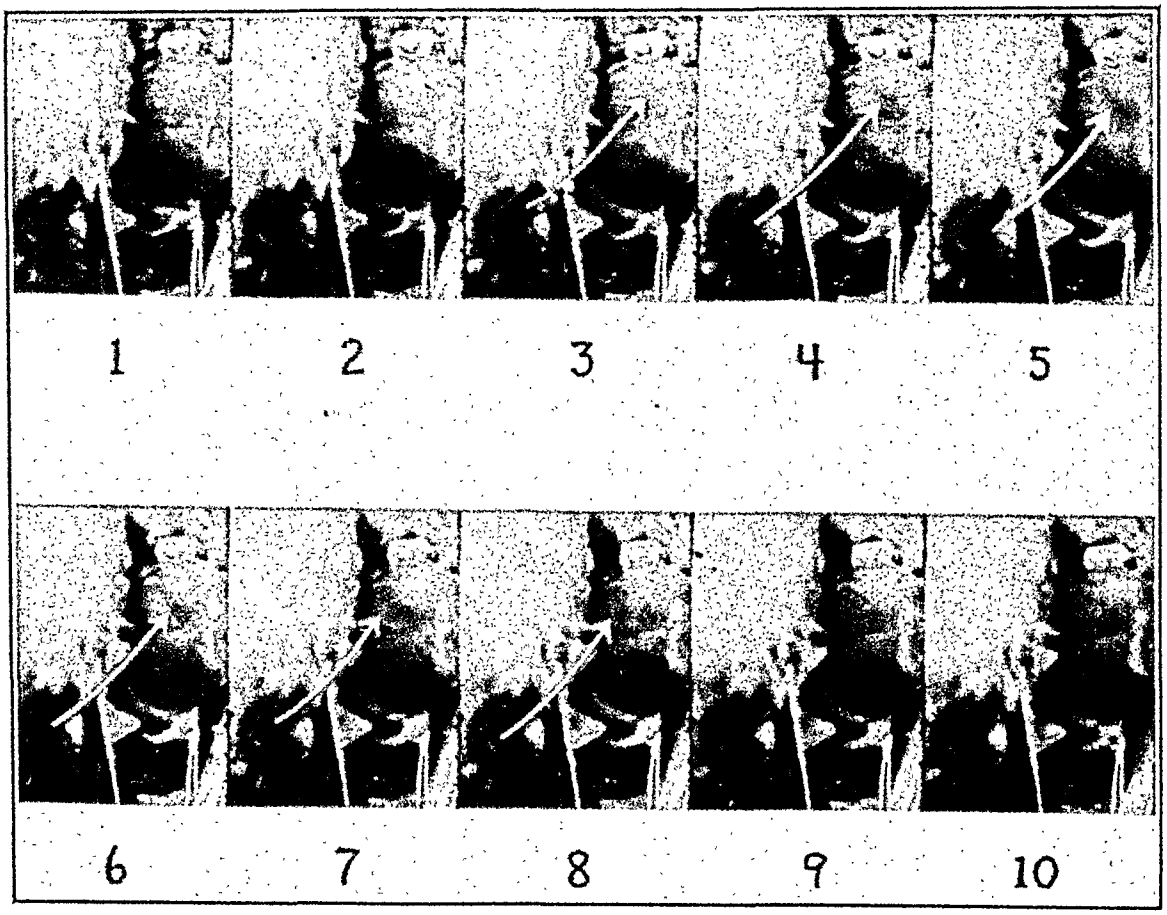

Fig. 3.—Ten successive frames from a cinematograph taken during typical terminal ventricular fibrillation which follows diphtheria poisoning. The white arrows indicate the rise and spread of one of the peculiar waves discussed in the text. Each frame represents 1/16 sec.

plethora and increased minute volume flow, and on four occasions preceded the decrease in minute volume output. In three other experiments the drop in pressure was contributed to by the decreased output of the heart. It follows that these vascular effects must be due in part at least to the direct action of the toxin.

The minute volume discharge of the heart increased at first, primarily as a result of the infusion, but later it declined despite the continued infusion. This may have been due, at times, partly to the poorer coronary blood flow which the drop in blood pressure could cause, but probably also to the depressing action of the toxin on the

contractile power of the heart. This is borne out by the fact that in three experiments, failure type of pressure curves were obtained with blood pressures at control levels and definitely above shock level. This occurred without any heart rate or electrocardiographic changes.

The stroke volume of the ventricles increased at first because of the infusion and later because of the slowing in heart rate; eventually the decrease in the contractile power of the heart overcame both the other factors so that the stroke volume declined. It is interesting to note that this decline in stroke volume occurred when the heart was distended and the initial pressure (the pressure existing before systole began) in its two ventricular chambers was still high—indicating real instances of overdistention, that is, distention that was detrimental to the heart and not beneficial as is true of the range in which Starling's law operates. This dilatation of the heart was not due to a plethora effect of the infusion since the quantities of fluid injected were too small, in four experiments being as little as 10 to 40 c.c. Distention was the direct result of the loss of power of the heart, permitting the accumulation of a systolic remainder in successive beats.

The pulse pressure in the aorta and pulmonary artery followed the changes in stroke volume except so far (a) as the dynamic effects were different in detail in the two ventricles in particular experiments and (b) as modified by changes in the distensibility of the arterial trees from time to time in the course of the experiment. The contour of these curves (Fig. 1) showed evidence, in the early stages, of the type of curves seen in a hyperdynamic heart working against high resistance and in the later stage, the smooth curves of the hypodynamic heart working against low resistance (Fig. 1, segment *D* and especially *E*). The evidence from these curves, therefore, jibes with the volume curve analysis. Further evidence for this view is found in the fact that despite the infusion, the distention of the heart, and the slowing, the duration of the ejection period of the ventricles, as well as their systoles, shortened in three out of six experiments measured. This is seen when the power of the heart is failing, as one of us has shown previously.[13, 14]

Similar changes in amplitude, contour, and span of the pressure curve were seen in the ventricular pressure recordings (Fig. 2). Here it can be seen that the infusion (with its resulting distention of the heart) and the slowing (with the greater resulting filling time) at first tend to make the ventricles more powerful parallel with the elevation in the diastolic pressure levels (segments *A*, *B* and *D*). Later, however, despite these influences, the curves became smaller in height, shorter in duration, and smooth. This failure type of curve was associated in Fig. 2, and in the other experiment having records of

both ventricles, with a drop in the diastolic levels. (In Fig. 2 compare segment *D* with *E*, *F*, and *G* and segment *A* with *C*.) This occurred in both chambers while the ventricles continued to increase in volume as apparent to the eye. This can only mean a loss of tone. Decreases in diastolic pressure occurred in a single ventricle in other experiments but no record was obtained of both ventricles except in the above two experiments. These observations are in accord with those of Johnson and Katz[12] that loss of tone occurs in the heart whose power is failing. It is further evidence of loss of power and is partly responsible for establishing the vicious cycle of overdistention.

The late drop in diastolic pressure within the right ventricle may account for the secondary decline in venous pressure seen toward the end of three of these experiments, although the venous pressure drop may also be due to a decrease in the return of blood to the heart because of stasis in the periphery.

Examination of our curves showed that events in the two sides of the heart were not always in phase; at times they went in opposite directions (segments *A* and *B* of Fig. 2). This phenomenon we have previously discussed (Brams and Katz[15] and Johnson and Katz[12]); it indicates the independence between the right and left hearts. We have found again, as previously stated (Katz[16]), that the start of systole and ejection is not synchronous in the two ventricles. Further, we noted that in one experiment the changes in this asynchrony of systole were decidedly smaller than the change found in intraventricular conduction time. This observation dealing with asynchrony is opposed to the view that intraventricular block is confined to one or the other ventricle and favors the contrary view that the block is often equally severe in both ventricles.

There is no doubt that the peripheral actions of the diphtheria toxin contributed to the failure of the heart in these experiments just as failure of the heart contributed to the peripheral vasodilatation and stasis. Nor is there any doubt that the action of the diphtheria toxin on conduction contributed to the heart failure. Nevertheless, we found evidence that the action of the toxin on the power of the heart often preceded the other cardiac actions and the peripheral effects. This is well shown by the curves in Fig. 2 (segments *B*, *C*, *D*, *E* and *F*).

It is of practical clinical importance to realize that diphtheria toxin acts directly on the contractile power of the heart and its tone since serious damage to the heart may be present without significant modification of the electrocardiogram or of blood pressure. Histological examination of these hearts failed to reveal any changes other than cloudy swelling. (We are indebted to Dr. O. Saphir of the Department of Pathology for this interpretation.)

SUMMARY

The acute effect upon the cardiac dynamics of injecting diphtheria toxin was studied in dogs. The study was based on records of mean arterial and venous blood pressures and records of the volume and pressure changes of the heart. Electrocardiograms were obtained also. The pressure curves of the various heart chambers (i.e., the two ventricles, the pulmonary artery, and the aorta) were recorded with Wiggers' manometers on a photokymograph. The volume and mean pressure curves were obtained on a smoked drum.

It was found that the diphtheria toxin produced a sinus slowing of the heart and, later, various types of A-V and intraventricular block. Extrasystoles of various types and paroxysmal tachycardia also were present, and eventually the heart went into a peculiar type of ventricular fibrillation which we have described. A vasodilatation in both the systemic and pulmonary circuits also resulted. Heart failure was caused by these disturbances in conduction and rhythm, and by the decreased coronary blood supply following systemic vasodilatation. There was definite evidence, however, that diphtheria toxin poisoned the heart in such a way that myocardial failure with its typical abbreviated and less powerful contraction occurred sometimes before these other changes came into operation. There was evidence also of a loss of tone in the ventricles toward the end. It is of practical importance to realize that diphtheria toxin acts directly on the contractile power and tone of the heart since serious damage to the heart may be present or develop quickly before significant modification of the electrocardiogram or of blood pressure is present.

REFERENCES

1. Harding, M. E.: Circulatory Failure in Diphtheria, London, 1920, University of London Press.
2. Rolly, F.: Arch. f. exper. Path. u. Pharmakol. 42: 283, 1899.
3. Romberg, E., Pässler, H., Bruhns, C., and Müller, W.: Deutsches Arch. f. klin. Med. 64: 652, 1899.
4. Stecher, R. M.: Am. Heart J. 4: 545 and 715, 1929.
5. Marvin, H. M.: Am. J. Dis. Child. 29: 433, 1925.
6. McCulloch, H.: Am. J. Dis. Child. 20: 89, 1920.
7. Smith, S.: J. A. M. A. 77: 765, 1921.
8. Shookhoff, C., and Taran, L. M.: Am. J. Dis. Child. 42: 811, 1931.
9. Nathanson, M. H.: Arch. Int. Med. 42: 23, 1928.
10. Karsner, H. T.: Human Pathology, Philadelphia and London, 1935, J. B. Lippincott Co.
11. Warthin, A. S.: J. Infect. Dis. 35: 32, 1924.
12. Johnson, V., and Katz, L. N.: Am. J. Physiol. 118: 26, 1937.
13. Katz, L. N., and Feil, H. S.: Arch. Int. Med. 32: 672, 1923.
14. Katz, L. N., and Feil, H. S.: Arch. Int. Med. 33: 321, 1924.
15. Brams, W. A., and Katz, L. N.: Am. J. Physiol. 98: 556, 1931.
16. Katz, L. N.: Am. J. Physiol. 72: 655, 1925.

MIDAXILLARY LEADS OF THE ELECTROCARDIOGRAM IN MYOCARDIAL INFARCTION*†

MERRITT B. WHITTEN, M.D.
DALLAS, TEXAS

THE midaxillary or lateral thoracic leads of the electrocardiogram, in some cases, appear to show earlier and to a more marked degree than the limb leads, the electrocardiographic changes characteristic of infarction in the part of the left ventricle supplied by the left coronary artery, and there is a suggestion that these changes may sometimes last longer than they do in the limb leads. On this account this work is presented, the writer hoping that others with greater facilities at their command may be able to report further clinical, and especially further post-mortem, data on this subject.

A proper understanding of this subject necessitates a review of the development of our present knowledge of the electrocardiographic localization of myocardial infarction, for it is on the previous work on this subject that the greater part of the present study is based.

Barnes and the writer[2] showed that changes in the RS-T segment and T-wave in the limb leads of the electrocardiogram often give indication of the part of the heart involved in myocardial infarction. We showed that, for the most part, infarction is generally confined to the left ventricle. Our work indicated that infarction of the part of the left ventricle usually supplied by the left coronary artery (that is, the anterior portion of the left ventricle and the anterior part of interventricular septum which are generally supplied by the anterior descending branch of the left coronary artery and sometimes the left, or obtuse, margin and left part of the posterior basal portion of the left ventricle where supplied usually by the circumflex branch of the left coronary artery) generally caused the so-called T_1 changes to occur in the electrocardiogram. In this paper, in order to avoid repetition, this type of infarction will be called a T_1 type of infarct. We found these T_1 changes in the electrocardiogram to consist of an early elevation (elevation not always seen) of the RS-T segment in Lead I alone or Leads I and II combined. This was followed by an inversion of the T and often by a depression of the RS-T below the isoelectric line in Lead I alone or Leads I and II combined. We also observed that similar changes in the RS-T and T, except that they occurred in Leads II and III, the so-called T_3 type of electrocardiogram, generally were associated with infarction in the posterior part of the interven-

*From the Department of Medicine, Baylor University.

†A preliminary report of this work was presented at the annual meeting of the Texas State Heart Association, Houston, Texas, May 25, 1936.

tricular septum and the adjacent portion of the posterior basal part of the left ventricle which usually is supplied by the right coronary artery. In this paper, for the sake of brevity, infarction in this location will be called a T_3 infarct.

Our work on localization of myocardial infarction has been confirmed by numerous writers. In addition, it has been added to as a result of the work on the Q-wave by Pardee,[7] Feniehel and Kugell,[3] and Wilson and his associates,[12] so that now it is generally accepted that a large Q_1 may be a part of the picture of the T_1 type of infarction and a large Q_3 may be associated with the T_3 type, with certain other requirements.

It was soon recognized that infarction produced by a left coronary artery lesion was not as readily shown by the electrocardiogram as that usually resulting from a right coronary artery lesion. The T_1 changes made their appearance later and sometimes were not observed at all. Wolferth and Wood[13, 14] called attention to this and introduced the anteroposterior thoracic leads, which they called Leads IV and V. With the use of these new leads they were able earlier to recognize infarction produced in the part of the heart generally supplied by the left coronary artery, and at times they could demonstrate it when it did not register at all in the limb leads. They considered the early findings of this lesion to be a depression of the RS-T_4 and a deep inversion of T_4. Later Q_4 usually disappeared, T_4 became upright and RS-T_4 might become slightly elevated. Changes in Lead V were reported as similar to those in Lead IV. The T_3 type of infarct (usually from a right coronary artery lesion) did not appear to be as well shown in the anteroposterior leads as in the standard limb leads.

Why does not the electrocardiogram register a T_1 type of infarct (left coronary artery lesion) as well as a T_3 type (right coronary artery lesion in most hearts) in the standard limb leads? If we consider the pathway that the electrical current is most likely to follow in the three limb leads one possible explanation suggests itself. In Lead I, with the right arm electrode applied to the right arm and the left arm electrode attached to the left arm, the shortest pathway for the electric current to pass would be from the right arm through the right shoulder region to the left shoulder and left arm. This is entirely above the heart. Wilson,[12] and Wolferth and Wood[13] have stated that the nearer an electrode is to the infarct the more likely it is to register the infarct and, conversely, the farther away it is the more indifferent the electrode becomes. If this be true, then Lead I is more indifferent than Leads II and III, as it is farther away from the left ventricle or even the heart itself. For Lead I to be made more sensitive to T_1 changes it would have to be taken so that the shortest path for the current to travel would run nearer to, or even better, directly through the heart itself. Following out this line of reasoning, the right arm

electrode was placed in the right midaxillary line and the left arm electrode in the left midaxillary line and the left leg electrode was applied to the left leg in its accustomed place. The regulation large metal electrodes were used and the electrodes were applied in such a manner that the long axis of the electrode rested on the midaxillary line (Fig. 1). Three midaxillary leads were taken. The first midaxillary lead (ax_1) was from the right midaxillary line to the left midaxillary line and was taken by setting the electrocardiograph as in taking Lead I of the limb leads. The midaxillary Lead II (ax_2) was taken by setting the electrocardiograph to take Lead II, the current passing from the right midaxillary line to the left leg. The midaxillary Lead III (ax_3) was taken by setting the electrocardiograph for Lead

Fig. 1.—Left lateral view showing the left arm electrode in place in the left midaxillary line. The right arm electrode was similarly placed in the right midaxillary line.

III and the direction of the current was from the left midaxillary line to the left leg. The first tracing using the midaxillary leads was taken Sept. 18, 1934 (Fig. 3).

Although it is natural to suspect that lateral thoracic leads should be investigated following the valuable contributions of Wolferth and Wood[13] on anteroposterior thoracic leads, the writer has found no published record of them. However, on May 12, 1936, Lundy[6] stated to the writer that in some unpublished work he had made 1,000 tracings, using the midaxillary Lead I (Lundy calls this Lead SS, meaning side to side). It is possible that he began his work first. However, his approach to the subject differs from the study here presented. Groedel[4] used a lead in which the right arm electrode was placed on

the right arm and the left arm electrode was placed in the left anterior axillary line at the level of the lower end of the sternum, which he considered to be especially sensitive for the left ventricle. Groedel's lead does appear to be quite sensitive to T_1 electrocardiographic changes, but does not register them quite as markedly as the midaxillary Lead I, as is seen later in this paper. Hyman[5] has been working with various thoracic leads but his work is as yet unpublished.

Since Sept. 18, 1934, the midaxillary leads have been used on more than 600 cases. Of this number there were many normal cases, some of which were studied for control purposes and others in the course of routine examinations. The normal (Fig. 2) for the midaxillary Leads I and II was the same as for the corresponding limb leads except that the voltage was a little greater in the midaxillary leads. In

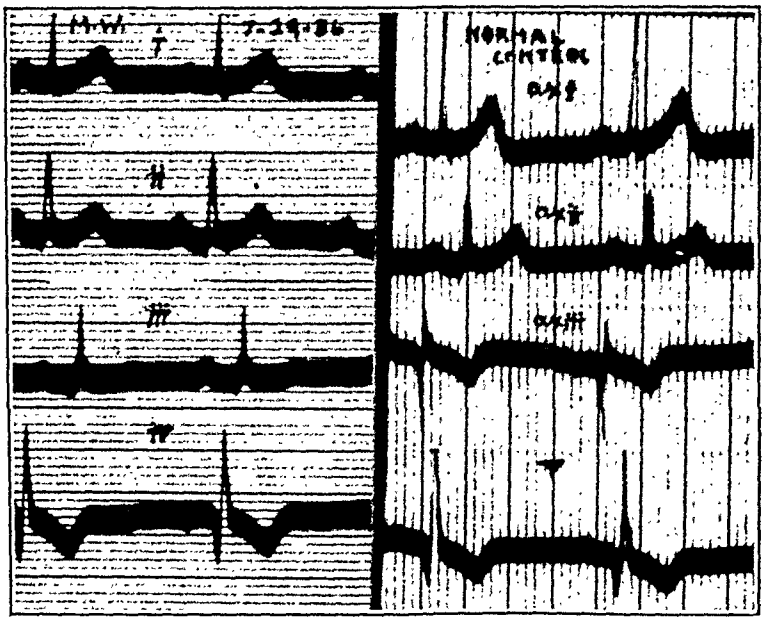

Fig. 2.—A normal control electrocardiogram. The complexes of the midaxillary leads are similar to those of the standard limb leads. Leads one to five are indicated in small Roman numerals, i, ii, iii, iv, and v, in this and the following figures. The midaxillary leads are marked ax_I, ax_{II}, and ax_{III}.

no case was there any inversion of the T-wave or isoelectric T or diphasic T in midaxillary Lead I alone or the combined Leads I and II unless there was definite clinical evidence to account for it. The same applied to abnormalities of the RS-T segment and the Q-wave. On the other hand, whenever the T-wave was inverted in the limb Leads I or I and II it was always found to be inverted in the corresponding midaxillary leads.

Midaxillary leads have been studied in 38 cases with definite history and electrocardiographic findings of myocardial infarction. Cases with bundle-branch block were not included. The three conventional leads and Leads IV and V* also have been taken for comparison. In some

*The anterior electrode was placed just to the left of the sternum and not at the apex for Leads IV and V.

only one tracing has been taken and in others it was possible to obtain serial electrocardiograms. In order to conserve space the history and electrocardiograms of all of these cases will not be presented. However, typical cases will follow to illustrate better the findings in this study.

There were 18 cases in this group with the T_1 type of electrocardiographic changes. Cases 1, 2, and 3 are of that type.

CASE 1.—Mr. D. S. was seventy-nine years old in July, 1933, when he began having anginal attacks. On Sept. 15, 1934, he had a severe acute myocardial infarction with pain lasting twenty hours. Pulmonary edema soon followed. He had another attack of pain Sept. 21, 1934. His death occurred Oct. 18, 1934. There was no post-mortem examination. An electrocardiogram on Sept. 17, 1934, showed a deep Q_1, a high

Fig. 3.

Fig. 4.

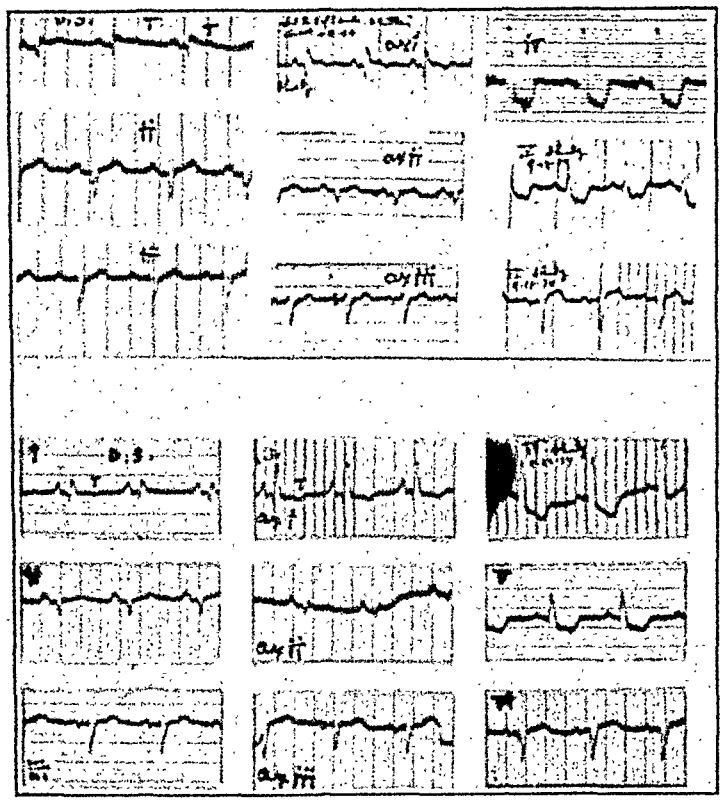

Fig. 3.—Case 1. Electrocardiogram three days after onset of acute myocardial infarction. Elevation of RS-T_1. Depression of RS-T_4 and RS-T_5. Deep Q_1 and midaxillary Q_1. T_1 is positive but the midaxillary T_1 has already become inverted.

Fig. 4.—Case 1. Electrocardiogram seven days after onset of myocardial infarction. T_1 has now become inverted but not as deeply as the midaxillary T_1. Midaxillary T_2 has become flattened.

take-off and definitely elevated RS-T_1, an inverted T_1, a complete absence of Q_4 and Q_5 and a marked depression of RS-T_4 and RS-T_5. On the following day, and just seventy-two hours after the onset of the pain, the first experiment with the midaxillary leads was performed. The tracing at this time was similar to the one of the previous day so far as the conventional leads and the anteroposterior leads were concerned, except that T_1 was not inverted (Fig. 3). In the midaxillary Lead I, Q_1 was greater than the limb Q_1 and midaxillary T_1 was inverted. On Sept. 20, 1934, a tracing was essentially the same except that T_1 of the limb leads had become slightly inverted and in the midaxillary Lead I the T had become more deeply inverted. In the limb leads T_2 was upright but in the midaxillary leads it was lower and somewhat diphasic. The last electrocardiogram, taken on Sept. 22, 1934, showed no further change (Fig. 4). In this case the T_1 type of change had been found to

be a little more marked in the midaxillary Leads I and II than in the corresponding limb leads. Furthermore, it appeared that these changes were a little further advanced in the midaxillary leads, suggesting that the proximity of the path of the lead to the heart had something to do with the form of its waves. It was because

Fig. 5.

Fig. 6.

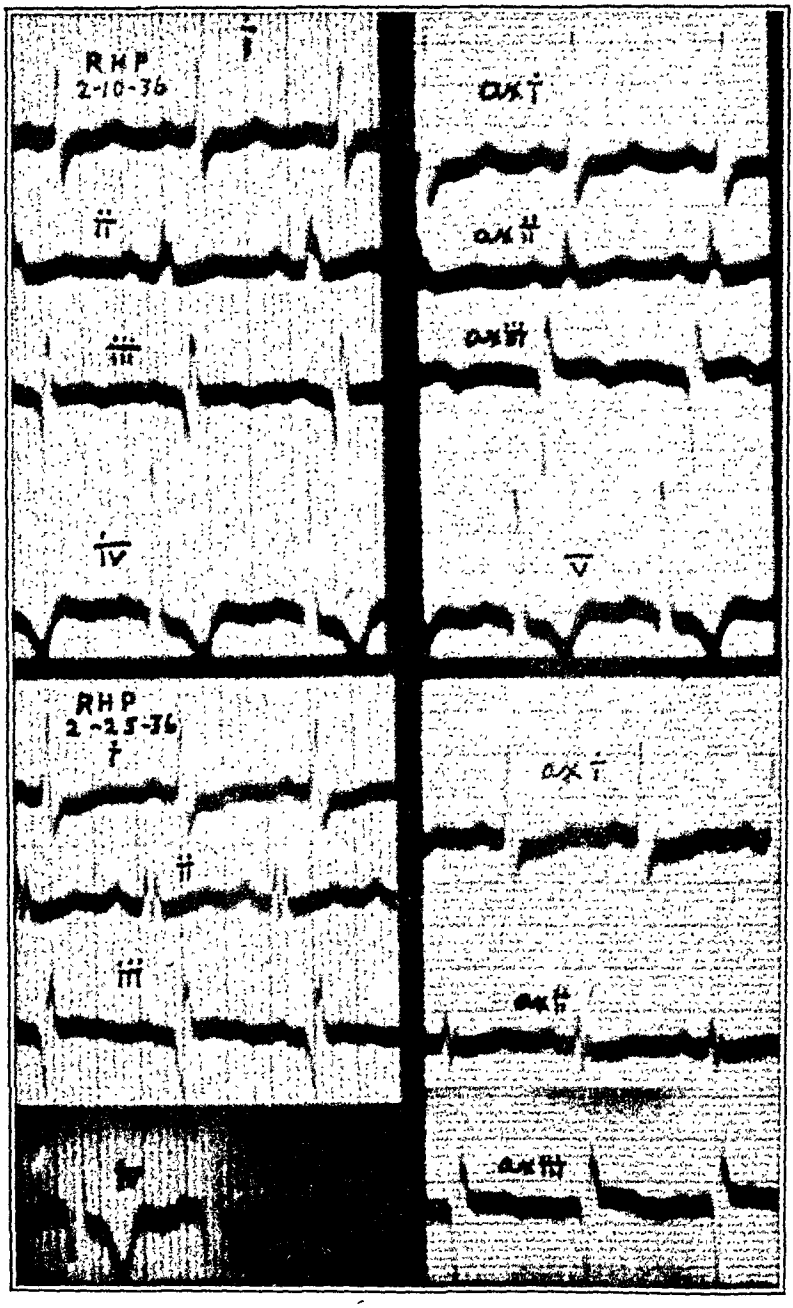

Fig. 5.—Case 2. Electrocardiogram on Feb. 10, 1936. Severe anginal attacks were experienced previous to this electrocardiogram but the acute myocardial infarction came later. The electrocardiogram was similar on Dec. 26, 1935.

Fig. 6.—Case 2. Electrocardiogram Feb. 25, 1936, taken fifteen hours after onset of acute myocardial infarction. The electrocardiogram was similar eight hours later. Note the depressed RS-T segment and diphasic T_1 in the limb and midaxillary leads. Q_1 has become normal.

the T_1 changes in the midaxillary leads seemed further advanced than in the limb leads in this case that additional cases were studied.

CASE 2.—Mr. R. H. P. was forty-eight years of age when first seen Feb. 25, 1931. He weighed 230 pounds. His electrocardiogram was normal at that time and on April 17, 1934. His blood pressure was 128 mm. of mercury systolic and 90 mm. diastolic. In the fall of 1935 when he was rejected for life insurance his blood pressure was 150 mm. of mercury systolic and 110 mm. diastolic. He had had anginal pains for a number of months and on Dec. 25, 1935, he had a severe attack lasting about one hour. The electrocardiogram on the following day was similar to Fig. 5, showing a deep Q_3 in the limb and midaxillary leads and a small Q_1 and Q_2. The QRS_2 was notched in the limb and midaxillary leads. He had another attack Feb. 9, 1936, and on the following day the electrocardiogram showed no further changes. On Feb. 24, 1936, he developed severe substernal pain which lasted twenty-four hours and was not relieved completely by hypodermic administration of morphine or dilaudid. An electrocardiogram taken fifteen hours after the onset of this attack showed a depression of the RS-T_1 and a diphasic T_1 in the limb and midaxillary leads. Lead IV was normal and remained so, as did Lead V in all of the remain-

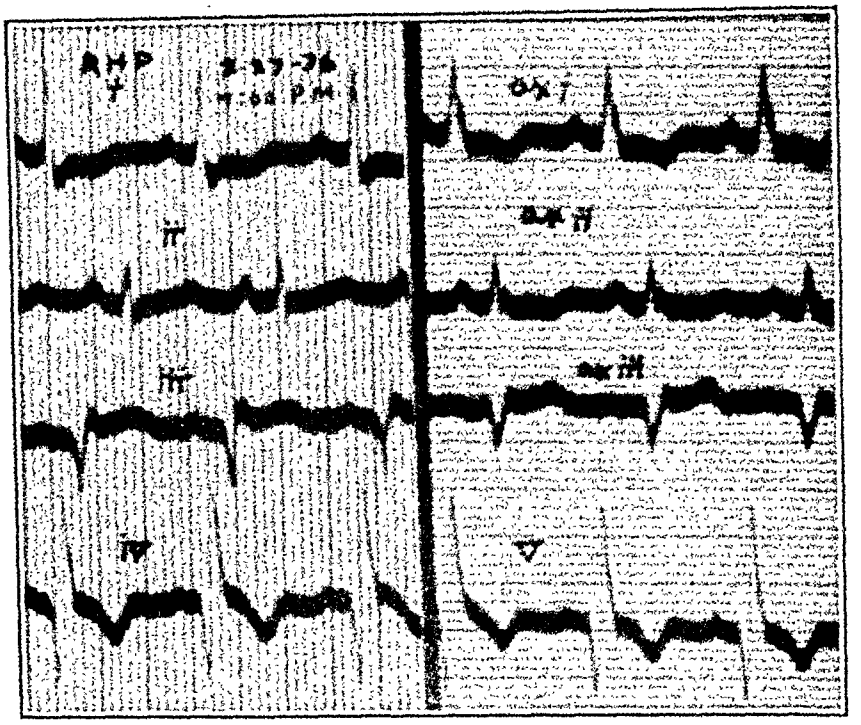

Fig. 7.—Case 2. Electrocardiogram of Feb. 27, 1936, taken three days after onset of infarction of myocardium. T_1 is still diphasic in the limb leads but has become inverted in the midaxillary Lead I and somewhat diphasic in the midaxillary Lead II. Leads IV and V are normal.

ing tracings (Fig. 6). The electrocardiogram was similar twenty-three hours later. Two electrocardiograms taken on Feb. 28, 1936 (Fig. 7), showed no further change in the limb Lead I, but in the midaxillary Lead I the T was definitely inverted. Tracings on March 4 and 5, 1936 (Fig. 8), showed inverted T_1 in both the limb and midaxillary leads. The T_1 inversion and RS-T_1 depression and upward convexity were much greater in the midaxillary Lead I than in the corresponding limb lead. Midaxillary T_2 was diphasic, while the conventional T_2 was upright and unchanged. On March 27, 1936, T_1 was isoelectric, while the midaxillary T_1 was still deeply inverted and the midaxillary T_2 diphasic (Fig. 9). On May 2, 1936, and on June 5, 1936 (Fig. 10), the entire electrocardiogram was normal except that the midaxillary T_1 was diphasic and the RS-T in that lead was slightly depressed. On July 13, 1936, T ax_1 was positive. The only reminder of the accident was a low take-off of the RS-T in Lead I and a still lower take-off in midaxillary Lead I.

The serial electrocardiograms in this case have shown the characteristic electrocardiographic changes following myocardial infarction of the T_1 type to appear earlier, to be more marked, and to last longer in the midaxillary than in the limb leads. In two tracings (Fig. 8)

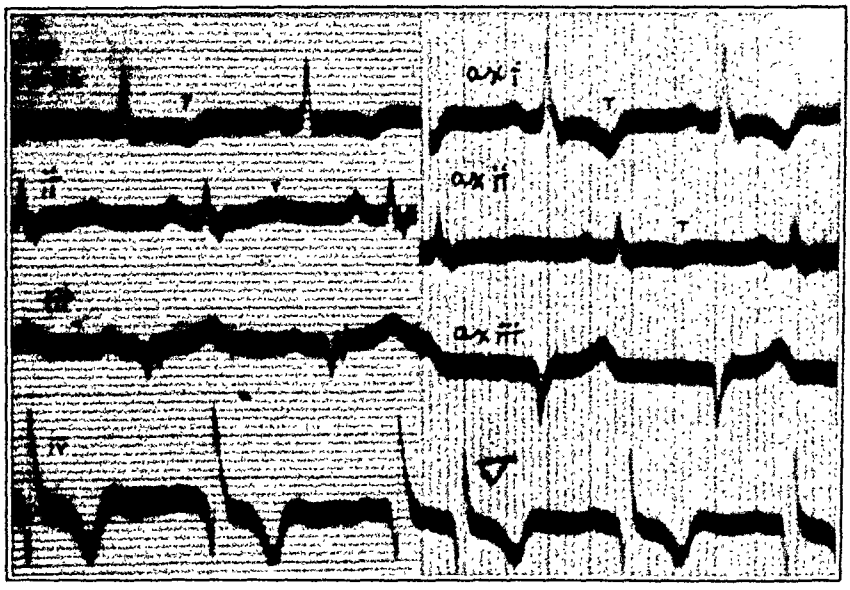

Fig. 8.—Case 2. Electrocardiogram taken March 5, 1936. T_1 is inverted in the limb and midaxillary leads, but the T_1 inversion and upward convexity of the RS-T segment are much greater in the midaxillary lead. T_2 is upright in the limb lead, but diphasic in the corresponding midaxillary lead.

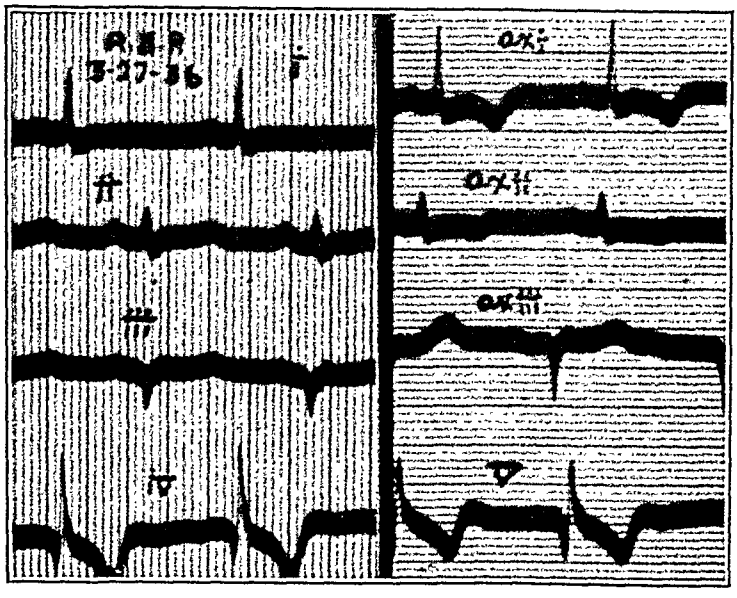

Fig. 9.—Case 2. Electrocardiogram taken March 27, 1936, thirty-one days after onset of myocardial infarction. The limb lead T_1 is now isoelectric, while in the midaxillary leads the T_1 is still deeply inverted and the RS-T_1 still has a definite upward convexity and T_2 is still diphasic.

definite inversion of the limb T_1 did occur to show that this was really a T_1 type of infarct. Leads IV and V of Wolferth and Wood,[13] though abnormal previously, remained normal after the onset of the infarction.

CASE 3.—Mr. I. R. I., aged forty-eight years, was seen in a neighboring city July 27, 1935, and an electrocardiogram was taken at that time. Three days previously he had begun with a typical history and later had the usual laboratory findings of acute myocardial infarction. The electrocardiogram showed a low voltage except

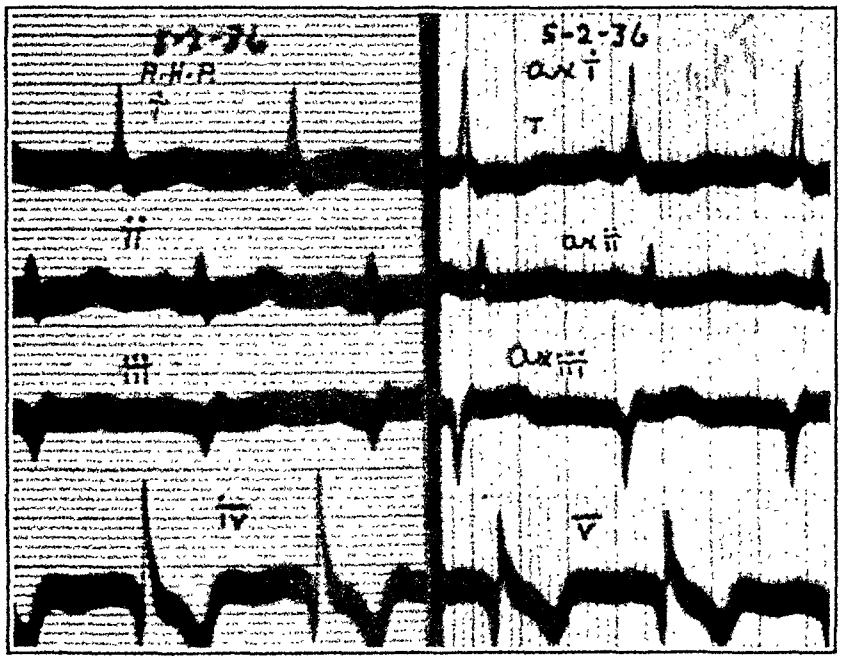

Fig. 10.—Case 2. Electrocardiogram taken on May 2, 1936. The T is now positive in the limb Lead I (i) but is diphasic in the midaxillary Lead I (ax_1) and the RS-T segment is still depressed below the isoelectric line in the latter lead.

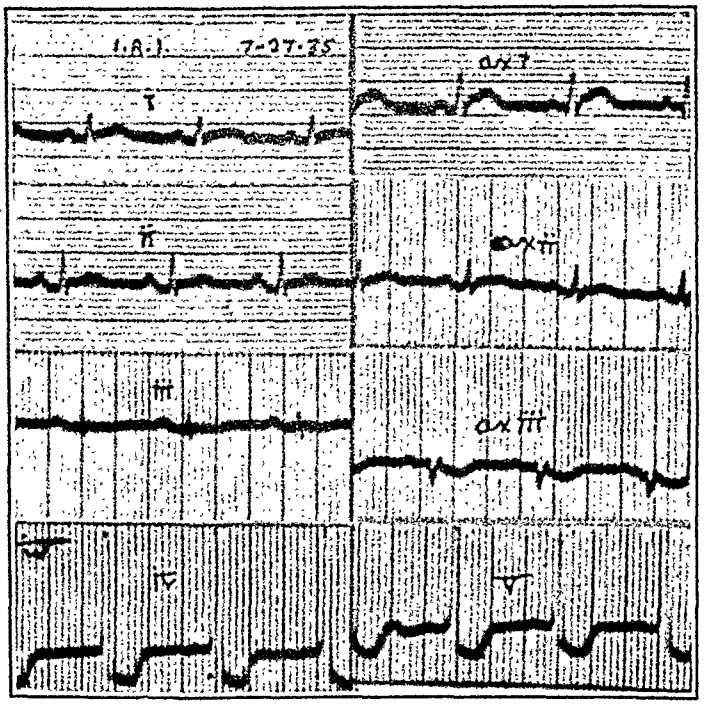

Fig. 11.—Case 3. T_1 type of electrocardiogram three days after onset of myocardial infarction. The elevation of the RS-T shows better in the midaxillary Lead I (ax_1) than in the corresponding limb lead (i). Depressed RS-T_4 and RS-T_6.

in Leads IV and V (Fig. 11). The only evidence of a recent infarction registered in the limb leads was a scarcely recognizable elevation of RS-T_1. The RS-T in the midaxillary Lead I was more definitely elevated and ended in an upright T. The amplitude of the QRS in the midaxillary Lead I was greater than in the correspond-

ing limb lead. Q_1 and Q_2 were absent and RS-T_1 and RS-T_2 were depressed. This is a typical early T_1 type of electrocardiogram with the changes more marked in the midaxillary and the anteroposterior thoracic leads than in the limb leads at the time the tracing was taken.

Besides the 3 cases briefly presented, 15 additional cases of the T_1 type were studied, making a total of 18 in all. Data concerning all 18 cases may be found in Table I. In 15 of these 18 cases the changes in the T-wave were more marked in the midaxillary T_1 than in the limb T_1. In the remaining 3 cases the T-changes were practically equal in the limb and midaxillary leads. In 6 cases it was shown that the T changes had occurred earlier in the midaxillary T_1 than in the limb T_1. In the remaining cases the electrocardiograms were not taken early enough or often enough to see in which the change occurred earliest, the limb or midaxillary leads. In no case was the T_1 change more marked or seen earlier in the limb than in the midaxillary leads. In 2 cases in which it was possible to follow through with serial electrocardiograms the T_1 changes persisted longer in the midaxillary Lead I than in the limb T_1. In no case was the reverse true. Because of persistent electrocardiographic changes, inability to secure serial electrocardiograms, and fatalities, the duration of the persistence of the T abnormality is unknown in most of the cases.

TABLE I

SUMMARY OF T_1 CASES. A COMPARISON OF THE CHANGES IN T_1 AND T_2 IN THE LIMB AND MIDAXILLARY LEADS

CASE	T_1 CHANGES MORE MARKED*	T_1 CHANGES APPEARED EARLIER†	T_1 CHANGES PERSISTED LONGER‡
1	ax_{1-2}§	ax_{1-2}	ax_2
3	ax_1		
2	ax_{1-2}§	ax_{1-2}	ax_{1-2}
4	ax_2		
5	ax_1		
6	ax_1		
7	ax_1	ax_1	
8	ax_1		
9	equal‖		
10	ax_{1-2}	ax_{1-2}	
11	equal		
12	ax_1		equal
13	ax_{1-2}	ax_2	
14	ax_1		ax_1
15	ax_1		
16	ax_1		
17	ax_1	ax_1	
38	ax_1	ax_1	

*Where ax_2 has been omitted it was normal or the changes were equal to those of the limb T_2.

†Where nothing has been recorded the electrocardiogram was not taken early enough to determine if changes appeared earliest in limb or axillary leads.

‡Where nothing has been recorded the patient was not followed long enough to determine if the electrocardiographic changes persisted longer in the midaxillary than in the limb leads.

§Limb T_2 never was abnormal.

‖T_1 changes were transient in both limb and midaxillary leads and quickly disappeared.

Changes in Lead II in this series of T_1 type infarcts were found to be more marked in the midaxillary position than in the limb leads in 5 of 16 cases in which this lead was taken. In 3 of these 5 cases the limb Lead II was normal. The limb Lead II changes in no case were greater than the midaxillary Lead II changes but were equal in 6 of the 16 cases. Lead II changes lasted longer in 2 cases in the midaxillary leads, but in no instance did the limb Lead II changes persist longer than those in the midaxillary Lead II.

The T_1 changes which were observed in the midaxillary Leads I and II in the cases in this group included significant elevation or depression of the RS-T segment, inversion of the T, cove-shaped (coronary) RS-T segments, and Q-waves of increased amplitude. Naturally all of these changes were not necessarily present in any one given case.

There were 14 cases showing a T_3 type of tracing included in this series. A brief description of 2 cases follows.

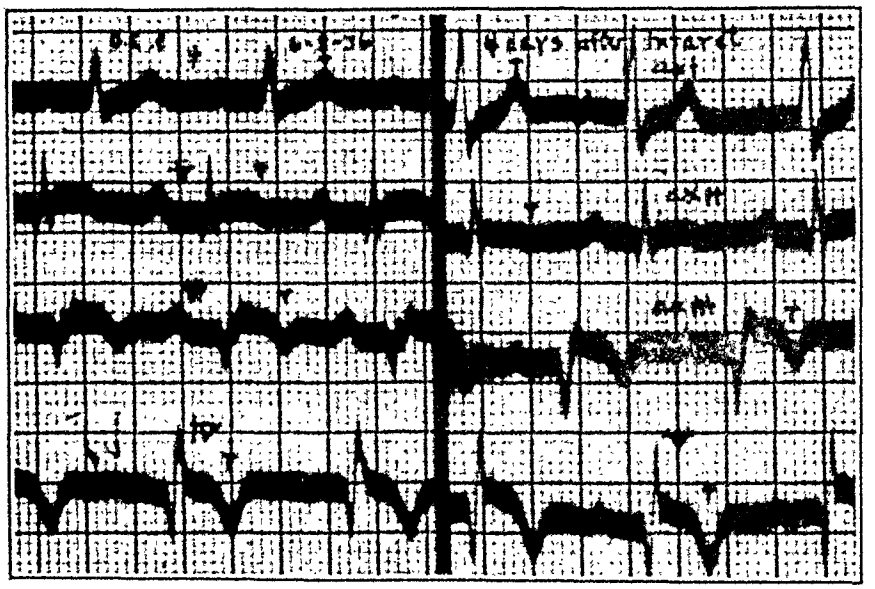

Fig. 12.—Case 18. Early T_3 type of electrocardiogram taken four days after the onset of acute myocardial infarction and showing elevated RS-T in the limb and midaxillary Leads II and III and in Leads IV and V. Also showing diphasic T_2 and inverted T_3 in the limb and midaxillary leads. The T_3 changes are slightly more marked in the limb than in the midaxillary leads.

CASE 18.—Mr. O. C., aged forty-six years, had an acute attack of myocardial infarction four days before the electrocardiogram was taken. The tracing (Fig. 12) showed a diphasic T_2 in the limb and midaxillary and anterior axillary leads* and an inverted T_3 in the limb, anterior axillary and midaxillary leads. The RS-T was elevated in Leads II, III, IV, V, ax_2, anterior ax_2 and anterior ax_3. There was a deep Q_2 in the limb leads and a deep Q_3 in the limb, anterior axillary and midaxillary leads. The changes in Lead II were a little more prominent in the limb leads than in either of the axillary positions.

CASE 19.—Mr. T. B. R., aged forty-nine years, was seen by me for an electrocardiographic study only. He had had angina pectoris during the preceding six

*In the anterior axillary leads the right arm electrode was placed on the right anterior axillary line and the left arm electrode on the left anterior axillary line, instead of in the corresponding midaxillary positions. This generally gave waves directed in the same direction but of greater amplitude than midaxillary leads in Leads I and II.

months. Acute myocardial infarction had begun about fifty-two hours before the tracing was taken and the pain had continued up to that time except when he was under the influence of morphine. The electrocardiogram (Fig. 13) showed a normal T_1 in the limb leads. In Leads II and III the RS-T was elevated markedly, with a high take-off from a notched R-wave. Large Q_2 and Q_3 were also present. In the midaxillary Lead I the T-wave was practically isoelectric and if there was any deflection from the isoelectric line it was toward inversion of the T. There was also a small Q in midaxillary Lead I. Midaxillary II was almost identical with Lead II except that it was of slightly less voltage. Midaxillary T_3 did not look much like midaxillary T_2 or the limb T_2 or T_3, for the R-wave was short and was not notched. In the midaxillary Lead III there was a deep Q, however, as well as an elevation of the RS-T interval with a high take-off. The T also was inverted, but not as deeply as in the limb Lead III.

The blood pressure remained elevated. The patient died Oct. 5, 1935. The post-mortem examination showed a massive infarction of the posterior part of the left ventricle and interventricular septum in the region usually supplied by the right coronary artery. The infarction extended to within 1 cm. of the apex but did not

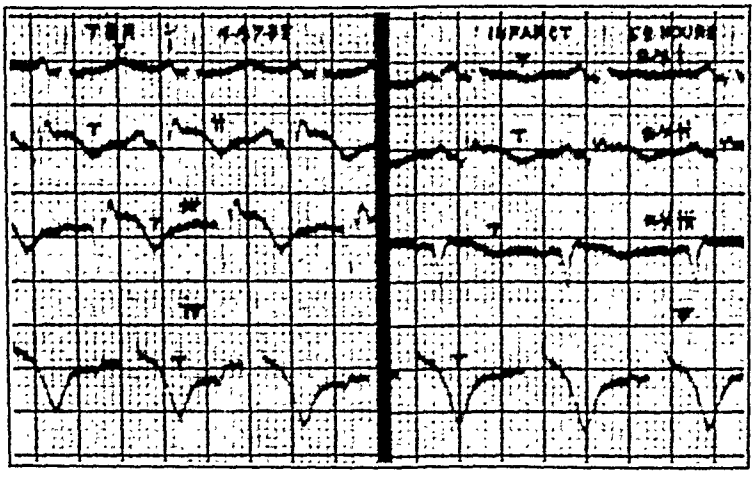

Fig. 13.—Case 19. Early T_3 type of electrocardiogram taken fifty-two hours after the onset of acute myocardial infarction. The inverted T_2 and T_3 elevated RS-T_2 and RS-T_3, deep Q_2 and Q_3 in the limb and midaxillary leads indicated T_3 type of infarct (posterior basal part of left ventricle) which was proved by post-mortem examination. The hypertension which persisted in spite of the acute infarction accounts for the inversion of the T in the midaxillary Lead I. The midaxillary T_1 is here shown to be more sensitive to left ventricular strain (hypertension) than the limb T_1, for the latter has remained upright.

reach to the apex. There was marked thinning of the posterior wall of the left ventricle about 2 cm. from the posterior part of the interventricular septum and about three-fifths of the distance from the coronary sulcus to the apex. A perforation had occurred at this point, and the pericardial cavity was filled with clotted blood. There were unusually large branches of the right coronary artery going to the infarcted region in the posterior part of the left ventricle and the posterior part of the interventricular septum. These vessels were markedly sclerotic and occluded by thrombi. They were of the size to be expected[9] when the right coronary artery is larger than usual and supplies more of the left ventricle toward the apex and toward the left than is found in the average heart. There was no infarction in the region supplied by the left coronary artery.

Case 19 shows the T_3 change in both the limb and midaxillary leads, but this change is shown better in the limb leads. The changes in the

midaxillary T_1 may best be interpreted as being a residual effect of the predominant left ventricular strain[1] from the hypertension, which showed better in the midaxillary Lead I than in the corresponding limb lead. (See comments and paper on ventricular strain[11] to follow.)

Table II shows a summary of these 2 cases and additional cases having evidence of only the T_3 type of infarct.

TABLE II

SUMMARY OF T_3 CASES. A COMPARISON OF T_2 AND T_3 CHANGES IN THE LIMB AND MIDAXILLARY LEADS

CASE	T_3 CHANGES MOST MARKED	T_2 CHANGES PERSISTED LONGER*, †
18	limb T_2‡	
19	limb T_2 & T_3	
20	limb T_2 sl., ‡	
21	limb T_2‡	
22	limb T_2 & T_3	
23	limb T_2 sl., ‡	
24	equal	
25	equal	mid-ax T_2
26	limb T_2 & T_3 sl.	
27	equal	mid-ax T_2 sl.,‡
28	mid-ax T_2 sl., ‡, ‖	
29	limb T_3§, ¶	
35	equal	
37	limb T_2 & T_3	

*Where nothing is recorded the patient was not followed long enough to determine changes.

†It was not possible in any case to show that the T_3 changes occurred earlier in the limb than the midaxillary leads, or vice versa.

‡Indicates changes in T_3 and T ax_2 are equal.

§Indicates T_2 and T ax_2 are equal.

‖T ax_1 is somewhat diphasic so there may have been some additional T_1 effect on T ax_2 besides the T_3 effect.

¶T ax_1 quite low but this patient had a previous hypertension so there may be some residual T_1 effect acting on T_2 also.

sl. Indicates slight difference.

In Table II there are listed 14 cases of the T_3 type of myocardial infarction. In 8 of these cases the T_3 change was shown better in the limb Lead II than in the midaxillary Lead II, in 1 case the change was greatest in the midaxillary Lead II, and in 5 cases the change was equal in the two sets of leads. The T_3 changes in the limb Lead III were greater than in the midaxillary Lead III in 5 cases, and equal to those in the limb leads in the remaining 9 cases. In no cases was it possible to determine whether the changes occurred earlier after infarction in the limb or in the midaxillary leads. In 2 cases the changes seemed to persist longer in the midaxillary Lead II than in the limb Lead II. In each case where the T_3 changes were present in the limb leads there was also definite change in the corresponding midaxillary leads. The midaxillary leads appeared to be of but little if any additional value in the T_3 type of infarction.

Six cases showed evidence of both the T_1 and T_3 abnormalities in their electrocardiograms. Two cases of this type in which post-mortem examinations were possible will be briefly described.

CASE 30.—Mr. C. R. H., aged forty-three years, was seen on March 9, 1935. He had had a few pains suggesting angina pectoris during the previous two years. During the week previous to the first electrocardiogram he had experienced six or seven attacks of substernal pain, either after meals or while at rest in bed, and one while climbing stairs. His last attack lasted at least fifteen minutes. Because of his frequent painful attacks even when at rest he was put to bed and kept quiet for about one month, and then was allowed to be up a little. On April 28, 1935, he was seized with a sudden severe abdominal pain. The urine contained blood. Morphine was required for relief. A diagnosis of left renal lithiasis was made. Two days later he had a marked pulmonary edema and then developed severe substernal pain considered to be acute myocardial infarction. A pericardial friction rub appeared.

The first electrocardiogram, which was taken on March 10, 1935, showed a depression of the RS-T interval in Lead I and elevation of this same interval in Lead III. In the corresponding axillary leads the same changes in the RS-T interval were present and were slightly more marked. There was a deep Q-wave in Lead III and in midaxillary Lead III. Leads IV and V were normal. The second

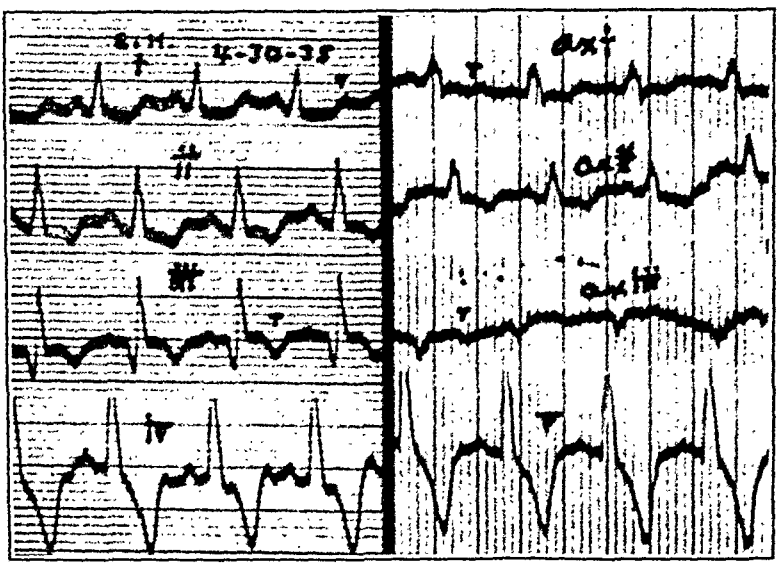

Fig. 14.—Case 30. Electrocardiogram two days after last acute myocardial infarction. The limb leads (i, ii, and iii) show a T_2 type of tracing with inverted T_2 and T_3 and deep Q_3. There is, however, a depressed $RS\text{-}T_1$ and $RS\text{-}T_2$ and a diphasic tendency to T_1 which suggest a possible T_1 change also. In the midaxillary leads (ax_I, ax_{II}, ax_{III}) the T_2 change is not well shown, while the T_1 is, the RS-T and T in midaxillary Leads I and II being quite similar. Autopsy showed both T_1 and T_2 types of infarcts.

tracing (Fig. 14) was taken about twelve hours after the development of the acute myocardial infarction, and a depression of the RS-T interval still remained in Lead I and in midaxillary Lead I, with the T-waves becoming diphasic. T_2 was inverted in the limb and midaxillary leads, but the inversion was more marked in the limb lead. T_3 was inverted but midaxillary T_3 was really diphasic. Q_4 and Q_5 were shortened and T_4 and T_5 more deeply inverted. Q_3 was deep. In the limb leads this was an electrocardiogram of the T_2 type and suggested infarction in the posterior part of the left ventricle in the part usually supplied by the right coronary artery. The midaxillary leads, however, were not so typical. Both the midaxillary T_1 and T_3 were diphasic. The T and RS-T in midaxillary Lead II resembled that of Lead I more than that in Lead III.

When there are changes in the T and RS-T in all three leads Barnes and I found such a comparison of Lead I or Lead III with Lead II was often a help in deter-

mining whether we were dealing with a T_1 type or T_3 type of tracing. This case, according to this observation then, would suggest a T_1 type of tracing in the midaxillary leads and a T_3 type in the limb leads.

The autopsy showed a stone lodged in the left ureter and a recent infarction of the midportion of the posterior part of the left ventricle. At the site of the infarct the heart was practically perforated, but pericardial adhesions had kept the heart from actually rupturing. There was also an acute infarction of the upper portion of the posterior part of the interventricular septum. These infarctions were all in the region supplied by the right coronary artery. There was no infarction in the right ventricle. There was an old fibrous endocardial and subendocardial infarction in the anterior portion of the interventricular septum where supplied by the left coronary artery.

The second electrocardiogram in the limb leads in Case 30 was of the T_3 type and showed a true picture of the recent infarct, which was in the usual site and was produced by a right coronary artery lesion. The depression of the RS-T interval in Lead I and in midaxillary

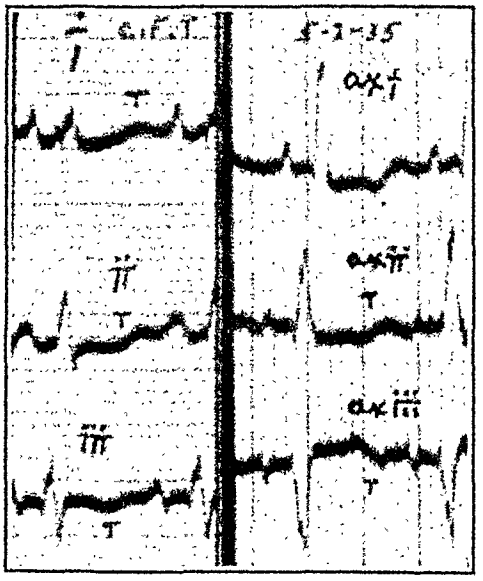

Fig. 15.—Case 31. Electrocardiagram taken just before death from pulmonary edema in a patient with multiple infarcts proved at autopsy to be of T_1 and T_3 types. In the limb leads (i, ii, iii) the T_2 is diphasic and T_3 inverted, suggesting a T_3 type of change but the RS-T_1 and RS-T_2 have a low take-off which has modified the changes in T_2. The T is diphasic in all of the midaxillary leads (ax_I, ax_{II}, ax_{III}) but is similar in midaxillary Leads I and II and midaxillary III is the reciprocal or invert of midaxillary Lead I. The RS-T depression in midaxillary II also is similar to the change in midaxillary I. The midaxillary tracing is of the T_1 type, while the limb leads show some T_3 changes.

Lead I was probably a result of the old anterior infarct, as these findings showed in the first tracing and were not entirely effaced by the later right coronary artery lesion. It is to be noted that the T_1 type of change was manifested better in the midaxillary leads and the T_3 changes were better displaced in the limb leads.

CASE 31.—Mr. C. F. T., aged sixty-eight years, was seen in consultation with Dr. George Carlisle, of Dallas. This patient had had a number of attacks of acute myocardial infarction. His blood Wassermann reaction was strongly positive but he had no sign of aortitis or aneurysm. He had had previous electrocardiograms which showed, on July 24, 1935, an inverted T_2 and T_3, on Feb. 7, 1934, a diphasic T_2 and an inverted T_3, on Dec. 7, 1934, a diphasic T_1 and inverted T_2 and T_3. Another

electrocardiogram (Fig. 15) taken when the patient was in extremis, just before death from pulmonary edema, showed, besides numerous premature ventricular contractions, a diphasic T_2 and an inverted T_3, suggesting a T_3 type of tracing. RS-T_2 was slightly depressed and there was a low take-off of RS-T_1. In the midaxillary leads all 3 T-waves were diphasic, but T_2 was similar to T_1 and not like T_3, suggesting a T_1 type. In the midaxillary leads RS-T_1 and RS-T_2 were depressed below, while the RS-T_3 was elevated above the isoelectric line.

The post-mortem examination showed that the heart weighed about 400 gm. There was a thinning out of the left ventricle wall from an old massive infarct involving the anterior part of the left ventricle and the apex with almost aneurysmal dilatation of the apex and with old adhesions of the apex to the pericardium. This region was supplied by the left coronary artery. Small depressions on the pericardial surface leading to the discovery of infarcts of the perpendicular or penetrating artery type, which I have previously described,[9] were found in the posterior basal part of the left ventricle where usually supplied by the circumflex branch of the left coronary artery and also where usually supplied by the right coronary artery. In this case, as occurs in about 10 per cent of hearts,[9] the entire posterior surface of the left ventricle was supplied by the left coronary artery. It has been shown[10] that the portion of the heart involved, and not the particular artery supplying it, determines the electrocardiographic findings in case there is a variation from the normal blood supply.

As far as the limb leads were concerned in Case 31 there was not much evidence of anything but the T_3 type of infarct, except in the electrocardiogram of Dec. 7, 1934, when the T_1 was diphasic and suggested the possibility that there also might be associated a left coronary artery lesion with a T_1 type of infarct. The final electrocardiogram, and the only one in which the midaxillary leads were taken, suggested in the limb leads that a T_3 type of infarct was present and in the midaxillary leads suggested a T_1 type. This seeming discrepancy really was an indication that the patient had both susceptible regions of the heart involved and this and other cases of this series suggest that the limb leads are more sensitive to the T_3 type of infarcts and the midaxillary leads more sensitive to the T_1 type.

TABLE III

SUMMARY OF CASES SHOWING BOTH T_1 AND T_3 CHANGES. A COMPARISON OF THE T_1 AND T_3 CHANGES IN THE LIMB AND MIDAXILLARY LEADS IS SHOWN

CASE	DATE OF ELECTRO-CARDIOGRAM	LEADS IN WHICH T_3 CHANGES WERE BEST SHOWN	LEADS IN WHICH T_1 CHANGES WERE BEST SHOWN	INDICATIONS OF BOTH T_1 AND T_3 CHANGES WERE SEEN
30	3/10/1935	equal	equal	limb & ax
	4/30/1935	limb	ax	limb & ax (?)
31	5/ 2/1935	limb	ax	limb
32	4/21/1936	limb	ax	ax
	4/22/1936	limb	ax	ax
33	7/ 6/1931	limb	*	*
	11/ 2/1934	limb	ax	limb
34	8/ 4/1936	equal†	equal	limb & ax
36	11/16/1936	limb	ax	ax

*Midaxillary leads were not taken in this electrocardiogram.

†This case had a previous electrocardiogram of the T_3 type only, in which only the limb leads were taken.

The 2 cases described and 4 additional cases having electrocardiograms suggestive of both the T_1 and T_3 type of infarct are shown in Table III. Although this series is small, 2 cases were verified by autopsy. A glance at the table indicates what has already been suggested, namely, that in most cases and in most of the electrocardiograms taken on cases of this type the T_3 infarct is better shown in the limb leads, while at the same time the T_1 type is better revealed in the midaxillary leads. In most instances the limb leads, while registering the posterior or T_3 type of infarct, also gave some suggestion or indication of a possible T_1 type of lesion. In two electrocardiograms the multiple infarcts seemed to be shown equally well in the limb and midaxillary leads. The T_1 change noted in the limb leads in combined T_1 and T_3 types of infarcts was a slight RS-T_1 depression with or without a diphasic element in the T-wave in Lead I. That these limb lead T_1 changes were not always present in combined T_1 and T_3 types of infarcts is seen in Case 32 in which the first electrocardiogram failed to show evidence of the T_1 type of infarct in the limb Lead I although it was clearly seen in the midaxillary Lead I.

It is interesting to note that in the normal electrocardiogram the midaxillary T_3 is more frequently inverted than the conventional T_3. In the presence of lesions tending to produce the T_1 change or in multiple infarctions of T_1 and T_3 type the midaxillary T_3 eventually is more likely to become positive than is the conventional T_3. Thus, all three midaxillary leads appear to be more sensitive to T_1 changes than the limb leads, even in the presence of a T_3 type of lesion.

COMMENT

Space has not permitted a detailed description of all of the cases of myocardial infarction which have been studied with the midaxillary leads. It is to be regretted that the series is so small and the post-mortem examinations are so few. There have not been many deaths among the group of patients studied and, unfortunately, the post-mortem examinations which were made were performed on patients whose electrocardiograms had indicated T_3 or combined T_1 and T_3 types of infarcts. Regardless of the paucity of post-mortem proof there is enough evidence based on our previous knowledge of the electrocardiographic localization of myocardial infarcts in the limb leads, which also were studied in each case, to indicate that the midaxillary leads accurately indicate the site of the infarction.

In all of the cases reported in this paper the right and left arm electrodes were placed in the corresponding midaxillary lines. Since infarction produced by a lesion of the left coronary artery is generally in the anterior part of the heart it was thought that this lesion might be shown better if the axillary electrodes were placed in the anterior axillary lines, rather than in the midaxillary position. Such a lead

does show greater amplitude of the T and the various other waves in Lead I and greater inversion of the T in the presence of a T_1 type of infarction, but as yet no evidence has been obtained to indicate that this lead is any more accurate or reliable than the midaxillary Lead I. Conversely, it might be expected that electrodes placed at the right and left posterior axillary line might show the T_3 changes of posterior infarcts best but this does not seem to be true in the few cases studied with these leads.

In a few cases Leads I, II and III were taken in all possible combinations, with the right arm electrode placed first on the right arm, then the right anterior, middle, and posterior axillary lines, and the left arm electrode attached to the left arm, left anterior, middle, and posterior axillary lines. None of these possible positions for the electrodes seemed to be superior to the midaxillary leads. The important point that was noted was that, as far as the T-wave inversion in Lead I was concerned, this inversion became progressively deeper in the following order as the leads approached the level of the heart: right arm to left arm, right midaxillary line to left arm, right arm to left midaxillary line, and right midaxillary line to left midaxillary line. No effort was made to determine differences in the electrocardiogram in the upper and lower levels in the midaxillary lines, for small electrodes were not used, the tests being confined to the use of the larger linear electrodes commonly used, at least until recently, in clinical electrocardiography.

Since the midaxillary leads pass through the heart from side to side they do not resemble Leads IV and V of Wolferth and Wood,[13] which pass through the heart in an anteroposterior direction. The midaxillary leads resemble more closely the standard limb leads. Since the thorax is narrower anteroposteriorly than laterally and the heart occupies more of the anteroposterior diameter than the lateral, one would expect to find Lead IV to be more sensitive than the midaxillary leads, and in the main this appears to be true. This would seem to place the midaxillary leads intermediate between the limb and anteroposterior leads as far as their sensitivity for T_1 changes is concerned. In general, then, we find that the limb Lead I is not as sensitive as might be desired for T_1 changes and is likely to be unchanged unless considerable pathologic damage has resulted. It is the author's impression that the anteroposterior leads go to the other extreme and may at times be a little too sensitive and show abnormality when clinically one is unable to account for it. In the absence of changes in the limb or midaxillary leads one must be a little cautious in interpreting diphasic and occasionally upright T, slight changes in the level of the RS-T segment or slight shortening or lengthening of the Q in the anteroposterior leads as always indicating cardiac abnormality. Marked changes in the anteroposterior leads appear to be more reliable. The

midaxillary leads appear to be enough more sensitive than the limb leads to show T_1 changes better, but not enough so to show changes that cannot be accounted for on a pathologic basis. Even though the anteroposterior leads seem to be more easily altered from the normal than the limb or midaxillary leads, some cases were studied in which, in the presence of T_1 changes in the limb leads, the anteroposterior leads remained normal (as in Case 2, Figs. 6 to 10). This indicates that in the future electrocardiography cannot be confined to a study of three or four leads without interfering with progress. Just what leads will eventually be found the most satisfactory is not known at present. More experimentation is needed. Other leads, such as Weinstein's[8] "multiple plane" leads, must be evaluated.

Leads IV and V have complicated electrocardiography, not so much because of the additional leads required, as from the necessity of developing a new standard for normal and abnormal in leads where all complexes, in fact, the whole tracing is inverted. This difficulty is not encountered in the midaxillary leads, for the right arm electrode is not placed closer to the heart than the left, so all of the complexes are normally upright.

The addition of three more leads would make electrocardiography more tedious. Since the midaxillary leads show the T_1 changes and not the T_3 changes more advantageously than the limb leads there is no real necessity for taking the midaxillary Lead III. Furthermore, any T_1 change likely to alter midaxillary Lead II is almost certain to change midaxillary Lead I to a more marked degree, so midaxillary Lead II also can be omitted. Thus, with the addition of only one more lead,* the midaxillary Lead I, or as it might be called, the lateral thoracic lead, it is possible to depict practically any significant T_1 change that these three midaxillary leads might show. If the midaxillary Lead I shows significant abnormality, then, if one desires, the midaxillary Leads II and III also may be taken, but very little additional information is likely to be gained except possibly in combined T_1 and T_3 changes.

In several cases there was a seeming contradiction, in that the limb leads suggested the T_3 type of infarction and the midaxillary leads the T_1 type (Table III). That both systems of leads were correct was seen in two of the cases that came to post-mortem examination, as infarction in the location anticipated for both the T_1 and T_3 electrocardiographic changes was found in each of these cases. In the remaining cases of this group there was a history of multiple acute coronary episodes. Furthermore, in 4 of the 6 cases in Table III there were some changes in the RS-T level and T in Lead I of the limb leads that suggested that there might also be an associated T_1 type

*It must be understood that the midaxillary Lead I is not recommended for, or even suggested as a substitute for, or to replace, the conventional limb Lead I.

of lesion. Electrocardiograms of the limb leads, such as those of Fig. 14 and Fig. 15, are of this character. Cases in which, in the presence of inversion of T_2 and T_3, there is also a diphasic or inverted T_1 should make one suspect a possible T_1 type of lesion, in addition to the T_3. Barnes and I found a number of these cases with changes in all three leads and suggested that eventually, if successive or serial electrocardiograms were taken, they generally would reveal the more recent or more predominant infarction or ventricular strain, in the absence of digitalis effect or pericardial adhesions. The rule, which has been previously referred to, and which Barnes and I followed in the interpretation of the T type of change in the electrocardiogram in some of these more difficult cases where there is some change in all three limb leads, was to observe carefully the T and RS-T in Lead II and determine whether it more nearly resembled the corresponding segments of Lead I or of Lead III. If it resembled Lead I we considered the tracing to be of the T_1 type, and if it resembled Lead III, we considered it to be of the T_3 type. This general rule has been followed in the interpretation of the electrocardiograms in the cases listed in Table III, and observation of this rule enables one to obtain a little additional knowledge from an electrocardiogram, even if confined to the limb leads. In these cases of combined T_1 and T_3 lesions, however, it was observed that the T_1 type showed best in the midaxillary leads, even in the presence of a rather extensive lesion generally associated with the T_3 type of electrocardiogram. Since the limb leads show the T_3 change the best and the midaxillary show the T_1 best it should be a little easier to recognize these multiple infarctions with both the T_1 and T_3 types of lesions without the necessity of repeated tracings.

When Barnes and I[2] stated that the electrocardiogram had a tendency to reveal the more recent, or more predominant, lesion it was not known at that time that the limb lead electrocardiogram registered T_3 changes in infarction more readily than T_1 changes, and one must take this factor into consideration. With the addition of the midaxillary leads to bring out better the electrocardiographic changes of a T_1 lesion, even in the presence of an associated T_3 type of lesion, our statement may more frequently be found to be correct, as it now may become a little easier to determine the more recent, or more predominant, lesion as well as to recognize an old T_1 type of lesion in the presence of a recent T_3 type, or vice versa.

It should not be assumed that the midaxillary leads are altered only by infarction. Like the limb leads they are altered also by digitalis, pericarditis, and strain working predominantly on one ventricle. Discussion of the effects on the midaxillary leads of conditions other than infarction is reserved for a publication[11] that is to follow. In diseases of the heart other than infarction the midaxillary leads, and

especially midaxillary Lead I, appear to act similarly to the limb leads, except that here again the midaxillary leads register changes in the T-wave in Lead I (chiefly inversion of the T) to a more marked degree, and the changes in the midaxillary leads appear to begin earlier and to last longer. This is especially true of the T_1 or T_1 and T_2 inversion of predominant left ventricular strain which may be observed in hypertension, aortic stenosis, and aortic regurgitation. As might be anticipated, the midaxillary leads are apparently not quite as sensitive as the limb leads to the T_2 and T_3 inversion in predominant right ventricular strain.

There are some who object to the introduction of additional electrocardiographic leads. No one can ignore the valuable contributions made to our knowledge of the heart and its action in health and disease, which have resulted from a study of the three standard limb leads. It is hoped that they may continue to add to our knowledge. But, after the monumental work of Wolferth and Wood, we cannot overlook the possibility that, for some purposes, additional leads may augment our knowledge and that leads may be found which may depict more easily or more accurately certain types of cardiac lesions. This paper has suggested that the midaxillary Lead I may be of some additional help in the T_1 type of infarction, which does not register as well as we would like in the limb leads. The paper to follow[11] suggests that the midaxillary Lead I is more sensitive and more easily changed in predominant left ventricular strain than is the corresponding limb lead. It is hoped that others may become interested in research on this subject and that with greater facilities at their command may be able to determine the true worth of the leads here suggested. Perhaps, in addition, leads which are still more sensitive than the ones described here, but which will accurately show T_1 changes, will be found.

CONCLUSIONS

1. The electrocardiogram can be made somewhat more sensitive to the T_1 type of changes associated with infarction in the part of the heart usually supplied by the left coronary artery if Lead I is taken so that the current passes more directly through the heart rather than entirely above it, as in the standard Lead I. Clinical trial of numerous lateral thoracic and arm-to-thorax leads showed the midaxillary leads to be the most satisfactory for this purpose.

2. The normal waves in the midaxillary leads are similar to those of the limb leads and all deviations from the normal appear to have the same significance as in the standard leads.

3. Normal control patients were not found to show any abnormalities of the T-wave or RS-T segment or Q except in midaxillary Lead III.

4. In myocardial infarction, as a rule, the midaxillary leads are found to show T_1 changes more readily than the corresponding limb leads.

These changes in some cases were seen to come earlier, in most cases to show more markedly, and in some cases to last longer in the midaxillary leads than in the limb leads. The T_3 type of infarction was recorded better in the limb leads for the most part, although in some cases this was not true.

5. In no case did inversion of T_1 or T_2 or significant depression or elevation of the RS-T_1 or RS-T_2 occur in the midaxillary leads unless there was definite reason to suspect cardiac damage. In no instance was inversion of the T_1 in the limb leads not associated with equal or greater inversion of the T_1 in the midaxillary leads.

6. The amplitude of the waves in the midaxillary Lead I generally is greater than in the standard Lead I. This alone does not account for the midaxillary Lead I appearing to be more sensitive to T_1 changes, as, for example, T-wave inversion was found in this latter lead when in the standard limb lead the T was merely diphasic or isoelectric, or even upright (positive).

7. In combined infarctions of the T_1 and T_3 types, the T_3 type is, as a rule, recorded best in the limb leads, while the T_1 generally is best shown in the midaxillary leads. It is possible, then, to find electrocardiographic evidence of both infarctions at one time.

REFERENCES

1. Barnes, A. R., and Whitten, M. B.: Study of T-Wave Negativity in Predominant Ventricular Strain, Am. Heart J. 5: 14, 1929.
2. Barnes, A. R., and Whitten, M. B.: Study of the RS-T Interval in Myocardial Infarction, Am. Heart J. 5: 142, 1929.
3. Fenichel, N. M., and Kugell, V. H.: The Large Q-Wave of the Electrocardiogram. A Correlation With Pathologic Observations, Am. Heart J. 7: 235, 1931.
4. Groedel, F. M.: Personal Communication.
5. Hyman, A. S.: Personal Communication.
6. Lundy, C. J.: Personal Communication.
7. Pardee, H. E. B.: Significance of Electrocardiogram With Large Q-Wave in Lead Three, Arch. Int. Med. 46: 470, 1930.
8. Weinstein, J.: Multi-Plane Chest Electrocardiography, Proc. Soc. Exper. Biol. & Med. 34: 253, 1936.
9. Whitten, M. B.: The Relation of the Distribution and Structure of the Coronary Arteries to Myocardial Infarction, Arch. Int. Med. 45: 383, 1930.
10. Whitten, M. B.: The Localization of Myocardial Infarction, Texas State J. Med. 27: 291, 1931.
11. Whitten, M. B.: Midaxillary Leads of the Electrocardiogram in Predominant Ventricular Strain and Other Cardiac Conditions. (In preparation.)
12. Wilson, F. N., Macleod, A. G., Barker, P. S., Johnston, F. D., and Klostermeyer, L. L.: The Electrocardiogram in Myocardial Infarction With Particular Reference to the Initial Deflections of the Ventricular Complex, Heart 16: 155, 1933.
13. Wolferth, C. C., and Wood, F. C.: The Electrocardiographic Diagnosis of Coronary Occlusion by the Use of Chest Leads, Am. J. M. Sc. 183: 30, 1932.
14. Wood, F. C., Bellet, S., McMillan, T. M., and Wolferth, C. C.: Electrocardiographic Study of Coronary Occlusion, Arch. Int. Med. 52: 752, 1933.

USE OF THE BARIUM-FILLED ESOPHAGUS IN THE X-RAY STUDY OF ABNORMALITIES OF THE HEART AND THE AORTA*

J. B. Schwedel, M.D.
New York, N. Y.

THE use of the barium-filled esophagus in the roentgen diagnosis of the heart and aorta has attained sufficient vogue to make it advisable at the present time to consider its value and its limitations. Following the demonstration of the relationship of the esophagus to

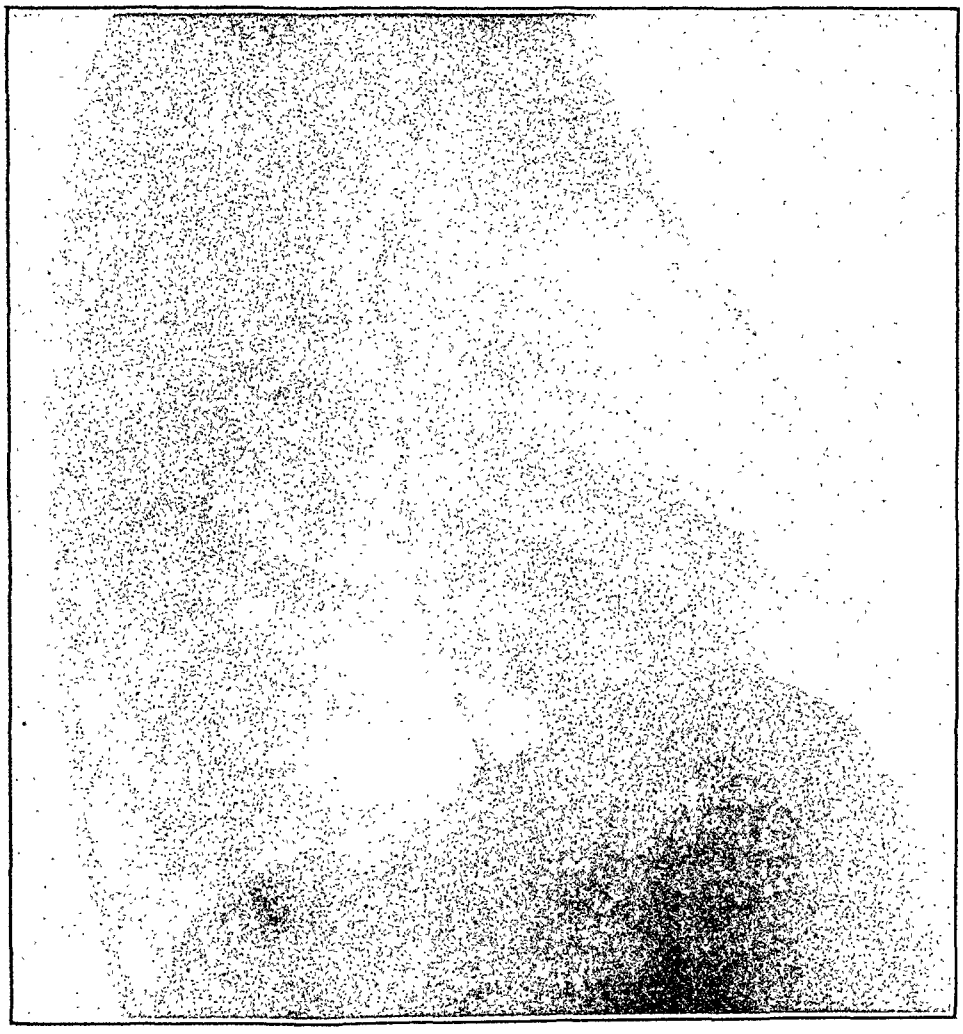

Fig. 1.—Normal heart in the right oblique position. The vertical course of the esophagus is indented by the aortic arch.

enlargement of the left auricle,[1] the barium-filled esophagus assumed a prominent rôle in the diagnosis of enlargement of that chamber. In the routine cardiac examination of all medical cases at the Montefiore Hospital extensive use is made of this important diagnostic aid. In the past four years there have been a number of instances in which the

*From the Radiographic Service of Dr. A. J. Bendick, and the Medical Service of Dr. L. Lichtwitz, Montefiore Hospital.

accepted criteria of posterior displacement of the esophagus in the right oblique view for the diagnosis of an enlarged left auricle have failed of confirmation. At post-mortem examination no enlargement of this chamber could be demonstrated.

This necessitated reexamination of the criteria for left auricular enlargement, and investigation into other causes for similar displacement of the esophagus. A case observation[2] (M.C.), published by myself and Dr. E. B. Gutman, offered a clue, subsequently corroborated by a large number of cases, that elongation of the aortic arch was responsible for most of the confusion.

Fig. 2.—Left auricular enlargement displacing esophagus posteriorly. Same patient as in Fig. 3.

In order to clarify the subject a brief review of the anatomical relationship is of sufficient importance to be presented here. The esophagus pursues a downward course anterior to the bodies of the thoracic vertebrae slightly to the left of the midline up to a point a few inches above the diaphragm where it deviates to the left to enter the abdomen. In its course it is compressed on its left side by the arch of the aorta to which it is attached by areolar and loose fibrous connective tissue. Below the area of compression the esophagus lies behind the posterior surface of the left auricle and anterior to the aorta. In the normal



Fig. 3.—Note the left auricular impression on the esophagus. It is compressed and displaced to the right.

Fig. 4.—The upper arrow shows compression to the right by the aortic arch. The lower arrow indicates deviation to the left in the postero-anterior position.

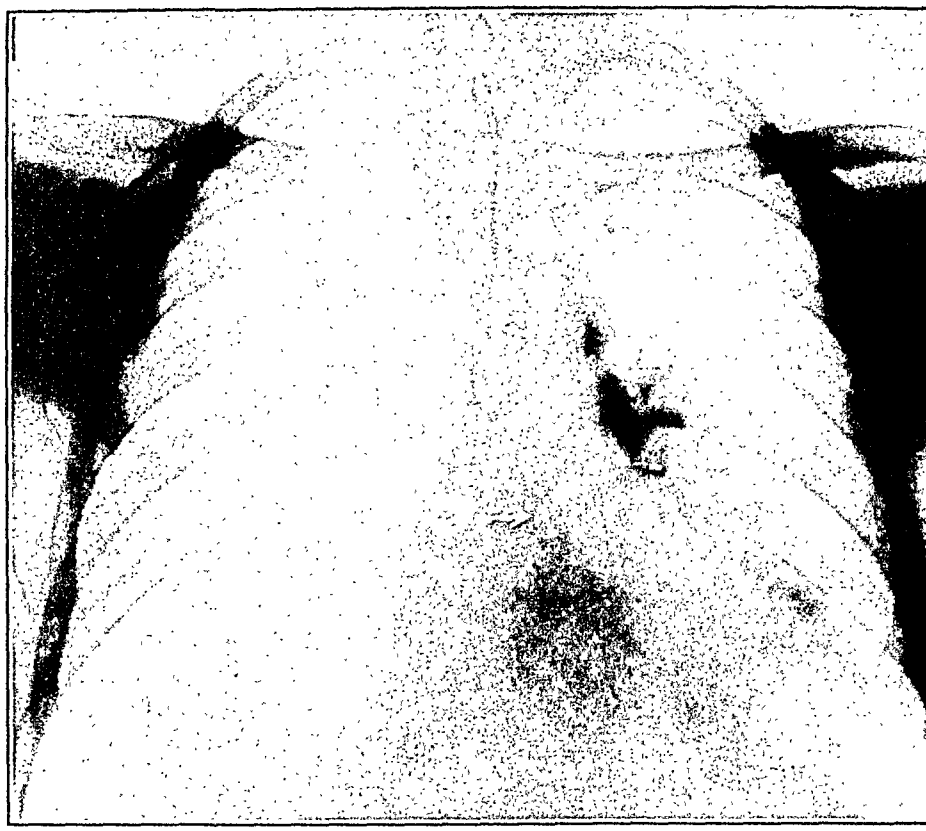

Fig. 5.—Barium displacements similar to those in Fig. 4.

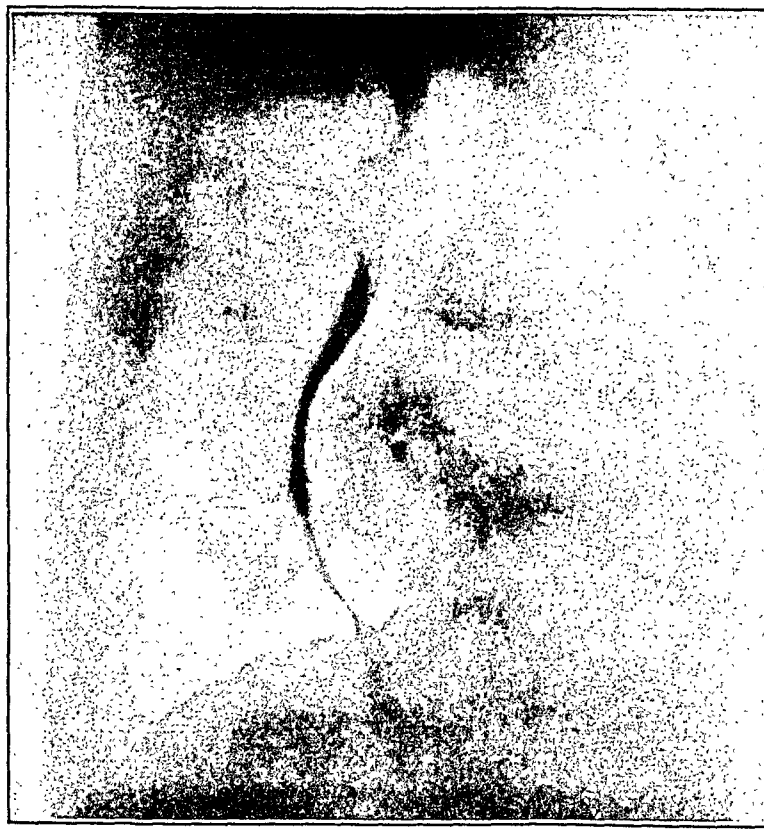

Fig. 6.—Though the left auricle definitely occupies the mid third of the retrocardiac space denoting left auricular enlargement (proved at autopsy), a space is observed between the left auricle and the esophagus. The length of the aortic arch pulled the esophagus sufficiently posteriorly that it no longer was in close relationship to the posterior surface of the heart. Same patient as in Fig. 5.

subject this space between the aorta and the left auricle measures but a few centimeters and this is occupied by the esophagus.

In conditions affecting the length of the aorta, such as is commonly seen in hypertension, arteriosclerosis, and aortic insufficiency, the esophagus, because of its attachment to the aorta, may be pulled posteriorly, increasing its distance from the posterior surface of the heart (left auricle). In aortic elongation, especially of the transverse portion of the arch, the esophagus is pulled not only posteriorly but also to the left, so that it no longer lies anterior to the vertebral bodies but rather in the left costovertebral gutter. This traction to the *left* and *posteriorly* is a key to the use of the barium-filled esophagus in the differential diagnosis of enlargement of the left auricle and the elongation of the aortic arch.

Fig. 7.—Same patient as in Figs. 4 and 9. The marked tortuosity of the elongated aorta is reflected by the appearance of the esophagus within the heart shadow.

Here it may be emphasized that displacement posteriorly and to the left does not occur in all cases of elongation of the aorta. It occurs only in those cases where elongation of the arch of the aorta is associated with adhesions, sufficient to displace the esophagus. These adhesions occur in over three-fourths of the adult post-mortem material, and they occur at and just below the area of aortic compression of the esophagus.

The examination of the heart consists of the fluoroscopic observation of the course of a swallowed spoonful of barium paste in the postero-anterior, right oblique, and left oblique positions. Radiographic films are useful for permanent record only.

In the normal heart the course of the esophagus is vertical (Fig. 1). The normal indentation of the aorta is seen in the postero-anterior and right oblique positions. In the left oblique view the indentation is generally less prominent. Below this indentation the course is vertical in all radiographic positions.

Fig. 8.—Same patient as in Figs. 5 and 6. Note posterior deviation of the esophagus due to adhesions just below the aortic compression. Left oblique position.

Enlargement of the left auricle displaces the esophagus posteriorly, as seen in all degrees of rotation into the right oblique position. In the postero-anterior position the barium-filled esophagus (Fig. 2) is either compressed or displaced to the *right* by the enlarged left auricle (Fig. 3). The course of the esophagus below the aortic indentation remains vertical.*

*Rarely is there displacement of the barium-filled esophagus to the left in the postero-anterior position. In such cases in the left oblique position, however, the posterior displacement does not take place at the aortic indentation of the barium-filled esophagus. This rare group will be taken up in greater detail in a subsequent report and apparently involves mass relationships between the right ventricle and both auricles.

With elongation of the transverse portion of the aortic arch associated with adhesions, a barium-filled esophagus will be pulled to the left in the postero-anterior view. This traction takes place just below the area of compression of the aortic arch. Thus, while the area of aortic compression of the esophagus is to the right the traction below pulls the esophagus to the left (Figs. 4, 5). The esophageal displacement of an enlarged left auricle usually is at a somewhat lower level.

In the left oblique view the esophagus is pulled posteriorly below the clearly visualized aortic arch before resuming its vertical course (Figs.

Fig. 9.—Same patient as in Figs. 4 and 7. Posterior pulling of the esophagus.

8, 9). In the right oblique position the esophagus may be pulled posteriorly, simulating left auricular enlargement. Careful rotation in several degrees of right obliquity will disclose the cause of the esophageal deviation, especially when in the postero-anterior view the deviation of the esophagus is to the *left*. The barium-filled esophagus may be drawn so far posteriorly as to leave a clear space between the esophagus and the left auricle (Fig. 6). In the right oblique view the esophagus may sometimes be seen within the heart shadow and on occasion it may seem even to be drawn anteriorly (Fig. 7), depending upon the degree of fluoroscopic rotation of the patient's heart and the degree of tortuosity

of the aorta. In this group, the deviation of the esophagus, it must be emphasized that the esophagus lies no longer in close relationship to the left auricle, but is drawn in even closer relationship to the descending thoracic aorta.

The posterior displacement of the esophagus where there is deviation to the left in the postero-anterior position cannot be maintained as a criterion of an enlarged left auricle. Enlargement of the left auricle in such instances must be judged by additional criteria such as a bulge into the middle third of the retrocardiac space as seen in the right oblique position, the appearance of the left auricle on the right border of the heart in the postero-anterior position, and the upward displacement of the left main bronchus as seen in the left oblique position.

Differentiation, by means of the barium-filled esophagus, between the groups of elongation of the aorta and of enlargement of the left auricle is of importance, especially in the fluoroscopic diagnosis of individuals in the forties and over. At Montefiore Hospital where a large proportion of the patients are of this age group I would estimate that fully one-fourth have esophageal displacement to the left in the postero-anterior position. This group undoubtedly formed a large proportion of our errors in the estimation of the degree of enlargement of the left auricle. Since this differential method has come into use the percentage of error must be considerably less.

SUMMARY

1. Posterior displacement of the barium-filled esophagus, as seen in the right oblique position, and its displacement to the right in the postero-anterior position are due to left auricular enlargement.

2. Deviation of the esophagus to the left below the area of aortic indentation in the postero-anterior position, and posteriorly in the left oblique position, is due to elongation of the transverse portion of the aortic arch.

3. The use of the barium-filled esophagus serves to differentiate elongation of the transverse portion of the aortic arch from left auricular enlargement.

REFERENCES

1. (a) Stoerck, Oskar: Zur Typographie des Mediastinum bei normaler und bei pathologischer Herzform, Ztschr. f. klin. Med. 69: 32, 1909-10.
   (b) Kovacs, F., and Stoerck, O.: Ueber das Verhalten des Oesophagus bei Herzvergroesserung, Wien. klin. Wchnschr. 23: 1471, 1910.
2. Rosler, H., and Weiss, K.: Ueber die Veraenderung des Oesophagusverlaufes durch den vergroesserten linken Vorhof. Fortsch. a. d. Geb. d. Roentgenstrahlen 33: 717, 1925.
3. Schwedel, J. B., and Gutman, E. B.: The Esophagus in Disease of the Heart and Aorta, Am. J. Roentgenol. 34: 164, 1935.

A MOBILE UNIT FOR SIMULTANEOUSLY RECORDING HEART SOUNDS, PULSE TRACING, AND ELECTROCARDIOGRAM*

K. Jochim, S. F. Gaddas, and H. Marquis
Chicago, Ill.

FOR the past five years we have been recording heart sounds and pulse tracing simultaneously, using several different methods and numerous experimental assemblies. For heart sounds we have used the Einthoven method with a string galvanometer, the Wiggers-Dean



Fig. 1.—The complete unit. *A*, Amplifier; *B*, camera; *C*, earphone with stethoscope attachment; *D*, crystal microphone; *E*, electrocardiograph control box.

capsule method with modifications, and finally a method employing a microphone, vacuum tube amplifier, and recording galvanometer. The apparatus and technic have been sufficiently standardized now to allow tracings to be made routinely. We are reporting the present assembly which has the advantages of simplicity and compactness.

The unit herein described was built around a Cambridge mobile electrocardiograph No. 3 (Figs. 1 and 2). The apparatus has several advantages: (1) The entire unit is self-contained and mobile; (2) the cost

*From the Cardiovascular Laboratory, Department of Physiology, and the Heart Station, Michael Reese Hospital, Chicago.

of the heart sound and pulse tracing equipment is relatively low; (3) the unit is easy to use and has few adjustments; and (4) it is accurate and gives consistent results.

HEART SOUND EQUIPMENT

The apparatus for recording the heart sounds consists of a microphone, a three-stage amplifier, and a small galvanometer. The amplifier was designed and built by one of us (H. M.), and, with the microphone and galvanometer, it was used clinically by Sacks, Marquis, and Blumenthal[1] and Sacks and Marquis.[2]

The microphone is of the piezo electric crystal type, which was found to be most suitable because it is "light, portable, inexpensive, does not require the use of any special transformer or batteries, and will operate in any position without any background noise or hiss."[2]

The amplifier is battery operated, and consists of two type 32 tubes in the first two stages and a type 33 in the power stage, all resistance-capacity coupled (Fig. 3). The volume is controlled by varying the grid bias of the second tube, and a fre-



Fig. 2.—Close-up showing the heart sound and pulse tracing registration apparatus. *A*, Lamp housing; *B*, lens tube; *C*, housing for prism combination; *D*, segment capsule for pulse; *E*, small lens; *F*, heart sound galvanometer; *G*, pulse cup; *H*, timer; *I*, shutter; *J*, camera slot.

quency-control potentiometer is connected across the output of the power stage. Two output jacks are provided, one for connecting the galvanometer, and the other for connecting simultaneously a single earphone receiver with a stethoscope attached so that the operator may hear the sounds that are being recorded (Fig. 4). Before the last stage there is a band pass filter circuit which passes only the narrow band between 50 and 70 cycles. This is for the purpose of picking up the low-pitched murmurs which may ordinarily escape notice. This filter may be cut in or out of the circuit by means of a switch. Without the filter, the frequency range of response is approximately from 60 to 3,000 cycles.* It is extremely important that the parts be exactly as specified, and so arranged as to avoid any stray coupling. Proper shielding is also essential.

The galvanometer was obtained from the General Electric X-Ray Corporation; it is identical with the one used in their Victor Electrocardiograph. It consists of a permanent magnet, in the field of which a small iron plate carrying a small mirror

*These figures apply to the amplifier only. The galvanometer itself has a natural frequency of 200 c.p.s., which, when the higher frequencies are recorded, causes some distortion. This is not significant for practical purposes.

is suspended by a metal ribbon. Two circular coils are so placed within the magnetic field that the audio frequency currents flowing through them from the amplifier change the magnetic field and cause the iron plate and mirror to oscillate. The movements of a beam of light reflected by this mirror are recorded photographically. The mirror and plate are immersed in oil for damping.

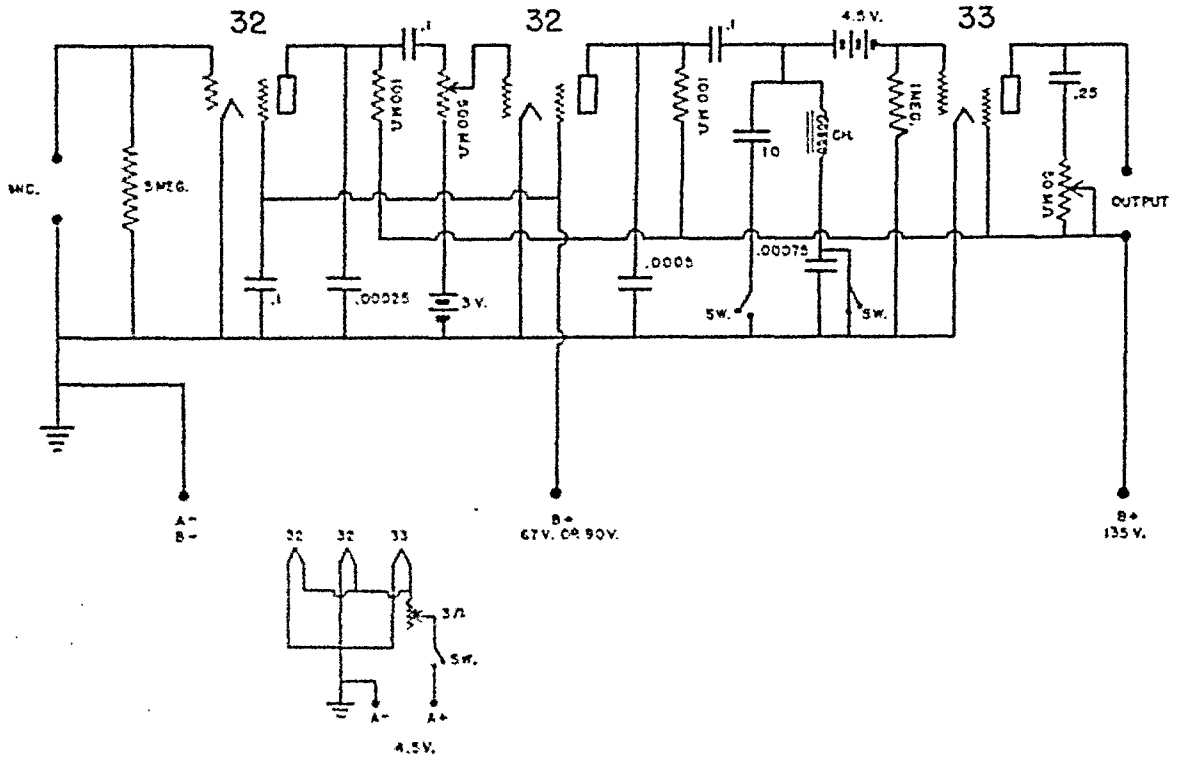

Fig. 3.—Schematic wiring diagram of the amplifier.

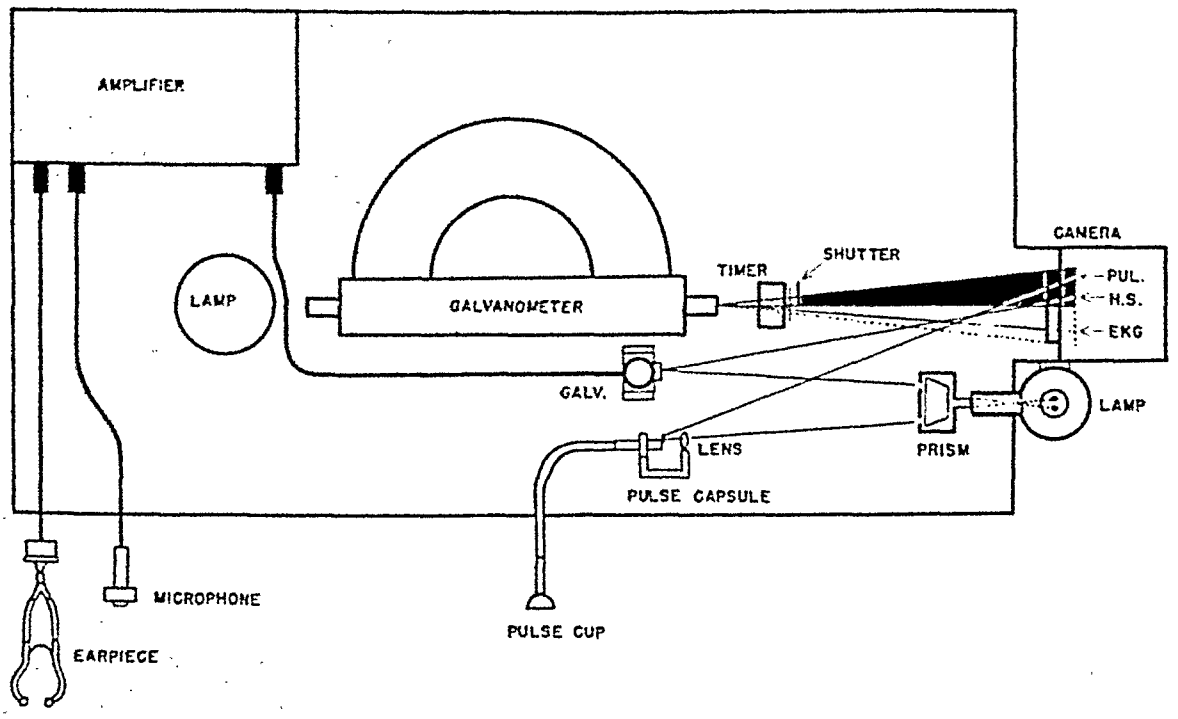

Fig. 4.—Diagram of top of electrocardiograph table showing arrangement of parts and paths taken by light beams.

For audible amplification of the heart sounds we are using a separate auxiliary unit consisting of a power amplifier and loud speaker designed for operation from the 110 volt D.C. line. The amplifier consists of a type 76 tube driving two 48's in push-pull.

PULSE TRACING EQUIPMENT AND LIGHT SOURCE

Optical registration of the pulse is accomplished by means of the usual Frank segment capsule method. The diagram in Fig. 4 represents a top view of the mobile electrocardiograph table and shows the arrangement of the pulse-tracing and heart-sound apparatus mounted on it. Figure 2 is a photograph of the actual equipment. The light source for both the heart-sound galvanometer and the pulse capsule consists of a Mazda automobile headlight bulb No. 1130, 32 c.p. It consumes 4 amperes at 8 volts, and it is operated directly from the 110 volt D.C. line with a 25 ohm, 4.5 ampere capacity resistance in series. The lamp is enclosed in a small, cylindrical housing having a short lens tube projecting from the front. Sliding over the lens tube is a second tube carrying a lens having a focal length of 2 inches and a diameter of 1 inch. Within the lens tube at the point where it joins the lamp housing, there is mounted a single, fixed, vertical slit approximately 1 mm. wide. The light bulb is turned with its socket so that the two parallel spiral filaments are in a line at right angles to the optical axis. This causes two narrow beams of light, almost parallel, to emerge from the center of the lens about 2 mm. apart. The unit immediately

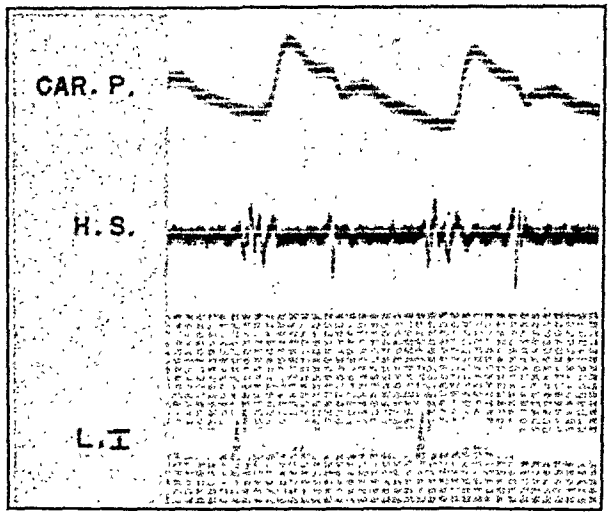

Fig. 5.—Simultaneous carotid pulse, *Car. P.*, heart sounds, *H. S.*, and electrocardiogram, *L. I.*

in front of the lens consists of a doubly reflecting combination of prisms taken from a colorimeter. The two beams of light enter the center of the prism combination and emerge from the front, one on each side, about 2 inches apart and parallel with the original paths.

One beam falls on the galvanometer mirror and is reflected onto the camera slit. The lens on the lamp housing is moved back and forth until this reflected beam produces, at the camera, a sharp image of the vertical slit. The small galvanometer (as well as the pulse tracing capsule) has two screws for adjusting the vertical and horizontal position of the beam.

The other beam falls on the mirror of the segment capsule, but in order that this reflected beam may be sharply focused on the camera without disturbing the focus of the first beam, it is necessary to introduce another lens in the path of the beam before it strikes the mirror on the capsule. This lens is ⅜ inch in diameter and has a focal length of 7 inches. By means of two small rods and clamps it is fastened to the stand which supports the capsule; its distance from the capsule is adjusted until the reflected beam is also sharply focused on the camera (approximately ¾ inch).

The capsule is connected by a short piece of rubber tubing to a metal cup which is placed in the usual way over the blood vessel from which the pulse tracing is to be made. The membrane on the capsule is made of dental dam or even thinner rubber, depending on the amplitude desired on the tracing. The small mirror is cut from a silvered cover slip 0.006 inch thick and fastened to the membrane with a drop of rubber cement.[3, 4]

Immediately in front of the timer is an adjustable metal shutter which may be set to block off the electrocardiographic light from half the field, so that the heart sounds and pulse tracing appear on the record as black lines on a pure white background. The lower half of the record containing the electrocardiogram has the usual gray background with white time lines (Fig. 5).

There are five units comprising the sound and pulse equipment: the lamp, the prism, the galvanometer, the segment capsule, and the amplifier. Each one is mounted on wedge-shaped dovetail base which fits into a corresponding female part on the table and is held in place by an automatic spring lock. Thus each unit may be easily removed from the electrocardiograph table and quickly put back into its exact working position. The positions of the two lenses and the prism may be adjusted once and clamped firmly so that no further adjustment is necessary. The wedge-shaped mounting blocks, the prism housing, and the segment capsule and its carriage are all made of an aluminum alloy, ST-17, which is light, strong, easily machined, retains a bright finish without plating, and is about half as expensive as unplated brass.

SUMMARY

A simple, compact assembly is described for recording heart sounds and pulse tracings simultaneously with the electrocardiogram.

We are indebted to Dr. Louis N. Katz for his interest and guidance in developing the method.

REFERENCES

1. Sacks, H. A., Marquis, H., and Blumenthal, B.: Am. Heart J. 10: 965, 1935.
2. Sacks, H. A., Marquis, H.: Proc. Soc. Exper. Biol. & Med. 32: 773, 1935.
3. Wiggers, C. J.: Circulation in Health and Disease, ed. 2, Philadelphia, 1923, Lea & Febiger.
4. Wiggers, C. J.: Pressure Pulses in the Cardiovascular System, London and New York, 1928, Longmans, Green & Co.

Department of Clinical Reports

PRIMARY FIBROSARCOMA OF THE HEART*

R. S. Fidler, M.D., R. W. Kissane, M.D., and R. A. Koons, M.D.
Columbus, Ohio

In 1918, Perlstein,[1] after a search of the literature on the subject, found thirty cases of primary sarcoma of the heart and added one case, but of these only three cases were classified as fibrosarcoma. In 1932 Popp[2] reported an additional case of fibroblastic sarcoma, but examination of Lymburner's collection[3] of 230 cases of primary tumors of the heart, 57 of which were sarcomas, failed to reveal additional cases of fibrosarcoma.

REPORT OF CASE

Baby M. B. was born Oct. 10, 1933, the twelfth child in the family; all the other chidren were living and well and had no anatomical defects. The family history was negative. This boy was born with a complete harelip and cleft palate and at the age of three months a bilateral inguinal hernia appeared. On March 5, 1934, the boy was admitted to the hospital on the service of Dr. Hugh Beatty, for repair of the facial defect. The physical examination on admission revealed a right opening into the oral pharynx, a defect in the right incisura region, and a complete harelip. The faucial and pharyngeal tonsils were not visible. The eyes, ears, neck, heart, and lungs presented no demonstrable abnormality, and there were no adenopathies. Roentgenographic examination showed no abnormal increase in the thymus shadow; the lungs were completely expanded, the trachea was normal in course and outline, and the heart normal, with no visible shadows suggestive of a tumor. The temperature was normal, pulse regular, rate 100, and the body weight was 12 pounds and 7 ounces. The blood count showed 80 per cent of hemoglobin, 4,240,000 erythrocytes, 19,250 leucocytes, with 34 per cent of polymorphonuclear cells and 66 per cent of lymphocytes. The Wassermann and Kahn reactions were negative; the coagulation and the bleeding time and the urine were normal. Cultures of the nose and throat showed no pathogenic organisms.

On March 16, 1934, a Brophy bone operation was done, in which some approximation of the cleft palate borders was obtained with difficulty because of a large amount of calcification of the superior maxillae. On March 29, 1934, the wires were tightened and on May 9, 1934, complete approximation of the cleft palate was obtained. These operations were performed under oxygen-ether anesthesia, and no untoward reaction occurred. On July 12, 1934, the cleft in the upper lip was closed under oxygen-ether anesthesia, but the child reacted badly to this anesthesia during the entire operation, and the respirations were shallow, jerky and arrhythmic. The pulse at the close of the operation was 176, and the temperature 108° F., while immediately before the operation the temperature had been normal. The child died twelve hours after operation.

*From the Pathological and Cardiological Departments of White Cross Hospital, Columbus, Ohio.

Autopsy.—The body was that of a well-developed male white baby, nine months of age, measuring 28 inches in length. The eyes were brown; the hair was light and thin. The jaws were firmly closed by rigor mortis, and the right side of the upper lip had been recently repaired in the process of closure of a harelip. The head was slightly larger than normal, but the contour remained regular and was not of sufficient size to classify as hydrocephalic. The posterior fontanel was completely closed, while the anterior fontanel was large, depressed and calcified only about the margin. There was a marked post-mortem lividity, but no special marks of identification.

Thoracic Cavity: The thymus was not enlarged, being instead somewhat small for a child of this age, and upon removal weighed 9 gm. Both lungs were free, and there was no increase in pleural fluid. The right lung was crepitant but deeply con-

Fig. 1.—The heart at autopsy, showing the dense circumscribed tumor occupying the interventricular septum at the apex, with marginal invasion into the myocardium of the left ventricle.

gested throughout, and in the lower lobe there was what appeared to be an early bronchial pneumonia with a few petechiae over the anterior pleural surface. The left lung was similar, and the trachea and bronchi were free and open. The pericardial sac was smooth and glistening and contained the usual amount of clear fluid. The heart and great vessels were in the normal position, but the heart was elongated, and the apical portion had a peculiar whitish color. The heart weighed 46 gm. and the longitudinal diameter on the anterior surface was 5.5 cm. from the atrial-ventricular groove to the apex. The right ventricle appeared to be somewhat small and measured 25 by 22 mm., and the pulmonary and tricuspid valves were normal, the pulmonary measuring 25 mm. and the tricuspid 45 mm. in circumference, while the myocardium was of the usual thickness. The left ventricular cavity measured 40 by 25 mm.; the mitral and aortic valves were normal, the mitral valve measur-

ing 38 mm. and the aortic 30 mm. in circumference. The foramen ovale was closed, and the ductus arteriosus was obliterated. In the apex of the heart, occupying the position of the interventricular septum and extending into the myocardium of the left ventricle, was a hard whitish mass. This tumor was dense, well circumscribed, measured 22 by 26 mm. and was overlaid by a thin layer of normal myocardium (Fig. 1). The cut surface of the tumor revealed fine interlacing bundles of fibrous tissue without degeneration. No other tumors were found and the coronary arteries were normal. The peritracheal and peribronchial nodes as well as those within the arch of the aorta were moderately hyperplastic.

Abdominal Cavity: The peritoneum, liver, gallbladder, pancreas, spleen, stomach, adrenal glands, and urinary bladder were normal. The mucosa of the duodenum

Fig. 2.—Low power photomicrograph showing the marginal invasion of the tumor into the myocardium of the left ventricle and the closely packed fibroblastic cells arranged in broad irregular bundles toward the center of the tumor.

and ileum was studded with small closely set elevations which had the appearance of multiple areas of lymphoid hyperplasia, while the rest of the intestinal tract was normal. The mesenteric lymph nodes were diffusely enlarged and congested; the largest measured 12 by 7 mm. There was a dilatation of the right and left ureters, averaging 4 mm. in diameter, and also a dilatation of the right and left pelves but the kidneys were normal.

Cranial Cavity: The brain and coverings were normal.

Microscopic Examination: There was marked congestion and edema in both lungs but no evidence of pneumonia. There was a marked hyperplasia of the lymphoid tissue of the duodenum in the submucosal layer with displacement out-

ward and erosion of the overlying mucosa. The spleen and kidneys were moderately congested. The mesenteric lymph nodes showed a marked hyperplasia and congestion almost to the point of hemorrhage.

The tumor in the heart was of a poorly circumscribed fibrous type which invaded and replaced the myocardium at the tumor margin (Fig. 2). Sections stained with hematoxylin-eosin, van Gieson, acid fuchsin, phosphotungstic acid-hematoxylin revealed the cells closely packed and of the fibroblastic type, while the cell margins were distinguished with difficulty and the cell nucleus was prominent and elongated. These cells formed broad bundles having a slight tendency to follow the few blood vessels present, but chiefly they were arranged so that longitudinal, cross and oblique sections appeared (Fig. 3). The intracellular stroma was not abundant. The



Fig. 3.—High power photomicrograph of the marginal portion of the tumor showing elongated nuclei of the fibroblastic type with the cell margins indistinct.

rest of the myocardium of the ventricles and auricles was normal, but in the interventricular septum immediately above the tumor there was a fibrosing process similar to that of the tumor but producing fibrous tissue of a more adult type.

Diagnosis: Primary fibrosarcoma of the heart. Generalized lymphoid hyperplasia with exception of the thymus. Congestion and edema of the lungs. Hydronephrosis. Recently repaired harelip and cleft palate.

COMMENT

This localized, fairly circumscribed fibrous tumor originating in the myocardium, probably from the perimesial tissue, growing and extend

ing by marginal invasion and conversion of the surrounding myocardial cells, and replacing these cells with young fibrous connective tissue cells and later by adult fibrous tissue, is considered by us and others* as a fibrosarcoma.

The case reported by Erickson[4] was in a male thirty-six years old, and the fibrosarcoma was in the left auricle. That of Juergen[5] was in a male thirty-six years old, with a fibrosarcoma in the right auricle. That of Raw[6] was in a female forty-three years old, with the fibrosarcoma in the right auricle, and that of Popp[2] was in a male thirty-three years old, with the fibrosarcoma in the right auricle. The case herein reported is exceptional because the fibrosarcoma was located and confined to the ventricle and appeared in a male only nine months old. It is also unique because the primary sarcomas are not considered to be associated with developmental defects as are the rabdomyomas, whereas associated with this tumor were a harelip, cleft palate, and double inguinal hernia.

REFERENCES

1. Perlstein: Am. J. M. Sc. 156: 214, 1918.
2. Popp, L.: Fortschr. a. d. Geb. d. Röntgenstrahlen 46: 23, 1932.
3. Lymburner, R. M.: Canad. M. A. J. 30: 368, 1934.
4. Erickson: Upsala läkarf. förh., 1908, Vol. 13, No. 6, Cited by Merez, Diss. Geneve, 1911.
5. Juergen: Berl. klin. Wchnschr. 28: 1031, 1891.
6. Raw: Brit. M. J. 2: 1335, 1898.

*Dr. L. J. Rhea and Dr. Maude Abbott, Montreal, Canada, who examined the sections.

ACUTE CORONARY THROMBOSIS AND MYOCARDIAL INFARCTION AFFECTING A PATIENT THIRTY-ONE YEARS OF AGE*

HARRY L. SMITH, M.D., AND H. CORWIN HINSHAW, M.D.
ROCHESTER, MINN.

WE HAVE been accustomed to think of acute coronary occlusion with myocardial infarction as mainly affecting individuals past forty years of age, and certainly in the majority of instances this impression is correct. The number of patients less than forty years of age who have died of acute coronary occlusion, which was proved by necropsy, is relatively small. Up to 1932, twenty proved cases and ten questionable cases had been reported in the literature. Before the characteristic electrocardiographic findings of acute myocardial infarction were well understood, it was difficult to be absolutely sure of the clinical diagnosis of acute coronary occlusion. With the advent of this electrocardiographic knowledge, the diagnosis of acute coronary occlusion and myocardial infarction can be made with higher degrees of certainty. Before we had the aid of the electrocardiograph, the diagnosis of acute coronary occlusion which affected young individuals had to be made with considerable reservations, but with its aid the diagnosis can now be definitely established without necropsy. Because of the extreme rarity of acute coronary occlusion among individuals who are in their early thirties, we are reporting a case in which the patient was thirty-one years of age.

REPORT OF CASE

When twenty-six years of age (1931) the patient had been refused a life insurance policy because of hypertension. During the succeeding five years the blood pressure had been taken, and urinalysis had been performed every few months by his home physician. The value for the systolic blood pressure had varied from 140 to 200 mm. of mercury. Albumin had been constantly present in the urine for three years before he came to the clinic. Subjectively, he had remained well until August, 1936, at which time he was thirty-one years and nine months of age.

In August, 1936, he had begun to note retrosternal distress after unusual exertion. Rest had afforded prompt relief. The symptom had progressed rapidly and had become associated with a numb feeling in the left arm, and, later, in both arms. Within a month he could not walk a single block without anginal pain. By October, 1936, even the exertion of dressing would produce the characteristic distress. When we first saw him, in November, 1936, he said that it took an hour and a half to dress and that he could walk only at the slowest pace, with frequent rests. He had severe, even violent, retrosternal pain. The pain was associated with numbness in both arms, which was maximal in the left anterior cubital fossa. Complete rest caused relief

*From the Section on Cardiology and the Division of Medicine of the Mayo Clinic.

within a few seconds or minutes. At one time he had had a pain that had been a great deal more severe than any other pain he had ever experienced, but this pain had not lasted longer than fifteen or twenty minutes and it had not been accompanied by shock or other symptoms which are usually associated with myocardial infarction. His tolerance for exercise had been decreased after this severe attack of pain, and each week thereafter he had seen a definite progression of the symptoms.

Physical examination revealed a well-looking young man who was very intelligent and cooperative. The value for the systolic blood pressure varied between 160 and 180 mm. of mercury. No other objective evidence of organic disease was detected by physical examination. Funduscopic examination showed a moderate degree of generalized narrowing of the retinal arteries without evident sclerosis or retinitis. Roentgenological examination of the thorax revealed a heart shadow that was well within normal limits. The urine contained moderate amounts of albumin (grade 2), and one specimen contained a few erythrocytes. An electrocardiogram, which was taken in September, a few days after the most severe attack of pain, showed an inversion of the T-wave and a change of contour of the S-T segment in Lead I, an exaggeration of the T-wave in Lead III, a positive T-wave in Lead IV (Wolferth), and an absence of the Q-wave in Lead IV. In view of these findings and the fact that an electrocardiogram taken about two months later revealed an essentially normal tracing, we have almost positive proof that the patient had an acute coronary occlusion with myocardial infarction.

COMMENT

This patient is of interest because he is only thirty-one years of age. He recovered from his acute myocardial infarction, but following the infarction a very severe progressive angina pectoris developed. Because of this, we believe the prognosis is very bad.

Department of Reviews and Abstracts

Selected Abstracts

Johnson, J. Raymond, and Wiggers, Carl J.: The Alleged Validity of Coronary Sinus Outflow as a Criterion of Coronary Reactions. Am. J. Physiol. 118: 38, 1937.

By recording the velocity of coronary sinus flow, returned at once to the superior vena cava, and by calculating the flow per beat and per minute, it was found that: 1, the coronary sinus normally empties into the atrium only during systole; 2, increasing the right ventricular pressure by compression of the pulmonary artery—the heart rate and aortic pressures remaining the same—causes a proportional augmentation of coronary sinus flow; 3, the increase in minute flow following only slight elevation of systolic right ventricular pressure is of the same order of magnitude as that frequently reported from stimulation of cardiac nerves or actions of drugs.

A theory is presented and supported by experiments that the division of coronary return flow between coronary sinus and thebesian veins is determined not only by the anatomical resistance of these respective paths, but by the height to which right ventricular pressure rises during each systole. This accounts for the proportionally larger flow from the coronary sinus in normally beating hearts and the greater drainage by thebesian vessels in dead hearts. It proves that a greater coronary sinus flow can occur through secondary increase in right ventricular pressure alone.

The conclusion is reached that inferences regarding vasomotor actions in the coronary system based on alterations in coronary sinus outflow cannot be accepted as crucial unless it is demonstrated that right ventricular systolic pressure remained unchanged.

AUTHOR.

Moore, Robert M., and Greenberg, Max M.: Acid Production in the Functioning Heart Under Conditions of Ischemia and of Congestion. Am. J. Physiol. 118: 217, 1937.

Both coronary arterial trunks were ligated in anesthetized cats. The heart became pale, and after a few minutes there were reflex signs of a stimulation of pain elements. In many experiments ventricular fibrillation ensued. In every case the ventricles became widely dilated within ten minutes after ligation of the arteries. After a period of ischemia varying from three to nine minutes, a sample of blood was taken from a coronary vein and a control sample from the vena cava. The coronary venous blood showed a marked lowering of pH, whereas its lactic acid content was increased greatly. The actual fall in pH, as indicated by comparison with blood from the vena cava, varied from 0.22 to 0.81. It exceeded 0.50 in nine of eighteen cats. In three animals the pH of the coronary blood fell below 6.6, and in one animal it reached 6.40. These pH values, we believe the lowest ever reported for blood from the living animal, illustrate how rapidly acid metabolites accumulate when functioning tissues are isolated from the arterial circulation.

Identical experiments were performed upon five dogs with results similar to those obtained in the cat.

In a separate series of cats all the major cardiac veins were ligated to produce venous congestion. Although the heart became markedly congested and its surface "wept" from transudation, the lowering of the pH of the coronary venous blood was so slight as to be questionable, and there was only a small change in the lactic acid content. After twenty or thirty minutes of congestion the heart continued to perform its function in an apparently normal manner.

Under the conditions of the experiments the lowering of the pH of the coronary venous blood to 6.6 or below after a few minutes of ischemia indicates a much greater acid change in the cardiac muscle. The significance of this chemical alteration is discussed with reference to the occurrence of pain in ischemic lesions of the heart and of the extremities. In view of the sensitivity of pain endings to acid (Moore, Moore, and Singleton, 1934), it is concluded that in such clinical cases the accumulation of acid metabolites in the area devoid of arterial circulation can well be of a magnitude to account for the pain.

AUTHOR.

Shipley, R. A., Shipley, Louise J., and Wearn, Joseph T.: The Capillary Supply in Normal and Hypertrophied Hearts of Rabbits. J. Exper. Med. 65: 29, 1937.

During normal growth of the rabbit heart, muscle fibers enlarge, and the capillaries multiply so that a relatively constant capillary supply per unit of tissue is maintained from the time of birth to maturity.

In cardiac hypertrophy the muscle fibers enlarge, but the capillaries do not multiply, and, as a result, the capillary supply per unit of tissue is reduced.

The decreased concentration of capillaries in the hypertrophied heart would constitute an impediment to the adequate exchange of metabolic substances, but the seriousness of the impediment cannot be estimated without further physiological data.

AUTHOR.

Marcu, J.: The Genesis of Embryonic Heart Action on the Basis of a Hydraulic Tube Phenomenon. Klin. Wchnschr. 15: 600, 1936.

The author noted that, when a continuous stream passes through an elastic rubber membrane, it becomes converted into an intermittent stream. He attributes the beating of the embryonic heart to a similar phenomenon.

L. N. K.

Schoedel, W.: Action of Vasodilator Substances on the Work and Blood Flow of Active Skeletal Muscles. Pflügers Arch. f. d. ges. Physiol. 237: 190, 1936.

The author found that vasodilators, like histamine, acetylcholine, adenosine, and muscle adenylic acid, did not improve muscle contraction.

L. N. K.

Paschkis, K.: Anemia and Anoxemia of the Heart Muscle—An Experimental Investigation of Angina Pectoris. Wien. Arch. f. inn. Med. 28: 447, 1936.

In rabbits small doses of adrenalin cause no electrocardiographic changes. The same doses cause changes in the T-wave, however, if the animal is made anemic. The adrenalin by increasing O_2 metabolism of the heart summates with anemia to cause anoxemia in the heart muscle.

L. N. K.

Halbsgut, A.: Action of Extracts of Bulbus Scillae and Scillaren on the Conduction System and Refractory Phase of the Frog's Heart. Klin. Wchnschr. 15: 420, 1936.

The author finds that the heart rate and conduction rate are slowed, systole is lengthened, and the refractory phase is lengthened. The heart eventually goes into a systolic standstill.

L. N. K.

Wood, Francis Clark, and Wolferth, Charles Christian: The Tolerance of Certain Cardiac Patients for Various Recumbent Positions (Trepopnea). Am. J. M. Sc. 193: 354, 1937.

Certain cardiac patients who are able to lie comfortably in one recumbent position cannot tolerate another.

They usually prefer the right side and dislike the left, but there are many variations.

Dyspnea and precordial discomfort are the most common symptoms which are experienced in one horizontal position and relieved on the assumption of another. Cough and anginal pain are less relieved by assuming another. Cough and anginal pain are less frequent. Fatigue, dizziness, and palpitation are also described. These are the same symptoms which lead an orthopneic patient to sit up.

Patients with this syndrome usually show considerable cardiac enlargement and definite reduction in cardiac functional capacity. The symptoms may change in intensity as the clinical condition of the patient changes. There is no apparent correlation between the position the patient prefers and any known cardiovascular characteristic, such as type of lesion, type of failure, or shape of heart.

Observation of patients in their unfavorable recumbent positions shows that their complaint of dyspnea is probably subjective phenomenon, a sense of suffocation, which may or may not be accompanied by obvious increase in rate or depth of breathing. This is also true of orthopnea.

Roentgenological study shows that the heart may move considerably as a patient changes from one side to the other; that the intensity of symptoms is not proportional to the distance the heart moves; that the shape of the heart and aortic arch may change markedly as the subject changes position; and that, with the patient in lateral decubitus, the heart is lifted during each inspiration, sometimes a distance of several centimeters.

The vital capacity does not tend to be greater in the most favorable recumbent position than in the most unfavorable one.

Patients in whom this phenomenon is marked do not assume their most unfavorable position at night, even when asleep. Those in whom it is less well developed are sometimes found in an unfavorable recumbent position during sleep, although they may deny that they can tolerate this position.

Observations of the pulse, the arterial pressure, the cervical veins, and the heart sounds have not as yet been productive of helpful information.

Electrocardiographic tracings have failed to show a change in an unfavorable position which can be attributed confidently to a change in cardiac action.

One subject without heart disease or preference for any particular recumbent position showed a lower cardiac output when lying on the left side than on the right.

Change of position of the heart with distortion of the large vascular channels in the mediastinum is suggested as a possible cause for this phenomenon. The venous return from the lungs might readily be obstructed by this mechanism.

These observations may help to explain the mechanism of production of orthopnea and paroxysmal noctural dyspnea.

This phenomenon has been named "trepopnea" for the sake of brevity, even though it does not express the concept adequately.

AUTHOR.

Sampson, John J.: Study of Depth Temperatures in Artificial Fevers and Cooling Air Chambers With Especial Reference to Cooling Effect of the Circulating Blood. Am. J. Physiol. 117: 708, 1936.

Temperature determinations of skin surfaces, deep skin, subcutaneous tissue, muscles, and blood in the precubital veins were made on normal individuals and on normally afebrile patients undergoing artificial fever treatments. Such observations were made under normal circumstances, at various stages of the fever production, by (1) intravenous vaccine, (2) the "blanket pack" method alone, and (3) the "blanket pack" preceded by heating in an electric light cabinet. Observations were made likewise on such individuals during cooling by surface sponging and by inspiration of iced air. Individuals with normal temperature were likewise studied under the influence of cooled air inhalation.

The recognized gradients between the deep tissue and surface skin were observed with the exception that occasionally the skin was warmer than the subcutaneous tissue under normal circumstances. This phenomenon generally occurred during artificial fever with the "blanket pack" method. The behavior of the intravenous blood temperature under various circumstances leads to the conclusion that the blood may serve as an important cooling agent to the general body tissues, losing more heat in the respiratory tract than has been believed heretofore.

AUTHOR.

Goldsmith, Grace: Cardiac Output in Polycythaemia Vera. Arch. Int. Med. 58: 1041, 1936.

Determinations of the cardiac output and detailed studies of the blood have been carried out over a period of eight months in a case of polycythemia vera. The cardiac output, which was elevated considerably above normal prior to the institution of treatment, decreased as certain hematologic values approached normal. The increase in the basal metabolic rate in this case does not entirely explain the increased cardiac output. It is suggested that the increased volume of blood may be a factor in this regard. Another factor may be the decreased percentage of plasma per unit of blood, causing a deficiency in the transportation of nutrient substances to the tissue. The cardiac output in three additional cases of polycythemia vera is reported; in two the findings were within normal limits; and in one there was a slight elevation of the output. Two of these patients were followed during treatment, and it was observed that the cardiac output tended to decrease as the blood picture approached normal.

AUTHOR.

Spink, Wesley W.: Pathogenesis of Erythema Nodosum, With Special Reference to Tuberculosis, Streptococcic Infection, and Rheumatic Fever. Arch. Int. Med. 59: 65, 1937.

Ten patients with erythema nodosum were critically studied.

No evidence of tuberculosis was present, except in one patient.

The following data indicate a causal relationship between *Str. hemolyticus* and erythema nodosum: In five of the ten patients a sore throat preceded erythema nodosum, and cultures in four cases revealed *Str. hemolyticus* of the beta type; intradermal injection of a streptococcus endotoxin (nucleoprotein) produced nodules

similar to the lesions of erythema nodosum in eight of the ten patients; excised streptococcic nodules and the lesions of erythema nodosum revealed the same histologic appearance; similar lesions were produced by the injection of broth filtrates of streptococci isolated from two of the patients. The same picture has been produced by the injection of tuberculin.

An analysis of the records of 133 patients treated for erythema nodosum at the Boston City Hospital from 1924 to 1934 revealed a similar causal relationship to streptococcic infections and, in addition, to rheumatic fever.

A general review of the literature is presented.

Erythema nodosum appears to be a nonspecific inflammatory reaction of the skin to a variety of bacterial, toxic, and chemical agents.

AUTHOR.

Coburn, Alvin F., and Moore, Lucile V.: Experimental Induction of Erythema Nodosum. J. Clin. Investigation 15: 509, 1936.

The intracutaneous injection of the appropriate antigen in a patient with subsiding erythema nodosum is regularly followed by an intense inflammatory reaction at the site of injection.

The development of this local reaction was followed in half of the subjects tested by a recrudescence of erythema nodosum in the areas recently affected.

The capacity of the involved extremities to develop erythema nodosum persisted for only a few weeks.

A possible relation between the induction of erythema nodosum and an antigen-antibody reaction is discussed.

AUTHOR.

Gibson, John G., and Evans, William A., Jr.: Clinical Studies of the Blood Volume: I. Clinical Application of a Method Employing the Blue Azo Dye "Evans Blue" and the Spectrophotometer. J. Clin. Investigation 16: 301, 1937.

The application of a method for determining the plasma and total blood volume employing the blue dye, Evans blue, and the spectrophotometer to the investigation of clinical problems is described.

Colorimetric errors inherent in earlier methods due to turbidity of plasma, lipemia, residual dye in repeated determinations, and hemolysis of samples are minimized by the use of the spectrophotometer, and a spectrophotometric method of correcting for hemolysis is described.

Errors due to variations in dye mixing time occurring in different clinical states, and possible dilution of injected dye by lymph are eliminated by calculating the plasma volume from a value obtained by extrapolation of the slope or disappearance of the dye from the blood stream, as determined by multiple samples taken over a period of at least thirty minutes after dye injection, to the time of injection.

By the "direct" method of repeated single determinations, volume changes of clinical significance in the same individual can be reliably measured at frequent intervals. By the "indirect method" changes in volume can be continuously followed for periods of from a few minutes to several hours.

Certain factors affecting the accuracy of the indirect method are discussed. A physiological response to serial blood sampling, consisting of a transient and variable decrease in the circulating plasma and red cell volume, renders accurate estimation

of the rate of disappearance of dye from the blood stream difficult. Experimental procedures may alter the intrinsic color of the serum and rate of dye disappearance.

AUTHOR.

Gibson, John G., and Evans, William A., Jr.: Clinical Studies of the Blood Volume: II. The Relation of Plasma and Total Blood Volume to Venous Pressure, Blood Velocity Rate, Physical Measurements, Age and Sex in 90 Normal Humans. J. Clin. Investigation 16: 317, 1937.

Plasma and total blood volumes, venous pressures, and blood velocity rates were determined in 49 normal males and 41 normal females.

No relationship exists in normal persons between variations in total blood volume, venous pressure, and blood velocity rate.

The total blood volume of normal males is greater than that of females, the difference being due to the greater red cell volume of males. The absolute red cell volume of females is less than that of males by a much greater degree than indicated by differences in red cell counts and hematocrit values.

With increasing age there is a decline in the blood volume comparable to decreases in basal metabolic rates and vital capacities.

In comparison to average values, the absolute total blood volume is high in muscular and obese persons and low in thin individuals; the volume per unit of body weight is high in muscular and in thin individuals and low in obese persons.

The blood volume of normal individuals varies within wide limits. The relationship to height or surface area offers a useful basis for estimation of normal volume in clinical investigation.

AUTHOR.

Gotsev, T.: Action of Acetylcholine on Blood Vessels, Blood Pressure, Heart and Vasomotor Centers. Arch. f. Exper. Path. u. Pharmakol. 181: 207, 1936.

The author attributes a drop in blood pressure to a slowing and a depression of the heart, since atropine causes the blood pressure to rise and the heart to accelerate. The volume of the viscera decreases, as a rule, whether the blood pressure rises or falls.

L. N. K.

Grosse-Brockhoff, F., Schneider, M., and Schoedel, W.: Vasomotor Interference in the Nerve Plexus of Skeletal Muscle Vessels Induced by Vasodilator Substances Following Hyperemia. Pflüger's Arch. f. d. ges. Physiol. 237: 178, 1936.

In local hyperemia in the skeletal muscle induced by acetylcholine, the authors find an absence of normal vasoconstrictor action of the carotid sinus and of small adrenalin injections. This refractoriness resembles the effect found in hyperemia following activity, and this refractoriness is absent when histamine, adenosine, or muscle adenylic acid is used. In fact, the response to small doses of adrenalin is exaggerated under the latter conditions.

L. N. K.

Roeske: Movements of Lower Lung Margin and Apex Beat on Lying Down and Sitting Up. Deutsche med. Wchnschr. 62: 542, 1936.

Movements are due to changes in position of the anterior chest wall in these two positions. The lower lung margin follows the chest, but the heart does not. Hence

with the subject lying down the lung margin moves down and the apex beat up. The movements of the anterior chest wall can be easily demonstrated by palpitation of the ribs.

L. N. K.

Herbst, R., and Manigold, K.: Circulatory Insufficiency and O_2 Deficiency. Ztschr. f. klin. Med. 129: 710, 1936.

The effect of the low pressure chamber on compensated and decompensated cardiac patients (valvular deformities, hypertension, emphysema, and coronary sclerosis) was determined. The response of patients with compensated hearts to lowering of pressure is the same as in normal subjects. In patients with decompensated hearts the onset of mountain sickness occurred at lower elevations, viz., 1 to 2 kilometers instead of 3.7 kilometers. Even at elevation lower than this an acceleration of the pulse and increased minute volume blood flow were noted. Before collapse occurred, the minute volume flow decreased.

L. N. K.

Block, C.: Extrasystolic Allorhythmia. Wien. Arch. f. inn. Med. 28: 55, 1936.

A case of old coronary occlusion is described in which there were A-V and intraventricular block and spontaneous allorhythmia. Each effective normal sinus beat was followed by a series of ventricular extrasystoles which interfered with the sinus rhythms. The changes in cycle length of the succeeding extrasystoles were ascribed to "exit" block which usually caused the second impulse to be blocked out. In larger runs of extrasystoles others were blocked out also.

L. N. K.

Neslin, W.: An Autonomic Auricular Rhythm. Wien. Arch. f. inn. Med. 28: 243, 1936.

A rhythm independent of sinus rhythm occurred in the auricles. The pacemaker affected only a part of the auricles and was blocked from the ventricle and sinus node. The author believes this to be an instance of complete persistent intra-auricular block.

L. N. K.

Block, C., and Pick, A.: Action of Magnesium on Ventricular Ectopic Rhythms Occurring in Digitalis Intoxication—III. Wien. Arch. f. inn. Med. 29: 435, 1936.

A case is described of auricular fibrillation with rapid ventricular rate. A 20 per cent solution of $MgSO_4$ caused ventricular slowing by producing an A-V block. The maximum effect lasted from five to fifteen minutes, but the action persisted for some time.

L. N. K.

Knoll, W., Girones, L., and Goerke, W.: Time Relation Between Heart Activity and the Electrocardiogram. Deutsche. med. Wchnschr. 62: 140, 1936.

Each electrocardiogram of an exposed heart, in a dog and in a monkey, was recorded simultaneously with the cinematograph. It was found that QRS occurs when the heart is dilating and T while the ventricle is contracting in size.

L. N. K

Frey, H.: The Efficiency of Various Electrocardiographs. Ztschr. f. Kreislaufforsch. 29: 41, 1937.

An ideal instrument should (1) register accurately at all vibration frequencies found in the electrocardiogram, (2) give proportional responses to all imposed stresses regardless of magnitude or direction, (3) cause no phasic distortion, (4) cause no alterations in potential at lead-off point, (5) be easily transportable, and (6) be easy to operate. The author discusses the various instruments on this basis. He concludes that the string galvanometer is not suitable for chest leads because of polarization. [This argument is not convincing.] The author believes that a constant potential amplifier and a cathode ray oscillograph when properly constructed are best. The alternating potential amplifier must have a time constant of at least 1 to 1.5 sec. if it is to be used. Moving coil oscillographs require an inherent vibration frequency of 600 to 1,000.

L. N. K.

Pick, A.: Concerning Atypical Bundle-Branch Block. Ztschr. f. klin. Med. 129: 719, 1936.

The author presents twenty-four cases of advanced intraventricular block, all of which showed a prolongation of the second phase of the QRS complex, the first phase being normal in duration or only slightly prolonged; and the T-wave was opposite in direction to the prolonged phase of QRS.

The prognosis in this group is similar to other groups of intraventricular block. The commonest cause of this condition was arteriosclerosis. A necropsied case is described, showing the transformation of an atypical to uncommon type of intraventricular block following myocardial infarction. This indicates that other conditions besides the location of the block help to determine the electrocardiographic appearance in man.

L. N. K.

Schlomka, G., and Gauss, G.: Clinical Electrocardiography: IV. Observations in Emphysema. Ztschr. f. klin. Med. 129: 760, 1936.

One hundred patients with emphysema were studied. The authors found a tendency toward right axis shift. The degree of this is related to severity of lung involvement.

L. N. K.

Langendorf, R., and Pick, A.: Electrocardiogram in Lung Embolism. Acta med. Scandinav. 90: 289, 1936.

Four necropsied cases of lung emboli showing marked electrocardiographic changes are described. No abnormalities in the heart or the coronary arteries were found to explain the changes. The authors found a total of 12 out of 16 cases in the literature which showed electrocardiographic changes in the first twenty-four hours typical of localized myocardial ischemia usually resembling posterior infarct. This does not run a typical course, however, in seriatum curves.

L. N. K.

Parade, G. W.: Heart Arrhythmias Following Mental and Physical Trauma. Med. Klin. 32: 733, 1936.

Two cases of auricular fibrillation are reported. In one case a healthy athlete developed a paroxysmal auricular fibrillation of several hours' duration during underwater swimming. In the second case an emotional but healthy man developed a similar paroxysm of several days' duration which was initiated by rage.

L. N. K.

Langendorf, R., and Pick, A.: Electrocardiogram in Acute Nephritis. Med. Klin. 33: 126, 1937.

In twelve cases of acute diffuse glomerulonephritis the authors found typical changes as illustrated in three cases described in detail.

The records must be distinguished from the curves seen in pericarditis and anterior wall infarction. The changes are ascribed to sudden elevation in blood pressure and presumably ischemia and inflammatory or toxic factors.

L. N. K.

Bischoff: A Case of Heart-Block (the Roentgenokymographic and Electrocardiographic Findings). Klin. Wchnschr. 15: 702, 1936.

A case of complete A-V block in a seventy-year-old man with ventricular rate of 20 and an abnormal QRST with widened QRS is presented. No evidence of heart failure was present, and the cerebral blood flow seemed adequate at rest and on slight exertion. The disorder could be identified on kymography.

L. N. K.

Rothberger, C. J., and Zwillinger, L.: Action of Magnesium on Strophanthin and Barium Tachycardia. Arch f. exper. Path. u. Pharmakol. 181: 301, 1936.

The authors found that magnesium depressed the ectopic pacemakers in animals and made it more difficult to induce strophanthin and barium tachycardia. This explains the action of magnesium clinically in abolishing extrasystoles and paroxysmal tachycardia. The quantities of magnesium required in anesthetized animals is greater than in man.

L. N. K.

Eckey, P.: Unusual Effects of Small Doses of Strophanthin on Rhythmicity and Conductivity of the Heart and Its Relation to Parasystole. Deutsches Arch. f. klin. Med. 178: 652, 1936.

In one case, three intravenous injections of 0.3 mg. of strophanthin caused a parasystole. In a second case two injections intravenously of 0.3 mg. each caused A-V block with dropped beats and Wenckebach periods. In a third case there was a prolongation of the P-R interval abolished by atropine and hence attributed to a vagus action.

L. N. K.

Schwartz, Sidney P.: Studies on Transient Ventricular Fibrillation: IV. Observations on the Clinical and Graphic Manifestations Following the Revival of the Heart From Transient Ventricular Fibrillation. Am. J. M. Sc. 192: 808, 1936.

Correlated observations were made of the clinical and graphic manifestations following the spontaneous revival of the heart from transient ventricular fibrillation in seven patients with either transient or established A-V dissociation.

It was determined that revival of the heart from transient ventricular fibrillation in man is associated usually with a postfibrillatory pause, followed by a variable standstill of the ventricles and an intermediary idioventricular rhythm with a progressive increase in the heart rate to as high as 160 beats per minute before the restoration of the basic ventricular rhythm.

The duration of this postfibrillatory period is dependent upon the duration of the antecedent period of ventricular fibrillation and is independent of the type of ventricular oscillations present during the fibrillatory period. It may vary from a few seconds to as long as one-half hour at one time.

The spontaneous revival of the heart from transient ventricular fibrillation is associated clinically with a sudden flushing of the face and entire skin by a pink-red coloration, a forceful pulsation of the heart against the chest wall, and a barely perceptible beat of the pulse at the wrist. With these events the eyes are opened, and loud screaming may be followed by incoherent and unintelligible speech, a very cloudy sensorium, and a progressive increase in the heart rate as noted from the electrocardiograms. This in turn is followed by a progressive lowering of the heart rate again to the original basic level prior to that present before the onset of ventricular fibrillation. Coma and a period of unconsciousness may then supervene and last as long as five hours after a major syncopal attack.

The period of apnea present during ventricular fibrillation is replaced at first by irregular periods of respirations in which inspiration is prolonged. There may then appear typical Cheyne-Stokes respirations as well as all forms of irregular respiratory movements noted after asphyxia.

Occasionally after repeated attacks there is a generalized anasarca, involving the face, the arms, and the entire skin.

All of these symptoms and signs are so unique that a clinical diagnosis of transient ventricular fibrillation may be suspected in an individual with syncopal seizures if they are noted after the attack.

Since the natural course of the revival of the heart from transient ventricular fibrillation includes a period of acceleration of the heart following a postfibrillatory standstill of the ventricles, it is a fallacy to assume that any drug administered during the postfibrillatory period is responsible for the successive events which appear after its use.

AUTHOR.

de Châtel, A.: An Analysis of the Pathological Changes in the S-T Segment and the T-Wave of the Electrocardiogram on the Basis of Direct Leads. II. Ztschr. f. d. ges. exper. Med. 98: 389, 1936.

The author indicates that the S-T and T changes following coronary ligation, monoiodoacetic acid, NaF, and hemorrhage are due to changes in the electronegativity of certain regions of the ventricles. In coronary ligation the anoxia causes an earlier activation of the region affected. In the more generalized anoxias the anterior wall of the base of the heart is activated earliest. [This is not convincing.]

L. N. K.

Cossio, P., Lascalea, M., and Fongi, E. G.: Alternation of the Heart Sounds. Arch. Int. Med. 58: 812, 1936.

In seven cases in which different degrees of pulsus alternans were present, the graphic record of the heart sounds showed alternation of the first sound in all cases and alternation of the second sound in only four cases.

The alternation of the first sound was concordant in all cases with the alternation of the pulse beats. In one case only it coexisted and was concordant with an alternation of the T-wave in the electrocardiogram. In another case it coexisted and was discordant with an alternation of the QRS complex.

Alternation of the second sound was concordant with alternation of pulse beats in one case and discordant in three cases. The discordance between alternation of the second heart sound and the pulse beats is associated with its transmissibility from the site where it originates to the place where it is heard in the precordium.

Deliberate precordial auscultation and a mental image of the way the alternation of sounds is perceived enabled recognition of the alternation in all cases. In two

of four cases in which alternation of the first and of the second sound was present, the alternation of the first sound was perceived easier than that of the second sound.

Alternation of the sounds is detected by means of auscultation by the slight differences in the intensity, pitch, and sound that the same sound shows in two successive cardiac cycles. In certain cases there may be a slight typical change in cadence, namely, of the rhythm of their succession.

AUTHOR.

Polanco, Mario: The Relation of Coronary Sclerosis to Symptoms and Its Distribution in 242 Fatal Cases. Am. J. Med. Sc. 192: 840, 1936.

Study was made of 242 consecutive cases with hearts whose coronary arteries were found postmortem to be sclerotic. There were 156 males (64.5 per cent) and 86 females (35.5 per cent).

History of pain of cardiac origin was given in 14.9 per cent of the cases, of which 24 were males and 13 females; 91.7 per cent of these were associated with marked sclerosis and 8.3 per cent with moderate sclerosis. No cases with mild sclerosis gave a history of pain.

Dyspnea and cardiac pain were the symptoms most frequently encountered. Signs of congestive heart failure were also predominant; of the arrhythmias, auricular fibrillation was the most common, and extrasystole, frequent.

The anterior descending branch of the left coronary artery was the most frequent to be "markedly" involved in the sclerotic process (eighteen times).

Of arteriosclerosis in other organs, the kidneys and spleen were more markedly attacked. Other organs were involved in varying degrees, showing that visceral arteriosclerosis tends to be generalized, although usually affecting the vessels of some organs more than others.

The ratio of heart weight to body weight was found to be increased in 90.8 per cent of the males and 91.3 per cent of the females. The average heart weight in 149 males was 417 gm., or 123 gm. (42 per cent) above normal. Of these, 84 per cent weighed more than normal. Of 78 females, the average weight was 387 gm., or 137 gm. (55 per cent) above normal; 83.3 per cent showed definite increase of heart weight.

AUTHOR.

Baumann, E.: Endocarditis Lenta. München. med. Wchnschr. 83: 469, 1936.

The author reports forty-three cases of this disease with positive blood cultures of *Streptococcus viridans.* In only one case was an apparent cure induced by neosalvarsan. Other procedure in this series were without avail.

L. N. K.

Kraiss, H.: Recovery in Endocarditis Lenta. Med. Klin. 22: 566, 1936.

A case of endocarditis lenta with possible recovery (or intermission) of two years' duration is presented. The possibility is considered that a pneumonia from which the patient recovered might have been responsible for the apparent cure.

L. N. K.

Hermann, K.: Pericardial Concretion. München. med. Wchnschr. 83: 889, 1936.

The signs of congestion are due not only to heart failure but to constriction of the veins entering the pericardium. Surgery gives excellent results.

L. N. K.

Bedford, D. Evan, and Parkinson, John: Right-Sided Aortic Arch. Brit. J. Radiol. 9: 776, 1936.

Right-sided aortic arch is a congenital malformation of the aorta due to an abnormal evolution of the embryonic arterial arches. Two anatomical varieties are recognized. It may be an isolated anomaly or may be combined with congenital malformation of the heart, especially with Fallot's tetralogy. Eleven cases of right-sided aortic arch are described, and their radiological features are discussed.

AUTHOR.

Taussig, Helen B.: The Clinical and Pathological Findings in Congenital Malformations of the Heart Due to Defective Development of the Right Ventricle Associated With Tricuspid Atresia or Hypoplasia. Bull. Johns Hopkins Hosp. 59: 435, 1936.

The central feature in this congenital malformation is the diminutive size of the right ventricle. The associated malformations can be postulated from the fact that the right ventricle does not function. The failure of the ventricle to function means that neither the tricuspid valve nor the pulmonary valve can function, and hence they are either atresic or markedly hypoplastic. Furthermore, it means that the only way for the blood to escape from the right auricle is through some defect in the interauricular septum. The extent of this defect determines whether the heart functions as a biloculate or a triloculate heart.

Clinically, the malformation is associated with persistent cyanosis and no murmurs. The diagnosis is established through the recognition of the diminutive size of the right ventricle. This condition can be recognized in the roentgenogram by the peculiar outline of the cardiac shadow. In the anteroposterior view, because of the absence of the pulmonary conus, the upper contour of the cardiac shadow immediately to the left of the sternum has a concave instead of a convex outline. In the left anterior oblique position the small size of the right ventricle is indicated by the absence of cardiac shadow anterior to that of the aorta. These observations are substantiated by the electrocardiogram which shows a left axis deviation.

The differentiation between a functionally biloculate and a triloculate heart depends upon the size of the interauricular septal defect. If there is free communication between the two auricles, i.e., functionally a biloculate heart, physical examination yields no additional positive findings. In contrast, when the interauricular septum is well formed, it causes obstruction to the outflow of blood from the right auricle. Under these circumstances, the auricular pulsation is transmitted to the liver and is readily palpable at its margin. It is this pulsation at the edge of the liver occurring in conjunction with a diminutive right ventricle which distinguishes a functionally triloculate from a functionally biloculate heart.

AUTHOR.

Coburn, Alvin F.: Specific and Non-Specific Changes in Blood Protein During Acute Rheumatism With Carditis. Internat. Clin. 4: 49, 1936.

Patients with rheumatic carditis show measurable changes in the proteins of the blood, both specific and nonspecific in character. These changes begin at the onset of the rheumatic attack. The nonspecific reaction (increase in the erythrocyte sedimentation rate) reaches its maximum level early in the course of the attack while electrocardiographic abnormalities are most marked. Specific changes (increase in titer of antibody to hemolytic streptococcus) can be detected at the beginning of

the attack but do not reach their maximum level until the nonspecific changes and symptoms are regressing. These relations are characteristic of acute rheumatism irrespective of whether the patient is having the initial attack or a subsequent recrudescence after a year or more of good health. In contrast, failing an antistreptolysin response to hemolytic streptococcus, the rheumatic subject does not develop an attack, and the sedimentation rate remains normal. This indicates that an antistreptolysin response is essential to the development of both the clinical symptoms and abnormal sedimentation rates. The relatively late development of the increase in titratable antibody as compared with the increase in sedimentation rate is a constant characteristic of the rheumatic attack. Its significance will be dealt with in a forthcoming communication.

AUTHOR.

Coburn, Alvin F., and Kapp, E. M.: Observations on the Development of the High Blood Sedimentation Rate in Rheumatic Carditis. J. Clin. Investigation 15: 715, 1936.

In acute rheumatism, the sedimentation rate may be considered as a measure of the extent of inflammation.

The increased sedimentation rate in acute rheumatism is caused by an increase in plasma fibrinogen and globulin.

An immunological test for a qualitative difference between the plasma protein fractions of normal and rheumatic individuals gave negative results.

A possible type of mechanism is suggested to account for the rise in sedimentation rate just before the onset of a rheumatic attack.

AUTHOR.

Coburn, Alvin F.: Observations on the Mechanism of Rheumatic Fever. Lancet 2: 1025, 1936.

It becomes increasingly clear that the immune response to hemolytic streptococcus infection is intimately connected with the development of rheumatic activity. Variations in the clinical character of the attack show a close parallel to the types of antistreptolysin curves developed. Up to the present time there has been no evidence as to whether the antistreptolysin curves observed in rheumatic fever were normal responses to hemolytic streptococcus infection or not. The data presented in this paper, in conjunction with findings referred to previously on other streptococcal infections, seem to indicate that the immune response of the rheumatic differ from the normal in that they are delayed. If this should prove to be true in the light of more extensive data on normal responses, then it must be assumed that the rheumatic subject who develops an attack handles the products of hemolytic streptococcus in a peculiar way. Such a concept harmonizes well with the prolonged antigenicity of this organism during rheumatic attacks as evidenced by the persistence of high antistreptolysin titre levels for months after infection. In addition to the apparent delay in the immune response of the rheumatic subject, there may also be a delay in the final elimination of hemolytic streptococcus products from the body. In conclusion, these observations suggest the hypothesis that the rheumatic state is characterized by an abnormal method of disposing of hemolytic streptococcus products. The mechanism whereby such an abnormal immune response may induce disease is unknown. Further information on the nature of this abnormality may make possible an experimental approach to the mechanism.

AUTHOR.

Norris, Robert F.: Primary Pulmonary Arteriosclerosis: Report of a Case With Marked Calcification of the Pulmonary Arteries. Bull. Johns Hopkins Hosp. 59: 143, 1936.

A case of primary pulmonary arteriosclerosis with calcification of the pulmonary arteries is presented, and the evidence in favor of such a diagnosis is discussed.

It is suggested that some cases of emphysema may be the result rather than the cause of pulmonary vascular sclerosis.

Primary pulmonary arteriosclerosis is not a clinical and pathological entity but a syndrome.

AUTHOR.

Schmitt, H.: Experimental Observations on the Pathogenesis of Rheumatic Atherosclerosis. Virchows Arch. f. Path. Anat. 296: 603, 1936.

Rheumatic atherosclerosis occurs in the aorta and coronary arteries only as a result of inflammatory degenerative processes. Animal experiments with serum injections convinced the author that the process is allergic with lipoid infiltration following cholesterol feeding. The lesions were localized here to the abdominal aorta. The involvement may be primarily medial or intimal.

L. N. K.

Pickering, G. W.: Observations on the Mechanism of Arterial Hypertension in Acute Nephritis. Clin. Sc. 2: 363, 1936.

Raised arterial pressure in acute nephritis probably results from vasoconstriction because:

(a) In three cases the circulation time, as estimated by the decholin method, was essentially the same when the blood pressure was high and when it was normal.

(b) The blood viscosity was slightly decreased in three and slightly increased in one patient during the phase of hypertension.

In four out of six cases of acute nephritis estimations of blood flow showed that during the phase of hypertension no abnormal vasoconstriction was present in the hand from which vasomotor nervous tone had been completely removed.

Hypertension seems to be due to vasoconstriction which is of essentially different origin in acute and chronic nephritis; in the former it is probably of nervous origin in most cases; in the latter it is probably not.

AUTHOR.

Böger, A., and Wezler, K.: Action of Musculature on the Elasticity of the Living Arterial Wall: Its Relation to "Red" Hypertension. Klin. Wchnschr. 15: 559, 1936.

The decreased distensibility accompanying blood pressure elevation produced by adrenalin (which the authors used to imitate change with age) occurs in the elastic aorta and the iliac arteries more markedly than in the brachial-radial arteries. Muscular contraction apparently makes the muscular arteries more distensible and so counteracts the action of the rising internal pressure. The increased distensibility acts as a compensatory mechanism to overcome the handicaps of the acute hypertension. The state of tone of these muscular arteries, thus, plays an important rôle in determining their distensibility. The methods of making these observations in man are described.

In patients with "red" hypertension observations indicate that this protective function of the smooth muscle is greatly disturbed. The pulse wave velocity was found to be greater in the muscular arm arteries in patients under fifty years of age with essential hypertension than in those of the same age without hypertension (even when the readings were corrected for the same internal pressure). In the case of the elastic arteries like the aorta no such difference in ratios for corrected pulse velocities could be made out between normal subjects and patients with hypertension.

L. N. K.

Geill, T., and Secher, K.: Studies Concerning the State of the Heart in Obesity: II. Obesity and Hypertension. Acta med. Scandinav. 87: 454, 1936.

Studies on 31 patients were made. The electrocardiogram was abnormal in all; 6 had left axis shift. The electrocardiographic changes occurred in young individuals, none of whom had any nephritis. Hypertension and obesity form a serious combination in affecting the heart.

L. N. K.

Sappington, S. W., and Cook, Hunter S.: Radial Artery Changes in Comparison With Those of the Coronary and Other Arteries. Am. J. Med. Sc. 192: 822, 1936.

The present study suggests: (1) That both age period changes and arteriosclerotic changes are maximal in the coronary arteries and minimal in the radial arteries and more or less intermediate in other vessels, such as the cerebral, splenic and renal arteries; (2) That atherosclerosis in the radial is such a rarity as to be negligible; and (3) That the anatomical condition of the radial artery has no bearing on visceral sclerosis.

Harkins, Henry N.: Mesenteric Vascular Occlusion of Arterial and of Venous Origin: Report of Nine Cases. Arch. Path. 22: 637, 1936.

The literature on occlusion of mesenteric blood vessels is reviewed with special reference to the subject of secondary surgical shock. Except for very occasional citation, this aspect of the condition has received little clinical notice either in reports or treatment. On the other hand, the literature on experimental occlusions indicates that secondary surgical shock from loss of a blood plasmalike fluid into the peritoneal cavity or of blood into the wall or lumen of the intestine may be a major factor in death in these cases.

Nine cases of mesenteric vascular occlusion are reported. Most of these were observed before interest in the possible presence of shock was aroused and were not adequately investigated from this standpoint. One of the purposes of this paper is to enter a plea for more adequate study of such cases from the standpoint of shock.

A study of these cases indicates that arterial occlusion is more common than venous occlusion; that most of the patients are in the upper middle age group; that vomiting is frequent, and often bloody in the venous type; that abdominal distention with fluid is frequently present; that the white blood cell count is elevated; that the temperature is only moderately high; that pain is greater than the accompanying rigidity and tenderness would indicate; and that the condition may simulate mild intestinal obstruction due to malignant disease.

Accompanying the hemorrhagic infarction of the intestines are edema of the bowel wall and mesentery, bloody fluid in the lumen of the bowel with melena and bloody vomitus, and an exudate of blood-stained plasmalike fluid in the peritoneal cavity.

AUTHOR.

Adamek, G., and Friedländer, E.: Venography in Thrombophlebitis. Med. Klin. 32: 222, 1936.

Radiopaque material (perabrodil or tonobryl B) was injected in the superficial vein toward the foot and the leg quickly lowered. This permitted visualization of deep veins and permitted localization of the thrombosis in the iliac veins.

L. N. K.

Smirk, F. H.: Observations on the Causes of Edema in Congestive Heart Failure. Clin. Sc. 2: 317, 1936.

There is a fall in the colloid osmotic pressure of the plasma, and some protein passes through the blood vessels with the edema fluid. The colloid osmotic pressure of the protein of this edema fluid has varied between 1.5 and 7 cm. of water, and this acts in opposition to the colloid osmotic pressure of the plasma. Thus the effective colloid osmotic pressure is reduced, and as a result the reabsorption of fluid into the blood vessels is decreased.

At rest the venous pressure in the legs is approximately equal to the general venous pressure plus the pressure of a column of water extending vertically downward from the manubrium sterni to the situation where the venous pressure is measured. Active muscular movements of the legs diminish the venous pressure in the legs by 10 to 100 cm. of water. Thus the incapacity for exercise of patients with heart failure increases the average venous pressure in the legs, throughout the day, to much above the normal. The increase above the normal of the average venous pressure in the legs of heart failure subjects is produced mainly by their muscular inactivity and to a much smaller degree by the increase in general venous pressure. The increases in the general venous pressure in cases of congestive heart failure are not by themselves sufficiently great to cause edema. All factors increasing the local venous pressure, however, will increase the effective filtration pressure and thus will increase the rate of transudation of fluid out from blood vessels. Conversely the counter pressure of the edema fluid on the outside of the blood vessels, which is exercised as the edema accumulates, will decrease the rate of transudation of fluid.

The permeability of the blood vessels to water and to crystalloids is demonstrably increased in congestive heart failure and this augments the rate of flow of fluid from the blood vessels. The increase in the permeability of the blood vessels to water and to crystalloids may be such that with equal effective filtration pressures the rate of transudation of fluid in congestive heart failure is twice the normal. Increase in the permeability of the capillaries to water and crystalloids only influences the rate at which loss of fluid from the blood vessels occurs, and, despite such an increase in capillary permeability, fluid will leave the blood vessels only in situations where the effective capillary pressure exceeds the effective colloid osmotic pressure of the plasma.

The magnitudes of the various factors which combine to cause edema in congestive heart failure differ from case to case. Two of the important causes of such edema, namely the increase in the capillary permeability and the fall in the colloid osmotic pressure of the plasma, are also partly responsible for the edema in the nephrotic stage of glomerulonephritis.

AUTHOR.

Barsoum, G. S., and Smirk, F. H.: Observations on the Histamine-Yielding Substance in the Plasma and Red Cells of Normal Human Subjects and of Patients With Congestive Heart Failure. Clin. Sc. 2: 337, 1936.

A. The nature of the histamine-yielding substances in blood.

It was shown by Barsoum and Gaddum that when blood is extracted by the method described in their paper, a substance appears in the extract which has many properties in common with histamine. The evidence that this substance in the extracts is actually histamine appears to be strong and is further supported by our observation that the histamine-like activity of the extracts is destroyed by a preparation containing histaminase. This paper concerns the nature of the mother substance in blood which on extraction by Barsoum and Gaddum's method yields a histamine-like body. The following observations show that H.Y.S. (histamine-yielding substance) has biological properties which bear a striking resemblance to those of histamine and that H.Y.S. may be identical with histamine.

The histamine-yielding substance (H.Y.S.) in normal blood and blood from heart failure cases, as estimated by Barsoum and Gaddum's method, is destroyed by a preparation containing histaminase.

The H.Y.S. is present in human liver and injections of watery extracts of liver produce a fall of blood pressure in anesthetized dogs. The substance which produces this fall of blood pressure is mostly destroyed by a preparation containing histaminase.

Rabbits' cells contain a high concentration of H.Y.S., and laked rabbits' blood, when injected intravenously, causes a fall of blood pressure of the anesthetized dog, and when applied directly to the isolated guinea pig ileum causes it to contract. These histamine-like properties are destroyed by a preparation containing histaminase, and destruction is associated with a decrease in the concentration of H.Y.S., as estimated by Barsoum and Gaddum's method.

It is characteristic of histamine that the exposure of the isolated guinea pig's ileum to high concentrations of histamine desensitizes the ileum to a subsequent dose of histamine but does not desensitize it to other stimulants. It is found that the guinea pig ileum when desensitized to histamine is also desensitized to laked rabbits' blood, which blood fails to cause contraction of the desensitized ileum. Likewise the guinea pig ileum can be desensitized to histamine by the previous application of laked rabbits' blood. The laked rabbits' blood after treatment with a preparation containing histaminase loses its capacity to desensitize the guinea pigs' ileum to histamine and to laked rabbits' blood untreated with the preparation of histaminase.

Equal doses of histamine and of H.Y.S. (as estimated by Barsoum and Gaddum's method) cause equal contractions of the isolated guinea pig ileum and equal falls of blood pressure in anesthetized dogs.

B. The histamine-yielding substance in the blood of congestive heart failure cases.

It was found that in congestive heart failure cases there is an increase in the concentration of H.Y.S. in whole blood, which is due exclusively to the increased concentration of H.Y.S. in the red cells. H.Y.S., when confined within the red cells, fails, however, to produce its usual depressor action upon the blood pressure. Thus the absence of any measurable increase in H.Y.S. in the plasma of heart failure cases seems to explain fully the absence of physiological or symptomatic indications of the excess of histamine in the whole blood of these cases.

The concentrations of H.Y.S. in plasma and in plasma transudates such as edema fluids and pleural fluids are approximately equal. This suggests that the H.Y.S. found in the plasma in vitro is present also in vivo.

The concentration of H.Y.S. in plasma and edema fluid from congestive heart failure cases is within the normal limits. This suggests that the presence of an excess of H.Y.S. in whole blood does not explain the increased permeability of the capillary bed in congestive heart failure.

AUTHOR.

Barsoum, G. S., and Smirk, F. H.: Observations on the Increase in the Concentration of a Histamine-Like Substance in Human Venous Blood During a Period of Reactive Hyperemia. Clin. Sc. 2: 353, 1936.

During reactive hyperemia of the human arm, following a period of complete obstruction to the circulation, there appears in the venous blood an increase in the concentration of a substance which has the biological properties of histamine. It is thought that the liberation of this histamine-like substance during circulatory arrest accounts at least in part for the hyperemia.

Gollwitzer-Meier, Kl.: Observations on the Circulatory Action of Some Analeptics. Klin. Wchnschr. 15: 508, 1936.

It was observed that large doses of coramine can make the normal and insufficient heart in the heart-lung preparation beat more poorly and less efficiently in terms of energy cost. Large doses of cardiazol do not have this detrimental action. In small doses both drugs improve the insufficient heart. They have no action on the coronary blood vessels.

In the intact circulation these drugs increase the venous return to the heart which in turn increases minute-volume flow. The arterial blood pressure rises and hence the coronary flow increases. In cats they cause, by central vagus action, a slowing of the heart.

L. N. K.

Brückner, G.: The Venous Pulse Contour in Silicosis. Deutsches Arch. f. klin. Med. 178: 604, 1936.

It was found that evidence of congestion in the right heart following silicosis manifests itself in the venous pulse. These affect the diastolic waves.

L. N. K.

Kjaergaard, Hans: Roentgenkymography in Diseases of the Heart. Acta med. Scandinav. Supp. 78: 1936.

It is felt that kymography is the future method for x-ray examination of the heart and that it will rank with the other methods of examination as a valuable supplement to auscultation, sphygmomanometry and electrocardiography. But, however valuable the kymography, it must not be overestimated and made the sole basis for the diagnosis, prognosis and therapy—no more than the other methods of examination. The most important basis for the judgment of a cardiac patient is now, as well as before, the clinical observation of what Mackenzie called "the response to effort."

AUTHOR.

Faber, Borge, and Kjaergaard, Hans: Kymographic Studies on the Influence of Brief Muscular Work Upon the Heart Function. Acta med. Scandinav. 89: 537, 1936.

On comparison of the changes in kymographic demonstrations of the heart in young normal individuals before and after brief muscular work, the authors believe that

brief exerting work produces changes in the heart similar to those demonstrable after more protracted work. These changes are increase of the heart rate, increase in the power of the individual contractions associated with a rise of the blood pressure, a diminution of the heart both in systole and in diastole, besides increase in the amplitude of the movements of the different regions of the heart; presumably the last-mentioned condition is the cause of the increased beat volume.

AUTHOR.

Dahm, M., and Meese, J.: Mediastinal Movement in Aortic Aneurysm. Fortsch. a. d. Geb. d. Röntgenstrahlen 53: 625, 1936.

The bronchial stenosis caused by aortic aneurysm is visible by x-ray, and the movements can be shown in the roentgenkymogram. Not all movements are due to bronchial stenosis. Anomalies of the diaphragm and pleural adhesions can also cause this phenomenon.

L. N. K.

Tilk, G. V.: The Relation of the Shadow of the Large Blood Vessels to the Depth of the Chest. Ztschr. f. Kreislaufforsch. 29: 2, 1937.

This study is based on an analysis of twenty-five cases. No relation was found between the x-ray shadow of the great vessels of the heart and the depth of the chest.

L. N. K.

Heckmann, K.: Actinocardiography. Klin. Wchnschr. 15: 757, 1936.

The light intensity of the heart shadow cast on the fluorescent screen by the x-ray machine is recorded by means of a photoelectric cell. The current from the photoelectric cell is amplified and recorded with a mirror galvanometer on moving photosensitive paper. This gives a volume curve of the heart (or other organ). This method shows that the recently developed ionographs are not suitable for volume recording. The method which the author describes gives not only the changes in the intensity of the heart shadow, but also the changes in its size. For this reason displacements of the heart have no effect on the curve.

L. N. K.

Holzmann, M.: Social-Medical Needs for Cardiac Patients. München. med. Wchnschr. No. 20, 812, 1936.

The author points out that while good results often follow hospital care of cardiac patients, one-half the patients return one or more times for further hospital care. He believes, therefore, in the establishment of convalescent and training stations for cardiacs after their release from the hospital and in the better control of these patients after their discharge into an ordinary or restricted existence.

L. N. K.

Korns, Horace Marshall, and Feller, Alto E.: Treatment of Occlusive Arterial Disease of the Extremities by Passive Vascular Exercise: Report of Sixty-Eight Cases. Arch. Int. Med. 59: 705, 1937.

Experience indicates, as does that of many other observers, that if collateral pathways are potentially adequate, passive vascular exercise helps to reestablish the circulation in an extremity which has been deprived of part of its blood supply by obliterative arterial disease.

AUTHOR.

Book Reviews

PASSIVE VASCULAR EXERCISES. By Louis G. Herrmann, A.B., M.D. 288 pages, 80 illustrations, and 4 color plates. Philadelphia, 1936, J. B. Lippincott Company.

This volume represents a timely presentation of the use of one of the most popular of the numerous mechanical devices which are so rapidly being produced in what might be termed as the machine age in medicine.

As the author points out in an instructive historical review, the principle of the use of pressure and suction together or separately in the treatment of vascular diseases is not a new one, having been in use more than 150 years, and in a form not dissimilar from the present in certain respects since 1798. The historical section seems unduly illustrated with modern apparatus including photographs of little significance such as those on pages 59, 63, and 68.

Certain contraindications to the use of the pressure suction apparatus have been noted, such as acute or subacute thrombophlebitis, obliteration of the arteriolar bed, acute infectious processes, and cellulitis. In addition, it is stated that no permanent benefit could be expected in conditions of high grade angiospasm of central origin. With these statements no one appears to differ.

On the other hand, it has been the experience of certain workers that the outstanding results claimed in this volume could not be duplicated with the same degree of success. Even the simple and fundamental observation regarding the elevation of surface temperature (p. 94) following the use of the apparatus has not, in the experience of the reviewer and others, been capable of constant reproduction. In fact, frequently the temperature of the skin has been lower after the treatment than before. This is in part, at least, responsible for the use of artificial hyperthermia as an important adjunct to the treatment. One might then question the relative merits of the two forms of treatment thus incorporated.

Although the reviewer agrees with the author in his belief that the clinical names of these diseases are of slight importance compared with an understanding of their pathological physiology, exception may be taken to the classification of the diseases as listed under the heading Primary Obliterative Arterial Diseases of Extremities (p. 126). Many of the conditions so listed are definitely secondary to external causes and should hardly be termed as primary, i.e., ligation of major artery, gunshot wounds, burns, etc.

Certain workers might question the occurrence of syphilitic thromboarteritis obliterans as a relatively common disease, as would be indicated by the author's series of six cases. The presence of a positive Wassermann test in a patient with arterial disease does not seem sufficient evidence in itself for the diagnosis but needs the further substantiation of the detection of the spirochetes in the walls of the vessels.

A useful chapter on the general management of arterial diseases is somewhat marred by the fact that it is practically confined to favorable reports of work with a number of substances presented in an uncritical manner. Negative and critical results have been published regarding certain of these substances and such data are at least as important in evaluating the true value of a given form of therapy.

The value of the pressure suction therapy is perhaps most widely accepted in the treatment of acute arterial emboli to the extremities. Yet even here the interpreta-

tion of results must be tempered by the fact that many of these cases clear up with the use of general heat, alcohol, etc., that the phenomena of apparent embolism may follow trauma and local phlebitis of an associated vein, which conditions clear up spontaneously, and lastly that a certain percentage of cases with embolism fail to respond even to this apparatus. These different aspects should be more critically evaluated.

In the treatment of frostbite Herrmann reports the good results which have been confirmed elsewhere.

The good results noted in cases of organic arterial disease complicated by infection, especially in diabetics, have not been duplicated, even with the addition of hyperthermia, in the experience of the reviewer and of other workers. In fact, in many such patients the infection appears to be aggravated.

Herrmann has found the machine to be of little value in the treatment of thromboangiitis obliterans, and in this we absolutely concur.

The problem with which workers in the field of diseases of the peripheral vessels are confronted appears to be not whether this and certain other machines will help to improve the circulation and restore these patients to health, but rather, whether the elaborate and expensive equipment will do this more satisfactorily than the *careful* use of the many simple measures which are available, and, if so, how much better? These questions are as yet unanswered in the minds of many careful observers. It must however be realized that our equipment of today in all probability does not represent the ultimate.

This volume may be regarded as a record of a clinical group which has had extensive experience with a rediscovered form of therapy. As such, it is of value for the inclusion of many new findings and as an aid to all others wishing to undertake this therapy.

ESSENTIALS OF ELECTROCARDIOGRAPHY. By Richard Ashman, Ph.D., Professor of Physiology, Louisiana State University Medical Center, and Director of the Heart Station Charity Hospital, and Edgar Hull, M.D., Assistant Professor of Medicine, Louisiana State University Medical Center. 212 pages, price $3.50, New York, 1937, The Macmillan Company.

This book is well printed and amply illustrated. It starts with a brief discussion of the instrument and a very good review of the physiology of the heart muscle. This is presented in a diagrammatic manner which is easy to comprehend, but, because it is diagrammatic, it gives the impression that many details are much more clearly understood than is actually the case. The illustrations throughout the book are accompanied by detailed interpretations of the records. These interpretations are conservative and should be very helpful to one learning to read the electrocardiogram.

One somewhat feels the absence of a presentation of the anatomical features upon which the spreading of the contraction wave must depend. Possibly, however, most of those who read this book may already have this knowledge in their minds.

The order of considering the various waves of the electrocardiogram is logical but the fact that normal and abnormal variations of the waves are considered in the same section leads one sometimes to a consideration of abnormal features in a record, which have not yet been described in their normal aspects. This might make it difficult for a beginner at the first reading of the book, but owing to the clearness and completeness of the descriptions, the second reading should lead to a good understanding of the subject.

The attempt to discuss special electrocardiographic features associated with different etiological types of heart disease leads to a certain amount of repetition.

It has a value to the beginner, however, in showing that electrocardiographic changes are due to myocardial lesions of certain pathological types rather than to the influence of any etiological factor.

The final section on cardiac arrhythmia is sufficiently complete and the illustrations are satisfactory.

THE FUNDAMENTALS OF ELECTROCARDIOGRAPHIC INTERPRETATION. By J. Bailey Carter, M.D., Clinical Instructor, Dept. of Medicine, Rush Medical College, Chicago, Ill. 326 pages, price $4.50, Springfield, Ill., 1937, Charles C. Thomas.

The printing and illustrations are good. The author makes a clear presentation of the origin of the waves of the electrocardiogram and shows many illustrations of its variations. Interpretations beneath these records would be helpful were it not that many of them overaccentuate the abnormality of certain features of the records. This is particularly true in regard to notching and slurring of the QRS group. Many times this is mentioned when very slight in degree and is often made the basis for a statement that myocardial damage is present when it seems likely that most electrocardiographers would disregard its presence. This is especially so in Figures 43, 44, 46 and in several others.

Figure 206, showing a curve commonly found in patients with hypertension, is said to "indicate a serious prognosis." This statement is not yet sufficiently established to be made in so unqualified a manner. Many other statements would not be generally agreed with, such as that "the S-T interval represents the period of electrical balance between cardiac apex and base"; also "all waves and intervals are best studied in Lead II." Pulsus trigeminus is illustrated by a record showing the recurrence of a group of three normal beats and a ventricular premature beat. There are so many statements throughout this book to which exception must be taken that the good features of the book are counteracted by the danger that the beginner will be misled.

THE COURSE OF THE ESOPHAGUS IN HEALTH AND IN DISEASE OF THE HEART AND GREAT VESSELS. By William Evans, M.D., F.R.C.P. Paper, 93 pages, London, 1936, His Majesty's Stationery Office.

The work described in this report was done by Doctor Evans at the London Hospital with the assistance of a grant from the Medical Research Council. The observations are confined to alterations of course and lumenal contour of the esophagus produced by adjacent normal or diseased organs. Abnormality arising in the lumen or wall of the esophagus itself is excluded from the scope of the brochure. Doctor Evans' report, which is profusely illustrated with roentgenograms and drawings, embodies his own studies of living persons and careful dissections of three cadavers, together with numerous citations from the literature. Among American observations cited are those of Rigler, Steel, and Mahaim. Impressions and deviations produced by the aortic arch, left bronchus, left auricle, descending aorta, and enlarged lymph nodes are described in detail. The booklet is comprehensive in its covering of the subject and is valuable to the radiological diagnostician.

INDEX TO VOLUME 13

A

Abbott, Maude E., 254
Abnormality, congenital, of heart, due to defective development of right ventricle associated with tricuspid atresia or hypoplasia, 754*
Abramson, D. I., Katz, L. N., Margolin, S., and Lourie, R., 217
Acceleration, importance of position on ability to withstand, 498*
Aceto-acetic acid, feeding of, production of intimal changes in arteries attempted in rat by, 246*
Acetylcholine, action of, on blood vessels, blood pressure, heart and vasomotor centers, 748*
  injected intraarterially, in sympathectomized subjects, 631*
  intensification by eserine of, upon secretion of adrenalin, 628*
  coronary arteries, reaction of, to, 500*
Acid, production of, in functioning heart under conditions of ischemia and of congestion, 743*
Actinocardiography, 761*
Adamek, G., and Friedländer, E., 758*
Addison's disease, thromboangiitis obliterans and, in same patient, 507*
Age, physiology of, 502*
  relation of, to structure of small arteries and arterioles in skeletal muscle, 246*
  significance of relative duration of systole in healthy persons, 379*
Air chambers, cooling: depth temperature in artificial fevers and, with special reference to cooling effect of circulating blood, 716*
Allen, Edgar V., and Lauderdale, T. L., 384*
—, and McKechnie, R. E., 383*
—, and Norman, I. L., 257
Allergy, idiosyncratic eosinophilic myocarditis, 242*
Allorhythmia, extrasystolic, 749*
Altschule, Mark D., and Blumgart, H. L., 589
Analeptics, circulatory action of, 760*
Andrus, Frank C. 246*
Anemia, anoxemia and, of heart muscle and angina pectoris, 744*
  condition of, acid production in functioning heart under, 743*
  hookworm, heart changes and physiological adjustment in, 550
Aneurysm, aortic, mediastinal movement in, 761*
  arteriovenous, with pronounced electrocardiographic changes, 95
  dissecting, of aorta, 129, 426
  of subclavian artery, cervical rib associated with, 507*
  popliteal, ruptured, demonstration by thorium dioxide arteriography, 127*
  thoracic, symptoms of, persistent hiccoughs as, 624
Angina pectoris, anemia and anoxemia of heart muscle and, 744*
Anoxemia, anemia and, of heart muscle and angina pectoris, 744*
Anxiety, symptom of, and cardiac psychosis, 394
Aorta, abdominal, stenosis, congenital, of, 633
  abnormality of, and heart, use of barium-filled esophagus in x-ray of, 723
  aneurysm, dissecting, of, 129, 426
    mediastinal movement in, 761*
  arch of, right sided, 754*
  studies, chemical and histological, upon, of horse, 502*
  thrombosis of, and coronary arteries with "fibrinoid" lesions, 126*
Aortitis, syphilitic, early, diagnosis of, teleroentgenography in, 297
Arenberg, H., 197
Arrhythmia, asystole, ventricular, effect of, on respiration, 239*
  atrioventricular, with and without retrograde block, 61
  physiological, of heart beat, 123*
Arteries, digital, of normal and hypertensive individuals, 1
  of extremities, sudden occlusion of, 383*
Arteriography, thorium dioxide, demonstration of ruptured popliteal aneurysm, 127*
  thorotrast study of acquired arteriovenous fistula, 247*
  thromboangiitis obliterans in negroes, 511
Arterioles (*see* Artery)
Arteriosclerosis, experimental, inhibition of, by potassium iodide and colloidal silicic acid, 627*
  investigations on, 124*
  human, in relation to cholesterol content of blood serum, 125*
  intima of coronary arteries in, vascularization and hemorrhage of, 127*
  pulmonary, primary, 756*
  rheumatic, pathogenesis of, 756*
Artery, "balloon" of, elasticity of, at different ages in man, 128*
  carotid, exteriorization of, dietary and emotional factors affecting blood pressure of cats, observed by, 238*
  changes in intima of, in rat by prolonged feeding of aceto-acetic acid, 246*
  coronary, arteriosclerotic, intima of, vascularization and hemorrhage of, 127*
    disease of, 254 (book review)
    left, circumflex branch of, blood flow in, of intact dog, 119*
    occlusion, acute impending, diagnosis of, 675
      experimental, hemodynamics of, 647, 664
      radial artery changes in comparison with those of, and other arteries, 757*
    reaction of, to acetylcholine, 500*
    sclerosis of, relation of, to symptoms, 753*
    thrombosis of, acute, and myocardial infarction affecting a patient thirty-one years of age, 741
      and aorta with "fibrinoid" lesions, 126*
      heart failure and other factors in its course and prognosis, 330
      size of heart after, 630*
  denervated, vasomotor tonus of, 380*
  digital, of normal and hypertensive individuals, 1

An asterisk (*) indicates that the reference is an abstract and not an original article.

Artery—Cont'd
disease, occlusive, of, treatment of, of extremity by passive vascular exercise, 761*
of lower extremity, relief of pain by peripheral nerve block in, 246*
human, velocity of blood stream, 249*
mesenteric, superior, embolization of, genesis of intestinal infarction following, 382*
occlusion, complete, of, with involvement of entire small intestine, 126*
mesentery, occlusion of, of arterial and venous origin, 757*
occlusion, acute, of extremities, 126*
of extremities, sudden occlusion of, 383*
peripheral, disease, obstructive, of, treatment of, by intermittent venous occlusion, 247*
importance of, in industrial practice, 507*
pulmonary, bloodless method of measuring pressure in, 504*
calcification, marked, of, 756*
constriction of, by adhesive pericarditis, 470
puncture of, measuring arterial pressure directly by, 377*
radial changes of, in comparison with those of coronary artery and other arteries, 757*
small, structure of, relation of age and hypertension to, in skeletal muscle, 246*
spasm of, in acute venous thrombosis, 247*
subclavian, aneurysm of, cervical rib associated with, 507*
thrombosis, extensive, of, and venous, complicating chronic ulcerative colitis, 125*
unopened, measurement of velocity of blood flow in, 128*
wall, living, elasticity of, action of musculature on, 756*
Arthritis, endocarditis, thrombotic nonbacterial, associated with, 243*
Ashmun, Richard, 763
Asphyxia, reduction in circulation through hand resulting from, 251*
Athletics, power and hypertrophy of heart following, 630*
Atherosclerosis (*see* Arteriosclerosis)
Autohemagglutination, reversible, with peripheral vascular symptoms, 386*

B

Babey, Andrew, 228
Bacal, H. L., and Struthers, R. R., 124*
Baker, Lyle A., McNamara, W. L., and Ducey, E. F., 108
Baldes, Edward J., Essex, H. E., Herrick, J. F., and Mann, F. C., 119*
Balloon, central position of, in circulation, 248*
Balmis, J., Vires, J., and May, P., 386*
Bansi, 497*
Bargen, J. Arnold, and Barker, N. W., 125*
Barker, Nelson W., and Bargen, J. A., 125*
Barsoum, G. S., and Smirk, F. H., 759*, 760*
Barto, A., and Lanari, A., 631*
Bärtschi, W., 500*
Battro, A., and Braun-Menendez, E. B., 252*
—, —, and Orias, O., 628*
Baumann, E., 753*
Bay, Emmett B., 241*
Bedford, D. Evan, and Parkinson, J., 754*
Bellet, Samuel, and Dyer, W. W., 72
Benzedrine, orthostatic hypotension, treated with, 114
Berger, A. A., 440
Berger, Adolph R., and Clark, E., 124*
Beriberi, pernicious, acute form of, and treatment by intravenous administration of vitamin B_1, 580
Betts, W., Roesler, H., and Gifford, U. G., 426
Bischoff, 751*
Bishop, G. H., and Gilson, A. S., 629*
Block, C., 749*
—, and Pick, A., 749*
Blood, arterial, oxygen and carbon dioxide content of, and venous, of normal subjects, 504*
saturation of, in man, 498*
circulating, cooling effect of, depth temperature in artificial fevers and cooling air chambers with special reference to, 746*
flow of, in circumflex branch of left coronary artery of intact dog, 119*
of kidneys studied with Rein stromuhr, 498*
peripheral, in surgical shock, 251*
regulation of, circulatory and chemical, during and after exercise, 496*
velocity of, and related aspects of circulation in normal pregnant women, 251*
in human arteries, 249*
in unopened arteries, 128*
volume of, in clinical cases of surgical shock, 251*
plasma and total blood volume, relation to venous pressure, blood velocity, physical measurements, age, and sex in 90 normal humans, 748*
pressure, acetylcholine, action of, on, 748*
action of deep breathing on, 380*
arterial, dome of, influence of musculature of blood vessels in, 376*
measuring directly by arterial puncture, 377*
bloodless method of, in pulmonary artery, 504*
bloodless method of measuring, in pulmonary artery, 504*
dietary and emotional factors affecting, observed by exteriorization of carotid artery, 238*
recording with electrical transmission, 379*
rise of, following strong electrical current, 499*
systemic, influence of splanchnic region on, 505*
variations of, in diseases of hypophysis, 245*
venous, estimation, direct, value of, in ambulatory cardiac patients, 440
measurements, comparative value of, in femoral and cubital veins, 431
protein, changes, specific and nonspecific, in, during acute rheumatism with carditis, 754*
venous, human, increase in concentration of histamine-like substance in, during period of reactive hyperemia, 760*
oxygen and carbon dioxide content of, and arterial, of normal subjects, 504*
vessels, acetylcholine, action of, on, 748*
cerebral, action of histamine upon, 631*
innervation in man, 247*
complication in cervical rib, 508*
of polycythemia, 257
dilatation and constriction of, in response to warming and cooling body, 508*

Blood vessels—Cont'd
extremities, embolectomy of, 252*
incidence and significance of, in normal and abnormal heart valves, 7
large, shadow of, relation of, to depth of chest, 761*
musculature, influence of, on arterial pressure dome, 376*
reactions of skin to active principles of body, 499*
relation of living mammalian lymphatic capillaries to, 376*
renal reaction of, during course of regulatory events in systemic circulation, 385*
significance of, in human heart valves, 275
skeletal muscle, nerve plexus of, vasomotor interference in, induced by vasodilator substance following hyperemia, 748*
sympathectomized, control of, by sympathomimetic hormones and relation to surgical treatment of patients with Raynaud's disease, 380*
volume, clinical application of method employing blue azo dye, "Evans blue," and the spectrophotometer, 747*
studies, relation of plasma and total blood volume to venous pressure, blood velocity rate, physical measurements, age and sex in 90 normal humans, 748*
total, relation of plasma and, to venous pressure, blood velocity rate, physical measurements, age, and sex in 90 normal humans, 748*
Blue azo dye, "Evans blue," and spectrophotometer, clinical blood volume studies using, 747*
Blumgart, Herrman L., and Altschule, M. D., 589
Böger, A., and Wezler, K., 128*, 248*, 376*, 756*
Böhme, 497*
Bohnenkamp, 495*
Bohning, A., Katz, L. N., Gutman, L., Jochim, K., Korey, H., Ocko, F., and Robinow, M., 17
Borg, Joseph F., and Johnson, C. E., 88
von Borisdorff, B., 377*
Brams, William A., and Golden, J. S., 207
Braun-Menendez, E., and Battro, A., 252*
—, —, and Orias, O., 628*
Breathing, deep, action of, on blood pressure, 380*
Brill, I. C., 175
Broemser, 496*
Bronk, D. W., Ferguson, L. K., Margaria, R., and Solandt, D. Y., 119*
Brouha, L., Cannon, W. B., and Dill, D. B., 501*
Brown, George E., and Fatherree, T. J., 1
Bruch, H., 631*
Brückner, G., 377*, 760*
Bruenn, Howard G., 413
Bruger, Maurice, Short, J. J., and Jaffe, L., 246*
Brüner, H., 379*
Busch, P., 245*

C

Cannon, W. B., Brouha, L., and Dill, D. B., 501*
Capillaries, lymphatic, mammalian, living, observations on, 376*
Capillary, supply of, in normal and hypertrophied hearts of rabbits, 744*
Carbaminocholinchloride, action of, upon circulatory and gastrointestinal system, 239*
Carbon dioxide and oxygen content of arterial and venous blood of normal subjects, 504*
Carcinoma of duodenum, cardiac rupture associated with metastases to heart from, 108
Cardiovascular system, action of carbaminocholinchloride upon, and gastrointestinal system, 239*
activity of, registration and interpretation of, in normal infant, 122*, 244*
reactions induced by electrical stimulation of cerebral cortex, 238*
syphilis of, 297
value of graphic methods in diagnosis in, 241*
Carditis, rheumatic, high blood sedimentation rate in, 245*
Carleton, H. M., and Liddell, E. G., 238
Carmichael, E. A., Uprus, V., and Gaylor, J. B., 508*
Carotid sinus reflex in man, 239*
Carter, J. Bailey, 764
Cassisnis, 495*
Castleman, Benjamin, Glendy, R. E., and White, P. D., 129
Centenera, D., and Springorum, W., 498*
Cerebral vascular innervation in man, 247*
Cerebrum, cortex of, cardiovascular reactions induced by electrical stimulation of, 238*
Chasis, Herbert, Clark, E., and Graef, I., 126*
de Châtel, A., 752*
Chest, closed: hemodynamics in experimental coronary occlusion, 664
depth of, relation of shadow of large blood vessels to, 761*
open: hemodynamics in experimental coronary occlusion, 647
Chester, William, 492
Children, electrocardiographic alterations produced by typhoid fever in, 123*
heart disease in, 36
rheumatic infections in, sedimentation rate and Schilling count, 124*
Chisholm, Donald R., 362
Cholesterol, content of, of blood serum, human, atherosclerosis in relation to, 125*
Circulation, action of, of analeptics, 760*
collapse of, nature of, induced by sodium nitrite, 502*
orthostatic, in man, following exercise, 495*
coronary, reactions of, criterion of, validity of coronary sinus outflow, 743*
dye injection method for studying, 250*
dynamics of, in tricuspid stenosis, 589
in sport, 385*
insufficiency of, and oxygen deficiency, 749*
peripheral, elevation of rectal temperature following mechanical obstruction to, 542
regulation of, mechanical basis of, 385*
studies on, in pregnancy, 251*
systemic, course of regulatory events in, reaction of renal vessels during, 385*
Clark, Eleanor L., and Clark, E. R., 376*
Clark, Eliot R., and Clark, E. L., 376*
Clark, Eugene, and Berger, A. R., 124*
—, Graef, I., and Chasis, H., 126*
Coburn, Alvin F., 754,* 755*
—, and Kapp, E. M., 245*
—, and Moore, L. V., 747*
Cochems, K. D., and Kemp, J. E., 297
Cohen, Mandel E., and Thomson, K. J., 251*
Cold, reduction in circulation through hand resulting from, 251*
Colitis, ulcerative, chronic, extensive arterial and venous thrombosis complicating, 125*

Collens, William S., and Wilensky, N. D., 126,* 247*
Coma, diabetic, electrocardiogram during and after emergence from, 72
Concretion, pericardial, 753*
Conduction, auriculoventricular, impaired mechanism of, in acute rheumatic fever, 413
system, action of extracts of bulbus scillae and scillaren on, and refractory phase of frog's heart, 745*
Congestion, condition of, acid production in functioning heart under, 743*
Cook, Hunter S., and Sappington, S. W., 757*
Cossio, P., Lascalea, M., and Fongi, E. G., 752*
Cutts, Frank B., 451

D

Dack, S., Master, A. M., and Jaffe, H. L., 330
Dahm, M., and Meese, J., 761*
David, F., and Siedek, H., 504*
Death, sudden, pathology and pharmacology of cardiac syncope and, 240*
Diabetes, coma of, electrocardiogram during and after emergence from, 72
Dicker, E., 631*
Dieckhoff, Josef, 121*
Digillo, Victor A., and Wolffe, J. B., 378*
Digitalis, action of, and indications for use in man and animals, 253*
administration of, in normal adults, electrocardiographic changes in, 129*
effect of, on hearts with insufficient aortic valves with and without hypertrophy, in heart-lung preparations, 121*
intoxication by, action of magnesium on ventricular ectopic rhythms occurring in, 749*
Digitoxin, sensitivity to, of hearts with insufficient valves with and without hypertrophy, 121*
Dill, D. B., Brouha, L., and Cannon, W. B., 501*
Diphtheria, alteration in heart in, 379*
severe, heart fifteen to twenty years after, 534
toxin of, dynamic effect of, acute experimental poisoning of heart with, 693
Dogs, training of, 495*
Domenech, F., and Marañón, 245*
Donal, John S., Jr., and Gamble, C. J., 120*
Dorsey, John L., 128*
Doryl (*see* Carbaminocholinchloride)
Dowling, Alexander S., Wearn, J. T., Moritz, A. R., Haskin, G. E., Hudson, C. L., and Orgain, E. S., 7
Dragstedt, Carl A., and Mead, F. B., 500*
Ducey, E. F., McNamara, W. L., and Baker, L. A., 108
Dye, injection method for study of circulation, 250*
Dyer, W. Wallace, and Bellet, S., 72

E

Echaque, E. Soaje, 123*
Eckey, P., 751*
Edeiken, Joseph, and Wood, F. C., 387
Edema, causes of, in congestive heart failure, 758*
Edens, E., 253*
Einthoven equilateral triangle and null potential electrode, 629*
Eldbloom, L. E., 501*
Electrocardiogram, alterations in, produced by typhoid fever in children, 123*
axis deviation, left, in dextroposition of heart showing, 104
beriberi, acute pernicious form of, and treatment by intravenous administration of vitamin B_1, 580
cardiac work and, 495*
changes in, in normal adults following digitalis administration, 129
pathological, in S-T segment and T-waves of, on basis of direct leads, 752*
in arteriovenous aneurysm, 95
diphasic QRS type of, in congenital heart disease, 202
during and after emergence from diabetic coma, 72
findings in heart-block, 751*
genesis of, concerning new concept of, 17
in beriberi, acute pernicious form of, 580
in hypertension, Lead IV, 308
in lung embolism, 750*
in malaria, 505*
in nephritis, acute, 751*
interpretation of, 256 (book review)
leads, midaxillary, of, in myocardial infarction, 701
notching in main deflection of, 629*
of myxedema heart, 123*
of specialized heart muscle, 630*
recorded, form of, effect of remote leads upon, 629*
time relation between heart activity and, 749*
variations in form of experimental ventricular ectopic beats induced in monkey and dog, 217
unit, mobile, for recording simultaneously heart sound, pulse tracing and, 731
Electrocardiographs, various, efficiency of, 750*
Electrocardiography, clinical, emphysema, 750*
use of chest leads in, 183
essentials of, 763 (book review)
fundamentals of, interpretations (book review) 764
Electrodes, null potential, and Einthoven equilateral triangle, 629*
Eliaser, Maurice, Jr., and Sampson, J. J., 675
Embolectomy of vessels of extremities, 252*
Embolism, lectures on, 255 (book review)
lung, electrocardiogram in 750*
pulmonary, experimental and infarction, 240*
relationship of hemorrhagic extravasations into leaflets of atrioventricular valves to, 124*
Embolization of superior mesenteric artery, genesis of intestinal infarction following, 382*
Emphysema, electrocardiographic observations in, 750*
Endocarditis, bacterial, subacute, 753*
patent ductus botalli with, and recovery, 492
recovery in, 753*
lenta (*see* Endocarditis, bacterial)
streptococcus viridans, subacute, failure of human immune transfusion and serum therapy, 619
thrombotic, nonbacterial, associated with prolonged fever, arthritis, inflammation of serous membranes and widespread vascular lesions, 243*
purpura thrombocytopenic acute, 243*

Endocarditis, thrombotic, nonbacterial—Cont'd
classification and general description, 242*
Epinephrine (see Suprarenal substance)
Erythema nodosum, induction, experimental, of, 747*
pathogenesis of, and tuberculosis, streptococcus infection and rheumatic fever, 746*
Erythromelalgia, case of, 386*
observations on, and symptomatic relief of, 483
Eserine, intensification by, of action of acetylcholine upon secretion of adrenalin, 628*
Esophagus, barium-filled, use of, in x-ray studies of abnormalities of heart and aorta, 723
course of, in health and in disease of heart and great vessels, 764*
displacement of, by cardiac lesions other than mitral stenosis, 228
Esser, C., 252*
Essex, Hiram E., Herrick, J. F., Baldes, E. J., and Mann, F. C., 119*
Euphylin, heart poisoned by, lactic acid metabolism of spontaneously failing heart and, 627*
Evans, William, 764*
Evans, William A., Jr., and Gibson, J. G., 747,* 748*
Exercise, circulatory and chemical blood regulation during and after, 496*
orthostatic circulatory collapse in man following, 495*
vascular, passive, 762 (book review)
treatment of occlusive arterial disease of extremities by, 761*

F

Faber, Borge, and Kjaergaard, H., 760*
Fatherree, Thomas J., and Brown, G. E., 1
Fear, reduction in circulation through hand resulting from, 251*
Feller, Alto E., and Korns, H. M., 761*
Ferguson, L. K., Bronk, D. W., Margaria, R., and Solandt, D. Y., 119*
Ferris, Eugene B., Jr., and Wilkins, R. W., 431
Fever, artificial, depth temperature in, and cooling air chambers with special reference to cooling effect of circulating blood, 746*
prolonged, thrombotic nonbacterial endocarditis associated with, 243*
Fibrillation, auricular, with congestive heart failure and no other evidence of organic heart disease, 175
ventricular, transient, 751*
Fibrinoid lesion, thrombosis of aorta and coronary arteries with, 126*
Fibrosarcoma, primary, of heart, 736
Fidler, R. S., Kissane, R. W., and Koons, R. A., 736
Findlay, F. M., 246*
Fischer, R., 377*
Fistula, arteriovenous, acquired; study by thorotrast arteriography, 247*
Flint, E. R., 508*
Fluid, extravascular administration of, transient hypertension following, 386*
Fongi, E. G., Cossio, P., and Lascalea, M., 752*
Freeman, Norman E., Shaw, J. L., and Snyder, J. C., 251*
Frey, H., 750*
Friedberg, Charles K., and Gross, L., 242,* 243*
—, and Sohval, A. R., 599
—, Gross, L., and Wallach, K., 243*
Friedländer, E., and Adamek, G., 758*

G

Gaddas, S. F., Jochim, K., and Marquis, H., 731
Gamble, Clarence J., and Donal, J. S., Jr., 120*
Gangrene from blocking of veins, 382*
Gastrointestinal system: action of carbaminocholinchloride upon circulatory system and, 239*
Gauss, G., and Schlomka, G., 750*
Gay, L. K., and Hardesty, J. T., 250*
Gaylor, J. B., Uprus, V., and Carmichael, E. A., 508*
Geill, T., and Secher, K., 757*
German physiological society, 498*
Gerstner, H., 499*
Gibson, John G., and Evans, W. A., Jr., 747,* 748*
Gifford, U. G., Roesler, H., and Betts, W., 426
Gilson, A. S., and Bishop, G. H., 629*
Girones, L., Knoll, W., and Goerke, W., 749*
Glendy, Robert Earle, Castleman, B., and White, P. D., 129
Gley, P., and Vaquez, H., 256
Glomus tumor, 126*
Goerke, W., Knoll, W., and Girones, L., 749*
Goiter, exophthalmic, occurrence and pathogenesis of cardiac hypertrophy in, 599
Goldberg, M., and Rothberger, C. J., 630*
Golden, J. S., and Brams, W. A., 207
Golden, Sherman E., Thompson, W. P., and White, P. D., 534
Golder, W., 629*
Goldsmith, Grace, 746*
Gollwitzer-Meier, Kl., 760*
Gotsey, T., 748*
—, Luchen, B., and Simmendinger, W., 505*
Gottdenker, F., and Rothberger, C. J., 627*
Gouley, Benjamin A., 470
Graef, Irving, Clark, E., and Chasis, H., 126*
Graves' disease (see Goiter, exophthalmic)
Green, H. D., and Hoff, E. C., 238*
Greenberg, Max M., and Lenore, R. M., 743*
Griffith, J. Q., Jr., Jeffers, W. A., and Lindauer, M. A., 380*
Gross, Louis, 275
—, and Friedberg, C. K., 242,* 243*
—, —, and Wallach, K., 243*
—, Mendlowitz, M., and Schauer, G., 647, 664
—, and Sohval, A. R., 242*
Grosse-Brockhoff, F., Schneider, M., and Schoedel, W., 748*
Gutman, J., Katz, L. N., Bohnen, A., Jochim, K., Korey, H., Ocko, F., and Robinow, M., 17
Gutzul, R., 382*

H

Halbsgut, A., 745*
Hardesty, J. T., and Gay, L. K., 250*
Harkins, Henry N., 757*
Hartmann, H., Orskov, S. L., and Rein, H., 385*
Hartog, H. A. Ph., and van Nieuwenhuizen, C. L. C., 308
Hashimoto, Hirotoshi, 580
Haskin, Grace E., Wearn, J. T., Moritz, A. R., Dowling, A. S., Hudson, C. L., and Orgain, E. S., 7
Haynes, Florence W., Weiss, S., and Wilkins, R. W., 503*
Heart, abnormality of, and aorta, use of barium-filled esophagus in x-ray of, 723

Heart, abnormality—Cont'd
congenital, patent ductus botalli, with subacute bacterial endocarditis and recovery, 492
clinical and pathological findings in, due to defective development of right ventricle associated with tricuspid atresia and hypoplasia, 754*
Heart, acetylcholine, action of, on, 748*
action of, time relation between, and electrocardiogram, 241*
embryonic, genesis of, on basis of hydraulic tube phenomenon, 744*
activity of, time relation between electrocardiogram and, 749*
after severe diphtheria, fifteen to twenty years later, 534
apex of, kymographic appearance of, in marked dilatation, 252*
arrhythmia (*see* Heart, mechanism of)
beat, apex of, movements of lower lung margin and, on lying down and sitting up, 748*
physiological irregularities of, 123*
capacity of, for work, with insufficient aortic valves with and without hypertrophy in heart-lung preparations and effect of digitalization, 121*
changes in hookworm anemia and physiological adjustment, 550
contraction of, lapse of, as affected by intrathoracic function, 120*
ectopic, of, experimental ventricular, induced in monkey and dog, variations in electrocardiographic form of, 217
ventricular, of, asynchronism of, in bundle-branch block, 628*
development of, physical methods of investigating, 241*
dextroposition of, showing left axis deviation in electrocardiogram, 104
dilatation, marked, of, kymographic appearance of cardiac apex in, 252*
diphtheritic alterations of, 379*
disease of, among seamen, 197
congenital, of, atlas of, 254 (book review)
diphasic QRS type of electrocardiogram in, 202
course of esophagus in, 764*
evidence of, orthodiagraphic study of college students without, 387
in children, 36
organic, auricular fibrillation with congestive failure and no other evidence of, 175
patients with, socio-medical needs for, 761*
ambulatory, with, value of direct venous pressure estimation in, 440
tolerance of, for various recumbent positions, 745*
pulmonary, occult, 501*
rheumatic, of, 36
age of onset of, 36
high blood sedimentation rate in, 245*
peripheral veins in, 498*
recurrence of, 36
specific and nonspecific changes in blood protein during, 754*
roentgen kymography, 760*
vessels and, 509 (book review)
enlargement of, 124*
extreme of, 207
failure of, investigation of, in course and prognosis of coronary thrombosis, 330
spontaneous, lactic acid metabolism of, and heart poisoned with
Heart failure—Cont'd
NaF monoiodoacetic acid and with euphylin, 627*
congestive, auricular fibrillation with, and no other evidence of heart disease, 175
causes of edema in, 758*
patients with, histamine-yielding substance in plasma and red cells of normal human subjects and, 759*
fibrosarcoma, primary, of, 736
field, electrical, of 629*
function of, kymographic studies on influence of brief muscular work upon, 760*
measure of, 377*
functioning, acid production in, under conditions of ischemia and of congestion, 743*
human, systolic suction, 498*
hypertrophy of, capillary supply in normal heart and, of rabbits, 744*
and power following athletics, 630*
occurrence and pathogenesis of, in Graves' disease, 599
work of, in, 687
irritability of, changes in, following systole, 499*
lesions of, displacement of esophagus by, other than mitral stenosis, 228
organic, of, 255 (book review)
measurements of, 495*
mechanism of, allorhythmia, extrasystolic, 749*
arrhythmias following mental and physical trauma, 750*
autonomic auricular rhythm, 749*
impaired auriculoventricular conduction in acute rheumatic fever, 413
transition between normal sinus rhythm, ventricular escape, A-V nodal rhythm, and A-V dissociation, 451
ventricular ectopic rhythm, action of magnesium on, occurring in digitalis intoxication, 749*
metabolism, meaning of, for respiration and, 496*
metastases to, from carcinoma of duodenum, cardiac rupture associated with, 108
muscle, anemia and anoxemia of, and angina pectoris, 744*
disease, undecompensated, medicinal therapy in, 252*
specialized, electrocardiograms of, 630*
myxedema, electrocardiogram, 123*
output of, in man, 120*
in polycythemia vera, 746*
poisoning, effect of acute experimental, with diphtheria toxin, 693
with NaF, monoiodoacetic acid, and with euphylin, lactic acid metabolism of spontaneously failing heart, 627*
psychosis of, and symptoms of anxiety, 394
rate of sympathectomized dog in rest and exercise, 501*
revival of, from transient ventricular fibrillation, 751*
rhythmicity and conductivity of, unusual effects of small doses of strophanthin on, and its relation to parasystole, 751*
rupture of, associated with metastases to heart from carcinoma of duodenum, 108
size of, after coronary thrombosis, 630*
sounds of, registration and reproduction of, by "phototones," 241*
unit, mobile, for recording simultaneously pulse tracing and electrocardiograms, 731

Heart—Cont'd
state of, in obesity, 757*
following introduction of radioactive substances into organism, 376*
sympathetic centers of, activity of, 119*
syncope of, pathology and pharmacology of, and sudden death, 240*
valves of human, significance of blood vessels in, 275
volume, minute, of, in intact animal following adrenalin, 499*
work and, 499*
work of, and electrocardiogram, 495*
and volume, 499*
metabolism and limits of, 495*
Heart-block, atrioventricular, complete, radiokymography, 252*
bundle-branch, asynchronism of ventricular contraction in, 628*
atypical, concerning, 750*
retrograde, atrioventricular rhythm with and without, 61
roentgen kymographic and electrocardiographic findings, 751*
Heckmann, K., 761*
Hemodynamic studies in coronary experimental occlusion, 647, 661
Hemorrhage, extravasations into leaflets of atrioventricular valves, 124*
Herbst, R., and Manigold, K., 749*
Hermann, H., Jourdain, F., Morin, G., and Vial, J., 628*
Hermann, K., 753*
Herrick, J. F., Essex, H. E., Baldes, E. J., and Mann, F. C., 119*
Herrmann, Louis G., 762
Hiccoughs, persistent, as sole symptom of thoracic aneurysm, 624
Hinshaw, H. Corwin, and Smith, H. L., 741
Histamine, action of, upon blood vessels of brain, 631*
Histamine-like substance, increase in concentration of, in human venous blood during period of reactive hyperemia, 760*
Histamine-yielding substance, in plasma and red cells of normal human subjects and of patients with congestive heart failure, 759*
Hochrein, 495*
Hochrein, M., and Matthes, K., 385*
Hoff, E. C., and Green, H. D., 238*
Hoff, H., and Pichler, E., 249*
Hoffmann, J., and Kohan, B., 505*
Holzlöhner, E., 498*
Holzmann, M., 761*
Hormones, sympathomimetic, control of sympathectomized blood vessels and relation to surgical treatment of patients with Raynaud's disease, 380*
Howes, E. L., and Lindskog, G. E., 507*
Hudson, Charles L., Wearn, J. T., Moritz, A. R., Dowling, A. S., Haskin, G. E., and Orgain, E. S., 7
Hunt, John H., 383*
Hyperemia, reactive, period of, increase in contraction of histamine-like substance in human venous blood during, 760*
vasomotor interference in nerve plexus of skeletal muscle vessels induced by vasodilator substance following, 748*
Hypertension, arterial, mechanism of, in acute nephritis, 756*
arterioles, digital, of normals and individuals with, 1
arteriosclerotic, "pale," 497*
electrocardiogram in, Lead IV, 308
essential, urine of patients with, presence of prolanlike substance in, 631*
eyeground examination, value of, in, and in renal disease, 496,* 497*
following extirpation of cardiac pressor-receptive nerves, 627*
Hypertension—Cont'd
menopause and, 245*
obesity and, 757*
"red," relation of action of musculature on elasticity of living arterial wall to, 756*
relation of, to structure of small arteries and arterioles in skeletal muscle, 246*
surgical approach, 246*
transient, in rats, following extravascular administration of fluid, 380*
use of pancreatic extract in treatment of, 378*
Hypophysis, disease of, variation of blood pressure in, 245*
Hypotension, orthostatic, treated with benzedrine, 114

I

Infant, normal, cardiovascular activity, registration and interpretation of, in, 244*
registration and interpretation of cardiovascular activity in, 122*
Infarct, intestinal, genesis of, following embolization of superior mesenteric artery, 382*
myocardial, acute coronary thrombosis and, affecting a patient thirty-one years of age, 741
midaxillary leads of electrocardiogram in, 701
pulmonary, experimental, and embolism, 240*
Infection, streptococcal, erythema nodosum, pathogenesis and, 746*
Intestine, infarction of, genesis of, following embolization of superior mesenteric artery, 382*
small, entire, involvement of, complete occlusion of superior mesenteric artery, 126*
Ischemia (*see* Anemia)

J

Jaffe, H. L., Master, A. M., and Dack, S., 330
Jaffe, Louis, Short, J. J., and Bruger, M., 246*
Jeffers, W. A., Griffith, J. Q., Jr., and Lindauer, M. A., 380*
Jellinek, E. M., and Looney, J. M., 504*
Jirka, Frank J., and Scuderi, C. S., 126*
Jobling, James W., and Meeker, D. R., 124*
Jochim, K., Gaddas, S. F., and Marquis, H., 731
—, Katz, L. N., Bohning, A., Gutman, I., Korey, H., Ocko, F., and Robinow, M., 17
Johnson, C. E., and Borg, J. F., 88
Johnson, J. Raymond, and Wiggers, C. J., 743*
Johnson, Victor, and Katz, L. N., 256
Jourdain, F., Hermann, H., Morin, G., and Vial, J., 628*

K

Kahlson and Mertens, O., 499*
Kapp, E. M., and Coburn, A. F., 245*
Katz, L. N., Abramson, D. I., Margolin, S., and Lourie, R., 217
—, Bohning, A., Gutman, I., Jochim, K., Korey, H., Ocko, F., and Robinow, M., 17
—, and Johnson, V., 256
—, and Wachtel, H., 202
—, Witt, D. B., and Lindner, E., 693
Kayser, G., and Weber, A., 241*
Kemp, Jarold E., and Cochems, K. D., 297
Kenenhcf, W. T., and Kohl, H., 502*
Key, Eimar, 252*

Kidney disease, eyeground examination, value of, in, and hypertension, 496,* 497*
Kilgore, Eugene S., 619
Kinsman, J. Murray, and Moore, J. W., 250*
Kirch, E., 630*
van Kiss, P., 379*
Kissane, R. W., Fidler, R. S., and Koons, R. A., 736
Kjaergaard, Hans, 760*
—, and Faber, B., 760*
Knoll, 495*
Knoll, W., Girones, L., and Goerke, W., 749*
Kohan, B., and Hoffmann, J., 505*
Kohl, H., and Kenenhof, W. T., 502*
Koons, R. A., Fidler, R. S., and Kissane, R. W., 736
Korey, H., Katz, L. N., Bohning, A., Gutman, I., Jochim, K., Ocko, F., and Robinow, M., 17
Korns, Horace Marshall, and Feller, A. E., 761*
—, and Randall, W. L., 114
Kraiss, H., 753*
Kramer, Kurt, 128*
Krebs, A., 376*
Kreuzfuchs, S., 501*
Kroetz, 496,* 498*
Kymographic studies on influence of brief muscular work upon heart function, 760*

L

Lactic acid metabolism of spontaneously failing heart and in heart poisoned with NaF, monoiodoacetic acid, and euphylin, 627*
Lanari, A., and Barto, A., 631*
Landé, Kurt E., and Sperry, W. M., 125*
Langendorf, R., and Pick, A., 750,* 751*
Larsen, Kaj, Neukirch, F., and Nielsen, N. A., 163
Lascalea, M., Cossio, P., and Fongi, E. G., 752*
Lauderdale, T. L., and Allen, E. V., 384*
Lazarus, Joseph A., 126*
Lead IV, electrocardiogram in hypertension, 308
Leads, chest, use of, in clinical electrocardiography, 183
direct, analysis of pathological changes in S-T segment and T-waves of electrocardiogram on basis of, 752*
midaxillary, of electrocardiogram in myocardial infarction, 701
remote, effect of, upon form of recorded electrocardiogram, 629*
Levy, Robert L., 254
Liddell, E. G., and Carleton, H. M., 238*
Lindauer, M. A., Griffith, J. Q., Jr., and Jeffers, W. A., 380*
Lindner, E., Witt, D. B., and Katz, L. N., 693
Lindskog, G. E., and Howes, E. L., 507*
Lingg, Claire, Roth, I. R., and Whittemore, A., 36
Loeffler, Louis, 382*
Looney, J. M., and Jellinek, E. M., 504*
Lourie, R., Abramson, D. I., Katz, L. N., and Margolin, S., 217
Loewenberg, S. A., and March, H. C., 624
Lucken, B., Gotsev, T., and Simmendinger, W., 505*
—, and Schütz, E., 499*
Lung, disease of, changes in form and size of heart in, 238*
embolism of, electrocardiogram in, 750*
lower margin of, movements of, and apex beat, on lying down and sitting up, 748*
sclerosis of, changes in form and size of heart in, 238*
Lutembacher, R., 255

M

McCombs, Robert P., and McElroy, J. S., 386*
McDonald, C. H., 687
McElroy, James S., and McCombs, R. P., 386*
McKechnie, R. E., and Allen, E. V., 383*
McNamara, W. L., Ducey, E. F., and Baker, L. A., 108
Magnesium, action of, on strophanthin and barium tachycardia, 751*
action of, on ventricular ectopic rhythms occurring in digitalis intoxication, 749*
Malaria, electrocardiographic observations in, 505*
Malikiosis, X., and Matthes, K., 249*
Manigold, K., and Herbst, R., 749*
Mann, Frank C., Essex, H. E., Herrick, J. F., and Baldes, E. J., 119*
Marañón, G., and Domenech, F., 245*
March, H. C., and Loewenberg, S. A., 624
Marcu, J., 744*
Margaria, R., Bronk, D. W., Ferguson, L. K., and Solandt, D. Y., 119*
Margolin, S., Abramson, D. I., Katz, L. N., and Lourie, R., 217
Marquis, H., Jochim, K., and Gaddas, S. F., 731
Master, A. M., Dack, S., and Jaffe, H. L., 330
Matteff, 495*
Matthes, K., 498*
—, and Hochrein, M., 385*
—, and Malikiosis, X., 249*
May, P., Vires, J., and Balmis, J., 386*
Maycock, W. d'A., 633
Mead, Franklin B., and Dragstedt, C. A., 500*
Mediastinum, movement of, in aortic aneurysm, 761*
Meeker, Dorothy R., and Jobling, J. W., 124*
Meese, J., and Dahm, M., 761*
Mendlowitz, Milton, Gross, L., and Schauer, G., 647, 664
Menopause, hypertension and, 245*
Mertens, O., and Kahlens, 499*
Misske, B., 123*
Molz, B., 629*
Monoiodoacetic acid, heart poisoned by, lactic acid metabolism of spontaneously failing heart and, 627*
Moore, John W., and Kinsman, J. M., 250*
Moore, Lucile V., and Coburn, A. F., 747*
Moore, Robert M., and Greenberg, M. M., 743*
Morawitz, P., 252*
Morin, G., Hermann, H., Jourdain, F., and Vial, J., 628*
Moritz, Alan R., Wearn, J. T., Dowling, A. S., Haskin, G. E., Hudson, C. L., and Orgain, E. S., 7
Mufson, Isidor, 483
Müller, A., 385*
Muller, E. A., 499*
Muller, K., and Sunder-Plassmann, P., 506*
Mundy, Caril S., and Steinberg, B., 240*
Murmur, cardiac, basal systolic, trigonoidation of semilunar valves and relation to, 362
Muscle, skeletal, active, work and blood flow of, action of vasodilator substances on, 744*
arteries and arterioles, small, in, relation of age and hypertension to, 246*
Myocarditis, eosinophilic, idiosyncratic allergic disease, 242*
Myocardium, infarction of, acute coronary thrombosis and, affecting a patient thirty-one years of age, 741

Myocardium, infarction of, midaxillary leads of electrocardiogram in, 701
tonsillitis and, 378*
Myxedema, electrocardiogram of heart in, 123*

N

Nathanson, M. H., 240*
Nehrkorn, O., and Weicker, B., 378*
Negroes, thromboangiitis obliterans in, 511
Nephritis, acute, electrocardiogram in, 751*
mechanism of arterial hypertension, 756*
Nerve, cardiac, pressor-receptive, extirpation of, hypertension following, 627*
peripheral, block of, relief of pain by, in arterial disease of lower extremity, 246*
plexus, vasomotor interference in, of skeletal muscle vessels induced by vasodilator substance following hyperemia, 748*
Neslin, W., 749*
Neukirch, Fritz, Larsen, K., and Nielsen, N. A., 163
Neurovegetative-hormone system, Raynaud's disease and, 506*
Nicole, R., 247*
Nielsen, Niels A., Larsen, K., and Neukirch, F., 163
van Nieuwenhuizen, C. L. C., and Hartog, H. A. Ph., 308
Norman, Irvin L., and Allen, E. V., 257
Norris, Robert F., 756*
Nystrom, Gunnar, 255

O

Obesity, state of heart in, 757*
Occlusion, acute arterial, of extremities, 125*
complete, of superior mesenteric artery with involvement of entire small intestine, 126*
mesenteric, vascular, of arterial and venous origin, 757*
sudden, of arteries of extremities, 383*
Ocko, F., Katz, L. N., Bohning, A., Jochim, K., Korey, H., and Robinow, M., 17
Okelberry, Alfred M., White, J. C., and Whitelaw, G. P., 380*
Olivet, 497*
Orgain, Edward S., Wearn, J. T., Moritz, A. R., Dowling, A. S., Haskin, G. E., and Hudson, C. L., 7
Orias, O., Battro, A., and Braun-Menendez, E., 628*
Orskov, S. L., Hartmann, H., and Rein, H., 385*
Orthodiagraphic study of college students who showed no evidence of heart disease, 387
Oxygen content and carbon dioxide content of arterial and venous blood of normal subjects, 504*
deficiency and circulatory insufficiency, 749*
saturation of arterial blood in man, 498*

P

Pain, cardiac, 254 (book review)
reduction in circulation through hand resulting from, 251*
relief of, by peripheral nerve block in arterial disease of lower extremity, 246*
Pal, J., 247*
Palme, F., 498*
Palmer, J. H., 630*
Pancreatic substance, use of, in treatment of hypertension, 378*
Parade, G. W., 750*
Parasystole, unusual effects of small doses of strophanthin on rhythmicity and conductivity of heart, and its relation to, 751*
Parkinson, John, 124*
—, and Bedford, D. E., 754*
Paschkis, K., 744*
Paterson, J. C., 127*
Pearl, Felix, 507*
Periarteritis nodosa, clinical aspects of, 382*
Pericarditis, adhesive, constriction of pulmonary artery by, 470
Pericardium, concretion of, 753*
Pfuhl, Wilhelm, 120*
Phototones, registration and reproduction of heart sounds by, 241*
Pichler, E., and Hoff, H., 249*
Pick, A., 750*
—, and Block, C., 749*
—, and Langendorf, R., 750,* 751*
Pickering, G. W., 756*
Poisoning, experimental, acute, of heart, dynamic effect of, with diphtheria toxin, 693
Polanco, Mario, 753*
Polycythemia, vascular complications of, 257
vera, cardiac output in, 746
Porter, William P., 550
Potassium iodide, inhibition of experimental atherosclerosis by, and colloidal silicic acid, 627*
Pregnancy, circulation in, 251*
Pressure, equalizer (*see* Balloon)
mean, of man in normal and pathological states, 256 (book review)
Prolan, presence of substance like, in urine of patients with essential hypertension, 631*
Pulse recording with electrical transmission, 379*
tracing of, mobile unit for recording simultaneously, heart sounds, electrocardiogram and, 731
venous, contour of, in silicosis, 760*
jugular, 377*
Purpura, thrombocytopenic, acute, nonbacterial thrombotic endocarditis associated with, 243*

Q

Quattlebaum, James T., 95

R

Raab, W., and Schlomka, G., 379*
Radioactive substance, introduction into organism, state of heart following, 376*
Radiokymography in total atrioventricular block, 252*
Randall, William Lloyd, and Korns, H. M., 114
Ranke, O. F., 498*
Raynaud's disease and neurovegetative-hormone system, 506*
control of sympathectomized blood vessels by sympathomimetic hormones and its relation to surgical treatment of, 380*
critical review, 383*
Refractory phase, action of extracts of bulbus scillae and scillaren on conduction system and, of frog's heart, 745*
Rein, 496*
Rein, H., Hartmann, H., and Orskov, S. L., 385*
Reindell, H., and Schlomka, G., 123*
Respiration, effect of ventricular asystole on, 239*
metabolism, meaning of, for heart and, 496*

Rheumatic fever, acute, mechanism of impaired auriculoventricular conduction in, 413
specific and nonspecific changes in blood protein during, with carditis, 754*
erythema nodosum pathogenesis and, 746*
mechanism of, 755*
Rheumatic infection in childhood, sedimentation rate and Schilling count in, 124*
Rib, cervical, associated with aneurysm of subclavian artery, 507*
vascular complication unusual in, 508*
Robinow, M., 104
—, Katz, L. N., Bohning, A., Gutman, I., Jochim, K., Korey, H., and Ocko, F., 17
Roddis, Louis H., 256
Roentgenogram, barium-filled esophagus, use of, in, of abnormalities of heart and aorta, 723
Roentgen kymogram findings in heart-block, 751*
kymography in diseases of heart, 760*
Roeske, 748*
Roesler, H., Gifford, U. G., and Betts, W., 426
Roth, Irving R., Lingg, C., and Whittemore, A., 36
Rothberger, C. S., and Goldberg, M., 630*
—, and Gottdenker, F., 627*
—, and Zwillinger, L., 751*

S

Sampson, John J., 746*
—, and Eliaser, M., Jr., 675
Sappington, S. W., and Cook, H. S., 757*
Schauer, Gerhard, Gross, L., and Mendlowitz, M., 647, 664
Schilling count in rheumatic infections in childhood, 124*
Schlomka, G., and Raab, W., 379*
—, and Gauss, G., 750*
—, and Reindell, H., 123*
Schmitt, H., 756*
Schneider, M., Grosse-Brockhoff, F., and Schoedel, W., 748*
Schoedel, W., 744*
—, Grosse-Brockhoff, F., and Schneider, M., 748*
Schott, Adolf, 61
Schreyer, K., 627*
Schütz, E., and Lueken, B., 499*
Schwartz, Sidney P., 751*
Schwedel, J. B., 723
Sciatica, unilateral, difference in skin temperatures between lower extremities, 501*
Scillae, bulbus, extracts of, action of, on conduction system and refractory phase of frog's heart, 745*
Scillaren, bulbus, extracts of, action of, on conduction system and refractory phase of frog's heart, 745*
Sclerosis, calcific, of aortic valve, 242*
Scuderi, Carlo S., and Jirka, F. J., 126*
Scupham, George W., and de Takats, G., 125*
Seamen, heart disease among, 197
Secher, K., and Geill, T., 757*
Sedimentation rate, high, development of, in rheumatic carditis, 245*
in rheumatic infections in childhood, 124*
Segura, Angel S., 122,* 244*
Serous membranes, inflammation of, nonbacterial, thrombotic endocarditis, associated with, 243*
Serum therapy, failure of, and human immune transfusions in subacute Streptococcus viridans endocarditis, 619
Shipley, Louise J., Shipley, R. A., and Wearn, J. T., 744*
Shipley, R. A., Shipley, L. J., and Wearn, J. T., 744*
Shock, surgical, peripheral blood flow in, 251*
pharmacological study of toxemia theory of, 500*
Short, James J., Bruger, M., and Jaffe, L., 246*
Siebeck, 497*
Siedek, H., and David, F., 504*
Sikl, H., 242*
Silbert, Samuel, 507*
Silicic acid, colloidal, experimental atherosclerosis, inhibition of, by potassium iodide and, 627*
Silicosis, venous pulse contour in, 760*
Simmendenger, W., Gotsev, T., and Lucken, B., 505*
Sinus, carotid, chemical receptors of, 498*
coronary, outflow of, validity of criterion of coronary reactions, 743*
Smirk, F. H., 758*
—, and Barsoum, G. S., 759,* 760*
Smith, Beverly C., 246*
Smith, Harry L., and Hinshaw, H. C., 741
Smithwick, R. H., 506*
Society for Digestive and Metabolic Disorders, communication, 495*
Society of German Biologists and Physicians, communication, 496*
Socio-medical needs for cardiac patients, 761*
Sodium fluoride, heart poisoned by lactic acid, and metabolism of spontaneously failing heart and, 627*
nitrite, nature of circulatory collapse induced by, 503*
Sohval, Arthur R., and Friedberg, C. K., 599
—, and Gross, L., 242*
Solandt, D. Y., Bronk, D. W., Ferguson, L. K., and Margaria, R., 119
Sorsky, Eliot, and Wood, P., 183
Spectrophotometer and blue azo dye, use of, in clinical blood volume studies, 747*
Sperry, Warren M., and Landé, K. E., 125*
Spiegel, Rose, 382*
Spink, Wesley W., 746*
Splanchnic region, influence of, upon systemic blood pressure, 505*
Sport, circulation in, 385*
Springorum, W., 499*
—, and Centenera, D., 498*
Steele, J. Murray, 542
Steinberg, Bernhard, and Mundy, C. S., 240*
Stenosis, congenital, of abdominal aorta, 633
Strauss, L. H., 627*
Stromuhr, Rein, blood flow of both kidneys studied with, 498*
Strophanthin, effects, unusual, of small doses of, in rhythmicity and conductivity of heart and its relation to parasystole, 751*
sensitivity to, of heart with insufficient valves with and without hypertrophy, 121*
Struthers, R. R., and Bacal, H. L., 124*
Suction, systolic, of human heart, 498*
Sunder-Plassmann, P., and Muller, K., 506*
Suprarenal substance, cardiac minute volume in intact animal following, 499*
intravenous administration of, response to, by normal and hypertensive individuals as measured by cutaneous temperatures, 1
secretion of, intensification by eserine of action of acetylcholine upon 628*

Sympathectomy, subjects injected intra-arterially, action of acetylcholine on, 631*
value of, in treatment of vascular disease, 506*
Syncope, cardiac, clinical, differentiation of types, 88
pathology and pharmacology of, and sudden death, 240*
Syphilis, cardiovascular, studies in, 297
Systole, relative duration of, significance of, 379*

T

Tachycardia, strophanthin and barium, action of magnesium on, 751*
de Takats, Geza, 125*
—, and Scupham, G. W., 125*
Taussig, Helen B., 754*
Teleroentgenography in diagnosis of early syphilitic aortitis, 297
Temperature, cutaneous, response of digital arterioles of normal and hypertensive individuals to intravenous administration of epinephrine as measured by, 1
depth, in artificial fevers and cooling air chambers with special reference to cooling effect of circulatory blood, 746*
rectal body, elevation of, following mechanical obstruction of peripheral circulation, 542
skin, differences in, between lower extremities unilateral sciatica, 501*
Thiel, 497*
Thomas, Henry M., Jr., 239*
Thompson, William Paul, Golden, S. E., and White, P. D., 534
Thomson, K. Jefferson, and Cohen, M. E., 251*
Thorium dioxide, arteriography by, demonstration of ruptured popliteal aneurysm, 127*
study of acquired arteriovenous fistula, 247*
Thörner, 495*
Thorotrast (*see* Thorium dioxide)
Thromboangiitis obliterans and Addison's disease in the same patient, 507*
in negroes, 511
in women, 373
transmission, accidental, from man to man, 384*
Thrombophlebitis, venography in, 758*
Thrombosis, aortic, and coronary artery with "fibrinoid" lesions, 126*
arterial, extensive, and venous, complicating chronic ulcerative colitis, 125*
coronary, acute, and myocardial infarction affecting a patient thirty-one years of age, 741
heart failure and other factors in its course and prognosis, 330
size of heart after, 630*
venous, acute, arterial spasm in, 247*
extensive, and arterial, complicating chronic ulcerative colitis, 125*
Thyroxin, action of, upon capacity for work and upon strophanthin sensitivity of cat's heart, 121*
Tilk, G. V., 761*
Tirala, L. G., 380*
Tobacco, control of habit, 128*
Tonsillitis, myocardium and, 378*
Toxemia theory of surgical shock, pharmacological study of, 500*
Transfusion, immune, human, failure of, and serum therapy in subacute streptococcus viridans endocarditis, 619
Trauma, mental and physical, heart arrhythmias following, 750*
Trepopnea, tolerance of certain cardiac patients for various recumbent positions, 745*
Trigonoidation of semilunar valves and relation to certain basal systolic murmurs, 362
Tube, hydraulic, phenomenon of, genesis of embryonic heart action on basis of, 744*
Tuberculosis, erythema nodosum, pathogenesis of and, 746*
Typhoid fever, electrocardiographic alterations produced by, in children, 123*

U

Udvardy, L., 238*
Ulrich, B., 239*
Uprus, V., Gaylor, J. B., and Carmichael, E. A., 508*
Urban, H., 239*

V

Valve, aortic, insufficiency of, work of left ventricle in, 241*
with and without hypertrophy in heart-lung preparations, capacity for work of hearts with, 121*
sclerosis, calcific, of, 242*
trigonoidation of, and relation to certain basal systolic murmurs, 362
heart, normal and abnormal, incidence and significance of blood vessels in, 7
tricuspid, stenosis of, circulatory dynamics of, 589
Valves, atrioventricular, leaflets of, extravasations, hemorrhagic, into, 124*
Van Dellen, Theodore R., and Wright, I. S., 373
Vaquez, H., and Gley, P., 256
Vascular system, disease of, and heart, 509 (book review)
peripheral, surgical treatment of, 125*
value of sympathectomy in, 506*
lesion widespread, of, endocarditis, thrombotic, nonbacterial associated with, 243*
peripheral, obstruction of, two quantitative tests of, 126*
regulation of humeral counter, 249*
symptoms in reversible autohemagglutination with, 386*
vasomotor control of, 250*
Vasodilator substances, action of, on work and blood flow of active skeletal muscles, 744*
vasomotor interferences in nerve plexus of skeletal muscle vessels induced by, following hyperemia, 748*
Vasomotor center, acetylcholine action of, on, 748*
interference in nerve plexus of skeletal muscle vessels induced by vasodilator substances following hyperemia, 748*
Veins, blocking of, gangrene from, 382*
occlusion, intermittent, treatment of peripheral obliterative arterial diseases by, 247*
peripheral, in rheumatic disease, 498*
rôle of, in circulatory collapse induced by sodium nitrite, 503*
thrombosis, extensive, of, and artery, complicating chronic ulcerative colitis, 125*
Venography in thrombophlebitis, 758*
Ventricle, left, work of, in aortic insufficiency, 241*
Vial, J., Hermann, H., Jourdain, F., and Morin, G., 628*

Vires, J., May, P., and Balmis J., 386*
Vitamin B_1, treatment by intravenous administration of, of acute pernicious beriberi, 580
Vodel, 498*
Volhard, F., 496*

W

Wachtel, H., and Katz, L. N., 202
Wallach, Kaufman, Friedburg, C. K., and Gross, L., 243*
Wearn, Joseph T., Moritz, A. R., Dowling, A. S., Haskin, G. E., Hudson, C. L., and Orgain, E. S., 7
—, Shipley, R. A., and Shipley, L. J., 744*
Weber, A., 241,* 241*
—, and Kayser, G., 241*
Weicker, B., and Nehrkorn, O., 378*
Weiss, Soma, Wilkins, R. W., and Haynes, F. W., 503*
Wezler, K., and Böger, A., 128,* 248,* 376,* 756*
White, James C., Okelberry, A. M., Whitelaw, G. P., 380*
White, Paul D., Glendy, R. E., and Castleman, B., 129
—, Thompson, W. P., and Golden, S. E., 534
Whitelaw, George P., White, J. C., and Okelberry, A. M., 380*
Whittemore, Alice, Roth, I. R., and Lingg, C., 36
Whitten, Merritt B., 701
Wiggers, Carl J., and Johnson, J. R., 743*
Wilensky, Nathan D., and Collens, W. S., 126,* 247*
Wilkins, Robert W., and Ferris, E. B., 431
—, Weiss, S., and Haynes, F. W., 503*
William Withering, 256 (book review)
Witt, D. B., Lindner, E., and Katz, L. N., 693
Wolferth, Charles Christian, and Wood, F. C., 745*
Wolffe, Joseph B., and Digilio, V. A., 378*
Women, thromboangiitis obliterans in, 373
Wood, Francis Clark, and Edelken, J., 387
—, and Wolferth, C. C., 745*
Wood, Paul, and Sorsky, E., 183
Wortis, Joseph, 394
Wright, Irving S., and Van Dellen, T. R., 373

Y

Yater, Wallace M., 127,* 247,* 511

Z

Zwillinger, L., and Rothberger, C. J., 751*